m, for detailed information on pathology books, visit our website www.jaypeebrothers.com, for detailed information on pathology b

Problem-based Questions in PATHOLOGY (with Solutions)

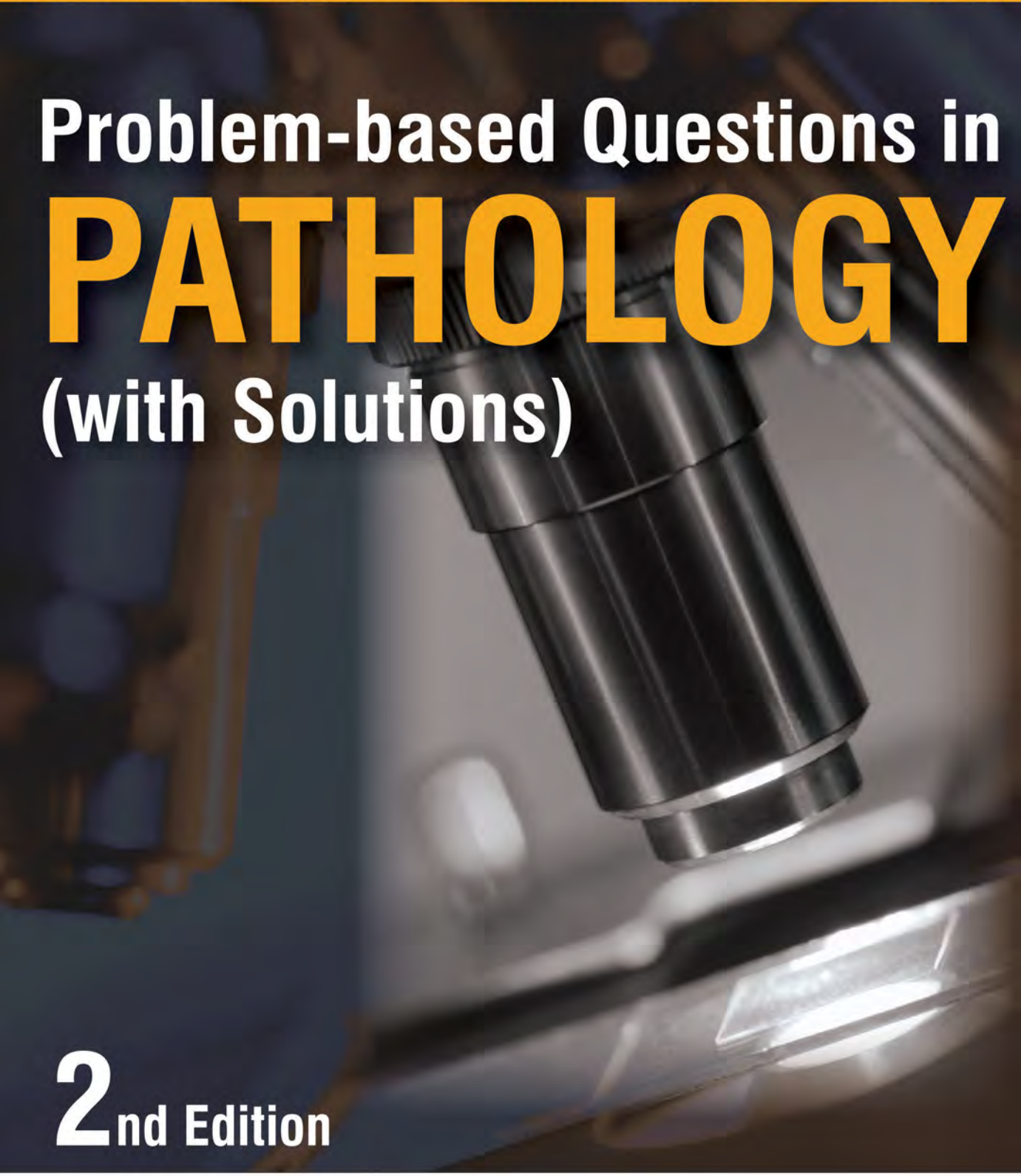

2nd Edition

Sanjay Sengupta

JAYPEE

Contents

Chapter 1: Cardiovascular System **1**

CQ1. A 9-year-old girl from an urban slum seeks medical attention for fever with pain and swelling of both knee and right wrist joints, affected one after another during last 7 days. *1*
- What is your provisional diagnosis?
- What are other possibilities?
- How do you investigate the case?
  - Acute rheumatic fever
  - Juvenile idiopathic arthritis
  - Septic arthritis
  - Valvular heart disease
  - Mitral valve slenosis

CQ2. A 15-year-old boy complaining of palpitation and breathlessness for 1 week. O/E: Fever with tender swelling of left elbow joint; right ankle joint was similarly affected 4 days ago. H/o sore throat 3 weeks before. *8*
- What is your provisional diagnosis?
- How will you confirm your diagnosis?

CQ3. A 5-year-old girl is admitted into hospital with jerky, irregular, uncontrolled movement of both hands for 7 days. There was an attack of febrile polyarthritis involving both elbow and ankle joints about 1 month before. *8*
- What is the most likely diagnosis?
- How will you proceed for confirmation of diagnosis?

CQ4. A boy, aged 16-year-old comes with fever and migratory polyarthritis for 1 week. He is also complaining of palpitation, respiratory distress and chest pain. *9*
- What are the possible causes?
- How will you proceed for diagnosis?
  - Lyme disease

CQ5. A 28-year-old female comes to outdoor with gradually increasing respiratory distress, palpitation and cough for 1 year. On enquiry, past H/o multiple attacks of febrile polyarthritis. *10*
- What are the probable causes?
- How will you investigate the case?
  - Chronic rheumatic heart disease
  - Cardiomyopathy
  - Constrictive pericarditis
  - Primary pulmonary hypertension
  - Rheumatoid heart disease
  - Pericarditis

CQ6. A middle-aged man is complaining of gradually increasing respiratory distress, chronic cough, palpitation, and pedal edema with occasional hemoptysis for last 3 years. He admits multiple attacks of polyarthritis during childhood. *18*
- What is your provisional diagnosis?
- How will you confirm it?

CQ7. A 25-year-old male patient gets admitted into hospital with low-grade, irregular fever for more than 6 weeks. Patient also complains of fatigue, lassitude, palpitation and respiratory distress. Careful history taking unmasks two additional features:
- Presence of gradually increasing breathlessness for last 2 years.
- Past history of multiple attacks of febrile polyarthritis during childhood *18*
- What are the possible causes?
- How will you proceed for diagnosis?
  - Subacute bacterial endocarditis
  - Infective endocarditis

CQ8. A 65-year-old male, living in a slum, alone, comes to outdoor with fatigue, weight loss and malaise for 2 months. Patient is also suffering from chronic cough, occasional hemoptysis and slowly progressive breathlessness for years. O/E: Mucocutaneous petechial spots and subungual hemorrhages seen. *22*
- What is your provisional diagnosis?
- What can be other possibilities?
- Describe the steps for confirmation of diagnosis.

CQ9. A 48-year-old male is complaining of sudden onset severe retrosternal chest pain, diaphoresis and respiratory distress. O/E: Rapid and feeble pulse with cold extremities. *22*
- What are the possible causes?
- How will you pinpoint your diagnosis?
  - Myocardial infarction
  - Pulmonary embolism with infarction
  - Aortic dissection
  - Tension pneumothorax
  - Acute bacterial pneumonia
  - Acute pancreatitis (brief)
  - Ischemic heart diseas
  - Atherosclerosis
  - Hypertensive vascular diseases
  - Health hazards of tobacco

CQ10. A 39-year-old male smoker with hypertension suddenly develops severe left sided chest pain with extension to left arm, sweating, respiratory distress and syncopal attack. *45*
- What are the possibilities?
- How will you investigate the case?

CQ11. A 65-year-old diabetic male gets admitted into hospital with mild retrosternal discomfort, breathlessness, tachycardia and progressively falling blood pressure for 3 hours. *45*
- What is the most likely diagnosis?
- How will you establish your diagnosis?

CQ12. A 56-year-old female, in the postoperative period, suddenly developed severe chest pain, breathlessness, cough with hemoptysis and pyrexia. *45*
- What is your provisional diagnosis?
- How will you proceed for diagnosis?

CQ13. A 33-year-old male smoker comes to surgical outdoor with severe pain in both lower limbs, particularly during walking, with bilateral wasting of calf muscles and ulceration over right great toe. *45*
- What is your provisional diagnosis?
- How will you justify your diagnosis?
  – Buerger's disease

CQ14. A 56-year-old male, complaining of severe headache over right temporal region for 3 months, suddenly developed dimness of vision of right eye. O/E: Dilated, tender blood vessel over temporal region. *46*
- What is the most likely diagnosis?
- How will you investigate the case?
  – Temporal arteritis

CQ15. A 25-year-old young femal seeks medical attention with coldness and numbness of fingers, vertigo and dimness of vision. O/E: Radial pulse on both upper limbs very weak. *47*
- What is your diagnosis?
- How will you establish your diagnosis?
  – Takayasu's arteritis

CQ16. A 30-year-old female presenting with a small, elevated, firm and tender nodule, reddish in color, at the subungual region of left second finger. *48*
- What is your provisional diagnosis?
- How will you confirm your diagnosis?
  – Glomus tumor

CQ17. A 36-year-old homosexual male, HIV +ve for 7 years, developed rapidly progressive multiple reddish nodules over ankle and calf of right leg with right popliteal and inguinal lymphadenopathy. *48*
- What are those lesions?
- How can you confirm the diagnosis?
  – Kaposi's sarcoma

CQ18. Teenage girl comes for consultation with excessive pain and swelling of both knee and elbow joints for a week. H/o cold, cough, fever and throatache 2 weeks prior to onset of presenting symptoms is present. *50*
- What is your provisional diagnosis?
- What can be other possibilities?
- How will you approach for diagnosis?

CQ19. A 39-year-old female, presented with slowly developing breathlessness, chronic cough and occasional hemoptysis for last 3 years. Past H/o repeated attacks of joint swellings with fever during childhood. *50*
- What are the possible causes?
- Discuss lab investigations for confirmation of your diagnosis.

CQ20. A 56-year-old male, smoker and hypertensive, complaining of severe pain in the left side of chest with sweating, palpitation and respiratory distress for 1 hour. *50*
- What are the probable causes?
- Describe the steps for diagnosis.

Chapter 2: Respiratory System 51

RQ1. A 52-year-old male, smoker comes to outdoor with cold, cough, fever, respiratory distress and profuse expectoration for 3 days. Previous history of similar attacks during last 2 years is present. *51*
- What are the possible causes?
- How will you proceed for diagnosis?
  - Chronic bronchitis
  - Bronchial asthma
  - Bronchiectasis
  - Lung abscess
  - Acute bacterial pneumonia

RQ2. A 68-year-old male, smoker presented with gradually increasing respiratory distress for last 1 year with cough, scanty expectoration, and weight loss. *61*
- What are the possibilities?
- How will your confirm your diagnosis?
  - Emphysema
  - Interstitial lung disease
  - Pulmonary tuberculosis

RQ3. A 28-year-old female presented with recurrent episodes of cough, wheezing and respiratory distress for more than 2 years. *71*
- What is the possible cause?
- What can be other possibilities?
- How will you proceed for laboratory investigation of the case?
  - Acute left ventricular failure

RQ4. A middle-aged man came for medical attention with recurrent attacks of fever, weight loss, chest pain, chronic cough, expectoration of foul smelling sputum and clubbing for more than 2 and half years. 73
- What are the possible causes?
- How will you investigate the case?

RQ5. A 5-year-old male child admitted into pediatric ward with high fever, chest pain, palpitation, respiratory distress and expectoration of rusty sputum for 2 days. *74*
- What is your provisional diagnosis?
- How will you investigate the case?

RQ6. A 75-year-old male suffering from bronchogenic carcinoma of left lung developed high fever, chest pain, respiratory distress with productive purulent foul smelling expectorate within a short period. *75*
- What is the most possible complication developed in this case?
- What are other possibilities?
- How will you proceed to diagnose the complication?

RQ7. Female patient, aged 53-year-old presented with low-grade fever, chest pain, weight loss and occasional hemoptysis for last 4 months. *75*
- What are the possibilities?
- How will you diagnose the case?
  - Bronchogenic carcinoma
  - Metastatic lung tumor
  - Lymphoma of lung

RQ8. A 32-year-old adult male seeks medical attention for gradually increasing breathlessness, fever, cough, and occasional hemoptysis with right-sided pleural effusion. *81*
- What is the possible diagnosis?
- What can be other possibilities?
- How can you confirm your diagnosis?

RQ9. A 60-year-old male smoker is complaining of dry cough, occasional hemoptysis, chest pain, anorexia, weight loss and clubbing for 5 months. *81*
- What is your provisional diagnosis?
- How will you establish your diagnosis?

RQ10. A 58-year-old male smoker working in an asbestos factory for 30 years, comes to outdoor with chest pain, weight loss, chronic cough, occasional hemoptysis and shortness of breath for 3 months. O/E: There is shifting of trachea towards left side with dull percussion note over right side of chest. *81*
- What are the possibilities?
- How will you progress for confirmation of diagnosis?
  - Malignant mesothelioma
  - Benign mesothelioma
  - Asbestosis with pleural effusion

RQ11. A middle-aged female complaining of chronic cough, chest pain, and shortness of breath for more than 1 year. Chest X-ray—Bilateral hilar lymphadenopathy. *86*
- What is your provisional diagnosis?
- What other possibilities should come into consideration?
- How will you confirm your diagnosis?
  - Sarcoidosis

RQ12. A 32-year-old female complains of intermittent attacks of diarrhea, cyanosis and flushing for 4 years, along with repeated attacks of bronchoconstriction. She is also complaining of dry cough and occasional hemoptysis during this period. Chest X-ray shows a small, circumscribed nodule in the left lung. *89*
- What is the most possible diagnosis?
- How will you proceed for confirmation of your diagnosis?
  - Bronchial carcinoid

RQ13. A 45-year-old male presents with a small, smooth rounded mass shadow on routine chest X-ray. There is no accompanying symptom. *90*
- What is the most probable diagnosis?
- How will you confirm the diagnosis?
  - Lung hamartoma

RQ14. A 50-year-old male, nonsmoker, seeks medical attention for cough with expectoration, often blood tinged, weight loss, anorexia, chest pain and evening rise of temperature for 3 months. *91*
- What is your provisional diagnosis?
- What can be other possibilities?
- Describe the steps for confirmation.

RQ15. A 29-year-old young femal was admitted to hospital with cough, occasional hemoptysis, low-grade fever and slowly developing breathlessness for more

than 1 year. O/E: Bilateral iritis, parotitis, cervical lymphadenopathy and hepatosplenomegaly. *91*
- What are the possibilities?
- How will you confirm your diagnosis?
  – Sjögren's syndrome

RQ16. A 58-year-old female seeks medical attention for dry cough, occasional hemoptysis, chest pain, and weight loss for last 6 months. Chest X-ray shows single large irregular opacity on peripheral portion of lower lobe of right lung *92*
- What is your provisional and differential diagnosis?
- Describe steps for confirmation of your diagnosis.

RQ17. A 72-year-old male, smoker, gets admitted with dry cough, occasional hemoptysis, chest pain, anorexia, and weight loss for last 2 months. O/E: Vague lump in the right iliac fossa along with hard right supraclavicular lymph node. *93*
- What is the most likely diagnosis?
- What are other possibilities?
- Describe steps for confirmation of diagnosis.

RQ18. A 73-year-old male, heavy smoker for more than 30 years, developed chronic cough, hemoptysis, chest pain, and weight loss for last 3 months.CT scan of the lung shows a large central shadow with irregular, infiltrating margins. Blood biochemistry shows hypercalcemia *93*
- What is your provisional diagnosis?
- How will you approach for confirmation?

RQ19. A 68-year-old male, smoker, presented with breathlessness, cough, and chest pain for 2 months. O/E: Ptosis with puffy face, swelling, and congestion of upper part of chest and neck, hoarseness of voice, clubbing along with tender swelling of right wrist joint. *93*
- What is the most likely diagnosis?
- How can you explain all the features?
- What are other causes and how will you proceed for diagnosis?
  – Thymoma

RQ20. A 72-year-old female, presented with intense chest pain, anorexia, weight loss, cough with occasional hemoptysis for 1 month. She also complained of intermittent flushing and diarrheal attacks. O/E: Muscular weakness and peripheral neuropathy of both lower limbs seen. Serum electrolyte study showed hyponatremia. *95*
- What is your provisional diagnosis?
- What can be other possibilities?
- How will you confirm your diagnosis?

RQ21. A 50-year-old male, smoker, with weight loss, chest pain, cough, and hemoptysis for 3 months. Chest X-ray: Large SOL at central portion of left lung. *95*
- What is your provisional diagnosis?
- How will you confirm your diagnosis?

RQ22. A 27-year-old female, nonsmoker, complaining of chronic cough, night sweat, weakness, slowly developing breathlessness and cervical lymphadenopathy. *95*
- What are the possibilities?
- How will you investigate the case?

RQ23. A middle-aged man with long-standing diabetes presented with low-grade fever for 2 months with chronic cough and occasional hemoptysis. *95*
- What is your provisional diagnosis?
- What are other possibilities?
- Describe steps for diagnosis.

RQ24. A 59-year-old male, working in sand blasting, gradually developed shortness of breath with chronic cough. *95*
- Chest X-ray showed fine nodular shadows in the upper part of both lungs.
- What are the possible causes?
- How can you confirm your diagnosis?

RQ25. A 9-year-old female child presented with sudden onset of fever with chill and rigor, chest pain, cough, and respiratory distress. *95*
- What is the most likely diagnosis?
- What should be your approach for confirmation of diagnosis?

Chapter 3: Gastrointestinal Tract, Hepatobiliary System and Pancreas 96

GQ1. A middle-aged alcoholic male gets admitted into emergency ward with epigastric pain and hematemesis for 24 hours. He admits frequent attacks of pain particularly during empty stomach in the recent past. *96*
- What is your provisional diagnosis?
- What can be other possibilities?
- How will you confirm your diagnosis?
  - Peptic ulcer
  - Zollinger-Ellison syndrome
  - Gastric carcinoma
  - Acute gastric ulcerations
  - Bleeding esophageal varices
  - Cirrhosis of liver
  - Esophageal tear

GQ2. A 36-year-old male comes to emergency with severe epigastric pain and vomiting for 5 hours. *107*
- What are the possibilities?
- How will you investigate the case?
  - Acute pancreatitis (detailed including pancreatic pseudocyst)
  - Acute cholecystitis
  - Chronic cholecystitis

GQ3. A middle-aged female seeks medical attention for a lump in the epigastric region with anorexia and vomiting for 3 months. *114*
- What can be the possibilities?
- What will be your line of approach for correct diagnosis?
  - Metastatic liver tumors
  - Hepatocellular carcinoma
  - Carcinoma of gallbladder
  - Carcinoma of the pancreas

GQ4. A 66-year-old female presents with anorexia, weight loss and weakness for 6 months. There is also history of hematemesis. O/E: There is a palpable lump over epigastric region. *118*
- What is your provisional diagnosis?
- What are other possibilities?
- How will you investigate the case?

GQ5. A 63-year-old female comes to outdoor with fatigue, weight loss, anorexia and weakness of both lower limbs for 3 months. O/E: There is a palpable lump over epigastric region. Routine blood examination shows: Low hemoglobin concentration and hypersegmented neutrophils with macro-ovalocytes. *118*
- What is your provisional diagnosis?
- How will you confirm your diagnosis?

GQ6. A 39-year-old female presented with fever associated with chill and rigor and tender hepatomegaly. *119*
- What are the causes?
- How can you confirm your diagnosis?
  - Amebic liver abscess
  - Pyogenic liver abscess
  - Ascending cholangitis

GQ7. A 49-year-old female complaining of nausea, anorexia, and pain abdomen for last 6 months. O/E: There is tenderness with a lump in the right hypochondrial region. *121*
- What are the possibilities?
- How can you confirm your diagnosis?

GQ8. A 36-year-old male presenting with anorexia low-grade fever, vomiting, pain abdomen and yellowish discoloration of urine for 1 month. *123*
- What is the most probable diagnosis?
- What are other possibilities?
- How will you proceed for diagnosis?
  - Infective hepatitis
  - Choledocholithiasis
  - Jaundice

GQ9. A 63-year-old male patient presents with anorexia, weight loss and dysphagia to solid food for last 2 months. He also admits occasional bouts of hematemesis in recent past. *136*
- What is your provisional diagnosis? What can be other possibilities? How will you confirm your diagnosis?
  - Malignant tumors of esophagus
  - Reflux esophagitis

GQ10. A 58-year-old male presents with ascites, pedal edema, anorexia, weight loss, muscle wasting of the extremities for last 4 years. He also complains of three attacks of hematemesis and malena during last 1 year. *139*
- What are the possible causes? How can you confirm your diagnosis?
  - Alcoholic liver disease (fatty liver, alcoholic hepatitis, alcoholic cirrhosis)
  - Adverse effects of alcohol

GQ11. A 32-year-old female gets admitted into medicine ward with anorexia, vomiting and ascites for 1 year. On enquiry there is intense pruritus, deep yellow urine and clay colored stool. O/E: There is hepatosplenomegaly. *147*
- What are the possibilities?
- How will you investigate the case?
  - Primary biliary cirrhosis
  - Secondary biliary cirrhosis
  - Primary sclerosing cholangitis

GQ12. A 23-year-old male presents with fluctuating hyperbilirubinemia, predominantly unconjugated, for years without illness. *151*
- What is your provisional diagnosis?
- What may be other possibilities?
- How can you confirm your diagnosis?
  - Gilbert's disease
  - Crigler-Najjar syndrome
  - Dubin-Johnson syndrome
  - Rotor's syndrome
  - Hemolytic jaundice

GQ13. A 22-year-old male presented with fatigue, weight loss, bouts of low-grade fever, anorexia and multiple attacks of jaundice for last 3 years. O/E: There was tender hepatomegaly. *153*
- What are the possible causes?
- How will you confirm your diagnosis?
  - Wilson's disease
  - α_1 antitrypsin deficiency (hepatic injury)
  - Drug-induced hepatitis
  - Autoimmune hepatitis

GQ14. A 8-year-old male child admitted into pediatric ward with anorexia, nausea, weight loss and ascites for 1 year. O/E: Spleen is enlarged with presence of dilated veins over anterior abdominal wall. *158*
- What are the possible causes?
- How will you investigate the case?
  - Indian childhood cirrhosis

GQ15. A 53-year-old female presented with hepatomegaly. Ultrasonography showed a single large mass on right lobe of liver. *160*
- What can be the possibilities?
- How will you investigate the case?
  - Hydatid cyst

GQ16. A 41-year-old fatty female presented with nausea, vomiting, indigestion and right upper abdominal pain for 7 days. Past H/o frequent attacks of similar symptoms during last 2 years. *163*
- What is your provisional diagnosis?
- What are other possibilities?
- How will you confirm the case?
  - Chronic gastritis

GQ17. A 28-year-old male presents with frequent passage of bulky, frothy, greasy stool with abdominal distension, muscle wasting, fatigue and weight loss for more than 1 year. *165*
- What are the possible causes?
- How can you confirm your diagnosis?
  - Celiac disease
  - Tropical sprue
  - Whipple disease
  - Giardia lamblia infection
  - Crohn's disease

GQ18. A 4-year-old male child presents with anorexia, loss of weight, failure to thrive and frequent passage of bulky, frothy stool with abdominal distension and indigestion for more than one year. *173*
- What can be the possible causes?
- Give an outline for confirmation of your diagnosis.
  - Malnutrition-related malabsorption
  - Lactase deficiency
  - Abetalipoproteinemia
  - Cystic fibrosis

GQ19. A 36-year-old female presents with frequent attacks of diarrhea, weight loss, fever and abdominal pain for last 3 years. *177*
- What are the possible causes?
- How will you investigate the case?
  - Ulcerative colitis
  - Irritable bowel syndrome

GQ20. A 33-year-old female is admitted into emergency ward for frequent bouts of bloody diarrhea with tenesmus and toxic features. H/o similar attacks twice during last 1 year are reported. *184*
- What are the possible causes?
- How will you confirm your diagnosis?
  - Bacillary dysentery
  - Ischemic bowel disease

GQ21. A 58-year-old male presenting with weakness, fatigue, weight loss and alteration of bowel habit for more than 6 months. O/E: There is pallor. Stool for occult blood test: (+) ve. *188*
- What are the possible causes?
- How will you investigate the case?
  - Colorectal carcinoma
  - Carcinoid tumor
  - GI tract lymphomas
  - Colorectal polyps
  - Hookworm infestation

GQ22. A 63-year-old male presented with alternate attacks of diarrhea and constipation for 3 months with an ill-defined vague lump in the iliac fossa. *198*
- What are the possible causes?
- How will you confirm your diagnosis?
  - Ileocecal tuberculosis

GQ23. Teenage girl comes to emergency with acute pain in the right iliac fossa with vomiting and fever for 12 hours. *200*
- What are the possible causes?
- How will you proceed for diagnosis?
  - Acute appendicitis
  - Meckel's diverticulitis
  - Amebic colitis
  - Acute salpingitis
  - Ovarian torsion
  - Acute cystitis

GQ24. A 72-year-old male admitted into emergency ward with pain in the right lower abdomen and vomiting. O/E: There is an ill-defined mass in the right iliac fossa. *205*
- What are the possible causes?
- How can you confirm your diagnosis?

GQ25. A 69-year-old male presented with anorexia, weight loss and pallor for 6 months. O/E: There was hepatomegaly and a vague, ill-defined mass in the right lower abdomen. *206*
- What is your provisional diagnosis?
- How can you investigate the case?

GQ26. A 59-year-old male and known alcoholic, complains of gradual swelling of abdomen and pedal edema for 2 years. There was about of hematemesis 2 months back. *206*
- What is your provisional diagnosis?
- How will you investigate the case?

GQ27. A 71-year-old male seeks medical attention for recent development of constipation for 1 month. He is suffering from weakness, fatigue and anorexia for 6 months. O/E: Pallor, palpable liver and a vague lower abdominal mass. *206*
- What is your provisional diagnosis?
- How can you confirm your diagnosis?

GQ28. Teenage girl comes to you with anorexia, nausea, vomiting and fever for 3 days. She also complains of yellowish discoloration of urine. *206*
- What are the possible causes?
- How will you approach for diagnosis?

GQ29. A 70-year-old male patient presents with anorexia, weight loss, fatigue and upper abdominal pain for 2 months. O/E: Liver is palpable with sharp margin. *206*
- What can be the possible etiologies?
- What should be your line of investigation?

GQ30. A 25-year-old female gets admitted into emergency ward with bloody dysentery, pain abdomen and features of shock. *207*
- What are the possible causes?
- How will you reach diagnosis?

GQ31. A 56-year-old male smoker is complaining of acidity and pain upper abdomen for 1 year. He has one attack of hematemesis. *207*
- What are the likely causes?
- How will you investigate the case?

GQ32. A 5-year-old girl presents with ascites and pedal edema for 1 year. O/E: There is splenomegaly. *207*
- Enumerate possible causes.
- Discuss the investigations you want to perform for confirmation of diagnosis.

GQ33. A 20-year-old male presented with fever, upper abdominal pain, anorexia, nausea and yellowish discoloration of urine for 5 days. *207*
- What is your provisional diagnosis?
- How will you propose to investigate the patient?

Chapter 4: Genitourinary System **208**

GUQ1. A 40-year-old male presents with weakness, fatigue, polyuria, hypertension and occasional hematuria for 3 years. O/E: Bilateral abdominal lumps at flanks. *208*
- What are the possible causes?

- How will you investigate the case?
  - Adult polycystic kidney
  - Childhood polycystic kidney disease
  - Most common causes of hydronephrosis
  - Renal calculi

GUQ2. A 6-year-old girl comes to outdoor with puffy face, pedal edema, oliguria and hematuria for 1 week. O/E: There is hypertension. *214*
- What is your provisional diagnosis?
- What can be other causes?
- How will you investigate the case?
  - Acute (poststreptococcal) proliferative glomerulonephritis
  - Nonstreptococcal glomerulonephritis
  - Rapidly progressive glomerulonephritis
  - IgA-nephropathy (Berger's disease)

GUQ3. A 4-year-old boy is brought to you with generalized swelling of the body (anasarca) for 5 days. Urine examination shows marked proteinuria. *219*
- What is your provisional diagnosis?
- Enumerate the causes and how will you confirm your diagnosis?
  - Lipoid nephrosis (minimal change glomerulonephritis)
  - Membranoproliferative glomerulonephritis
  - Membranous glomerulonephritis
  - Focal segmental glomerulosclerosis

GUQ4. A 42-year-old female admitted into hospital with anasarca and hypertension for 2 weeks. Routine urine examination shows massive proteinuria. *226*
- What is your provisional diagnosis?
- What are the causes of development of this disease?
- How will you establish the etiology?
  - Diabetes mellitus
  - Amyloidosis
  - Systemic lupus erythematosus (SLE)

GUQ5. A 33-year-old female comes to outdoor with generalized swelling of the body. O/E: There are malar rashes, photosensitivity, pain and swelling of both knee joints. Routine urine examination shows heavy proteinuria. *253*
- What is the possible diagnosis?
- How will you investigate the case?

GUQ6. A 29-year-old male presented with anasarca and heavy proteinuria. On enquiry, there was long standing H/o diabetes mellitus. *254*
- What is your diagnosis?
- How will you confirm your diagnosis?

GUQ7. A 53-year-old female, suffering from rheumatoid arthritis for more than 15 years, gradually develops difficulty in articulation, anasarca and heavy proteinuria. O/E: There is macroglossia and irregular pulse rate. *254*
- What is the possible diagnosis?
- How will you confirm it?

GUQ8. A 42-year-old female presents with hematuria, proteinuria, hypertension and hemoptysis for 2 weeks. *254*
- What is your provisional diagnosis?
- What are other causes?
- How will you confirm your diagnosis?
  - Wegener's granulomatosis
  - Malignant hypertension
  - Renal cell carcinoma with metastasis to lung

GUQ9. A 15-year-old girl complains of acute abdominal pain, knee joint swelling, hematuria and purpuric rashes over buttock. *261*
- What is the provisional diagnosis?
- What can be other possibilities?
- How will you confirm your diagnosis?
  - Henoch-Schönlein purpura

GUQ10. A 30-year-old male is presenting with severe oliguria, hypertension and edema for last 24 hours. H/o hematuria for 2 weeks; patient was symptomless 2 weeks back. *262*
- What is your provisional diagnosis?
- What will be your approach for confirmation of diagnosis?
  - Rapidly progressive glomerulonephritis (RPGN)

GUQ11. A 63-year-old male presents with slowly progressive weakness, anorexia, fatigue and weight loss for 1 year. O/E: There is edema and hypertension. Investigation: Urine protein ++; Blood urea – 86 mg%; Serum creatinine – 3.2 mg% *263*
- What is your provisional diagnosis?
- What are the most common causes?
- How will you differentiate the conditions?
  - Chronic glomerulonephritis
  - Chronic pyelonephritis
  - Analgesic abuse nephropathy

GUQ12. A 51-year-old male admitted to emergency ward with anuria for 24 hours following an attack of diarrhea and vomiting for 3 days. *268*
- What can be the possibilities?
- How will you investigate the case?
  - Acute tubular necrosis (ATN)
  - Hemolytic-uremic syndrome (HUS)

GUQ13. A 36-year-old female presents with fever associated with chill and rigor, malaise, vomiting, dysuria, frequency and pain at right costovertebral angle for 5 days. *271*
- What can be the possibilities?
- How will you investigate the case?
  - Acute pyelonephritis

GUQ14. A 28-year-old female presenting with fever, accompanied by chill and rigor, vomiting, dysuria, hematuria and severe pain in the lower abdomen for 24 hours. *273*
- What are the possible causes?
- How will you investigate the case?
  - Ureteric calculi
  - Lower urinary tract infection

GUQ15. A 54-year-old male presented with repeated attacks of hematuria for last 6 months. *275*
- What are the possible causes?
- How will you confirm your diagnosis?
  - Renal tuberculosis
  - Carcinoma of urinary bladder

GUQ16. A 63-year-old male presents with recurrent hematuria for last 3 months with mild left costovertebral pain. O/E: There is a palpable swelling at left flank. *280*
- What is your provisional diagnosis?
- What can be the differential diagnosis?
- How can you investigate the case?

GUQ17. A 52-year-old male presents with intermittent hematuria for 3 months with attacks of frequency and dysuria. *280*
- What are the possible causes?
- How will you investigate the case?
  - Chronic prostatitis
  - Acute prostatitis
  - Chronic cystitis
  - Acute cystitis
  - Hunner's ulcer
  - Cystitis glandularis
  - Malakoplakia

GUQ18. A 53-year-old male presented with painless hematuria for 4 months along with rapidly developing left sided varicocele. O/E: There is a lump over left flank. *283*
- What is your provisional diagnosis?
- How will you confirm your diagnosis?

GUQ19. A 3-year-old male child is brought to pediatric outdoor with rapidly increasing abdominal lump for 2 months. Associated symptoms are fever, hematuria and weakness. *283*
- What is your provisional diagnosis?
- What can be other possibilities?
- How will you investigate the case?
  - Wilm's tumor
  - Neuroblastoma
  - Rhabdomyosarcoma arising from lower genitourinary tract

GUQ20. A 46-year-male comes with an elevated, ulcerated lesion over glans penis, present for 2 months. *288*
- What are the possible causes?
- How can you confirm your diagnosis?
  - Invasive carcinoma of penis
  - Verrucous carcinoma of penis
  - Carcinoma in situ of penis
  - Condyloma acuminatum
  - Syphilis

GUQ21. A 5-year-old male comes to outdoor with a nontender, small right-sided inguinal swelling present since birth. O/E: Right scrotal sac is empty. *294*
- What is your provisional diagnosis?
- What are the investigations you want to perform for confirmation?
  - Cryptorchidism

GUQ22. A 16-year-old male comes to outdoor with high fever and bilateral testicular swelling for 2 days. On enquiry, there is H/o fever and bilateral parotitis 1 week back. 295
- What is your provisional diagnosis?
- How can you confirm your diagnosis?
  - Mumps and mumps orchitis

GUQ23. A 56-year-old male presents with a cauliflower-like growth with central ulceration over glans penis for 2 months. O/E: The mass is nontender. There are also two discrete firm lymph nodes in the left inguinal region. *297*
- What is your provisional diagnosis?
- How will you confirm your diagnosis?

GUQ24. A male aged 63-year-old seeks medical attention for urinary frequency, nocturia, dysuria and sense of incomplete evacuation of bladder for last 6 months. *297*
- What is your provisional diagnosis?
- What can be other possibilities?
- How will you proceed for confirmation?
  - Nodular hyperplasia of prostate
  - Carcinoma of the prostate

GUQ25. Old man, aged 75 years, complains of back pain and frequency. Rectal examination shows presence of hard nodular areas over prostate. PSA: 8.9 ng/ ml. *302*
- What is your provisional diagnosis?
- What can be other possibilities?
- How will you investigate the case?

GUQ26. A 39-year-old male presents with a rapidly increasing right inguinal mass for 3 months. On enquiry, he admits presence of a small swelling at the same site since birth. O/E: Right scrotal sac is empty. *303*
- What is your provisional diagnosis?
- How will you confirm your diagnosis?
  - Testicular tumors

GUQ27. A 63-year-old male presents with left supraclavicular hard lymph node, noted 2 weeks back. O/E: Hard, nontender left testicular swelling present. *309*
- What is your provisional diagnosis?
- Enumerate different histological variants appropriate for history.
- How will you confirm your diagnosis?

GUQ28. A 4-year-old male child is brought to OPD with right testicular swelling for 1 month. O/E: Medium sized swelling, nodular and nontender without pallor or, lymphadenopathy. *309*
- What are the possible causes?
- How will you investigate the case?

GUQ29. A 37-year-old male comes to outdoor with right testicular swelling noted 2 weeks back after an inguinal injury. O/E: Irregular, nodular swelling of right testis with loss of testicular sensation. *309*
- What are the possible causes?
- How will you investigate the case?
  - Clotted hydrocele

GUQ30. A middle-aged female, 42-year-age, comes to G and O OPD with leukorrhea for 6 months. Pap smear examination shows presence of dysplastic cells. *310*
- What are the possible causes?
- How will you investigate the case?
  - Chronic cervicitis
  - Chronic cervicitis with low-grade and high-grade cervical intraepithelial lesion
  - Invasive carcinoma of cervix

GUQ31. A 45-year-old female comes to gyne OPD with H/o postcoital bleeding. *316*
- What is your provisional diagnosis?
- How will you investigate the case?

GUQ32. A 39-year-old multiparous woman is complaining of menorrhagia and irregular vaginal bleeding for last 6 months. She also complains of dysmenorrhea. P/V: Bulky uterus. *316*
- What is your provisional diagnosis?
- What are other causes?

- How can you confirm your diagnosis?
  - Leiomyoma of uterus
  - Endometrial carcinoma
  - Choriocarcinoma of uterus

GUQ33. A 63-year-old female comes to gyne OPD with postmenopausal vaginal bleeding. *321*
- What are the possible causes?
- How will you confirm your diagnosis?

GUQ34. A 35-year-old female presents with irregular vaginal bleeding for last 3 months. H/o abortion 5 months back; Inv: Chest X-ray shows multiple SOLs in both lungs. *321*
- What is your provisional diagnosis?
- How can you confirm your diagnosis?

GUQ35. A 25-year-old female with amenorrhea for 10 weeks is complaining of excessive vaginal bleeding and passage of grape-like structures. *322*
- What is your provisional diagnosis?
- What can be other possibilities?
- How can you confirm your diagnosis?
  - Hydatidiform mole
  - Invasive mole
  - Placental site trophoblastic tumor

GUQ36. A 37-year-old female presents with a large lower abdominal swelling for 3 months. USG: Large right ovarian SOL 16 cm in diameter partly solid and partly cystic with multiple deposits in omental tissue. *325*
- What is your provisional diagnosis?
- How will you investigate the case?
  - Ovarian carcinoma

GUQ37. A 49-year-old female presents with ascites for 3 months. USG shows presence of right ovarian SOL, 10 cm in diameter. *335*
- What are the possible causes?
- How can you confirm your diagnosis?

GUQ38. A 42-year-old parous woman is complaining of voice changes and hirsutism for 2 months. P/V examination shows right ovarian enlargement. *335*
- What are the possible causes?
- How can you confirm your diagnosis?

GUQ39. A 10-year-old girl comes to outdoor with rapidly developing lower abdominal mass and tenderness. P/V examination shows huge enlargement of left ovary. *335*
- What are the possible causes?
- How can you proceed for diagnosis?

GUQ40. A 8-year-old girl comes to outdoor with features of precocious puberty. USG of abdomen shows a solid ovarian SOL on left ovary – 8 cm in diameter. *335*
- What are the possible causes?
- How can you investigate the case?

GUQ41. A 23-year-old female comes to outdoor with a well-defined mobile lump 2 cm in diameter over upper and outer quadrant of left breast. *335*
- What is your provisional diagnosis?
- How can you confirm your diagnosis?
  - Fibroadenoma of breast
  - Phyllodes tumor
  - Sarcoma of breast

GUQ42. A 37-year-old female comes to outdoor with a vague nodular swelling over right breast for 1 year. The mass is tender and tenderness increases during menstruation. *337*
- What is your provisional diagnosis?
- How can you confirm your diagnosis?
  - Fibroadenosis of breast
  - Proliferative breast diseases (epithelial hyperplasia, sclerosing adenosis and small duct papillomas)

GUQ43. A 58-year-old female comes to outdoor with hard and fixed lump of left breast 5 cm in diameter and ulcerations in the overlying skin. She admits presence of a small lump for 9 months with rapid increase in size during last 3 months. On examination, left axillary lymph nodes are palpable. *340*
- What is your provisional diagnosis?
- How can you classify the disease?
- What are the steps for diagnosis?
  - Carcinoma of the breast

GUQ44. A 34-year-old female comes to outdoor with a lump in the periareolar region of left breast present for 5 months. *348*
- What can be the possible diagnosis?
- How can you confirm your diagnosis?
  - Large duct papilloma of breast

GUQ45. A 41-year-old female comes to the outdoor with H/o blood mixed discharge from nipple. *349*
- What can be the causes?
- How will you confirm your diagnosis?

GUQ46. A 46-year-old male comes to outdoor with painless hematuria and palpable mass on left flank. *349*
- What are the possible causes?
- How will you confirm your diagnosis?

GUQ47. A 3-years-old boy presents with a rapidly growing abdominal mass. *349*
- What is your provisional diagnosis?
- What can be other possibilities?
- How can you confirm your diagnosis?

GUQ48. A 65-year-old male presents with lower abdominal pain, dysuria and frequency for more than 3 months. *349*
- What are the possible causes?
- How will your investigate the case?

GUQ49. A 6-year-old male child gets admitted into pediatric ward with generalized swelling of body for 7 days. Routine examination of urine shows heavy proteinuria. *349*
- What is your provisional diagnosis?
- What can be the causes of these changes?
- How will you proceed for confirmation of diagnosis?

GUQ50. A 58-year-old female presents with edema, hypertension, anemia and weakness for 6 months. Blood examination shows serum urea–72 mg%, serum creatinine – 3.8 mg%. *350*
- What are the possible causes?
- How can you investigate the case?

GUQ51. A 53-year-old postmenopausal female comes to gyne OPD with intermittent bleeding P/ V for 3 months. *350*
- What are the possible causes?
- How will you establish your diagnosis?

GUQ52. A 42-year-old female presents with a painless nodule over upper and outer quadrant of left breast. Enumerate the causes. *350*
- How can you pinpoint your diagnosis?

Chapter 5: Bone, Joints, Soft Tissue and Skin 351–431

BQ1. A 70-year-old female is brought to emergency with fracture neck femur following minor injury. She also suffered from fracture lower end of radius few months back. She admits chronic back pain and musculoskeletal pain for more than years. *351*
- What is the underlying etiology?
- How will you proceed for confirmation?
  - Senile osteoporosis

BQ2. A 16-year-old male comes to outdoor with a discharging sinus just below right knee joint. O/E: The site shows features of inflammation. The boy is also suffering from pyrexia for 3 weeks. *353*
- What are the probable causes?
- How can you confirm your diagnosis?
  - Pyogenic osteomyelitis
  - Tuberculous osteomyelitis

BQ3. A 15-year-old boy comes to outdoor with a hard, tender, nodule, 2 cm in diameter, just above left knee joint, present for 6 months. X-ray: Cortical lytic shadow in lower part of left femur. *357*
- What can be the possibilities?
- How can you confirm your diagnosis?
  - Osteochondroma
  - Osteoid osteoma
  - Chondroblastoma
  - Chondromyxoid fibroma
  - Solitary enchondroma

BQ4: A 19-year-old female complaining of a rapidly growing tender mass over right shoulder, fixed to the bone. *361*
- What is your provisional diagnosis?
- What are other possibilities?
- How can you confirm your diagnosis?
  - Classification of bone tumors
  - Osteosarcoma
  - Chondrosarcoma
  - Giant cell tumor of bone
  - Ewing's sarcoma

BQ5: A 63-year-old female comes to OPD with a slowly developing large tumor near hip joint, present for more than 1 year. *370*
- What are the possible causes?
- How will you proceed for confirmation of diagnosis?
  - Fibrosarcoma
  - Malignant fibrous histiocytoma
  - Benign fibrous histiocytoma

  - Dermatofibrosarcoma protuberans
  - Chordoma
  - Metastatic bone tumor

BQ6: A 7-year-old girl presents with a large, tender, rapidly growing mass, present over midthigh region for 3 months. *378*

- What are the possible tumors?
- How can you confirm your diagnosis?

BQ7: A 29-year-old female comes to OPD with a globular swelling just below knee joint for more than 1 year. *378*

- What can be the possible causes?
- How can you confirm your diagnosis?
  - Synovial sarcoma
  - Pigmented villonodular tenosynovitis
  - Giant cell tumor of tendon sheath

BQ8: A 22-year-old male comes to orthopedic OPD with painful swelling over left shoulder joint. X-ray shows pathological fracture with lytic bone lesion. *381*

- What are the possible causes? How can you differentiate the conditions?
  - Nonossifying fibroma
  - Fibrous cortical defect
  - Fibrous dysplasia
    - Monostotic variant
    - Polyostotic variant
  - Solitary bone cyst
  - Aneurysmal bone cyst

BQ9: A 59-year-old male presented with localized tenderness and swelling of right upper thigh. X-ray showed a lytic bone lesion over upper femur with extension into surrounding soft tissue and pathological fracture. *385*

- What are the possibilities?
- How can you confirm your diagnosis?

BQ10: A 60-year-old male complaining of weakness, lethargy and diffuse skeletal pain for last 1 year. O/E: There is anemia and pedal edema. X-ray of the skull shows multiple punched out lytic lesions. *385*

- What is your provisional diagnosis?
- How can you confirm your diagnosis?
  - Multiple myeloma
  - Solitary plasmacytomas
  - Monoclonal gammopathy of uncertain significance (MGUS)
  - Heavy chain disease
  - Primary amyloidosis
  - Waldenstrom's macroglobulinemia

BQ11: A 48-year-old female presenting with painful swellings and deformities of small joints of hands and feet along with bilateral tender knee joint swellings for last 3 years. *391*

- What is your provisional diagnosis?
- What can be other possibilities?
- How will you confirm your diagnosis?
  - Rheumatoid arthritis
  - Juvenile rheumatoid arthritis
  - Gouty arthritis

BQ12: A 13-year-old girl comes to outdoor with pain and swelling of right knee joint along with high fever for 5 days. *401*
- What is your provisional diagnosis?
- What are other possible causes?
- How will you investigate the case?
  - Suppurative arthritis
  - Tuberculous arthritis

BQ13: A 59-year-old male presents with excruciating pain in the right great toe with swelling and mild rise of body temperature for 2 days. No H/o local injury. *404*
- What is your provisional diagnosis?
- How can you investigate the case?

BQ14: A 53-year-old female presents with swelling and tenderness of both small and large joints for more than 5 years. There is restriction of joint movements with deformities in both hands. *404*
- What is your provisional diagnosis?
- How will you confirm your diagnosis?

BQ15: A 30-year-old male presents with a soft, fluctuant nontender swelling over right inguinal region for 4 weeks. O/E: There is localized tenderness over lumbosacral vertebra with intermittent fever. *404*
- What is the most possible diagnosis?
- How can you confirm your diagnosis?

BQ16: A 37-year-old male presents with a slow growing lump over right wrist joint for 2 years. *405*
- What are the possible causes?
- How can you confirm your diagnosis?
  - Ganglion
  - Lipoma
  - Neurofibroma
  - Plexiform neurofibroma

BQ17: A 66-year-old male seeks medical attention with a huge tumor at mid thigh, present for 6 months. X-ray: Soft tissue swelling. *409*
- What are the possible causes?
- How can you confirm your diagnosis?
  - Liposarcoma
  - Malignant peripheral nerve sheath tumor

BQ18: A 23-year-old male presents with a rapidly growing tumor over nape of the neck for 5 months. *413*
- What can be the probable causes?
- How will you establish final diagnosis?

BQ19: A 37-year-old female seeks medical attention with a large parietal tumor present over ant. abdominal wall for 6 months. *413*
- What are the possible causes?
- How can you differentiate the causes?
  - Desmoid tumor

BQ20: A 66-year-old male presents with progressive abdominal swelling for last 3 months. CT scan of abdomen shows large retroperitoneal tumor. *414*
- What are the possible causes?
- How can you confirm your diagnosis?
  - Leiomyosarcoma

BQ21: A 41-year-old female comes to skin OPD with a raised, flat black colored plaque present over nape of the neck for years. She is complaining of itching and increase in size of the lesion with color changes for last 2 months. *416*
- What is your provisional diagnosis?
- Describe the steps for confirmation of diagnosis.
  - Malignant melanoma
  - Pigmented nevus
  - Dysplastic nevus

BQ22: A 48-year-old male complaining of weakness, weight loss and anorexia for last 3 months along with right inguinal firm swelling; O/E: An ulcerated blackish lesion seen over right great toe present for 1 year along with hepatomegaly. *421*
- What is your provisional diagnosis?
- How can you confirm your diagnosis?

BQ23: A 23-year-old male complains of a soft to firm swelling over back 4 cm in diameter, present for 5 years. *421*
- What are the possible causes?
- How can you confirm your diagnosis?
  - Dermoid cyst
  - Sebaceous cyst

BQ24: A 37-year-old male presents with multiple small soft tissue swellings over different parts of the body for years. *423*
- What are the possible lesions?
- How can you confirm your diagnosis?

BQ25: A 43-year-old male comes to OPD with a slow growing huge tumor covering most of the scalp and present for more than 5 years. *423*
- What is your provisional diagnosis?
- How can you confirm your diagnosis?
  - Turban tumor

BQ26: A 58-year-old male comes to skin OPD with an elevated ulcerated skin swelling present over dorsal aspect of forearm for 6 months with irregular infiltrating margin and prominent blood vessels on superficial surface. *423*
- What can be the possible causes?
- How will you confirm your diagnosis?
  - Squamous cell carcinoma of skin

BQ27: A 63-year-old female presents with a slow growing elevated skin lesion with ulceration present just below lower eyelid for 2 years. *425*
- What is your provisional diagnosis?
- What can be other possibilities?
- How can you confirm your diagnosis?
  - Basal cell carcinoma

BQ28: A 39-year-old female presents with well demarcated plaque-like scaly cutaneous lesions over elbow, knee and scalp for 2 years along with pain and swelling of both knee joints for more than 6 months. *426*
- What is your provisional diagnosis?
- How can you confirm your diagnosis?
  - Psoriasis

BQ29: A 39-year-old female presents with multiple skin bulla, vesicles and ulcerations distributed widely over trunks and extremities along with mouth ulcerations. 427
- What are the possible causes?
- How can you investigate the case?
  - Pemphigus
  - Bullous pemphigoid
  - Dermatitis herpetiformis

BQ30: A 7-year-old girl comes to outdoor with a discharging sinus over right ankle joint for 2 weeks. There is accompanying history of high fever with chill. O/E: Tenderness over lower part of tibia. *431*
- What is your provisional diagnosis?
- What can be other causes?
- How will you confirm your diagnosis?

BQ31: A 21-year-old male comes to surgery outdoor with a rapidly growing huge tumor present close to left knee joint for 5 months. *431*
- What are the possible causes?
- How can you establish final diagnosis?

BQ32: A 35-year-old female comes to OPD with a slowly developing globular firm swelling just below the knee joint for 1 year. *431*
- Enumerate possible causes?
- How can you differentiate the lesions?

BQ33: A 35-year-old female is complaining of pain and swelling of small joints of both hands for more than 1 year. She also admits stiffness of all joints particularly during morning for the same duration. *431*
- What is your provisional diagnosis?
- Describe the criteria for confirmation of diagnosis.
- Briefly describe the etiopathogenesis.

BQ34: A 16-year-old boy presents with a huge swelling near shoulder joint. X-ray shows osteolytic lesion of upper humerus with soft tissue involvement. *431*
- What is your provisional diagnosis?
- How can you classify the lesion?
- Now suddenly, the boy is complaining of breathlessness, chest pain and hemoptysis. What is the possible complication?
- How can you confirm the condition?

BQ35: A 66-year-old male comes to outdoor with high fever and tender swelling of left great toe for 2 days. On X-ray: No fracture is noted. *431*
- What is the most probable diagnosis?
- Mention the specific investigations helping in diagnosis. Now the patient is complaining of pain in the right flank with vomiting and dysuria.
- Identify the possible complication. How can you confirm it?

Chapter 6: Hematology and Lymphoreticular System 432

Differential diagnosis of anemia:
- Classification of anemia
- Diagnosis of microcytic hypochromic anemia
  - Investigations of Fe deficiency anemia and its causes
  - Investigations of thalassemic syndromes
  - Investigations of anemia of chronic disorder
  - Investigations of sideroblastic anemia

- Diagnosis of macrocytic anemia
  - Causes of macrocytic anemia
  - Investigations of normoblastic macrocytic anemia
  - Investigations of megaloblastic anemia
    - Investigations of Vit. B_{12} deficiency
    - Investigations of folate deficiency
- Diagnosis of normochromic normocytic anemia
  - Causes of NN anemia
  - Investigations of aplastic anemia

(Causes of pancytopenia and ferrokinetic study included)

  - Investigations of anemia of pregnancy
  - Investigations of anemia due to protein energy malnutrition
  - Investigations of hemolytic anemia
  - Investigations of anemia of chronic infection
  - Investigations of anemia of chronic renal failure
  - Investigations of anemia of chronic liver disease
  - Investigations of anemia of chronic inflammatory disorder
  - Investigations of anemia of acute leukemia
  - Investigations of anemia of chronic leukemia
  - Investigations of anemia of endocrinopathies
  - Investigations of myelopthisic anemia
- Differential diagnosis of pancytopenia
- D/D of hypersplenism

(Definition, pathogenesis, etiology and diagnosis included)

HQ1. A 39-year-old rural female coming from low socioeconomic background, presents with progressive weakness, fatigue, lassitude and palpitation for last 1 year. O/E: Moderate pallor with stomatitis, glossitis and koilonychia; no hepatosplenomegaly or, lymphadenopathy: *476*
- What is your etiological diagnosis?
- Enumerate possible underlying causes. How can you confirm your etiological diagnosis and pinpoint underlying causes?
  - Iron deficiency anemia

HQ2. A 4-year-old male child, living in an urban slum, is suffering from irritability, growth retardation and anorexia for more than 6 months. O/E: Pallor-+; Liver – Palpable, soft, 1 finger; Spleen – Not palpable; Lymph nodes – 2 discrete small rt. cervical lymph nodes palpable; Hair – Lusterless, dry; Angular stomatitis+ *483*
- What is your provisional diagnosis about the cause of anemia?
- What are the deficient factors that may lead to development of anemia?
- How will you establish the diagnosis of particular deficiency?

HQ3. A 55-year-old male is complaining of weakness, anorexia, weight loss and dyspnea for last 2 months. He also complains of irregular bowel habit for last 6 months. O/E: Pallor: +; Liver: Palpable, 3 cm below costal margin with hard nodular tender surface; Abdominal lump: Palpable over right iliac fossa *483*
- What is your provisional diagnosis?
- What type of anemia is expected in this set up?
- Describe hematological investigations for confirmation of type of anemia?

HQ4. A 31-year-old female gets admitted into medicine ward with progressively worsening symptoms like palpitation, chest pain, dyspnea, weakness and

lassitude for last 1 year. Routine hematological findings are as such: Hb – 6.1 gm%; TRBC – 2.9 million/cumm; TLC – 8,200/cumm.; DC – N_{59}, E_{07}, B_0, L_{33}, M_{01}; TPC – 2,16,000/cumm.
RBC series: Microcytic hypochromic anemia with moderate poikilocytosis and anisocytosis; no normoblast seen; reticulocyte count low; no parasite seen *483*

- What is the possible type of anemia?
- Enumerate the causes of development of this type of anemia?
- What are other causes of microcytic hypochromic anemia?
- How can you investigate a case of microcytic hypochromic anemia?

HQ5: A 43-year-old female patient suffering from weakness, palpitation and easy fatiguability for last 3 months. O/E: Pallor with tongue ulcers seen; no hepatosplenomegaly or lymphadenopathy; Inv: Stool for occult blood test – negative *484*

- What can be etiological diagnosis of anemia in this set up?
- How can you investigate the case for confirmation of diagnosis?
  - Megaloblastic anemia
  - Pernicious anemia
  - Aplastic anemia

HQ6. A 53-year-old male comes to outdoor with progressive weakness, anorexia, dyspnea on exertion and pallor for last 6 months. He also complains of weakness of lower extremities with difficulty during walking. The patient's record shows H/o gastrectomy 20 years back for bleeding gastric ulcer. *494*

- What is your provisional diagnosis?
- How can you investigate the case?

HQ7. A 37-year-old female, suffering from Hashimoto's thyroiditis, is complaining of gradual loss of sensation in both legs with progressive difficulty during walking for last 7 months. O/E: Pallor–Moderate; Icterus–Mild; Hepatosplenomegaly–Mild enlargement *495*

- What is your provisional diagnosis?
- Describe the expected peripheral blood picture in this case?
- What is the role of bone marrow aspiration for diagnosis of this case?
- What other tests must be done for confirmation?

HQ8. A 43-year-old male presents with weakness, lassitude, and anorexia for last 6 months. O/E: Pallor-+; Glossitis -+ Inv: Hb – 8.1 gm %; TRBC -2.8 million /cumm; TWBC-4, 200/cumm; TPC-1, 46,000 /cumm; DC of leukocytes: N_{56}, E_{03}, B_0, L_{39}, M_{02}. Peripheral smear: Macro-ovalocytosis with presence of hypersegmented neutrophils *495*

- What is the possible type of anemia?
- What are the causes of this type of anemia?
- What other causes can give rise to macrocytosis of circulating RBC?
- How can you differentiate those causes from the anemia of this particular patient?

HQ9. A 59-year-old male presents with high fever, severe anemia and petechial bleeding spots over trunk and extremities for 3 days. He has received chloramphenicol for treatment of enteric fever 3 weeks back, O/E: No palpable lymph node or hepatosplenomegaly *495*

- What is your provisional diagnosis?
- Enumerate other causes for development of similar disorder. How will you confirm your provisional diagnosis?

HQ10. A 48-year-old female presents with severe anemia for 2 months. O/E: No hepatosplenomegaly or, lymphadenopathy Inv: Hb – 4.1 gm%, TLC—2,900/cumm.
TPC—1,42,000/cumm; DC—N_{37}, E_{01}, B_{00}, L_{61}, M_{01} ; RBC series—Normocytic and normochromic *496*
- What is your provisional diagnosis?
- Enumerate other conditions with similar blood picture. Briefly describe the investigations helping in differential diagnosis.

HQ11. A 4-year-old male child is suffering from growth retardation, irritability and anorexia till infancy. O/E: Pallor–Marked; huge enlargement of liver and spleen with sternal tenderness, but no marked lymphadenopathy; depressed nasal bridge with malar prominence *497*
- What is your provisional diagnosis?
- How can you confirm your diagnosis?
  - Thalassemia syndromes
  - β- thalassemia major
  - β-thalassemia intermedia
  - β-thalassemia minor
  - α-thalassemias
  - Hydrops fetalis
  - HbH disease
  - α-thalassemia trait
  - Silent carrier of α-thalassemia
  - δβ thalassemia
  - Hereditary persistence of HbF
  - Prevention of thalassemia

HQ12. A 5-year-old girl has received regular blood transfusions since infancy.
Routine blood examination shows:
Hb – 3.8 gm%; TRBC – 3.1 million/ cumm; TPC – 1,96,000/cumm
DC – N_{36}, E_{03}, B_{00}, L_{59},M_{02}
RBC series: Microcytic hypochromic anemia with target cells and polychromasia; Normoblast: 20/100 WBC *506*
- What is your provisional diagnosis?
- How can you confirm your diagnosis?

HQ13: A 57-year-old male presents with passage of dark, smoky urine for 3 days. He has taken primaquin 2 days back. *506*
- What is your provisional diagnosis?
- Enumerate other causes giving rise to similar clinical picture?
- How can you confirm your diagnosis?
  - G6PD deficiency hemolytic anemia
  - Favism
  - Pyruvate kinase (PK)deficiency hemolytic anemia

HQ14: A 59-year-old female is admitted into emergency ward with anuria for 24 hours. She complains of snakebite 3 days before. *509*
- What is your provisional diagnosis?
- How can you explain pathogenesis of anuria?
- Describe the hematological and biochemical abnormalities expected in this set up.

HQ15: A 43-year-old male presents with recurrent episodes of passage of dark, smoky urine for last one and half years. O/E: Mild pallor with mild hepatomegaly *510*
- What is your provisional diagnosis?
- What are other possibilities?
- How can you confirm your diagnosis?
  - Paroxysmal nocturnal hemoglobinuria
  - Paroxysmal cold hemoglobinuria
  - Cold hemagglutinin disease

HQ16: A 27-year-old male of low socioeconomic status comes to medicine outdoor with progressive weakness, indigestion and abdominal discomfort for last 1 year. O/E: Moderate pallor without any lymphadenopathy, hepatosplenomegaly or, abdominal lump Inv: Stool for occult blood test: Positive *514*
- What is the most probable type of anemia?
- What is the expected etiology?
- What can be other possibilities?
- How can you confirm your diagnosis?

HQ17: A 39-year-old male alcoholic presents with moderate anemia; examination of peripheral smear shows macrocytic anemia. *514*
- What is the possible etiological cause of anemia?
- How can you investigate the case?

HQ18: A 2-year-old male child presents with growth retardation and repeated respiratory tract infections. O/E: Significant pallor with splenomegaly blood picture: Normochromic normocytic anemia with presence of irreversible sickled cells *514*
- What is the most likely diagnosis?
- Describe the lab investigations for confirmation of diagnosis. During treatment, the child suddenly develops tender swelling of both hands and feet with pyrexia.
- What is the possible complication? Describe the pathogenesis of development of such complication. Enumerate other possible complications.
  - Sickle cell disease
  - Sickle cell trait
  - Homozygous sickle cell disease
  - Double heterozygous sickle cell β-thalassemia disease
  - Other hemoglobinopathies

HQ19: A 19-year-old female is being investigated for moderate anemia. O/E: Icterus-Mild; no hepatosplenomegaly Inv: Normochromic normocytic anemia; sickling test: Positive *521*
- What is your provisional diagnosis?
- What can be other possibilities?
- How can you confirm your diagnosis?
- Enumerate other causes of normocytic normochromic anemia.

HQ20: A 2-year-old female child presents with growth retardation, severe, anemia, splenomegaly and mild icterus since infancy. *521*
- What are the possible causes?
- How can you confirm your diagnosis?

HQ21: A 13-year-old boy presents with chronic anemia, hepatosplenomegaly and mild icterus.
Result of Hb-electrophoresis: HbF—82%

HbA—15%
HbA_2—03%
The boy has not received any blood transfusion. *522*
- What is your provisional diagnosis?
- How can you confirm your diagnosis?

HQ22: A 26-year-old pregnant female presents with moderate anemia during 2nd trimester of pregnancy, which is refractory to therapy. Result of Hb electrophoresis: HbA—93%; HbF—1.5%; HbA_2—5.5% *522*
- What is your provisional diagnosis?
- Describe the abnormalities in peripheral smear examination and relevant biochemical investigations helping in diagnosis?
- What precaution must be taken during management of this type of anemia?
- What will be your judgment regarding continuation of pregnancy?

HQ23: A 28-year-old male presents with moderate pallor, mild icterus and hepatosplenomegaly.
Hb-electrophoresis: HbA—48%, HbH—31%, HbF—20%, HbA_2—1% *522*
- What is your provisional diagnosis?
- Describe the possible genetic abnormalities in this case?
- What are the causes of development of anemia in this case?
- Briefly outline lab. investigations for confirmation of diagnosis.

HQ24: A 16-year-old boy is admitted into medicine ward with irregular pyrexia for more than 3 months. O/E: Pallor- Moderate; Spleen-Moderately enlarged, firm; Liver- Mild enlargement, firm *524*
- What are the possible causes?
- How can you confirm your diagnosis?
  - Chronic malaria
  - Chronic kala-azar

HQ25: A 4-year-old girl presents with huge splenomegaly and pallor. *526*
- What are the possible causes?
- How can you confirm your diagnosis?
  - Gaucher's disease

HQ26: A 57-year-old male complaining of progressive weakness, weight loss and anorexia for last 3 months. O/E: Moderate pallor with massive enlargement of spleen. *528*
- What are the probablities?
- How can you confirm your diagnosis?
  - Chronic myeloid leukemia (CML)
  - Myelofibrosis with myeloid metaplasia
  - Acute myelofibrosis
  - Hairy cell leukemia

HQ27: A 56-year-old healthy female is complaining of recurrent development of small, localized bruises at different parts of the body for more than a year.
Inv: BT, CT- Normal; TPC: 2,36,000/ cumm *537*
- What are the possible causes?
- How can you confirm your diagnosis?
  - Purpura simplex
  - Senile purpura

HQ28: A 22-year-old male comes to emergency with epistaxis. He has similar attacks before. O/E: Small raised telangiectatic spots are seen over oral mucosa. Family history reveals bleeding manifestations in older brother. *537*
- What is your provisional diagnosis?
- How will you confirm your diagnosis?
  – Osler-Rendu-Weber syndrome

HQ29: A 7-year-old boy is admitted into medicine ward with colicky pain abdomen, vomiting and bloody diarrhea for 2 days. O/E: Bilateral tender knee swellings with large purpuric rashes over buttocks and both elbows.
Investigation: Urine examination shows hematuria and proteinuria. *538*
- What is your provisional diagnosis?
- How can you confirm your diagnosis?
  – Henoch- Schönlein purpura

HQ30: A 4-year-old girl is brought to emergency with severe epistaxis for 1 day. O/E: There are presence of multiple petechial spots over trunks and extremities without any hepatosplenomegaly or, lymphadenopathy. History reveals an attack of common cold 2 weeks before. *540*
- What is your provisional diagnosis?
- How can you confirm your diagnosis?
  – Idiopathic thrombocytopenic purpura

HQ31: A 29-year-old female seeks medical attention with repeated attacks of petechial bleeding spots over trunks and extremities and menorrhagia during last 3 years. *543*
- What is your provisional diagnosis?
- How can you confirm your diagnosis?

HQ32: A 12-year-old boy presents with epistaxis and petechial spots over trunks and extremities for 2 days. *544*
- What are the possible causes?
- How can you confirm your diagnosis?
  – Drug-induced thrombocytopenia
  – Acute leukemia (ALL or AML)

HQ33: A 46-year-old male seeks medical attention with weakness, fever and multiple petechial spots over body for 3 days. O/E: Moderate pallor is present. *553*
- What can be the possible causes?
- How can you confirm your diagnosis?

HQ34: A 27-year-old male gets admitted into emergency ward with excessive bleeding following tooth extraction. Inv.: Normal platelet count; prolonged bleeding time and clotting time *554*
- What is your provisional diagnosis?
- What can be other causes?
- How can you confirm your diagnosis?
  – von Willebrand's disease
  – Thrombasthenia

HQ35: A 7-year-old male child presents with high fever and tender swelling of left knee joint. On careful enquiry, following facts are revealed:
– Bleeding tendency from minor trauma since infancy
– Presence of bleeding tendency in one of the maternal uncles of the child.
Aspiration from the affected joint yields frank blood. *557*

- What is your provisional diagnosis?
- How can you confirm your diagnosis?
  - Hemophilia A or B

HQ36. A 36-year-old female suffering from obstructive jaundice due to choledocholithiasis for more than 2 months, has developed easy bruisability following minor trauma. *560*
- What is your provisional diagnosis?
- Explain the pathogenesis of bleeding manifestations. Mention the investigations necessary for confirmation of diagnosis.
  - Hemorrhagic disorder due to clotting Vit. K dependant of deficiency factors

HQ37: A 28-year-old female, during postoperative period after partial thoracotomy of left lung, suddenly develops bleeding from multiple sites, fluctuating consciousness and rapid fall of urinary output. *560*
- What is the most likely diagnosis?
- How can you confirm your diagnosis?
  - Disseminated intravascular coagulation (DIC)

HQ38: A 26-year-old female presents with easy bruisability and mild menorrhagia for years. *565*
- What are the possible causes?
- How can you confirm your diagnosis?

HQ39: A 32-year-old male presents with easy bruisability and prolonged bleeding from minor injuries since adolescence. *565*
- What are the probable causes?
- How can you confirm your diagnosis?

HQ40: A 56-year-old male presents with weakness, lassitude and chronic anemia for more than 3 years. He has received multiple blood transfusions during this period. RBC morphology: Dimorphic picture with both microcytic hypochromic and normochromic normocytic erythrocytes. *565*
- What is the most possible diagnosis?
- How can you confirm your diagnosis?
  - Sideroblastic anemia

HQ41: A 6-year-old boy presents with high fever, mouth ulcerations, petechial bleeding spots over skin, severe pallor and sternal tenderness. *567*
- What is your provisional diagnosis?
- How can you confirm your diagnosis?

HQ42: A 3-year-old girl is admitted into hospital with high fever, pallor, generalized lymphadenopathy and gum bleeding for 3 days. *567*
- What is your provisional diagnosis?
- How can you confirm your diagnosis?

HQ43: A 48-year-old female, suffering from invasive duct carcinoma of right breast for more than 2 years, gradually develops profound anemia during last 3 months. Examination of peripheral smear shows leukoerythroblastic blood picture. *567*
- What is the possible cause of progressive anemia?
- What is leukoerythroblastic blood picture?
- Enumerate the conditions along with differential diagnosis of diseases presenting with leukoerythroblastic blood picture.
  - Leucoerythroblastic blood picture

HQ44: A 11-year-old girl presents with fever, hepatosplenomegaly and generalized lymphadenopathy for 7 days. *568*
- What are the possible causes?
- How can you confirm your diagnosis?
  - Infectious mononucleosis
  - Lymphoma

HQ45: A 12-year-old boy presents with pallor and cervical lymphadenopathy. Routine chest X-ray shows a large mediastinal mass. *584*
- What are the possibilities?
- How can you confirm your diagnosis?

HQ46: A 10-year-old girl presents with high fever and cervical lymhadenopathy for 7 days. There is no history of ingestion of any drug recently. Blood examination shows: Hb—4.2 gm%, TLC—3, 600/cumm and TPC—87, 000/cumm *584*
- What is the most likely diagnosis in this set up?
- How can you confirm your diagnosis?

HQ47: A 9-month-old baby is suffering from high fever with respiratory distress for 3 days. Blood examinations show: Hb—8.8 gm%; Normochromic normocytic anemia; TLC—48, 500/cumm; DC—Myelocyte: 04%; Metamyelocyte: 07%; Band form: 15%; Neutrophil: 56%; Eosinophil: 01%; Basophil: 00%; Lymphocyte: 17%; Monocyte: 00%; TPC – 4,28,000 /cumm; ESR – 118 mn (1st hour). *584*
- What is your provisional diagnosis?
- How can you explain the blood picture?
- What other tests you should perform for confirmation?

HQ48: A 23-year-old male presents with high fever, severe pallor, hepatosplenomegaly and petechial bleeding spots over trunk for 3 days. *585*
- What is your provisional diagnosis?
- How can you confirm your diagnosis?

HQ49: A 42-year-old male presents with bleeding gum for 5 days. O/E: Pallor, splenomegaly and gingival hyperplasia; examination of peripheral smear shows presence of blast cells. *585*
- What is your provisional diagnosis?
- Can you guess about specific subvariant of the disease?
- How can you confirm your diagnosis?

HQ50: A 46-year-old male presents with chest pain, cold, cough, respiratory distress and high fever for 3 days.
Inv: Hb – 10.1 gm%, normocytic, normochromic erythrocytes
TWBC – 35,000 /cumm; DC: Mye – 02%, Metamye – 03%, Band form – 15%, N_{71}, E_{02}, B_{00}, L_{06}, M_{01}; TPC – 3,46,000 /cumm *585*
- What is your provisional diagnosis?
- What can be other causes producing similar blood picture?
- How can you differentiate these conditions on hematological examinations?
  - D/D of myeloid leukemoid reaction and CML

HQ51: A 51-year-old female came to outdoor with weakness, pallor and splenomegaly for 2 years. Routine hematological investigation showed: Hb—9.9 gm%, TLC—1, 86,000/cumm, TPC—1, 72,000/cumm. What is your provisional diagnosis? After 3 months, the lady again came back with rapid enlargement of spleen, extreme lassitude, progressive pallor and cervical lymphadenopathy. *586*
- What is your provisional diagnosis?
- What is the possible complication?

- Mention the clinical and hematological parameters for diagnosis of this complication.
- What is the prognosis of this complication?
  - Accelerated phase of CML

HQ52: A 66-year-old male presents with cervical and axillary lymphadenopathy for 6 months.
Inv: TLC—2, 67,000/cumm of which 90% are lymphocytes. *587*
- What is your provisional diagnosis?
- How can you confirm your diagnosis?

HQ53: A 47-year-old female comes to outdoor with purpuric skin rashes for 3 days with extreme prostration for last 1 month. O/E: Severe pallor with moderate splenomegaly. There is no past H/o bleeding. *588*
- What are the possible causes? How can you confirm your diagnosis?

HQ54: A 43-year-old male presents with weakness, lassitude, moderate pallor, sternal tenderness and splenomegaly for 6 months. *590*
- What are the possible causes?
- How can you confirm your diagnosis?

HQ55: A 11-year-old boy comes to outdoor with weakness, pallor, fever and cervical lymphadenopathy for 1week. Chest X-ray: Enlarged mediastinal mass *590*
- What is your provisional diagnosis?
- How can you confirm your diagnosis?

HQ56: A 76-year-old male complaining of weakness and generalized lymphadenopathy for more than 6 months, without any other ailments. *591*
- What are the possible causes?
- How can you confirm your diagnosis?

HQ57: A 7-year-old girl is admitted into hospital with high fever, hepatosplenomegaly, generalized lymphadenopathy and pallor for 5 days. Peripheral smear examination shows presence of abnormal lymphocytes. *591*
- What are the possible causes?
- How can you confirm your diagnosis?

HQ58: A 29-year-old male comes to outdoor with weakness, weight loss and chronic diarrhea for more than 3 months. O/E: Patient is chachectic with high fever and cervical lymphadenopathy. Careful examination and history taking reveals: H/o intravenous drug abuse for more than 2 years. *591*
- What is your provisional diagnosis?
- What can be other possibilities?
- How can you confirm your diagnosis?
  - AIDS

HQ59: A 35-year-old male presents with generalized lymphadenopathy, low-grade fever, weight loss and cough with hemoptysis for last 4 months. Careful history reveals bisexual habits for 20 years. *607*
- What are the possible causes? How can you confirm your diagnosis?

HQ60: A 3-year-old boy presents with severe anemia, hepatosplenomegaly and growth retardation since infancy. *607*
- What is the most likely diagnosis? What can be other possibilities? Briefly describe the laboratory investigations for confirmation of your diagnosis?

HQ61: A 5-year-old boy presents with multiple petechial spots over skin and mucosa 7 days after an attack of febrile illness. *607*
- Mention your provisional diagnosis?

- What can be other common causes with similar presentation?
- Describe the peripheral smear and bone marrow findings expected in this set up along with the role of these investigations in differential diagnosis.

HQ62: A 67-year-old male patient seeks medical attention with severe pallor, hepatomegaly and right lower abdominal hard mass. He is also complaining of weakness, anorexia and altered bowel habit for last 3 months *607*
- What is your diagnosis?
- What is the likely cause of anemia in this case?
- Describe the expected peripheral smear findings in this set up. Mention the biochemical tests essential for etiological diagnosis of anemia.

HQ63: A 28-year-old multiparous woman is complaining of weakness, anorexia, and easy fatiguability for last 1 year. O/E: Moderate degree of pallor with concavity of finger nails *607*
- What is your diagnosis about etiology of anemia?
- How can you confirm your diagnosis?
- What other deficiencies may take part in pathogenesis of anemia in this case?
- How can you prove this deficiency by laboratory investigations?

HQ64: A 33-year-old female presents with repeated attacks of spontaneous bleeding in the skin and mucosa for last 4 years. O/E: No hepatosplenomegaly or, sternal tenderness *607*
- What is your provisional diagnosis?
- How can you confirm your diagnosis?

HQ65: A 6-year-old girl is admitted into emergency ward with severe pallor, lymphadenopathy, and petechial bleeding spots over skin with high fever. *607*
- What is the likely diagnosis?
- What can be other possibilities?
- Briefly describe the steps for confirmation of your diagnosis?

HQ66: A 58-year-old male is complaining of weakness, lassitude, anorexia, and weight loss for last 3 months. O/E: Moderate pallor with huge splenomegaly *608*
- What are the common causes?
- How will you proceed for diagnosis?

HQ67: A 52 years male, with a long history of alcohol addiction, is complaining of weakness, anorexia and easy fatigability for 6 months. O/E: Severe pallor with angular stomatitis; Hepatosplenomegaly – Mild; Sternal tenderness – Absent *608*
- Mention the likely cause of anemia?
- How can you confirm the etiology?

HQ68: A 38-year-old female gets admitted into medicine ward with severe pallor, confusion and gait abnormalities. She has undergone gastrectomy 15 years back for uncontrollable peptic ulcer bleeding. *608*
- What is your provisional diagnosis?
- How can you confirm your diagnosis?
- What precautions you must take during treatment of this patient?

HQ69: A 35-year-old male seeks medical attention with high fever, pallor, spontaneous bleeding in skin and mucosa and sternal tenderness for last 7 days. *608*
- What is your provisional diagnosis?
- What can be other possible causes?
- How can you investigate the case?

HQ70: A 45-year-old male, treated with chloramphenicol for enteric fever 3 weeks back, comes to outdoor with severe pallor, sternal tenderness, nasal bleeding and high fever. *608*
- What is your provisional diagnosis?
- Describe the expected peripheral blood picture in this case.
- What other causes can give rise to similar peripheral smear findings?
- How can you differentiate those cases on bone marrow examination?

HQ71: A 6-year-old girl presents with pallor, mild jaundice, moderate splenomegaly and repeated attacks of painful swellings of both hands since infancy. *608*
- What is your provisional diagnosis?
- How will you proceed for confirmation of diagnosis?

HQ72: A 19-year-old male presenting with fever and generalized lymphadenopathy for 7 days: *608*
- What can be the possible causes?
- How can you confirm your diagnosis?

HQ73: A 16-year-old boy is admitted into Medicine ward with low-grade irregular fever, pallor and hepatosplenomegaly for more than 6 months. 608
- What are the possible causes?
- How can you confirm your diagnosis?

HQ74: A 53-year-old female presents with pallor, fatigue, weight loss and massive splenomegaly for 6 months. *608*
- What are the possible causes?
- How can you confirm your diagnosis?

HQ75: A 32-year-old female seeks medical attention with continuous fever, diarrhea and weight loss for 4 weeks. O/E: Generalized lymphadenopathy of cervical, axillary and inguinal regions; careful interrogation uncovers that the patient is working as prostitute for more than 15 years. *609*
- What is your provisional diagnosis?
- How can you confirm your diagnosis?
- How can you monitor the progress of the disease?

HQ76. A 5-year-old boy was brought to emergency with weakness, irregular fever and body ache for last 1 month. O/E: Generalized lymphadenopathy, sever pallor and tenderness over bones. *609*
- What is the most likely cause of illness?
- How will you approach for proper diagnosis?
- Discuss the factors associated with outcome of the disorder.

HQ77. A 50-year-old male was complaining of chronic weakness and early fatigability for last 1 year. Examination of PBS revealed following features:
Hb–8.0 gm%; TLC–4, 100/cumm; TPC–1, 03, 000/cumm.
Careful examination of WBC series showed 2% cells with open, loose chromatin, nuclear membrane irregularities and prominent nucleoli. *609*
- Mention your provisional diagnosis. State in brief steps for confirmation of diagnosis. Comment about outcome of this disorder.

HQ78. A 56-year-old male seeks medical attention with fever, weakness, petechial bleeding spots over extrimites and recurrent episodes of epistaxis during last two months. O/E: Splenomegaly with sternal tenderness.
Report of hematological investigation: Hb–4.1 gm%, TLC–1, 12, 000/cumm. *609*
- Enumerate the possible causes?
- How will you investigate the case for confirmation of diagnosis?

HQ79. A 5-year-old boy is suffering from severe anemia since infancy and needs regular blood transfusions. Lab investigations show raised serum bilirubin and reticulocyte count. His sister is also suffering from anemia since infancy but does not need blood transfusion. *609*
- What is your provisional diagnosis?
- How can you explain difference in presentation of both children?
- How will you approach for diagnosis?

HQ80. A 3-year-old girl presented with anemia and jaundice since infancy. Family history revealed affected brother but normal sister. *609*
- What is the probable diagnosis?
- How can you confirm the etiology?
- Comment about transmission of the disease.

Chapter-7: Central Nervous System **610**

CNSQ1: A 2-year-old boy was brought to hospital in a comatose stage. He was suffering from high fever with stiffness of neck for 2 days. Immediate lumbar puncture yielded hazy fluid with high opening pressure. *610*
- What is the most likely diagnosis in this set up?
- What are other possible causes?
- How will you proceed for confirmation?
  - Acute pyogenic (baeterial) meningitis
  - Acute viral meningitis / meningoencephalitis
  - Acute fungal meningitis

CNSQ2: Result of CSF study in a 6-day-old drowsy baby is as follows: CSF pressure is increased with slightly hazy fluid, CSF protein—157 mg%, Sugar—9 mg%, Cl^-—122 mEq/lit; Cell count—1200/cumm; mostly neutrophils. *626*
- What is your provisional diagnosis?
- What tests you want to do for further confirmation?

CNSQ3: A 17-year-old girl came to outdoor with fever, intense headache, photophobia and neck rigidity. Examination of CSF showed: *626*
- Protein—79 mg%, Sugar—58 mg%
- Cell count—185/cumm, mostly lymphocytes

Younger brother of the girl suffered an attack of fever with rash 7 days back.
- What is the most likely diagnosis?
- State the points helping you to reach the diagnosis?
- What additional investigations you want to perform for diagnosis?

CNSQ4: A 36-year-old female, receiving immunosuppressive therapy, suddenly developed high fever, headache, drowsiness, neck rigidity and convulsion. Report of CSF examination as follows:
Pressure—Highly increased
Sugar—22mg%
Protein—116mg%
TLC—540/cumm
DC—Lymphocyte: 70%, Neutrophil: 30% *627*
- What is your provisional diagnosis?
- What other conditions can give rise to similar clinical features?
- How can you differentiate those conditions by CSF study?

CNSQ5: A 4-year-old-male child was suffering from low-grade fever, anorexia, irritability, loss of playfulness for 3 weeks. For 2 days the child became drowsy, apathetic,

did not take any food with one episode of convulsion. Lumbar puncture yielded clear fuild in high pressure with formation of fine cob-web coagulum on standing. *627*
- What is your provisional diagnosis?
- How can you confirm your diagnosis?
  - Tuberculous meningitis

CNSQ6: A 26-year-old male was brought to emergency in a comatose state. No other history was available. LP yielded slightly hazy fluid with high opening pressure. *629*
- What are the possible causes?
- Discuss the changes in CSF that will help to differentiate the conditions.

CNSQ7: 15-year-old girl was admitted into hospital with features of circulatory collapse. She was suffering from high fever, headache and vomiting for last 24 hours. O/E: Patient was comatose with purpuric rashes over chest and back. *629*
- What is your provisional diagnosis?
- What investigation should be done for immediate confirmation?
- State the expected result of that investigation in this case?

CNSQ8: 10 days neonate was brought to emergency with bizarre movement of body. The baby was suffering from irritability, continuous cry, refusal to food and low-grade fever for last 48 hours. O/E: Anterior fontanellae was bulging. *630*
- What is your provisional diagnosis?
- How can you confirm?

CNSQ9: A 13-year-old boy is complaining of high fever, headache, photophobia and recurrent vomiting for 24 hours. Ophthalmoscopy reveals bilateral papilledema. There is a fine maculopapular rash over face, neck and upper chest. *630*
- What is the most likely diagnosis?
- Detail the steps for confirmation.

CNSQ10: Tapping of subarachnoid space yielded deep red fluid in case of an adult male aged 47-year-old. *630*
- What futher tests you want to perform over CSF and for what purpose?

CNSQ11: A 17-year-old adolescent boy presents with high fever and neck rigidity. Report of CSF study is as follows:

Opening pressure:	208 mm of water
Physical examination:	Hazy fluid with presence of large irregular grayish clot
Chemical examination:	Protein—195 mgm%
	Glucose—13 mgm%
	Chloride—118 mEq/lit
Cytological examination:	Cell 1850/count—cumm
	DC-Neutrophil—95%
	Mononuclear—05%

Microbiological study:
Gram's stain: Presence of gram-positive cocci
Culture: Growth of organism *631*
- What is your provisional diagnosis?
- What are the organisms expected to be isolated in this case?
- What other investigations you want to perform with CSF?
- What are the changes you expect in routine blood examination in this case?
- What other blood test you want to perform and why?

CNSQ12: Report of CSF in a 4-year-old boy is as follows:
Pressure: 102 mm of water
Physical character: Colorless, slightly hazy fluid which on standing for half an hour produces fine cob-web coagulum.
Chemical examination: Protein—98 mgm%
Glucose—29 mgm%
Chloride—67 mEq/lit
Cytological study: Cell count—160/cumm
Cell type—Lymphocyte—80%
Neutrophil—20%
Microbacterial study:Gram's stain: No organism detected
Z-N stain: Acid fast bacilli present *631*

- What is your diagnosis? What is the sensitivity of Z-N stain in diagnosing this condition? What other tests you want to do on CSF for confirmation? What other types of changes you may expect in cytological study of these cases?

CNSQ13: A 12-year-old girl was brought to emergency with recurrent episodes of convulsion. Study of CSF showed:
Opening pressure: 84 mm of water
Physical character: Clear, colourless fluid without any clot formation
Chemical examination: Protein: 71 mg%
Glucose: 58 mg%
Chloride: 122
mEq/lit
Cytological examination: Total count: 85/cumm
Differential count: Lymphhocyte: 100%
Microbiological study: Gram's stain—Negative
Z-N stain—Negative
Routine culture—Negative
Culture for AFB—Negative *632*

- What is your diagnosis? What additional tests are to be done on CSF for confirmation?

CNSQ14: A 29-year-old female is complaining of severe headache for last 2 months. She has an attack of generalized convulsion 2 days back. CT scan of the brain reveals a single hypodense space occupying lesion (SOL) in the left temporal lobe. *632*

- What are the possible causes?
- How can you investigate the case?
  - Brain tumor—primary or, metastatic
  - Tuberculoma of brain
  - Neurocysticercosis

CNSQ15: Read the following CSF reports carefully and in each case answer the following questions: *635*

a. What is the most likely diagnosis?
b. What are the points favoring the diagnosis?
c. What additional tests should be done for confirmation of etiology?
d. What are the expected clinical features and complications in these cases?
   i. Fluid: Faint hazy; opening pressure—166 mm of water
   Chemical examination: Protein—67 mg%
   Sugar—43 mg%
   Chloride—136 mEq/lit

Cytological examination: Total count—35/cumm
Cell type—Lymphocytes only
Microbiological examination: Gram's stain and Z-N stain do not show any organism

ii. Opening pressure: 186 mm of water
Physical examination: Slightly hazy fluid that forms fine cob-web coagulum on standing
Chemical examination: Protein—93 mg%
Sugar—23 mg%
Chloride—88 mEq/lit
Cytological examination: Cell count—85/cumm
Cell type-Lymphocytes—80%
Neutrophil—20%

iii. Pressure: Highly increased; fluid comes out in jet
Physical examination: Hazy fluid with presence of large grayish clot
Chemical examination: Protein—158 mg%
Sugar—11 mg%
Chloride—129 mEq/lit
Microbiological examination: Gram's stain shows presence of gram (+)ve cocci

CNSQ16: A 3-year-old boy was brought to emergency with convulsion. The child was suffering from high fever for 2 days with headache. On examination there was neck rigidity. Lumbar puncture yielded turbid fluid in high pressure. *636*
- What is your provisional diagnosis?
- What other conditions can give rise to similar appearance?
- How can you establish the diagnosis?

CNSQ17: A 17-year-old young girl was admitted with short history of high fever, headache, vomiting and maculopapular rashes over trunk and extremities. On examination, the patient was in a confused state with neck stiffness. *636*
- What is the most likely diagnosis?
- Discuss the differential diagnosis and necessary investigations.

CNSQ18: A 7-year-old boy presents with anorexia, irritability, weakness and low-grade fever for 2 weeks. For last 2 days the boy is in a confused mental state with one episode of convulsion. Lumbar puncture yielded faint hazy fluid that on standing produces cob-web coagulum. *636*
- What is the most likely diagnosis?
- How can you proceed for confirmation?

Chapter-8: Problem Cards **637**

PC1: An 18-year-old boy presents with a tender, red swelling over right great toe at the site of a scratch injury occurring 24 hours before. *637*
- What is the basic pathological reaction responsible for this swelling?
- What are the classical signs of this condition?
- Explain the causes of tenderness and redness.
- What is the most important cell responsible for this reaction?
- What are the vascular changes associated with this type of lesions?

PC2: A 36-year-old female is complaining of a nonhealing ulcer over right foot present for 3 weeks. . *638*
- What type of pathological reaction is expected at the site of ulcer?
- Mention the most important cell associated with this reaction.
- How can you classify this type of tissue reaction?

PC3: A 6-year-old boy presents with an open wound with red granular surface 48 hours after an injury. *638*
- What is this granular tissue?
- Why it appears red and granular?
- Describe the histological picture.
- How it helps to relieve injury?

PC4: Microscopic examination of a tumor reveals an ill-defined pink homogeneous acellular area infiltrated with inflammatory cells as seen in microphotograph. *638*
- What is the lesion?
- Define the condition. Mention the different variants. If the tumor tissue is taken from brain, what particular type of lesion you will expect?

PC5: Look at the two cutaneous wounds as given in pictures (see next page). First one is clean and sharp with stitched margins and second one is lacerated with tissue loss. *638*
- What type of healing is expected in each lesion?
- How the healing process differs in two wounds?
- Name some factors accelerating healing process in both. Among the two wounds, in which lesion regeneration, at least partly, is possible?

PC6: A 60-year-old male diabetic presents with a foul smelling spreading blue black lesion of right great toe and other toes. *639*
- Identify the lesion. Define the condition.
- How can you classify it?
- What is the role of diabetes in pathogenesis?

PC7: A 29-year-old pregnant lady presents with bilateral lower limb swelling which pits on pressure. *639*
- What is the condition?
- Give definition.
- Name few etiological conditions.
- Why this change occurs in this particular condition?

PC8: During autopsy examination of a 67-year-old male, a soft, friable reddish mass was seen to be attached to the wall of left atrium of heart. *640*
- LAA: Left atrial appendage
- MV: Mitral valve
- : Friable raddish mass.

- What is this reddish mass?
- Define its process of origin.
- Name one important predisposing condition.
- What are the outcomes of this lesion?

PC9: A 13-year-old girl suffering from uncontrolled acute lower respiratory tract infection, suddenly develops cool calmy extremities, rapid thready pulse, falling blood pressure and sweating with confusion. *640*
- What is the developing complication?
- Define it. Classify the condition.

- What particular variant is expected in this set up?
- Name two important mediators.

PC10: Young female complains of continuous sneezing, rhinorrhea, red eyes and respiratory distress developed immediately after dusting of carpets. *640*
- What is the cause of this ailment?
- Give few other examples.
- What is the most important cell helping in pathogenesis?
- Name some important mediators.

PC11: An 8-year-old girl presents with a raised swelling over forearm 48 hours after subcutaneous tuberculin injection at the same site. *641*
- What type of tissue reaction occurs at the site?
- What type cells are responsible for this reaction?
- Enumerate the responsible mediators.
- Mention the histopatho-logical (HP) features.

PC12: Gross examination of a group of excised lymph nodes reveals hard consistency with chalky white cut surface. *641*
- What is the pathological process responsible for this change?
- Classify the process with definition and example of each variety.
- Which particular variant is expected to be responsible in this set up?

PC13: A 16-year-old boy presents with mental retardation, delayed developmental mile stones, pot belly, thick protruded tongue, slanting eyes and coarse skin with gentle behavior. *641*
- Identify the congenital disorder.
- What is the expected genetic abnormality?
- Name few other similar diseases?
- What is the most important predisposing condition?
- What is the commonest cause of death of these children?

PC14: A 63-year-old male presents with marked thinning of right leg following two months immobilization of the same limb on account of fracture midshaft of right femur. *642*
- Mention the pathological process responsible for such change.
- Define the process. What other causes can bring similar changes?
- Does this process can affect internal organs?
- Give example.

PC15: A 35-year-old male presents with slowly developing raised firm itchy superficial swellings developed on anterior chest wall over old burn scars. *642*
- Name the lesion.
- What is the responsible pathological process?
- Name another similar pathological lesion mentioning important points of differentiation.

PC16: Elderly male smoker presents with chest pain, anorexia, weight loss, dry cough and hoarseness of voice for last 10 weeks. There is a hard fixed palpably enlarged lymph node in the right supraclavicular region. CT scan of the thorax shows a large ill-defined heterogenous mass in the right upper lobe of lung. *642*
- Mention your provisional diagnosis.
- How can you classify the lesion?
- How smoking aids in pathogenesis? Why hoarseness occurs?
- Enumerate important means for confirmation of diagnosis

PC17: A 37-year-old male smoker came to medical attention with chronic cough, chest pain, weight loss, evening rise of body temperature and occasional bouts of hemoptysis during last 6 months. Chest X-ray revealed a large cavitary lesion in the apex of right lung. *643*
- What is the most likely diagnosis?
- Enumerate further investigations.
- Describe the histological picture.
- Mention the complications.

PC18: A 73-year-old male suddenly developed high fever with chest pain, purulent cough and respiratory distress. Chest X-ray showed consolidation of right upper lobe of lung. *643*
- What is the most likely diagnosis?
- What is the common age group of this ailment?
- What are the stages of disease progression?
- Mention the characteristic hematological changes.
- Write the complications.

PC19: A 42-year-old male smoker presents with acute severe chest pain extending to left upper arm, rapid feeble pulse and extreme sweating. Immediate ECG tracings show prominent ST elevation with T-wave inversion. *644*
- What is your provisional diagnosis?
- Name the predisposing factors.
- Enumerate few biochemical markers helping in diagnosis.
- Write the complications.

PC20: A 6-year-old boy from a poor socio-economic background comes to outdoor with bilateral knee and elbow joint swellings developed during last one week one after another with fever and tachycardia. He had an attack of sore throat 3 weeks prior to present illness. *644*
- What is your provisional diagnosis?
- How can you confirm your diagnosis?
- What is the significance of prior attack of sore throat?
- What is the long-term complication?

PC21: Young male smoker is complaining of upper abdominal pain with heart burn and dyspepsia which is partially relieved by intake of food. Endoscopy of stomach show a single, small circumscribed lesser curvature ulcer. *644*
- What is your diagnosis?
- Describe the HP features.
- Name one important predisposing factor other than smoking.
- What can be the complications?

PC22: A 63-year-old male presents with anorexia, weight loss, dyspepsia, episodes of hematemesis for last 3 months.

Endoscopy of stomach demonstrates a large, polypoid, irregular growth situated close to greater curvature. *645*
- Identify the possible lesion.
- What are different gross and microscopic variants of the disease?
- Name two etiological factors.
- What are the complications?

PC23: A 76-year-old male presented with a vague lump in the right lower abdomen, anorexia, weight loss and progressive weakness for last 4 months. Stool for

occult blood test was strongly positive USG whole abdomen demonstrated a right iliac mass possibly of cecal origin. *645*
- What is the most likely diagnosis?
- What is the expected histological variant?
- Name one important predisposing factor.
- What type of anemia can occur in this set up and why?
- What is the significance of location of the mass with prognosis?

PC24: A 16-year-old girl presents with anorexia, malaise, weakness and yellowish discoloration of urine for last 4 days. Liver function test shows hyperbilirobinemia (mixed conjugated and unconjugated) with elevated hepatic transaminases *646*
- What is your provisional diagnosis?
- Name the etiological factors with mode of transmission.
- What are the outcomes of this illness?

PC25: A 51-year-old alcoholic male gradually develops huge abdominal swelling with prominent superficial veins over abdomen. He is also complaining of anorexia, weight loss and thinning of extremities for a long duration. *646*
- What is your probable diagnosis?
- Mention important etiological factors.
- Describe the classic histological changes in liver.
- Why abdominal veins are dilated? Enumerate the complications.

PC26: A 71-year-old female presented with tender hepatomegaly with anorexia and weight loss for 2 months. USG demonstrates a circumscribed but heterogenous liver mass. Serum α-fetoprotein level was highly increased. *646*
- What is your provisional diagnosis?
- Why α-fetoprotein level was estimated?
- What type of abnormality in LFT is expected in this set up?
- Mention the methods for confirmation of diagnosis

PC27: Report of examination of liver function tests and viral markers of hepatitis of a 32-year-old female is as given below:
Bilirubin—0.75 mg%, SGPT—Mild elevation, Alkaline phosphatase—Normal, HbsAg— +ve, HbeAg— +ve, Anti Hbc— + ve, Other markers— –ve. *646*
- What is your clinical diagnosis?
- Mention the significance of HbeAg positive result.
- What will be the specific change in hepatocytes expected in this set up?
- Comment about outcome of this stage.

PC28: A 4-year-old baby suddenly develops generalized swelling of the body for 1 week. Routine urine examination reveals heavy proteinuria, lipiduria, hyaline and fatty casts without any RBC or significant rise of pus cell count. *647*
- What is the most likely diagnosis?
- Define the criteria of your diagnosis.
- What is the commonest cause in this age group?
- Mention the characteristic changes confirming the diagnosis.
- What other causes can give rise to similar changes?

PC29: A 60-year-old male presents with loin pain, fullness and occasional attacks of painless hematuria for last 3 months. USG of abdomen demonstrates a circumscribed swelling at the upper pole of right kidney. Biopsy of the kidney swelling is done with features shown below. *647*
- What is your diagnosis?
- Why it is so named? How it spreads?

PC30: A 62-year-old male presents with gradually increasing dysuria for last six months. Digital rectal examination unmasks nodular, firm enlargement of the prostate gland. Biopsy is taken from the gland. *648*

- Mention your diagnosis.
- Discuss the HP features.
- Enumerate the complications.
- Is there any biochemical markers?

PC31: A 48-year-old female was suffering from dysmenorrhea and menometrorrhagia for last 1 year. Internal examination revealed bulky uterus. Gross examination of the cut opened uterus after hysterectomy showed multiple small to large, circumscribed myometrial swelling. *648*

- What is your provisional diagnosis?
- Describe the histology.
- Name the extrauterine sites of this lesion.
- How can you classify the lesion?

PC32: A 56-year-old postmenopausal female presents with irregular vaginal bleeding for last 6 months. Cervical cytology (Pap smear) shows presence of dysplastic squamous cells in a background of hemorrhage and necrosis. Later on, hysterectomy specimen reveals a polypoid, fragile mass at cervix. *649*

- What is the specific diagnosis?
- What particular histological variant you expect?
- Name different gross appearance of the tumor.
- Is there any specific infective etiology?

PC33: An aged female presents with weight loss, anorexia, thinning of extremities with progressive abdominal swelling for last 2 months. USG of abdomen demonstrates a huge partly solid and partly cystic right ovarian mass. Excised ovarian mass shows following gross and microscopic features. *649*

- What is your provisional diagnosis?
- Name two cystic and two solid ovarian neoplasms.
- What peculiarity you can see in the cytoplasm of this lesion, as seen in the microphotograph.
- What is the cause of this change?

PC34: A 20-year-old female complains of a swelling right breast. O/E: Small well, circumscribed, highly mobile swelling is found on the upper and outer quadrant of right breast.

Microscopic appearance of the excised nodule is shown below. *650*

- What is your diagnosis?
- Describe the histological picture.
- Name different variants of the lesion.
- What is the nature of the lesion.
- What is giant fibroadenoma and how it behaves?

PC35: A 49-year-old female presents with a poorly circumscibed left breast swelling, fixed to deeper structures with surface ulcerations and destruction of nipple. *650*

- What is your provisional diagnosis?
- Describe the typical HP features?
- Name few histological variants.
- How the disease spreads ?

PC36: An 8-year-old boy presents with fever, tenderness around left elbow joint and a discharging sinus just below the joint for more than 1 month as shown in the photograph. X-ray of the affected joint shows a partly lytic, partly sclerotic lesion at the upper end of ulna. Excised tissue from the lesion shows under microscope mixture of dead and woven bones, infiltrated with both acute and chronic inflammatory cells. *651*
- What is your provisional diagnosis?
- What is the name of dead bones found in this lesion?
- What are the expected hematological changes?
- Enumerate important complications

PC37: A 19-year-old female presents with a rapidly growing tender bony swelling above the left knee joint for last 6 weeks. X-ray of the joint shows a large lytic lesion in the lower end of femur with periosteal reaction. Rediological as well as HP features of the excised lesion are depicted in the pictures below. *651*
- What is your provisional diagnosis?
- Describe the classical HP features.
- How can you classify the lesion.
- Mention the common age of occurrence.
- How it spreads?

PC38: A 40-year-old male complains of a slow growing globular swelling close to right wrist joint. X-ray of wrist joint demonstrates a mixed lytic and sclerotic, eccentric, circumscribed lesion confined to lower end of radius. FNAC of the lesion reveals following features. *652*
- What is your diagnosis?
- Describe the histology.
- Name few other giant cell containing lesions of bone.
- What is the biological behavior of the lesion?

PC39: A 73-year-old male presents with a slow growing nodular ulcerated lesion of face below right eyelid for 1 year (see photograph).
Excision of the lesion shows features as shown in the picture. *652*
- What is your provisional diagnosis?
- What is the behavior of the lesion?
- What are the common locations?
- What is the age group affected?

PC40: A 47-year-old male presents wtih a blackish elevated lesion in the left foot for years which undergoes rapid increase in size with ulceration during last 2 months. O/E: There is a hard fixed lymph node at left inguinal region. FNAC from the inguinal node shows small dyscohesive clusters of pleomorphic atypical cells with intra and extracellular brown pigment. *653*
- What is the most likely diagnosis in this set up?
- What is the cell of origin?
- Name the brown pigment.
- How the tumor behaves?

PC41: A 29-year-old multiparous lady presents with progressive weakness, lassitude and anorexia for last 6 months. She usually walks barefoot. Occult blood test in stool is postive.

Examination of PBS shows microcytic, hypochromic erythrocytes with anisocytosis and poikilocytosis (large arrows). *653*
- What is your provisional diagnosis?

- Enumerate causes of microcytic hypochromic anemia.
- Pinpoint exact etiology of the disorder.
- Name the characteristic poikilocyte seen in this condition (small arrows).
- What is the significance of reticulocyte count in this set up?

PC42: A 48-year-old chronic alcoholic male complains of progressive weakness, pallor and dyspnea on exertion for last one year with bilateral progressive weakness of lower extremities. Examination of PBS shows presence of macroovalocytes wtih hypersegmented neutrophils. *654*

- What is your provisional diagnosis?
- Describe the expected features in PBS.
- Explain the cause of lower limb weakness.
- How can you confirm your diagnosis?
- How will you plan for treatment of such cases?

PC43: A 20-year-old pregnant lady presents with microcytic hypochromic anemia not responding to iron therapy. Estimation of serum iron and ferritin shows level towards upper limit of normal range. *654*

- What will be the most likely diagnosis?
- What abnormalities you expect in PBS?
- How will you confirm your diagnosis?
- Does the pregnancy need termination?

PC44: A 3-year-old girl needs repeated transfusions of blood since infancy. O/E: Small, malnourished child with severe anemia, mild jaundice, hepatosplenomegaly, prominent cheek bones and sternal tenderness. Examination of PBS shows microcytic hypochromic erythrocytes with severe anisocytosis and poikilocytosis, plenty of target cells, prominent polychromasia and numerous normoblasts. *654*

- What is your first diagnosis?
- What type of patterns you expect in Hb-electrophoresis of the patient?
- What type of abnormalities you expect in parents?
- Name two most common type of genetic abnormalities that can be inherited by the affectd girl.

PC45: A 11-year-old boy presents with moderate anemia, jaundice and periodic attacks of painful swellings of fingers and toes for almost 10 years. PBS shows typical features. *655*

- What is your provisional diagnosis?
- What is the diagnostic clue as seen in the PBS?
- Does the boy present with splenomegaly?
- What type of jaundice you expect in this set up?
- What will be the urine color?
- What abnormalities you expect in Hb-electrophoresis and globin gene analysis?

PC46: A middle-aged man presents with progressive weakness, pallor and massive splenomegaly for last 6 months. Total leukocyte count is 1,50,000/cumm. PBS also shows characteristic changes. *655*

- What is your provisional diagnosis?
- Describe the PBS.
- How can you confirm your diagnosis?
- What is the closest differential diagnosis?
- Name different stages of the disease.

PC47: A 56-year-old female complains of acute onset of severe pallor, high fever and bleeding gum approximately 1 month after receiving chloramphenicol therapy. *656*
- Mention your provisional diagnosis.
- Describe the expected PBS.
- Describe the bone marrow aspirate findings.
- What is the confirmatory test?
- Comment about prognosis.

PC48: A 81-year-old male presents with gradually developing weakness, generalized lymphadenopathy and hepatosplenomegaly for last one year. Microphotograph of the peripheral smear is given below. Total leukocyte count is 2,40,000/cumm. *656*
- What is your provisional diagnosis?
- What can be the closest differential diagnosis?
- Which cell in PBS helps in differential diagnosis (arrow marked)?
- How can you confirm your diagnosis?
- Discuss the RBC morphology in this case.

PC49: A 3-year-old girl suddenly develops high fever and bleeding gum with extreme weakness. O/E: Severe pallor, sternal tenderness, cervical lymphadenopathy and hepatosplenomegaly. Microphotograph of the PBS is given below. Total count of leukocytes is 21,000/cumm. *657*
- What is your provisional diagnosis?
- Identify the two marked cells as shown in the PBS and describe their features.
- How can you classify this disorder?
- What is the aim of using cytochemical stains in this set up?

PC50: A 37-year-old female presents with extreme lassitude, irregular fever, weight loss and petechial bleeding spots over different parts of the body for last one month. O/E: She has severe pallor, sternal tenderness with hepatosplenomegaly. Examination of peripheral smear shows presence of atypical cells with more than two nucleoli and rod-like reddish structures in the cytoplasm. *658*
- What is your provisional diagnosis?
- Identify the atypical cells and rod-like structures.
- Describe the morphology of atypical cells.
- What is the diagnostic criteria of this disorder?
- What special stain do you like to use in this condition?

PC51: A 73-year-old man, suffering from high fever and acute cholecystitis with accompanying peritonitis, presents with following blood picture:
TLC:32,600/cumm;DLC:Metamyelocyte—07%,Bandforms—11%,Neutrophil—68%, Eosinophil—01%, Basophil—00%, Lymphocyte—10% Monocyte—03%.
Platelet: Adequate. *658*
- What is this typical blood picture?
- What is the expected ESR value in this set up?
- What special features you expect in the neutrophils?
- Comment about LAP score?

PC52: A 3-year-old boy presents with high fever, facial rashes, headache, neck rigidity and convulsion. Examination of PBS shows following features:
TLC: 43,000/cumm; DC: N_{17}, E_{01}, B_{00}, L_{81}, M_{01}.
Platelet: Adequate. *658*
- Comment about this blood picture.

- What is the closest differential diagnosis?
- What can complicate the differentiation process?

PC53: A 49-year-old male presents with weakness and generalized lymphadenopathy for 6 months. Examination of PBS does not reveal any abnormality. FNAC from cervical lymph node demonstrates diffuse infiltration of monomorphic lymphoid cells with nuclear membrane irregularities and open chromatin pattern. Macrophages and mature lymphocytes are scanty. Immunochemical stain later proves monoclonality of infiltrating lymphoid cells. Microphotograph of excised lymph node is given below. *659*

- What is your provisional diagnosis?
- Name the different methods for classification of this disorder.
- Name two specific B and T-lymphocyte markers. Why PBS must be examined in these cases?

PC54: A 41-year-old male presents with fever and weight loss for 4 months. O/E: Bilateral cervical lymphadenopathy. Lymph nodes are firm, discrete and nontender. FNAC from the lymph nodes show presence of large binucleated giant cells in a background of mixed inflammatory cells particularly plasma cells and eosinophils. Microphotograph of excised lymph node also shows presence of large binucleated cells. *659*

- Identify the large cell as seen in the picture. Describe its morphology. What is your provisional diagnosis? Name different variants of the large cell. Mention specific CD markers of this giant cell. How can you classify the disease? What is the peculiarity of the spread of this disease?

PC55: A 6-year-old boy gets admitted into pediatric ward with epistaxis, bleeding gum and petechial bleeding spots all over body for 1 day following an attack of cold, cough and fever 3 weeks before. O/E: Liver, spleen and lymph nodes are not palpable. Examination of PBS reveals grossly inadequate platelet count (approximately 10,000/cumm). No immature cell is seen. *660*

- What is your provisional diagnosis?
- What will be the expected changes in the bone marrow?
- Name some other causes of low platelet count?
- How will you differentiate this condition from others?
- State the results of BT and CT in this condition. What is 'pseudothrombocytopenia'?

PC56: A 31-year-old female presents with severe bleeding following tooth extraction. She admits increased bleeding tendency even from minor injuries since infancy. Examination of PBS does not show any abnormality. BT and CT both are seen to be prolonged. *660*

- What is your provisional diagnosis?
- What is the exact hematological abnormality?
- How it is genetically carried?
- Why there is prolongation of both BT and CT?

PC57: A 10-year-old boy presents with repeated painful knee swellings since crawling (see picture). He also suffers from excessive bleeding from minor injuries. Episodes of bleeding due to minor traumas are also reported in one of his maternal uncles. Aspirations of the knee joints yield frank blood. *661*

- What is your provisional diagnosis?
- Describe the genetic inheritance of the disease. How can you classify the disease? Grade the severity of the disease. Discuss the results of BT and CT.

PC58: A 32-year female sex worker seeks medical attention with fever, weakness, rapid weight loss and persistent diarrhea for last 6 months. O/E: Moderate pallor, cervical lymphadenopathy and hepatosplenomegaly. *661*
- What is your first clinical diagnosis?
- What other conditions can give rise to similar features?
- What should you do to confirm your diagnosis?
- Name some specific neoplasms associated with this disorder.
- Name the specific etiological agent.

PC59: A 36-year-old healthy female presents with following report.
FBs–102 mg%; PPBS–121 mg%; Urine sugar (Both fasting and PP): +ve. *662*
- What is the disorder?
- Discuss etiology.
- How the disease progresses?
- Name other causes of detectable sugar in urine.
- Name one test used for this purpose.

PC60: A 39-year-old male presents with following blood and urine report.
FBS—89 mg%; Fasting urine sugar—Nil; PPBS—83 mg%; PP urine sugar—Nil; BS 1 hr after meal—206 mg%; corresponding urine sugar— +; Patient had partial gastrectomy 2 years before due to bleeding ulcer. *662*
- What is your diagnosis?
- Why this type of response in oral glucose tolerance is termed 'lag curve'?
- What is the actual pathogenesis of this disease?
- How the disease progresses?

PC61: A 59-year-old male suffering from diabetes mellitus for 25 years has recently developed pedal edema, puffiness of face and pallor. Urine examination shown following feature: Sugar—+, Alb—++, P. cells—2–3/HPF, RBC—Nil, Hyaline cast—+. *662*
- What is your provisional diagnosis?
- What biochemical tests should be done in this set up?
- What confirmatory test you want to perform and what are the expected findings?

PC62: Study the following oral glucose tolerance test curves and identify each. *662*

PC63: Read the following routine urine reports carefully and give your provisional diagnosis. *665*

PC64: A 9-year-old girl complains of facial puffiness with passage of smoky urine. Routine urine examination shows: Protein — +; P. cells: 2–3; HPF; RBC—Plenty; RBC casts— +. *667*
- What is your provisional diagnosis?
- Mention different components of the disorder. What type of renal pathology can lead to this disorder?
- What biochemical changes you will expect in the blood?

PC65: Report of liver function test of a 26-year-old male suffering from chronic jaundice as follows:
Bilirubin—2.3 mg%; Unconjugated variant—1.8 mg%; Conjugated variant—0.5 mg%; SGPT, SGOT and Alkaline phosphatase—Normal level; Hb–variant analysis fail to show any abnormality. *668*
- What is your provisional diagnosis?
- Name some other similar causes of hyperbilirubinemia.
- What is the actual cause of this disorder?
- How the disease progress? Why Hb–variant analysis was done?

PC66: A 26-year-old female presents with pallor and jaundice.
Urine color—Light yellow; Stool color—Deep yellow; LFT—Unconjugated hyperbilirubinemia. No other abnormality; Reticulocyte count—4.2%. *668*
- What is your diagnosis?
- Explain the color of stool and urine.
- Name some disorders with similar picture.
- What is the significance of reticulocyte count?

PC67: A 16-year-old male complains of low-grade fever with pain abdomen for 3 days. Urine color is deep yellow but stool color is clay-colored. *668*
- What is your provisional diagnosis? Enumerate the etiology.
- Explain the color of stool and urine.
- What are the expected changes in LFT?
- What is the significance of estimation of urobilinogen level in urine in this set up?

PC68: 6 months infant presents with continuous cry, refusal to food and bulging anterior fontanelle with irregular fever for 14 days. Aspiration of CSF fluid yields clear fluid which form fine coagulum on standing (see figure). Pressure is moderately raised. Protein—108 mg%, Sugar—30 mg%, Cell count—110/cumm, mixture of lymphocytes and monocytes. *669*
- What is your provisional diagnosis?
- What can be other possibilities ?
- How can you confirm your diagnosis?
- Name two complications

PC69: A 9-year-old girl presents with high fever, headache, neck rigidity and convulsion for last 2 days.
CSF examination shows: Pressure—Highly increased; Fluid—Hazy, forms large clot; Protein—186 mg%; Sugar—10 mg%; Cell count—1200/cumm; Cell type—Majority neutrophils. *669*
- What is your provisional diagnosis? Mention the site ideal for CSF aspiration.
- Explain the causes of high protein and low glucose level

PC70: A 3-year-old boy get admitted with drowsiness, high fever, intense headache, photophobia and neck rigidity for 2 days.
CSF examination reveals: Pressure—Moderately raised; Fluid—Clear, no clot; Protein—106 mg%; Sugar—49 mg%; Cell count—86/cumm; Cell type—Mostly lymphocytosis. *670*
- What is your provisional diagnosis?
- What can be other causes?
- How will you confirm your diagnosis?

Bibliography *671*
Index *673*

CHAPTER 4

Genitourinary System

GUQ1

***

A 40-year-old male presents with weakness, fatigue, polyuria, hypertension and occasional hematuria for 3 years. O/E: Bilateral abdominal lumps at flanks.

- **What are the possible causes?**
- **How will you investigate the case?**

Ans. **Possible causes**:

– Adult polycystic kidney

– Bilateral hydronephrosis.

[**Adult polycystic kidney**:

- It is a congenital disorder characterized by presence of multiple expanding cysts in both kidneys that ultimately destroy renal parenchyma.
- It is an autosomal dominant disorder.
- As the cysts are slow growing, symptoms do not appear before 4th or 5th decade.
- This disease is always bilateral and is responsible for 10% cases of chronic renal failure.
- The precise gene involved is named as PKD1 (located over 16p 13.3) and codes a protein-polycystin. This protein is possibly responsible for cell-cell and cell-matrix interactions.
- PKD2 and PKD3 are other genes, which may be involved.
- How this abnormal PKD1 gene will give rise to cyst formation is not clearly defined. Current hypothesis is tabulated below:

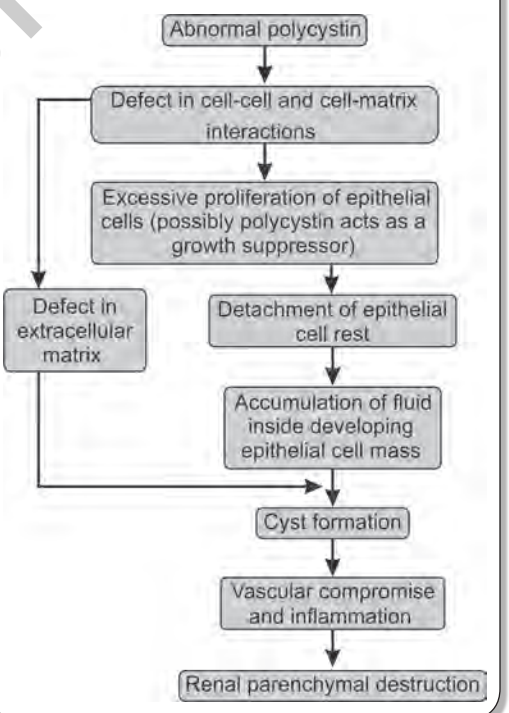

JAYPEE BROTHERS

- Grossly, both kidneys are enlarged and each may weigh upto 4 kg. Form the surface these are composed of multiple cysts 3–4 cm in size without any intervening parenchyma. Accumulated fluid may be clear, turbid or even hemorrhagic.
- Microscopically, cysts are lined by tubular epithelium. Papillary projections are often seen inside the lumen. Occasionally, glomerular tufts may be present inside cystic spaces. Few functioning nephrons may also be present.
- Patients usually remain asymptomatic until appearance of features of chronic renal failure. But in some cases excessive dilation or hemorrhage inside cysts may produce pain. Pain may also occur due to excretion of blood clot producing renal colic.
- Other presenting features are:
  - Large palpable abdominal masses which often produce dragging sensation.
  - Hematuria, polyuria, proteinuria, hypertension and progressive renal failure with azotemia.
- There are also cyst formation in other organs like:
  - Liver: 40% cases have polycystic liver disease. Cysts are derived from biliary epithelium. Usually asymptomatic, but hepatomegaly with pain abdomen may occur.
  - Spleen, pancreas or lung.
  - Circle of Willis: It can produce subarachnoid hemorrhage and responsible for 4–10% deaths in polycystic kidney disease.
  - Mitral valve producing prolapse.
- Diagnosis can be made upon:
  - Clinical features.
  - Urine routine examination.
  - Renal function tests.
  - USG and CT scan of kidney and other organs.
  - Renal biopsy.
  - Examination of resected kidney.
- The disease progresses slowly and patients may survive for a long-time. Causes of death are:

Hypertension and its complications	– 40%
Intercurrent infections	– 25%
Cerebrovascular accidents	– 15%

Childhood polycystic kidney disease: Autosomal recessive inheritance; presentation most commonly during perinatal period; infantile or juvenile variants are rarely seen.

- *Common presentation*:
  - Bilateral kidney enlargement at birth.
  - Rapidly developing renal failure and death in early infancy.
  - Survivors will develop congenital hepatic fibrosis with portal hypertension and splenomegaly. This feature may rarely develop in adult polycystic kidney diseases.
- *Gross*:
  - Enlargement of kidney with smooth outer surface.
  - Numerous small cysts in the cortex and medulla giving kidney sponge like appearance.
  - Dilated elongated channels parallel to cortex, replacing cortex and medulla.
- *Microscopy*: Affected kidney will show dilation of collecting tubules of all nephrons forming cysts. These cysts are lined by cuboidal cells.

Liver will also show multiple epithelial lined cysts and portal bile duct proliferations.

Other cystic diseases of kidney:

Medullary sponge kidney: Medullary cysts are present. Hematuria and

JAYPEE BROTHERS

recurrent infections with stone formation are the presenting features.

Simple cysts: Presence of multiple cysts; no organomegaly; hematuria may occur.

Dialysis associated cystic disease: Cystic degeneration of already diseased kidney; hemorrhage common complication; renal cell carcinomas can develop from the wall of the cysts.

Familial juvenile nephronophthisis: Autosomal recessive disorder; kidney is smaller in size with multiple corticomedullary cysts. Progressive renal failure will appear from infancy.

Adult–onset medullary cystic disease: Autosomal recessive; features are similar to previous disease. Only renal failure appears in adult life.

Bilateral hydronephrosis: Hydronephrosis is defined as progressive dilation of renal pelvis and calyceal system with resultant atrophy of renal parenchyma occurring as a result of obstruction to outflow of urine.

Etiology: Obstruction in urinary tract (obstructive uropathy) is the cause of hydronephrosis. Unrelieved obstruction, if present for a prolonged duration, will ultimately progress to hydronephrosis.

Common causes of obstruction are:
Congenital: Presence of congenital urethral strictures, posterior urethral valves, severe vesicourethral reflux, bladder neck obstruction, etc.

Pelviureteric junction (PUJ) obstruction: Usually idiopathic
Urinary calculi.
Benign prostatic hypertrophy.
Tumors obstructing urinary outflow like bladder carcinoma or carcinoma prostate.
Inflammation of urinary tract.
As a complication of normal pregnancy or genital prolapse of females.
Spinal cord injury or dysfunctional abnormality.
Obstruction may be:
Sudden or insidious: *Calculi vs. prostatic hypertrophy.*
Complete or partial.
Unilateral or bilateral: Obstruction at the level of bladder or below will produce bilateral obstruction.

Most common causes of hydronephrosis: *Idiopathic pelviureteric junction obstruction is the major cause of unilateral hydronephrosis. Right kidney is more commonly affected. Presence of aberrant blood vessels are often thought to be the cause.*

Pathogenesis
- Obstruction will give rise to pressure over pelvicalyceal system with dilation.
- High pressure inside pelvis will be reflected back to cortex by collecting tubules resulting in atrophy.
- There is also vascular compression with diminished medullary plasma flow.
- Initially, these vascular changes are reversible and medullary functional abnormalities appear only with prolonged obstruction.
- Initial functional defect is failure of the tubules to concentrate urine.
- Glomerular filtration rate (GFR) is affected at a later stage.
- Obstruction naturally also predisposes to infection with interstitial inflammatory cell infiltration and fibrosis.

Pathology: Sudden complete obstruction will lead to rapid fall of GFR with mild dilation of pelvicalyceal system. But subtotal intermittent obstruction will not impair GFR initially, resulting in huge dilation.

JAYPEE BROTHERS

Gross: Kidney will become increased in size with dilation of pelvis and calyces on cut section. There is also thinning of renal parenchyma. Inflammatory fibrosis is evident. Finally, kidney will transform into a thin-walled cystic structure.

Microscopical features: Thinning and atrophy of cortex; diffuse interstitial inflammatory cell infiltrate and fibrosis; dilated pelvis with blunting of pyramids.

Clinical features

- Pain: It may occur due to distension of pelvis.
- Enlarged kidney: Unilateral or bilateral.
- Polyuria and nocturia: It is due to loss of tubular concentrating function.
- Oliguria and anuria: With bilateral complete obstruction; survival only possible with early release of obstruction.
- Features of renal failure like hypertension, pallor and rising azotemia: uncommon in unilateral obstruction, but long standing bilateral obstruction will always lead to this complication.

Diagnosis

- Clinical features
- Routine urine examination
- Other renal function tests
- Intravenous pyelography
- Ultrasonography and CT scan.

(Dietl's crisis: It is associated with unilateral hydronephrosis and characterized by dragging sensation in the affected site following voluminous intake of water, and relief of symptoms after passage of large volume of urine).

Renal calculi

– Common cause of urinary tract obstruction.

- Men commonly affected; peak age is 20–30 years.
- Gout, cystinuria, etc. congenital or acquired metabolic disorders predispose to stone formation.
- Biochemically, four main types of stones:
  - Calcium stones: Composed of calcium oxalate with or without calcium phosphate; responsible for 75% cases.
  - Triple phosphate stones: Composed of magnesium ammonium phosphate; known as struvite stones and account for 15% cases.
  - Uric acid stones: Slightly more than 5% of stones.
  - Cystine stones: Upto 2% of stones are of this type.

Mucoproteins are present in each variant of stone as organic matrix.

- Stones are formed due to supersaturation of plasma by stone forming elements such as:
  - Calcium stones: Hypercalcemia and hypercalciuria are responsible for this type of stone formation. Following conditions are associated: Hyperparathyroidism, sarcoidosis, diffuse bone diseases and absorptive hypercalciuria.
  - Triple phosphate stones are formed by infection of urea-splitting bacteria, which converts excreted urea to ammonia. These stones are largest. Stag horn calculi are of this type.
  - Uric acid stones are commonly associated with gout and acute leukemias due to rapid cell turnover.
  - Cystine stones: Associated with cystinuria.
- Apart from supersaturation, alteration in urinary pH, decreased urine volume and bacterial infections are the conditions influencing stone formation.

JAYPEE BROTHERS

- But many stones can occur without any obvious cause. So, it is now postulated that there are some physiological inhibitors of crystal formation in urine like nephrocalcin, a glycoprotein, citrate, glycosaminoglycans, pyrophosphate, etc. Deficiency of these inhibitors will result in stone formation.
- Stones are more commonly formed in the renal pelvis and urinary bladder. Pelvic stones are small, unilateral and smooth. Rarely, larger stag horn calculi may be formed.

Entry of the pelvic stones in the ureter will produce obstruction. Stones in the ureter may commonly lodge at any of the four locations: At the beginning of ureter, at the crossing of renal artery, at the level of upper border of hipbone and at vesicoureteral junction.

Result will be renal colic and unilateral obstruction.

Bladder stones are larger in size and usually will not produce obstructive features but pain, hematuria and infections are common presenting features.

Common features of renal calculi are:
- Urinary tract obstruction
- Hydronephrotic changes in kidney
- Renal colic
- Silent hematuria
- Recurrent infections.]

For differentiation of these two conditions history, clinical examination and relevant investigations are important.

History

	Adult polycystic kidney	*Hydronephrosis*
Types of disease	Congenital	Acquired, rarely congenital
Family history	Significant	Usually not important
Age	40 – 50 year	Any age, commonly in adults
Unilateral or bilateral disease	Both kidneys are involved	One or both kidneys may be involved
Pain	Uncommon	Common due to pelvic distension
Hematuria	±	Uncommon
Polyuria and nocturia	±	Commonly seen in early cases
Oliguria	Uncommon	May be associated with bilateral complete obstruction
Symptoms of urinary tract infection	Rare	Common
Symptoms of heart failure	±	Absent
Symptoms of cerebrovascular accident	±	Absent

JAYPEE BROTHERS

Examination

	Adult polycystic kidney	*Hydronephrosis*
Hypertension	Common	±
Anemia	Common in late stages	±
Abdominal lump	Bilateral huge lump	Uni or bilateral lump of variable size
Hepatomegaly	±	Absent
Signs of mitral valve prolapse	±	Absent
Signs of hemorrhagic cerebrovascular accidents	±	Absent
Signs of chronic renal failure	Always present in later stage	Not expected in unilateral cases

Investigations

Routine blood examination:

↓ Hb%: Expected in late stages of adult polycystic kidney and bilateral hydronephrosis.

↑ TLC with ↑ ESR: Associated with hydronephrosis during acute attack of urinary tract infection.

Urine examination:

RBC: ± In both conditions.

Pus cells: Plenty of pus cells indicate UTI, which often complicates hydronephrosis.

Albumin: UTI may gives rise to albuminuria. But in late stages of both diseases there will be albuminuria.

Specific gravity: Low fixed specific gravity (1010) occurs due to kidney failure in late stages of both conditions.

X-*ray of kidney, urinary bladder and ureter (KUB)*: Stones can be demonstrated as most are radiopaque.

USG of abdomen:

- Adult polycystic kidney: Huge enlargement of kidney of both sides with multiple thin-walled cysts.
- Hydronephrosis: Large kidney, dilated pelvicalyceal system with thinned out cortex; stones often can be present.
- Multiple cysts in liver, pancreas, and spleen: Features of polycystic kidney.

CT scan of abdomen: Better identification of renal or other organ changes.

Echocardiography: It may demonstrate mitral valve prolapse in cases of adult polycystic kidney.

Cystoscopy and ascending pyelogram: Bladder stones, tumors, prostatic tumors, urethral obstructions or ureteral obstructions can be demonstrated as causes of hydronephrosis.

Excretion urography: Essential test for detection of hydronephrosis; **Earliest change**: **Clubbing of the calyces**. Polycystic kidney disease will show spider leg or bell-like appearance.

Isotope renography: Most helpful test to establish dilatation of renal collecting system due to obstruction, as seen in hydronephrosis. DTPA scanning is very much helpful in early cases.

Serum urea and creatinine: Adult polycystic kidney cases surely have increased level towards terminal stages. Only bilateral hydronephrosis may lead to elevation of blood levels of urea and creatinine.

JAYPEE BROTHERS

Renal biopsy:
- Adult polycystic kidney: Multiple thin-walled cysts lined by variable epithelium with papillary projections at occasional cysts. Normal nephrons may also be present.
- Hydronephrosis: Dilated pelvis with blunting of pyramids, thinning of cortex and interstitial chronic inflammatory cell infiltrate with fibrosis.

Examination of resected kidney:
- Adult polycystic kidney: Hugely enlarged kidneys – each may weight-up to 4 kg; multiple cysts of 3–4 cm in size containing fluid separated by thin intervening septa.
- Hydronephrosis: Large kidney; dilated pelvis; thinned cortex.
- *Genetic study*: It may be done over adult polycystic kidney cases to locate abnormal genes.

GUQ2

***

A 6-year-old girl comes to outdoor with puffy face, pedal edema, oliguria and hematuria for 1 week. O/E: There is hypertension.
- **What is your provisional diagnosis?**
- **What can be other causes?**
- **How will you investigate the case?**

Ans. **Provisional diagnosis**: Acute (post-streptococcal) proliferative glomerulonephritis.

Other causes: Nonstreptococcal glomerulonephritis.

Rapidly progressive glomerulonephritis.

IgA-nephropathy (Berger's disease).

[**Acute poststreptococcal glomerulonephritis**: It is the commonest cause of acute glomerulonephritis in children. It presents with **acute nephritic syndrome characterized by sudden onset of hematuria, oliguria, edema and hypertension**. This form of glomerulonephritis may occur in epidemic form.

Etiopathogenesis:
- The disease occurs 1–4 weeks after an infection of Group A, β-hemolytic Streptococci (commonly type 12, 4 and 1); usually skin or pharyngeal infections.
- Over-crowding and poor hygiene predisposes to development of disease.
- The disease is thought to be immune mediated because:
  - There is a time gap between initial skin or pharyngeal infection and the development of renal pathology sufficient for building up of antibody titer.
  - Elevated serum titers of antibody against one or more streptococcal products are present.
  - Hypocomplementemia of patient's serum.
  - Presence of granular deposits of immunoglobulin in the glomeruli.
  - Dense deposits in the glomeruli as seen under electron microscope.
- Exact component of Streptococci that will produce cross-reacting antibody against glomerular protein is yet to be identified.

Pathology: Grossly, kidney may not show any change or slightly increased in size. But *light microscopic findings* are often diagnostic showing:
- Hypercellular and enlarged glomeruli.
- Infiltration of neutrophils and monocytes.
- Proliferation of endothelial, mesangial and sometimes epithelial cells.
- Obliteration of capillary lumens.
- Interstitial edema and inflammation.
- Presence of red cell casts in the tubules.

JAYPEE BROTHERS

Involvement of glomerulus is diffuse, i.e. all lobules of a glomerulus are involved.

Immunofluorescent microscopy will show: Focal granular deposits of IgG, IgM and C_3 in the mesangium and basement membrane.

Electron microscopy reveals: Discrete, amorphous, electron dense deposits on the epithelial side of basement membrane like humps; subendothelial and intramembranous deposits also seen; swelling of endothelial and mesangial cells.

Clinical features: Young child will present with following symptoms within 1–4 weeks after a throat or skin infection:
- Malaise, fever, nausea and vomiting
- Oliguria and red colored urine
- Hypertension and edema.

Adults will present with: Edema, hypertension and azotemia—

Course

Children: Complete recovery: 95% cases
Slow progress to chronic glomerulonephritis: 1–3%
Rapidly progressive glomerulonephritis: Less than 1% cases.

Adults: Complete recovery: 60%
Rapidly progressive glomerulonephritis: Only in few cases chronic proteinuria, hypertension and hematuria: 40% cases.
Few of the last group will ultimately develop chronic glomerulonephritis.

Diagnosis
- Clinical signs and symptoms
- Urine examination:
  Proteinuria – Less than 1 gm/day
  RBC – Cast may also be present
  Pus cells – Not frequent
- ↑Serum urea and creatinine
- Renal biopsy – Diagnostic
- Tests for confirmation of streptococcal etiology.

Nonstreptococcal acute glomerulonephritis:
- **Clinical features, pathological changes and diagnostic features** are similar to acute poststreptococcal glomerulonephritis.
- There will be no evidence of streptococcal infection.
- A variety of bacterial (staphylococci, meningococci, etc.), viral (hepatitis B, hepatitis C, etc.) and parasitic (Malaria) infections can produce this disease.

Rapidly progressive (crescentic) glomerulonephritis: RPGN is not a single disease entity, but a clinical syndrome associated with severe glomerular injury and is characterized by rapid loss of renal function progressing to renal failure within weeks to months. It can occur in a lot of conditions with immune mediated glomerular injury. Classic histological feature in all conditions is formation of crescents in glomeruli.

Etiopathogenesis: There are three main types of RPGN:

Type I RPGN: It occurs due to development of antiglomerular basement membrane (anti GBM) antibody. This antibody may cross-react with pulmonary alveolar basement membrane producing pulmonary hemorrhage. Goodpasture's syndrome is a classical example of type I RPGN presenting with pulmonary hemorrhage and linear deposits of IgG and C_3 in the GBM. Goodpasture's antigen is present in the noncollagenous portion of α_1 domain

JAYPEE BROTHERS

of type IV collagen. Viral infections, exposure to organic solvents or, different drugs may produce autoantibodies against this antigen. Smoking also helps in pathogenesis.

Type II RPGN: It can be a complication of any form of immune complex mediated disease and is characterized by granular (lumpy bumpy) deposits of immunoglobulins over basement membrane. Proliferative glomerulonephritis, SLE, IgA nephropathy and Henoch-Schönlein purpura all can give rise to this type of RPGN.

Type III RPGN: This is also known as pauci-immune disease and there will neither be any anti-GBM antibodies nor any circulating immune complexes. Most of the patients have antineutrophilic cytoplasmic antibody (ANCA) in the serum. Wegener's granulomatosis is an example of this type of RPGN.

It is to be mentioned that about 50% RPGN cases occur without any well-defined renal or extrarenal diseases. A quarter of these cases have anti-GBM antibody without pulmonary involvement, another quarter have circulating immune complexes and rest 50% are pauci-immune type.

Pathology

Gross: The affected kidney will become enlarged, pale in color with focal minute hemorrhages over external surface.

Light microscopy:

- Presence of crescents in the Bowman's space of most of the glomeruli, which is formed by proliferation of parietal cells.
- Monocytes, lymphocytes, macrophages and neutrophils also reach the space and help in formation of crescents.
- Ultimately, there will be obliteration of Bowman's space with compression of glomerular tufts.

Fibrin strands will deposit inside crescents.

Immunofluorescent microscopy:

Type I — Linear deposits; Type II—Granular deposits; Type III–No deposition or, scanty linear or, granular deposit Electron microscopy: Subepithelial deposits may be present. Rupture of GBM is present in most cases.

Clinical features

- Hematuria, hypertension and edema.
- Oliguria often progressing to acute renal failure.
- Pulmonary hemorrhage may be present.
- Systemic manifestations of other diseases like SLE may be present.

Diagnosis

- Clinical features
- Urine examination:
  - Albumin—Moderate more than 1 gm/day.
  - RBC–Plenty, often with casts.
  - Pus cells–Not frequent.
- Progressive rise of urea and creatinine
- Renal biopsy
- Tests to confirm associated diseases.

IgA nephropathy (Berger's disease): Berger's disease is characterized by prominent IgA deposits in the glomerular mesangium. So, for confirmation of diagnosis, immunofluorescence is always required. **This is the most common type of glomerulonephritis**, irrespective of age and racial differentiation.

JAYPEE BROTHERS

IgA deposit in mesangium may occur secondarily in Henoch-Schönlein purpura, liver or, intestinal diseases.

Pathogenesis: IgA is mainly secreted in the mucosal surfaces. Low levels of monomeric form is present in the serum. But IgA nephropathy shows: ↑ Serum polymeric IgA; presence of circulating IgA immune complexes in some cases; hypocomplementemia.

These findings suggest this possible hypothesis:

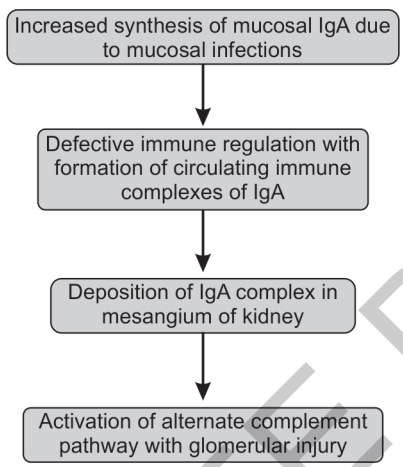

Pathology

Grossly, there may not be any change.

Light microscopy: Changes may be minimum to overt; mesangial proliferation and widening along with segmental proliferation of epithelial or, endothelial cells or, crescent formations are seen.

Immunofluorescent microscopy: Mesangial deposition of IgA, C_3 and lesser amounts of IgG and IgM.

Electron microscopy: Electron dense deposits are demonstrable in the mesangium.

Clinical features

- Children and young adults are affected
- Patients may present with any of these features:
  - Gross hematuria after a mucosal infection: Most common presentation.
  - Microscopic hematuria with or without proteinuria: 30–40% cases.
  - Acute nephritic syndrome: 5–10% cases.
  - Rarely, nephrotic syndrome.

Course: Hematuria may last for few days and then disappears completely. But repeated hematuria is often present. Slow progression to chronic renal failure over a period of 20 years can occur in a quarter to half of the cases.

Diagnosis

- Typical clinical presentation.
- Serum level of polymeric IgA is increased.
- Low serum complement level.
- Histopathological examination of kidney including immunofluorescent and ultrastructural studies.]

For differential diagnosis clinical features are as important as laboratory investigations:

Investigations

Routine blood examination: No specific change except in Goodpasture sydrome, which can be associated with significant anemia. Pancytopenia with raised ESR is seen in SLE.

Special tests of blood:

- Low complement level: Expected in all four conditions except type I or, possibly type III RPGN.

JAYPEE BROTHERS

History

	Acute post-streptococcal glomerulonephritis	*Nonstreptococcal glomerulonephritis*	*RPGN*	*IgA nephropathy*
Age	Commonly children	Commonly children	Any age	Children and young adults
Course	Acute	Acute	Rapid	Acute or chronic
Presentation	Acute nephritic syndrome	Acute nephritic syndrome	Rapidly developing renal failure	Only hematuria or acute nephritic syndrome or nephrotic syndrome
Hemoptysis	–	–	±	–
Purpuric spots	–	–	±	±
Skin rash and joint involvement	–	–	± (SLE)	–
Passage of smoky urine	+	+	+	±
H/o skin infection or sore throat weeks before	+	–	–	–
Nonstreptococcal infection few weeks before	–	+	–	–
Poor socio-economic status	Common	Variable	NS	NS

Examination

	Acute post-streptococcal glomerulonephritis	*Nonstreptococcal glomerulonephritis*	*RPGN*	*IgA nephropathy*
Pallor	±	±	Common	±
Edema	±	+	+	+
Oliguria	±	±	+	±
Hypertension	±	±	+	±
Pulmonary signs	–	–	±	–
Signs of GI or respiratory tract infections	–	–	–	±
Signs of connective tissue disease or vasculitis	–	–	±	±

JAYPEE BROTHERS

- Presence of circulating immune complexes: Also present in all conditions except type I and III RPGN.
- ↑ Serum polymeric IgA: Associated with IgA nephropathy.
- Presence of serum ANCA: Type III or, few type II cases of RPGN.
- Antinuclear antibodies: Type II RPGN due to SLE.
- Elevated serum level of antistreptolysin O, or antistreptodoranse: Associated with poststreptococcal glomerulonephritis.
- Evidences of nonstreptococcal infections like HBsAg antibody: Associated with nonstreptococcal glomerulonephritis.
- Elevated serum level of urea and creatinine: Mild elevation may be present in all conditions. But rapid rise is expected in RPGN.

Routine urine examination:
Poststreptococcal or nonstreptococcal glomerulonephritis: Proteinuria—Below 1 gm/day; Hematuria—Plenty of RBC, rarely blood casts.
RPGN: Proteinuria—Commonly above 1gm/day; Hematuria—Marked, often blood casts are seen.
IgA nephropathy: Proteinuria—Variable; Hematuria—Variable.

Renal biopsy:
Streptococcal or nonstreptococcal glomerulonephritis:
- LM (light microscopy): Diffuse involvement of many nephrons; large hypercellular glomeruli with proliferation of endothelial, mesangial or, rarely epithelial cells with inflammatory cell infiltration; interstitial edema and inflammatory cell infiltration.
- IM (immunofluorescent microscopy): Focal granular deposits of IgG, IgM and C_3 in basement membrane and mesangium.
- EM (electron microscopy): Basement membrane humps on epithelial side with subendothelial and intramembranous deposits.

IgA nephropathy:
- LM: Variable changes with mesangial proliferation and widening.
- IM: Mesangial deposition of IgA and C_3.
- EM: Mesangial electron dense deposits.

RPGN:
- LM: Involvement of most of the nephrons; formation of crescents in the Bowman's space.
- IM: Variable in different types:
  - Type I: Linear deposits of immunoglobulin and complement over basement membrane.
  - Type II: Focal granular deposit.
  - Type III: No deposit or, focal linear or granular deposits.
  - EM: Rupture of basement membrane.

Renal biopsy is the key for differentiation of the diseases. But establishing evidence of particular infection can only differentiate streptococcal or nonstreptococcal glomerulonephritis.

GUQ3

***

A 4-year-old boy is brought to you with generalized swelling of the body (anasarca) for 5 days. Urine examination shows marked proteinuria.

- **What is your provisional diagnosis? Enumerate the causes and how will you confirm your diagnosis?**

Ans. The child is possibly suffering from nephrotic syndrome.

Commonest cause of nephrotic syndrome in children is lipoid nephrosis.
Other causes are:
- Membranoproliferative glomerulonephritis.
- Focal segmental glomerulosclerosis.
- Membranous glomerulonephritis.

JAYPEE BROTHERS

detailed information on pathology books, visit our website **www.jaypeebrothers.com,** for detailed information on pathology books,

Problem-based Questions in PATHOLOGY (with Solutions)

During publication of the first edition of *Problem-based Questions in Pathology*, there was much confusion about acceptability of the approach as it was a pioneer work dealing with the clinical problems with solutions suitable to an undergraduate pathology teaching curriculum. The second edition hopes that it would also be a success like the first one. A lot of corrections and changes have been incorporated in each chapter. The first two chapters are almost completely rewritten. Two new chapters dealing with CNS pathology and problem cards, respectively are also included. An utmost care has been taken in each step to discuss all the topics in an orderly point-wise and lucid manner avoiding any confusion. The book would help young students of pathology to discover the actual patients behind the problems, paving the steps of their future success in clinical practice.



Sanjay Sengupta MBBS, DTM & H, MD (Path) is currently working as an Associate Professor in the Department of Pathology at Bankura Sammilani Medical College (BSMC), Bankura, West Bengal, India. He did his MBBS from RG Kar Medical College, Kolkata, West Bengal in 1989. Later, he received DTM & H diploma from School of Tropical Medicine, Kolkata. He has been awarded with MD (Pathology) degree from VSS Medical College, Burla, Odisha in 1996. He joined as a Demonstrator in the Department of Pathology at MCH, Kolkata, West Bengal in 1998. He also served in the Department of Pathology at CNMC, Kolkata, and Dr BC Roy Memorial Hospital for Children, Kolkata, as an Assistant Professor. He has published more than 30 original research articles and case reports in various national and international reputed journals.

Available at all medical bookstores
or buy online at www.jaypeebrothers.com

JAYPEE BROTHERS
Medical Publishers (P) Ltd.
www.jaypeebrothers.com
Join us on facebook.com/JaypeeMedicalPublishers

Shelving Recommendation
PATHOLOGY

ISBN 978-93-5250-003-1
9 789352 500031