brothers.com, for detailed information on neurology books, visit our website www.jaypeebrothers.com, for detailed information on neurology books, visit our website www.jaypeebrothers.com, for detailed information on neurology boo

Neuroscience

EEG Atlas

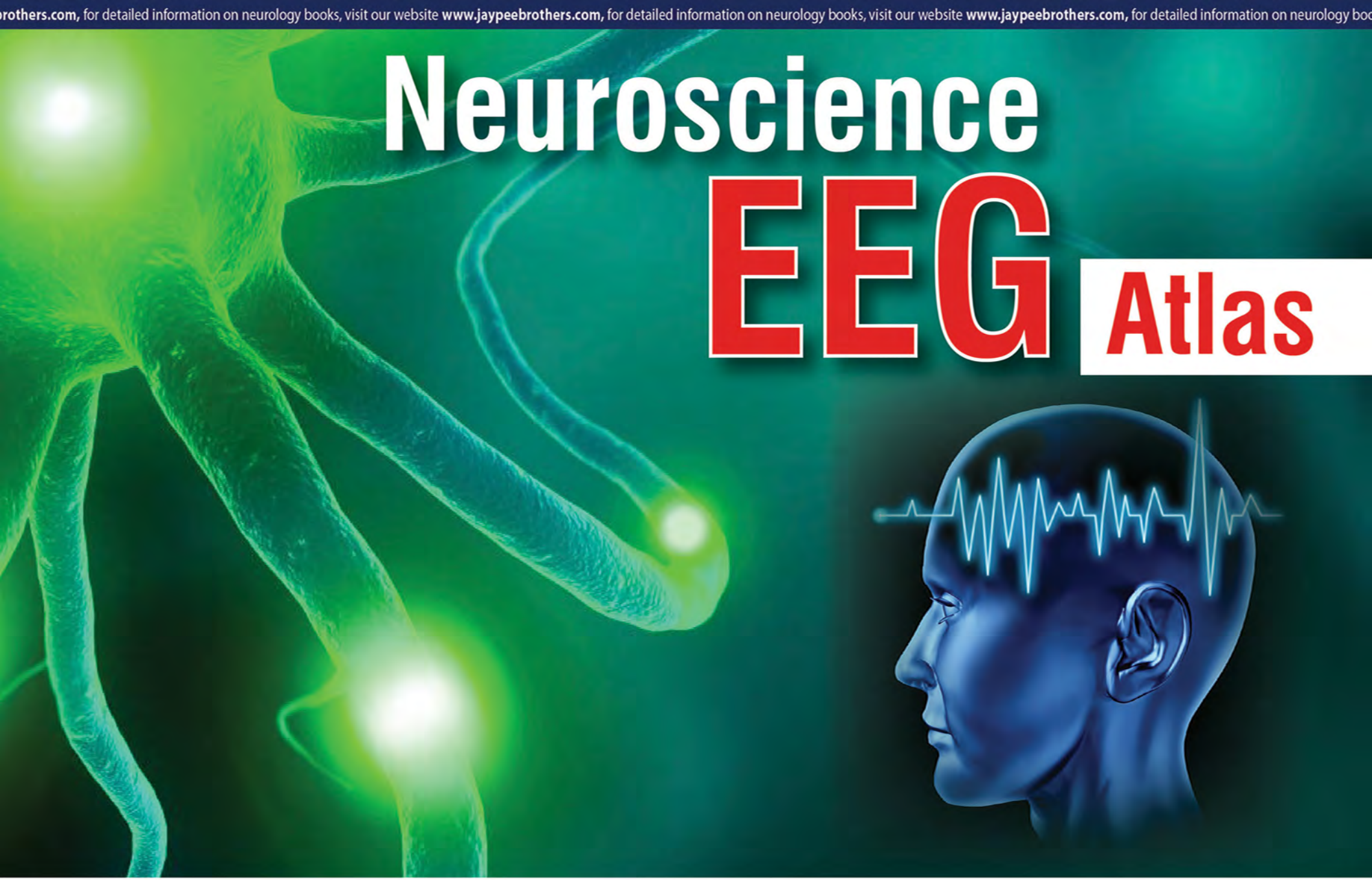

Amitabh Nundy

Foreword
JS Kathpal

JAYPEE

Contents

1. **Pattern of Artifacts** 1
2. **Normal EEG** 11
3. **Pediatric EEG** 28
4. **Seizures** 51
5. **Encephalitis** 79
6. **Dementia** 94
7. **Alcoholism with Tremors (Anxiety-Depression, Behavior Problem)** 97
8. **Nonepileptiform Discharges** 101
9. **Syncopal Attack** 107
10. **Space Occupying Lesions** 110

Index *131*

CHAPTER 4 Seizures

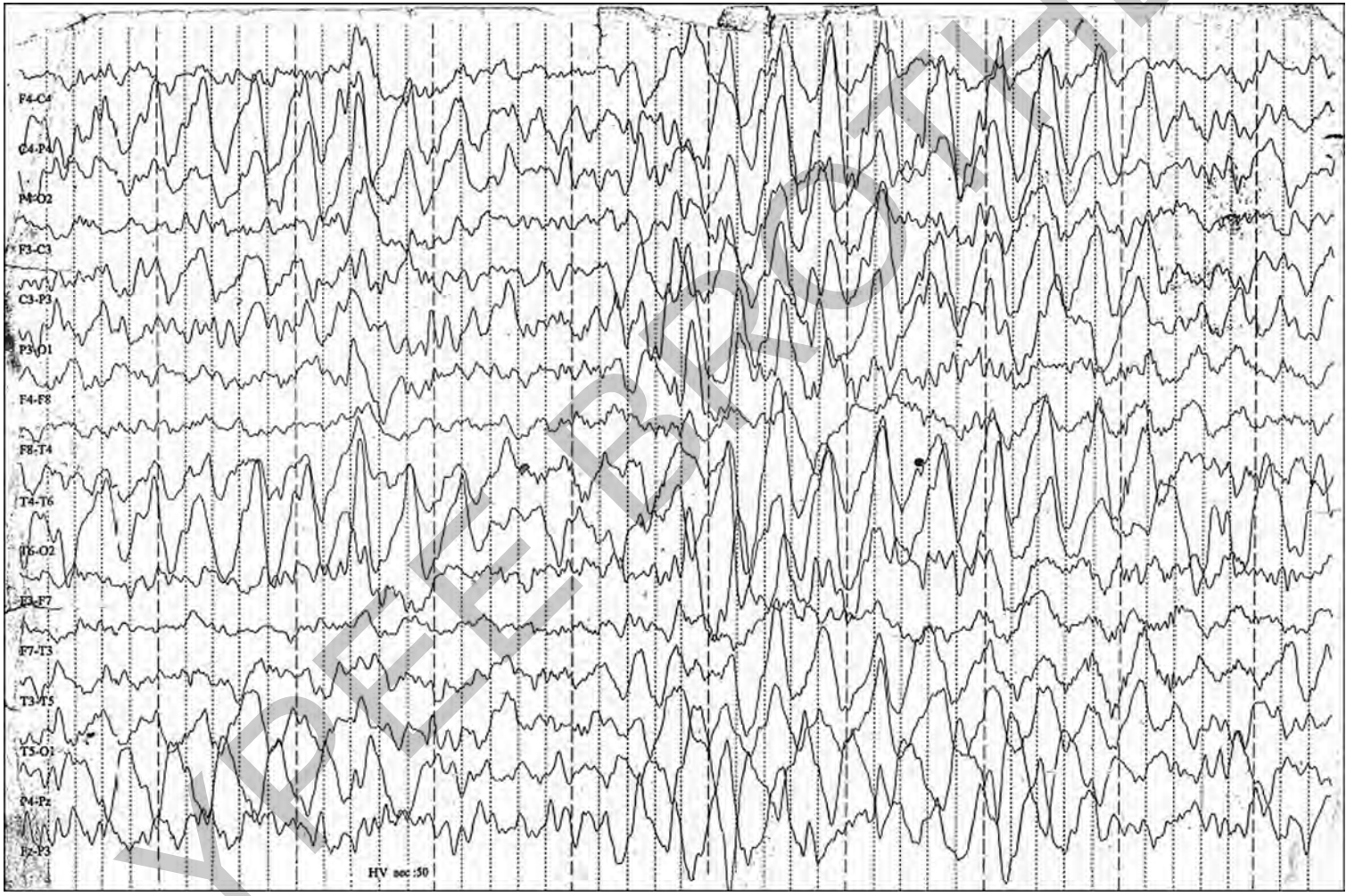

Figure 51 Video EEG
History of patient: Generalized seizure

JAYPEE BROTHERS



Figure 52 Eye open-close did not show any changes (12 years old male), known case of generalized seizure, many attacks, eptoin (100 mg) 1 tablet TDS

JAYPEE BROTHERS



Figure 53 Post-hyperventilation record (18 years old female), generalized seizure, had 2 attacks in 6 months, no medications

JAYPEE BROTHERS

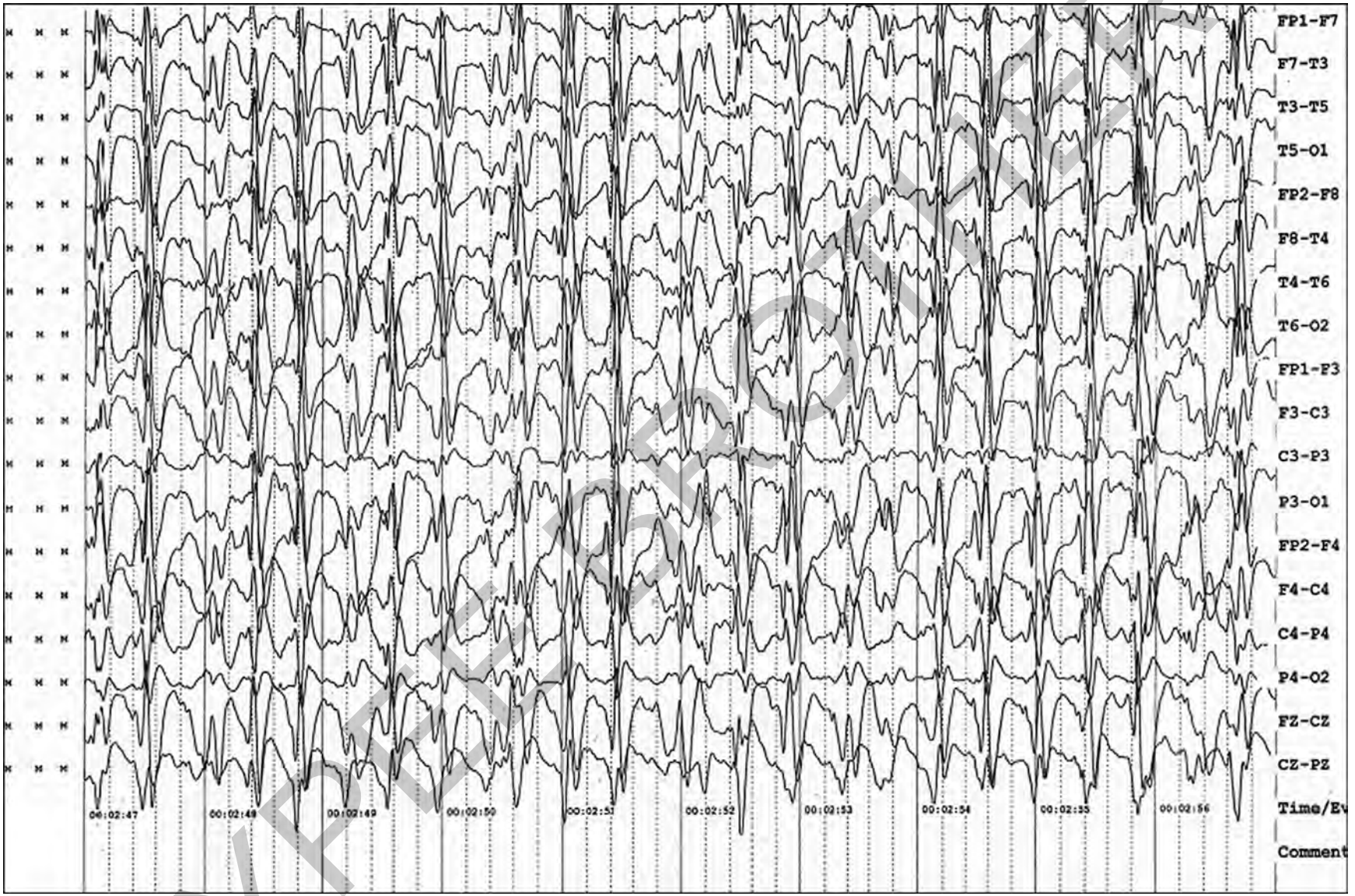

Figure 54 3 per second spike and wave discharges (12 years old female), partial seziure—vacant look since 3 years, for few seconds daily attack, was on homeopathy treatment for 1 year

JAYPEE BROTHERS

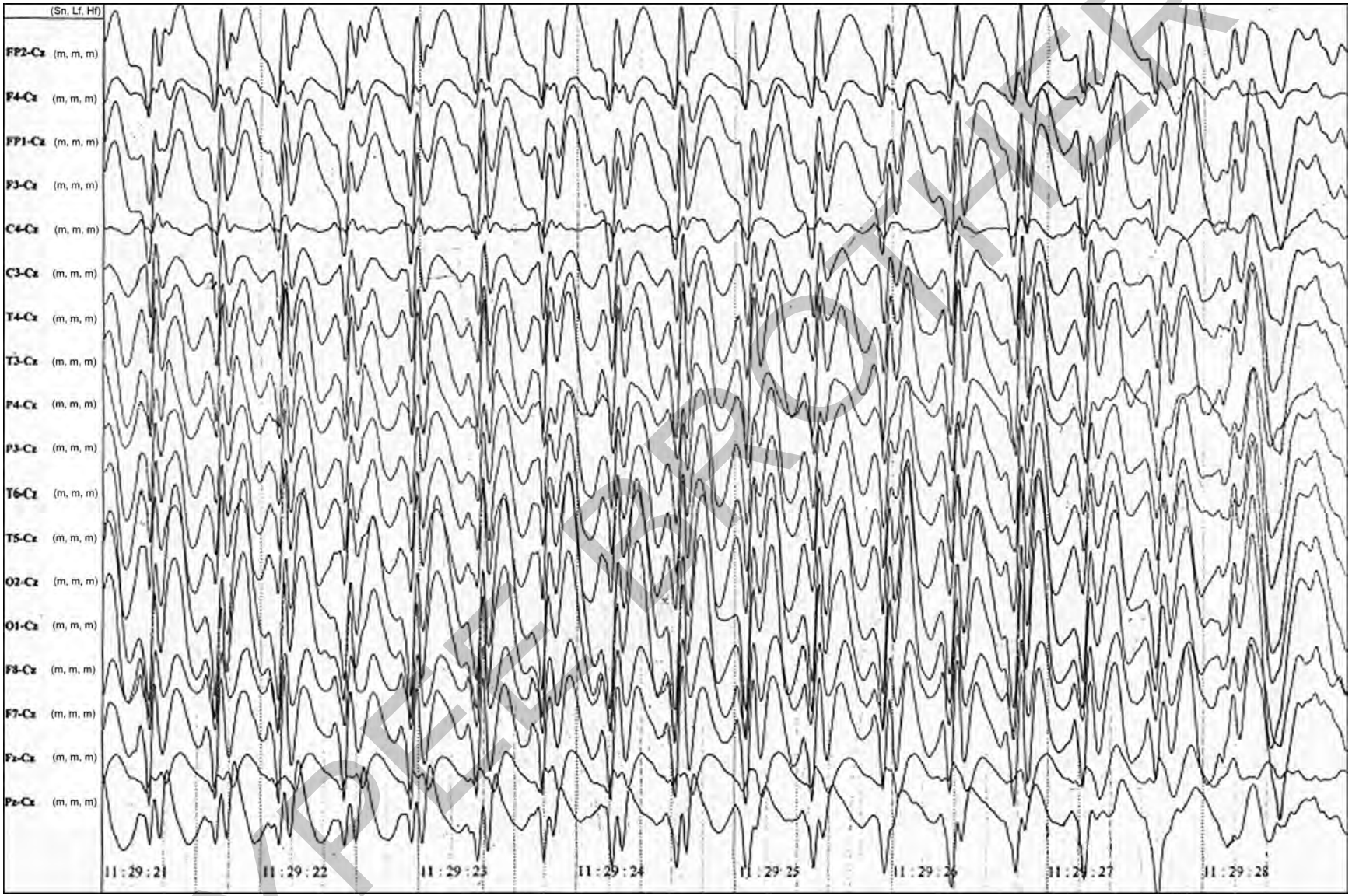

Figure 55 Clinical attack (22 years old male), petit mal epilepsy

JAYPEE BROTHERS

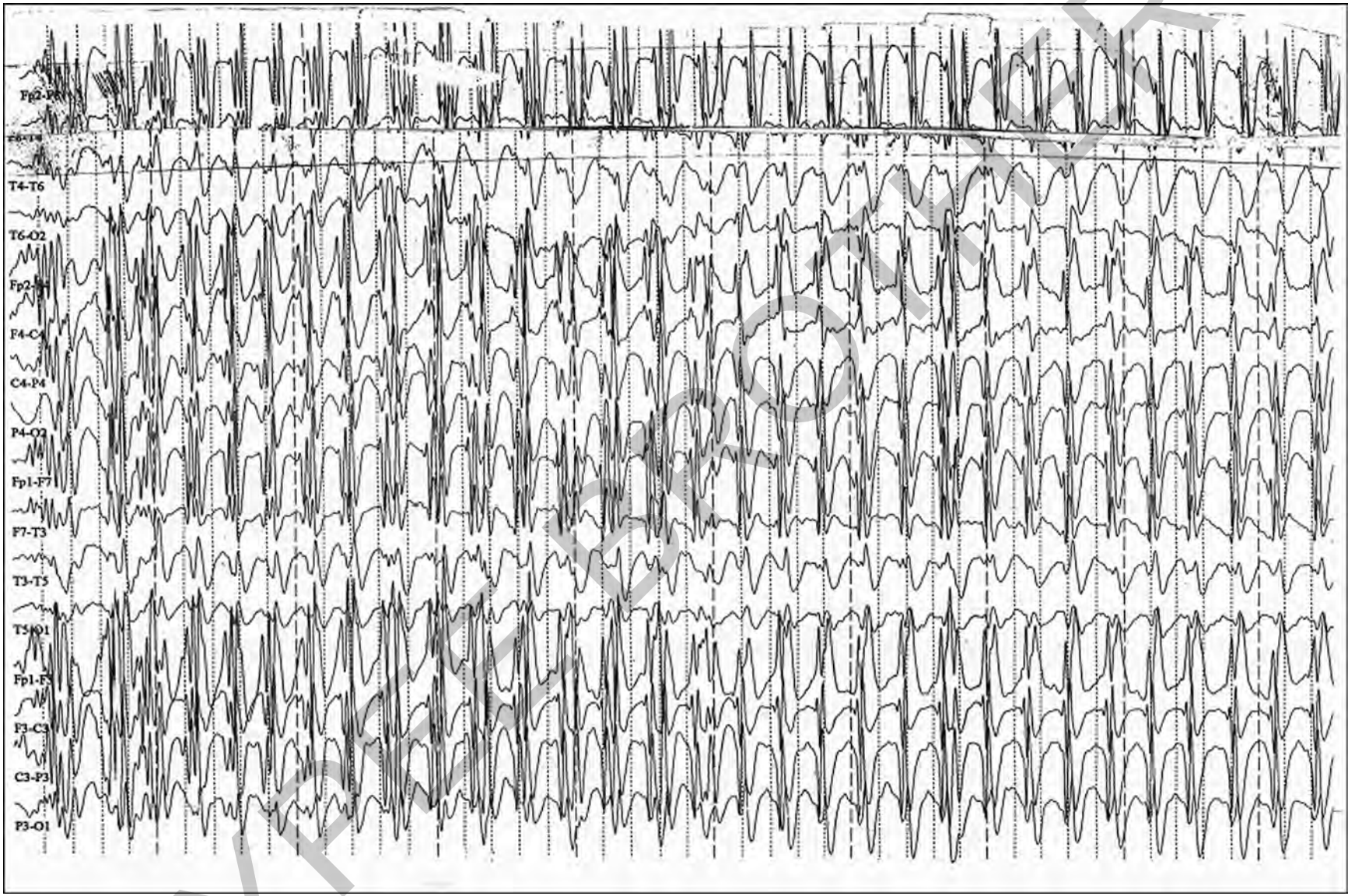

Figure 56 Video EEG (spike and wave discharges)

JAYPEE BROTHERS

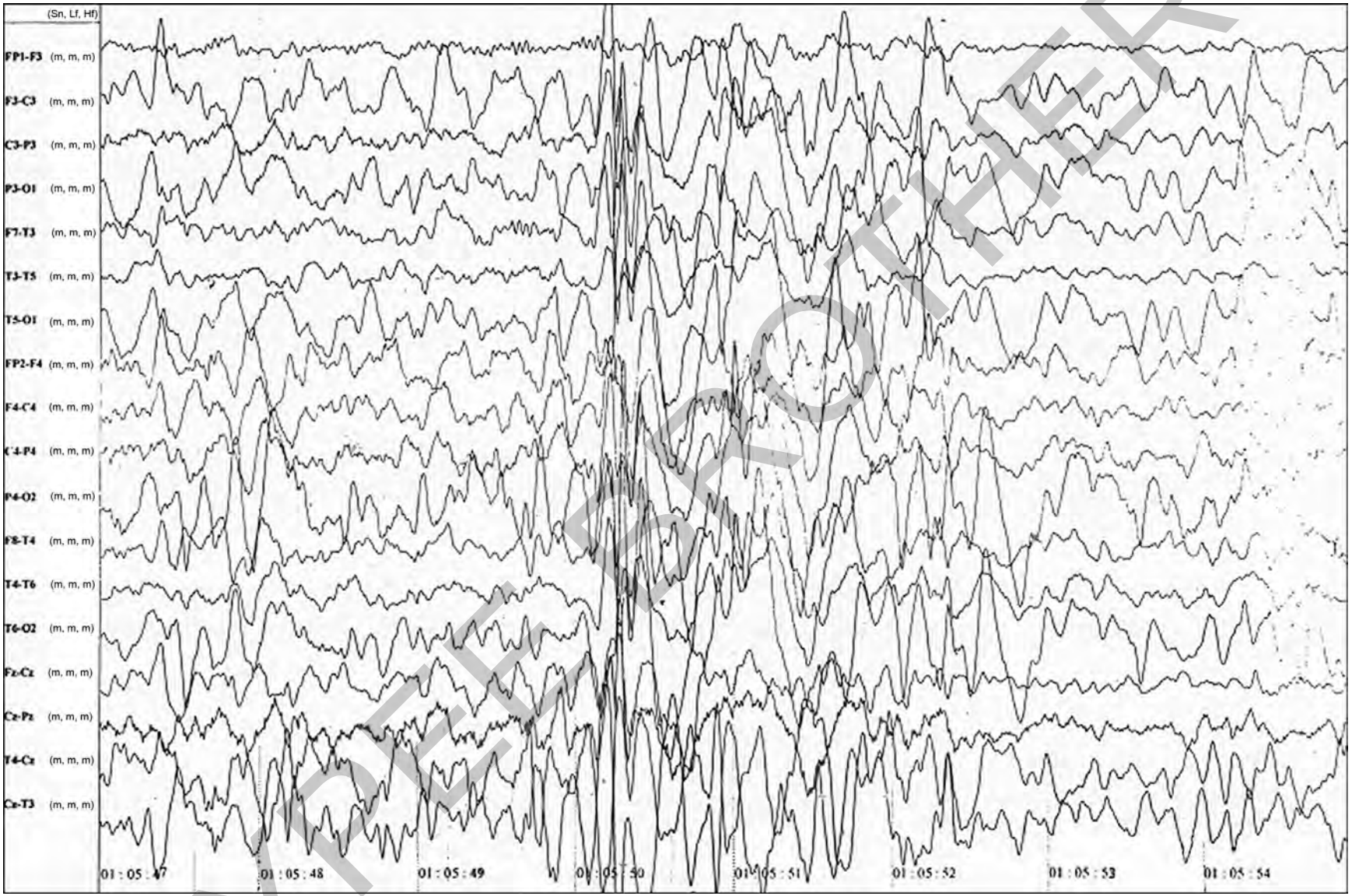

Figure 57 Sleep record, normal background activity, generalized sharp waves, sharp and slow are recorded

History of 8 years old male: (i) Unconsciousness for 3–5 minutes; (ii) Convulsion and fitting and no tongue bite; (iii) Had 4 episodes; (iv) No family history; (v) Patient is on phenobarb BD

JAYPEE BROTHERS

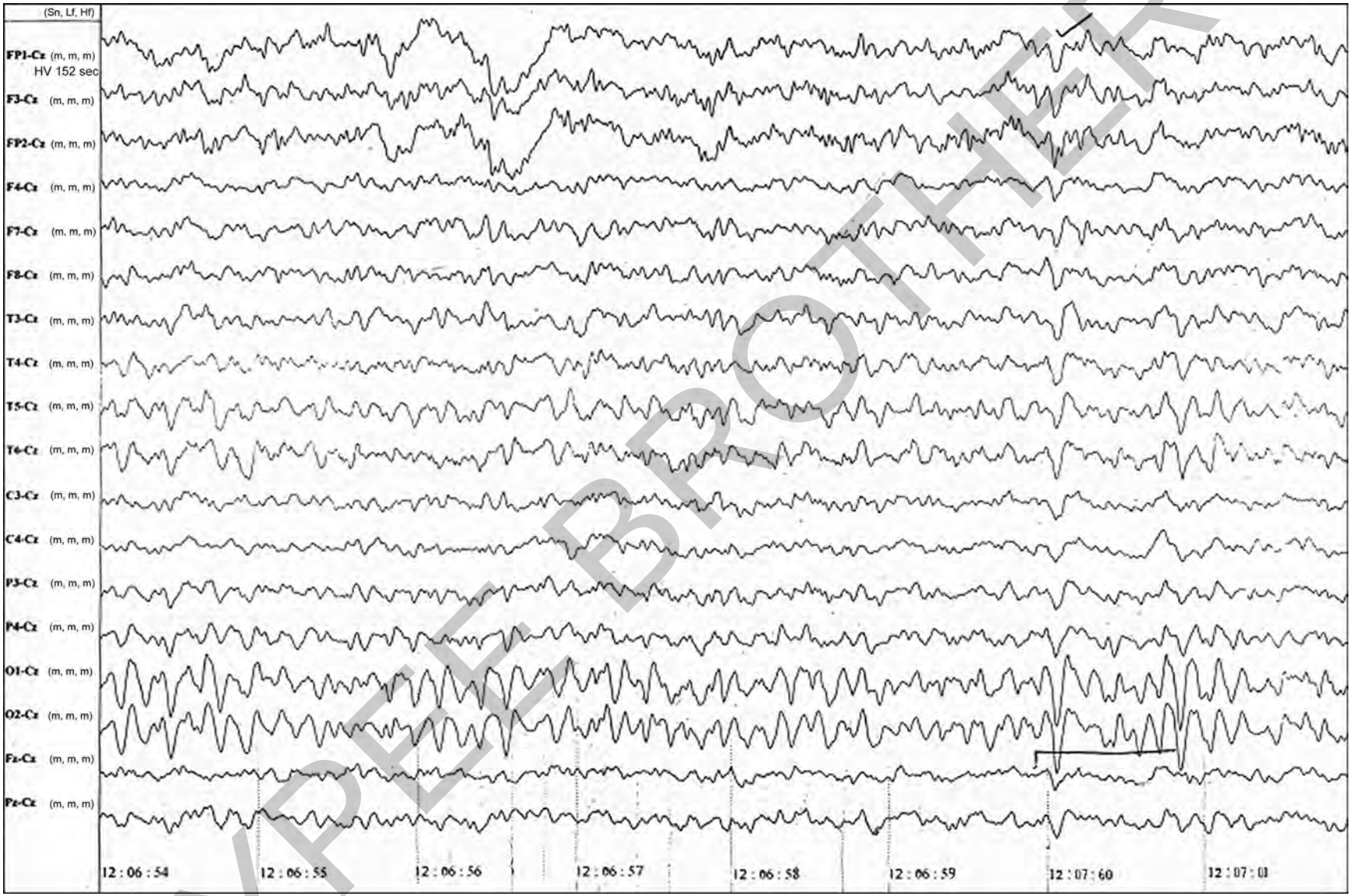

Figure 58 Alpha is irregular, theta and occasional sharp waves are seen bilaterally, borderline abnormal record

History of patient: (i) Known case of epilepsy–20 years; (ii) Patient is on phenobarbitone (30 mg) 1 tablet daily; (iii) Valparin (500 mg) 1 tablet BD

JAYPEE BROTHERS

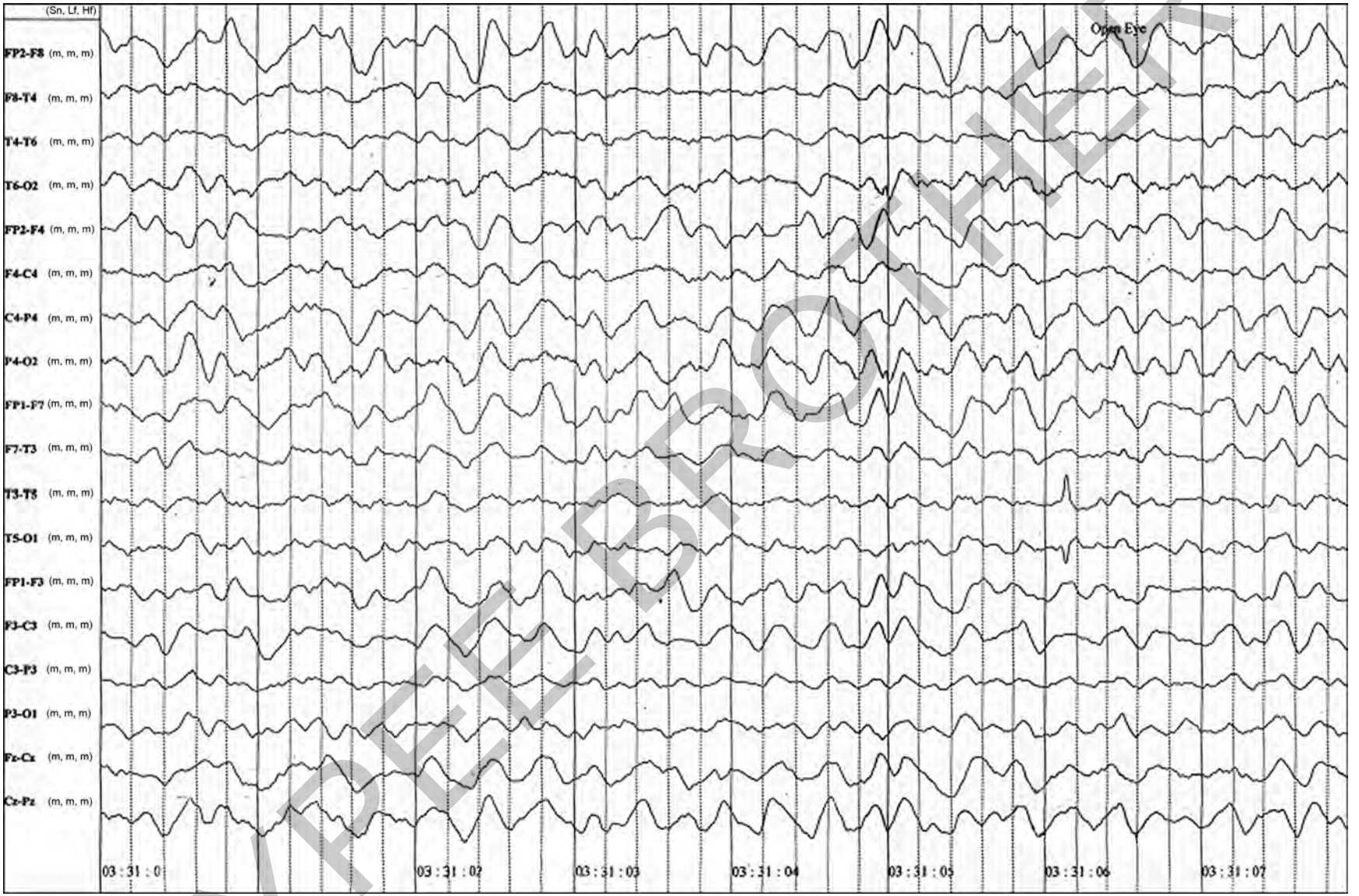

Figure 59 Alpha is absent from bilaterally, postictal slow activity

History of 35 years old male: (i) Known case of epilepsy; (ii) Had many attacks–8 years; (iii) Last attack yesterday night–12 hours earlier

JAYPEE BROTHERS

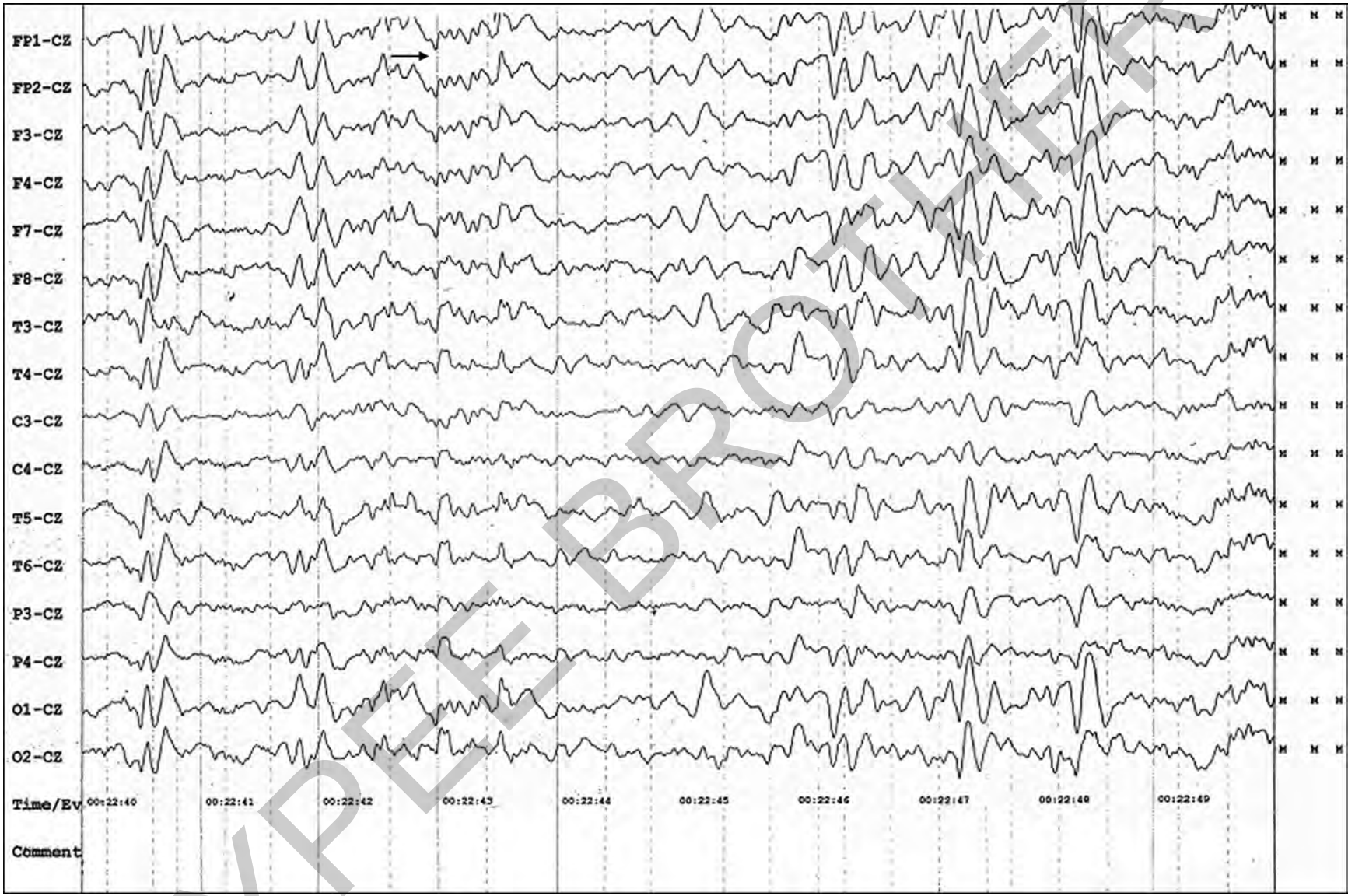

Figure 60 Epileptic disorder

History of 20 years old female: (i) Generalized convulsion 2 years; (ii) No medications yet; (iii) Had 3–4 attacks, sleep attack; (iv) No family history; (v) Taking eptoin (100 mg) 1 tablet 2 times daily

JAYPEE BROTHERS

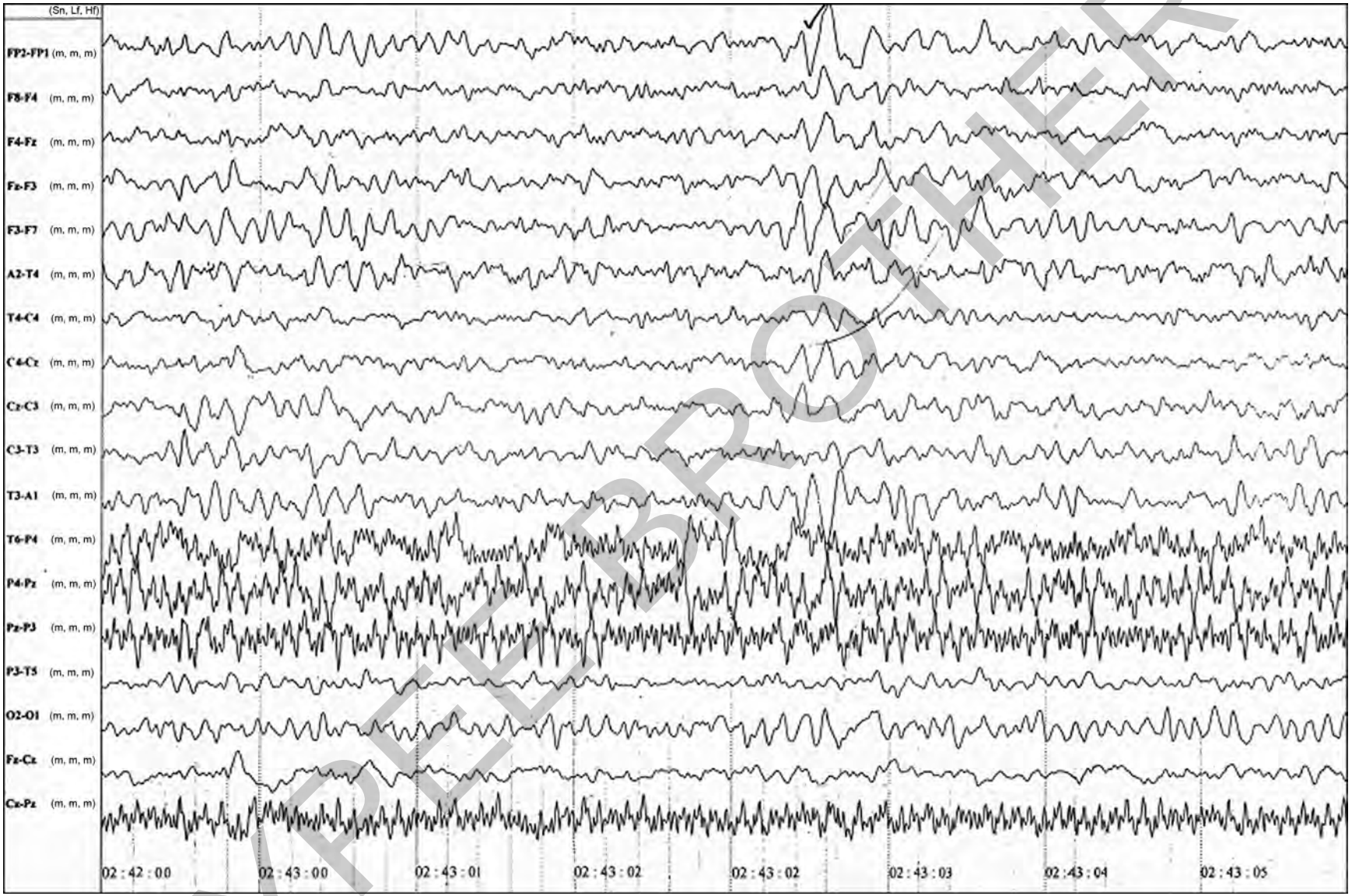

Figure 61 Late onset epilepsy

History of 62 years old male: (i) Having headache 2 months; (ii) Attack of unconsciousness for 2–3 minutes; (iii) Convulsion

JAYPEE BROTHERS

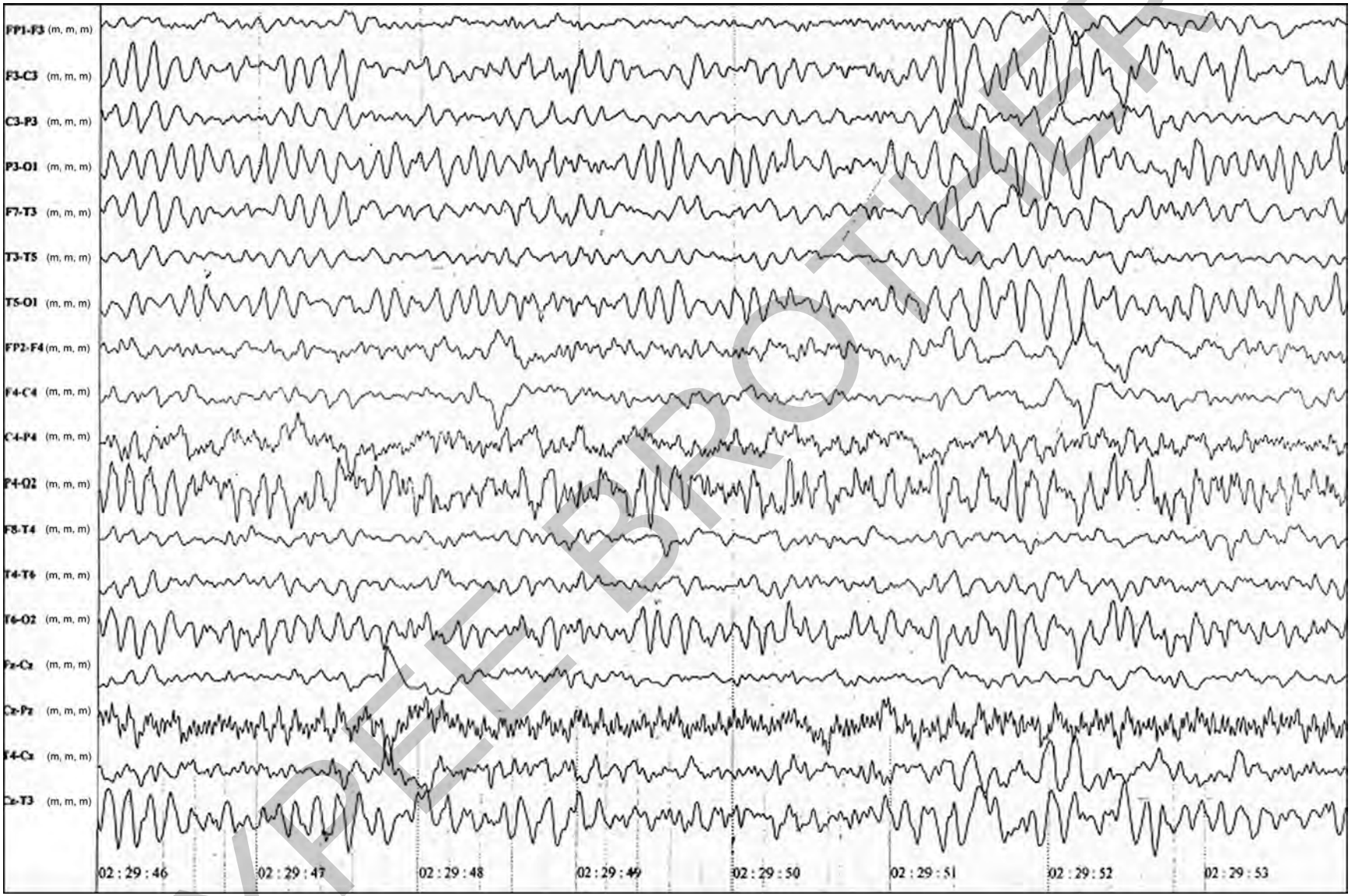

Figure 62 Generalized seziure (30 years old female), single attack

JAYPEE BROTHERS

detailed information on neurology books, visit our website **www.jaypeebrothers.com,** for detailed information on neurology books, visit our website **www.jaypeebrothers.com,** for detailed information on neurology books, visit our webs

Neuroscience EEG Atlas

Salient Features

- Covers normal, abnormal and epileptiform electroencephalogram (EEG) patterns as well as seizure patterns of special significance
- Sharpens the interpretation skills with an even larger array of both normal and abnormal EEG pattern figures and text designed to optimize recognition of tell-tale findings
- Includes hundreds of EEG figures, which help to spot abnormalities and identify the pattern
- Excellent as a quick reference, orients the basics of EEG, helps to identify the characteristic EEG wave features and leads to the EEG diagnosis through a table that organizes all of the EEG patterns according to their wave features.

Amitabh Nundy BSc EEGT (Cal) is the Incharge, Department of Neurophysiology, Ruxmaniben Deepchand Gardi Medical College, Ujjain, Madhya Pradesh, India.



Available at all medical bookstores
or buy online at www.jaypeebrothers.com

JAYPEE BROTHERS
Medical Publishers (P) Ltd.
www.jaypeebrothers.com

Join us on facebook.com/JaypeeMedicalPublishers

Shelving
Recommendation
NEUROLOGY

ISBN 978-93-5250-020-8