website **www.jaypeebrothers.com,** for detailed information on dental books, visit our website **www.jaypeebrothers.com**

Mucocutaneous Lesions in DENTISTRY

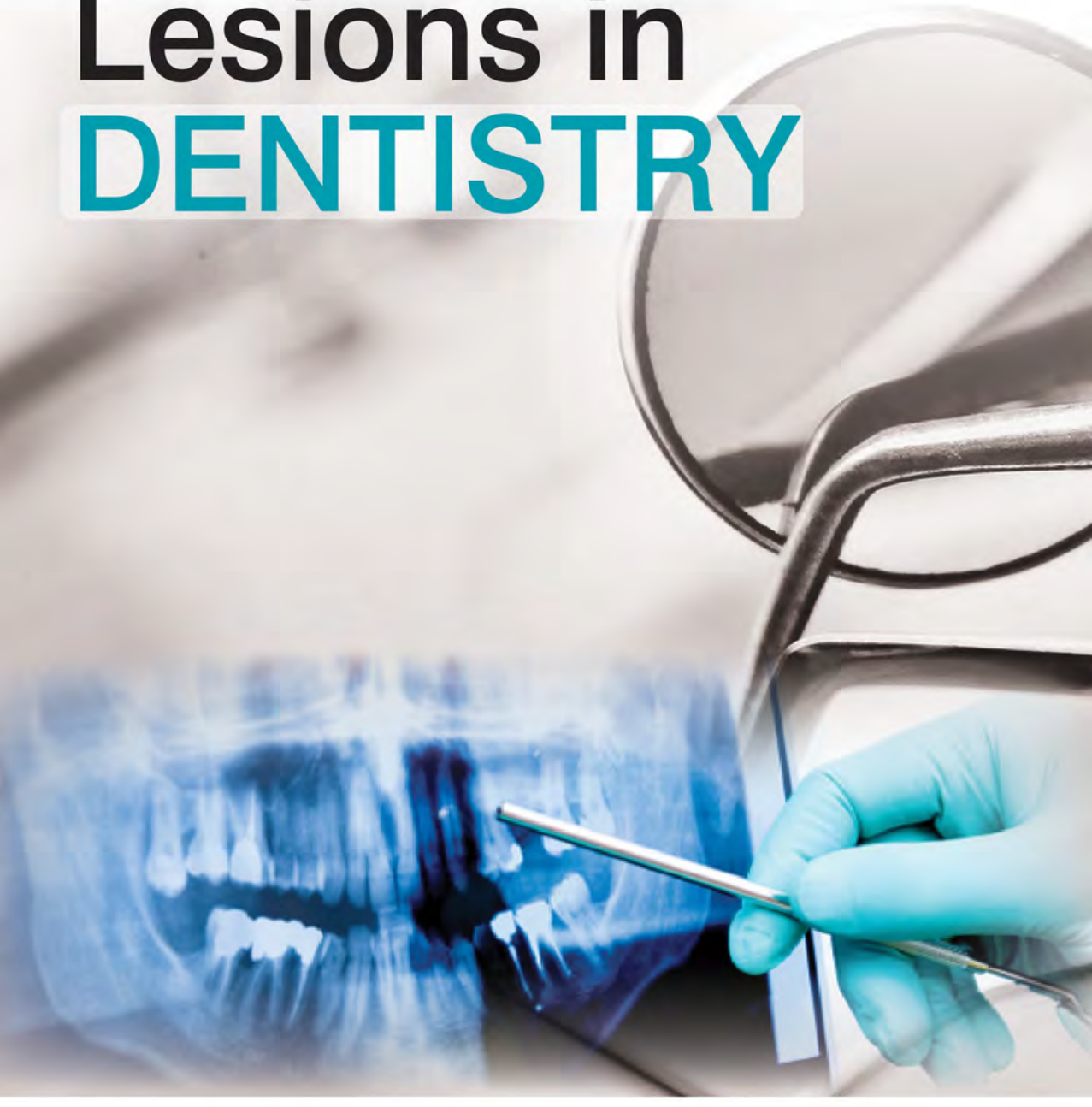

Vijay Kumar Biradar

Forewords
Manohar Bhatt
Vela D Desai

JAYPEE

Contents

Chapter 1: Introduction and Classification **1–8**
- Dermatologic lesions 1
- Primary lesions 2
- Secondary skin lesions 4
- Vascular lesions 6
- Classification of skin diseases 7

Chapter 2: Hereditary Ectodermal Dysplasia **9–15**
- Pathogenesis 9
- Classification 11
- Clinical features 12
- Oral manifestations 13
- Histopathologic features 14
- Diagnosis 14
- Differential diagnosis 15
- Treatment 15
- Prognosis 15

Chapter 3: Hypersensitivity Reactions **16–23**

Chapter 4: Oral Lichen Planus **24–32**
- Etiology and pathogenesis 24
- Clinical features 25
- Oral manifestations 27
- Classification 28
- Differential diagnosis 30
- Management 30

Chapter 5: Systemic Sclerosis **33–38**
- Pathogenesis 33
- Clinical features 34
- Classification 34
- Oral manifestations 36
- Histologic features 37
- Diagnosis 38
- Treatment 38

Chapter 6: CREST Syndrome (Acrosclerosis) **39–41**
- Clinical features 39
- Diagnosis 40
- Histologic features 41
- Treatment and prognosis 41

Chapter 7: Psoriasis **42–44**
- Etiopathogenesis 42
- Clinical features 42
- Oral manifestations 43

JAYPEE BROTHERS

- Histologic features 43
- Differential diagnosis 44
- Treatment 44
- Prognosis 44

Chapter 8: Pemphigus **45–54**
- Epithelial biology 45
- Pemphigus and variants 46
- Pemphigus vulgaris 48
- Possible etiologic factors 50
- Clinical features 51
- Histologic features 51
- Treatment and prognosis 53

Chapter 9: Paraneoplastic Pemphigus **55–58**
- Clinical features 56
- Pathogenesis 57
- Diagnostic criteria 57
- Treatment 58

Chapter 10: Pemphigoid and Other Basement Membrane Diseases **59–68**
- Classification of pemphigoid group of diseases 60
- Epithelial biology 60
- Mucous membrane pemphigoid 62
- Direct immunofluorescence (DIF) 65

Chapter 11: Erythema Multiforme **69–82**
- Toxic epidermal necrolysis (Lyell's syndrome) 80
- Drug-related erythema multiforme 81
- Drug-related toxic epidermal necrolysis 82

Chapter 12: Lupus Erythematosus **83–94**
- Pathogenesis 83
- Clinical features 84
- Mucocutaneous disease 86
- Histopathology 92

Chapter 13: Epidermolysis Bullosa **95–101**
- Pathogenesis 95
- Epidermolysis bullosa simplex 97
- Junctional epidermolysis bullosa 98
- Epidermolysis bullosa dystrophic, dominant 98
- Epidermolysis bullosa dystrophic, recessive 99

Chapter 14: Darier's Disease **102–108**
- Pathogenesis 102
- Clinical features 104
- Diagnosis 106
- Treatment 107

JAYPEE BROTHERS

Chapter 15: Dyskeratosis Congenita **109–113**
- Pathogenesis 109
- Clinical features 109
- Oral manifestations 110
- Histologic findings 112
- Treatment 113

Chapter 16: White Sponge Nevus **114–118**
- Pathogenesis 114
- Clinical features and oral manifestations 115
- Histologic features 116
- Treatment 117

Chapter 17: Warty Dyskeratosis **119–120**
- Clinical features 119
- Histologic features 119
- Treatment and prognosis 119

Chapter 18: Cowden Syndrome **121–126**
- Pathogenesis 121
- Clinical features 121
- Differential diagnosis 126
- Treatment 126

Chapter 19: Peutz-Jeghers Syndrome **127–130**
- Pathogenesis 127
- Clinical features 128
- Diagnosis 129
- Differential diagnosis 129
- Treatment and prognosis 130

Chapter 20: Hereditary Benign Intraepithelial Dyskeratosis **131–133**
- Clinical presentation 131
- Treatment 133

Index *135–136*

JAYPEE BROTHERS

CHAPTER
4

Oral Lichen Planus

INTRODUCTION[1]

Oral lichen planus (OLP) is a chronic inflammatory disorder affecting stratified squamous epithelia. The disease is relatively common, affecting approximately 1–2% of the population, an incidence equal to well-known diseases such as psoriasis and Barrett's esophagus.

Whereas in the majority of instances, cutaneous lesions of lichen planus (LP) are self-limiting and cause itching, oral lesions in OLP are chronic, rarely undergo spontaneous remission, are potentially premalignant and are often a source of morbidity. Furthermore, oral lesions, unlike cutaneous lesions, are difficult to palliate (Figs 4.1 and 4.2).

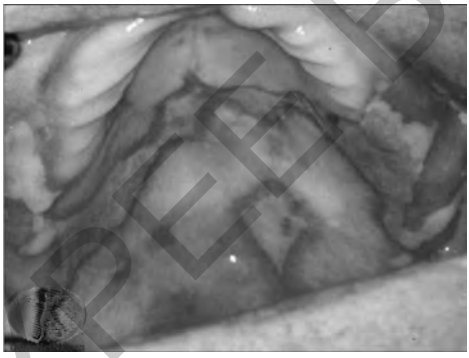

Fig. 4.1: OLP due to drug reaction



Fig. 4.2: OLP reaction to amalgam

ETIOLOGY AND PATHOGENESIS[3]

The cause of LP is not known but immunologic mechanisms triggered by poorly defined antigenic stimulations plays a pivotal role in the pathogenesis of the disease. Cell-mediated immune response is believed to play the major role in the pathology of the disease. Presence of activated antigen presenting cells (Langerhans cells, dendritic macrophages) in the lesional skin could be demonstrated in the early stage of the disease.

JAYPEE BROTHERS

$CD4^+$ cells initiates immune response in which activated keratinocytes also take part. $CD8^+$ T lymphocytes mediate the damage to the epidermis and leads to the characteristic lichenoid tissue reaction.

There is evidence of the role of HLA-associated genetic susceptibility in the causation of the disease.

There are cases of lichen planus-type rashes (known as lichenoid reactions) occurring as allergic reactions to medications for high blood pressure, heart disease and arthritis. These lichenoid reactions are referred to as *lichenoid mucositis* (*of the mucosa*) or *dermatitis* (*of the skin*).

Contact allergens in dental restorative materials or toothpastes (contact hypersensitivity reactions).

Mechanical trauma (*Koebner phenomenon*) (Fig. 4.3).

Lichen planus has been reported as a complication of chronic *hepatitis C virus* infection and can be a sign of *chronic graft-versus-host disease* of the skin (Fig. 4.4).

It has been suggested that true lichen planus may respond to stress, where lesions may present on the mucosa or skin during times of stress in those with the disease.



Fig. 4.3: Koebner phenomenon



Fig. 4.4: Graft-verses-host disease

CLINICAL FEATURES[1]

OLP develops most commonly in the 5th to 6th decades of life, and in women more than twice as often as in men, patients of all ages may develop the disorder.

Extraoral Manifestations

Patients with OLP frequently have concomitant disease in one or more extraoral sites. Therefore, a thorough evaluation and multidisciplinary approach is required to uncover potential sites of extraoral involvement.

Approximately 15% of patients with OLP develop cutaneous lesions. The classic appearance of skin lesions consists of erythematous to violaceous papules that are flat-topped and occasionally polygonal in form (Fig. 4.5). A network of fine lines (Wickham striae) often overlies many of

JAYPEE BROTHERS

the papules. Cutaneous LP may also appear in several atypical forms that are not easily recognizable.

Typically, cutaneous lesions develop within several months after the appearance of the oral lesions, and the severity of the oral lesions does not seem to correlate with the extent of cutaneous involvement.

Undoubtedly, the most frequent extraoral site of involvement in female patients with OLP is the genital mucosa with lesions developing in 20% of women with OLP. The association of LP of the vulva, vagina and gingiva is recognized as the vulvovaginal-gingival syndrome. When LP affects the genital mucosa, the erosive form of the disease is the predominant type (Fig. 4.6) although asymptomatic reticular lesions can be identified in a quarter of all patients. Various symptoms including burning, pain, vaginal discharge, and dyspareunia are frequent and are noted in patients with erythematous and erosive disease. Not uncommonly, patients with mild oral involvement display severe erosive vulvovaginal disease, and patients afflicted with severe oral involvement develop only mild asymptomatic genital disease. Reports of malignant transformation of genital lichen planus in women underscore the need for an early diagnosis and the institution of prompt treatment for these patients.

The penogingival syndrome represents the male equivalent of the vulvovaginal-gingival syndrome of LP. Although the concomitant involvement of oral and genital LP is much less common in males than females, recognition and treatment of the disease are important as malignant transformation of penile LP has been reported.

Lichen planopilaris represents LP involvement of the scalp and hair follicles causing a scarring alopecia. Lichen planus may also involve the nails producing thinning and ridging of the nail plate and splitting of the distal free edge of the nail. Healing with a scar produces a pterygium, an uncommon but characteristic LP nail manifestation. Lichen planus of the nails and scalp are uncommon in patients with OLP.

The clinical features of esophageal LP have been well documented, and the disease appears to develop most commonly in patients with OLP.



Fig. 4.5: Cutaneous LP: Violaceous papules that are flat-topped and polygonal in form covered with a network of fine lines (Wickham striae)



Fig. 4.6: Vulvovaginal LP: The characteristic lesion is a tender, painful, erythematous atrophic or eroded introitus of the vulvovaginal area

JAYPEE BROTHERS

The overwhelming majority of patients with esophageal LP are diagnosed as a result of painful symptoms, with dysphagia being the predominant complaint. Although malignant transformation has not been reported, untreated esophageal LP may result in chronic pain and strictures. Patients with OLP may also develop the disease in one or more sites including the ocular, bladder, nasal, laryngeal, otic, gastric, and anal structures although these sites of involvement are uncommon.

ORAL MANIFESTATIONS[1]

Oral lichen planus lesions usually have recognizable and distinctive clinical features and a characteristic distribution. OLP may manifest in one of three clinical forms: Reticular, erythematous (atrophic) and erosive (ulcerated, bullous). Whereas reticular lesions occur as isolated lesions and are often the only clinical manifestation of the disease, erythematous lesions are accompanied by reticular lesions, and erosive lesions are accompanied by reticular and erythematous lesions in almost all cases. This feature helps clinically differentiate OLP from other vesiculo-erosive diseases such as pemphigus and pemphigoid, which are characterized by isolated areas of erythema and/or erosions.

The **reticular lesions**, the most recognized form of OLP, encompass white lesions, which appear as a network of connecting and overlapping lines (Wickham striae), papules or plaques (Fig. 4.7). Although some patients may display an impressive array of diffuse and widespread reticulated lesions, they rarely complain of symptoms and often, are unaware of their presence.

Erythematous (Fig. 4.8) **and erosive** (Fig. 4.9) OLP lesions result in varying degrees of discomfort. The number of ulcerations is variable as are their size and location; rarely, bulla that ruptures easily may be observed in the erosive form of OLP. The erosive lesions hardly ever remit spontaneously and may lead to confusion with other autoimmune mucosal, vesiculoerosive diseases, which share similar clinical features.

The posterior buccal mucosa is the most frequent site of involvement followed by the tongue, gingiva, labial mucosa, and vermilion of

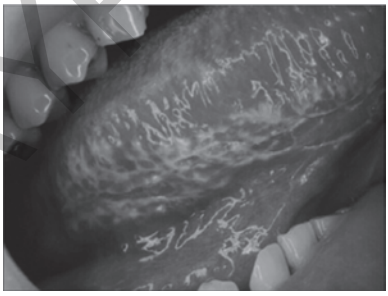

Fig. 4.7: Reticular lesions may be papular, plaque-like, and lacy and are the most recognized form of OLP



Fig. 4.8: Erythematous OLP lesions, when present, are almost always accompanied by reticulated lesions

JAYPEE BROTHERS

the lower lip. Lesions on the palate, floor of the mouth, and upper lip are uncommonly noted.

Approximately 10% of patients with OLP have the disease confined to the gingiva. Gingival LP presenting as small, raised white, lacy papules or plaques, may resemble keratotic diseases such as leukoplakia. Erythematous lesions affecting the gingiva result in desquamative gingivitis (Fig. 4.10), the most common type of gingival LP. Erosive lesions resembling those observed in other vesiculoerosive diseases including pemphigoid, pemphigus, linear IgA disease, and foreign body gingivitis also produce desquamative gingivitis not easily identified as lichen planus unless there are coexistent reticular lesions on the gingiva or elsewhere in the oral cavity.

Lichen planus isolated to a single oral site other than the gingiva is uncommon. Patients with isolated lip lesions and tongue lesions have been described although many patients who present with isolated lesions eventually develop more widespread disease.

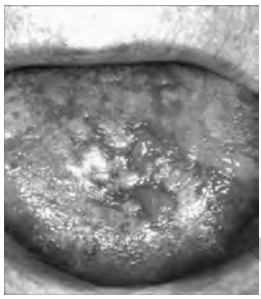

Fig. 4.9: The most severe and painful lesions of OLP develop in the erosive form of the disease



Fig. 4.10: OLP confined to the gingiva, typically with atrophic and erosive lesions resulting in desquamative gingivitis

CLASSIFICATION

Andreason in 1968 divided OLP into 6 clinical forms:
Atrophic (erythematous)
Reticular
Erosive (ulcerated)
Bullous
Papular and Plaque-like.

The bullous form: It presents as fluid-filled vesicles which project from the surface.

The hypertrophic form: It may also appear on the oral mucosa, generally appearing as a well-circumscribed, elevated white lesion resembling leukoplakia (Fig. 4.11).

Atrophic (erythematous): It appears clinically as smooth, red, poorly defined areas; often but not always with the peripheral striae evident. It usually occurs on the gingiva (Fig. 4.12).

JAYPEE BROTHERS

Papular and Plaque-like: It confluents white patches similar to oral keratosis; usually seen in smokers (Fig. 4.13).

Histologic Features:[2] Basal epidermal keratinocyte damage and lichenoid-interface lymphocytic reaction are the two major pathological findings. There are presence of hyperkeratosis, increased granular layer, irregular acanthosis, liquefactive degeneration of the basal cell layer and band-like lymphocytic infiltrate in the upper dermis. In mucosal lichen planus, plasma cells are more prominent. Degenerated keratinocytes (colloid, Civatte bodies) are present at the dermal-epidermal junction (Fig. 4.14, Table 4.1).

Direct immunofluorescence shows heavy deposits of fibrin at the dermo-epidermal junction. Deposits of IgM and less frequently IgG, IgA and C3 are also found in the colloid bodies (Fig. 4.15).



Fig. 4.11: Hypertropic OLP

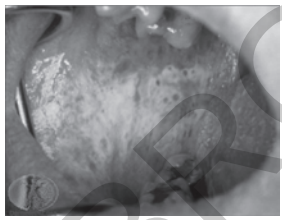

Fig. 4.12: Atrophic OLP

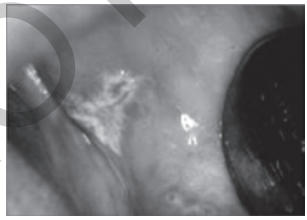

Fig. 4.13: Plaque-like OLP



Fig. 4.14: Hyperkeratosis, saw toothed rete ridges, and a band-like infiltrate of lymphocytes subjacent to the epithelium

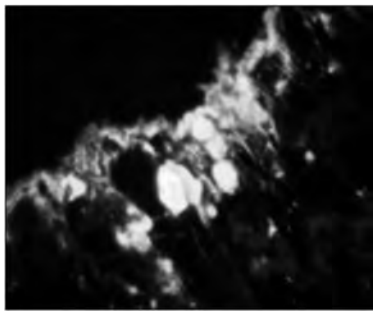

Fig. 4.15: Direct immunofluorescence shows heavy deposits of fibrin at the dermoepidermal junction

JAYPEE BROTHERS

Table 4.1: Histopathologic and immunofluorescent features OLP

Histology (Eisenberg, 2000)
- Essential features
  - Superficial band-like infiltrate of T lymphocytes
  - Basal cell liquefaction degeneration
  - Normal epithelial maturation pattern
- Additional features
  - Jagged, spindly rete ridges
  - Civatte bodies
  - Separation of epithelium from lamina propria

Immunofluorescence of perilesional mucosa (Helander and Rogers, 1994)

Fibrin and shaggy fibrinogen in a linear pattern at the basement membrane zone

Cytoids in the absence of deposition of fibrinogen.

Lichen planus may also affect the genital mucosa—vulvovaginal-gingival lichen planus. It can resemble other skin conditions such as atopic dermatitis and psoriasis.

Rarely, lichen planus shows esophageal involvement, where it can present with erosive esophagitis and stricturing. It has also been hypothesized that it is a precursor to squamous cell carcinoma of the esophagus.

DIFFERENTIAL DIAGNOSIS[2]

The clinical differential diagnosis include lichenoid drug reactions, lichenoid reactions associated with contact hypersensitivity to restorative materials, leukoplakia, lupus erythematosus, and graft-versus-host disease (GVHD). Direct immunofluorescence can aid in distinguishing OLP from other lesions specially from vesiculobullous lesions such as pemphigus vulgaris, benign mucous membrane pemphigoid, and linear IgA bullous dermatosis.

MANAGEMENT[2] (FLOWCHART 4.1)

In general, nonerosive oral lichen planus is asymptomatic and treatment is often unnecessary. However, patients with erosive type oral lichen planus often present with significant management problems. At present, none of the available treatment is specific or universally effective. An algorithm for the management of oral lichen planus is shown. All patients should optimize their oral hygiene. Oral candidiasis should be excluded or treated accordingly. In symptomatic patients with apparent contact dental factor, patch test with replacement of the amalgam or gold restorative material is suggested in those who are sensitized to these metals. In those with no apparent contact factor, topical or intralesional steroid is usually the first line treatment. A short course of systemic steroid may be necessary for more rapid control. In steroid-

JAYPEE BROTHERS

dependent patients, azathioprine or topical cyclosporine can be added as an adjunctive therapy. In refractory cases, alternative therapies such as topical or systemic retinoids, antimalarial, dapsone, oral PUVA, thalidomide or topical tacrolimus may be considered. Surgical treatments such as laser, cryotherapy and excision may exacerbate the conditions due to the Koebner phenomenon.

Note: *Oral lichen planus presenting as atrophic, erosive or bullous clinical types are usually symptomatic and refractory to treatments. In patients with oral lichenoid lesions, drug eruption due to oral medications or dental contact factor should be eliminated.*

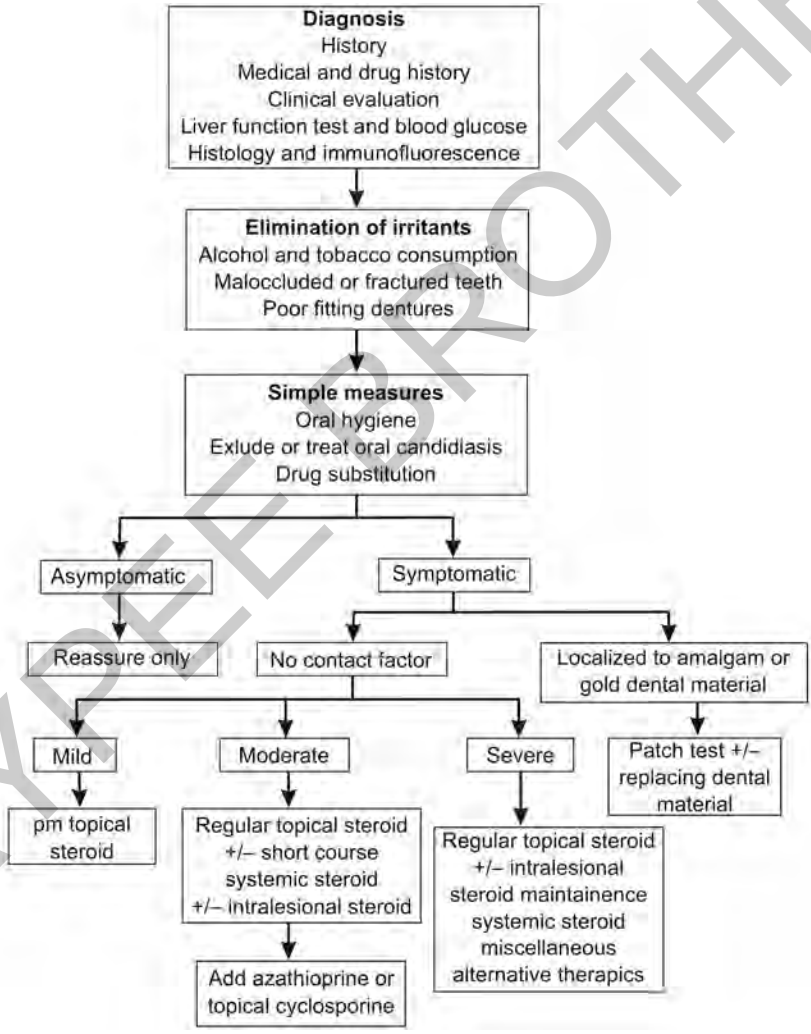

Flowchart 4.1: Management of lichen planus

JAYPEE BROTHERS

REFERENCES

1. Eisen D, Carrozzo M, Bagan Sebastian JV, Thongprasom K. Oral lichen planus: Clinical features and management. Mucosal Diseases Series, Oral Diseases 2005;11(5):338–49.
2. Cheng SY. Oral lichen planus, Hong Kong Dermatology & Venereology Bulletin. 13 March, 2002.

JAYPEE BROTHERS

for detailed information on dental books, visit our website **www.jaypeebrothers.com,** for detailed information on dental

Mucocutaneous Lesions in DENTISTRY

Mucocutaneous Lesions in Dentistry focuses on etiopathogenesis, clinical features and management of individual dermatologic diseases related to orofacial structures. Subject matter has been made clear by lucid language with schematic figures. The references provide a complete look of mucocutaneous lesions. Superb illustrations and a reader-friendly writing style help you understand both basic science and clinical applications, going beyond the facts to a deeper level of comprehension. It is the well-rounded coverage you need to succeed as a dental professional.



Vijay Kumar Biradar PhD Scholar MDS is presently Reader in Department of Oral Pathology and Microbiology, Jaipur Dental College, Maharaj Vinayak Global University, Jaipur, Rajasthan, India. He did his BDS from Bapuji Dental College and Hospital, Davangere, Karnataka, India and MDS from Government Dental College, Thiruvananthapuram, Kerala, India through All India Postgraduate Medical Entrance Examination (AIPGMEE). He is a PhD Scholar and has many international and a national publication to his credit. He has teaching experience for undergraduates and postgraduates. He has presented many scientific papers and posters in national conferences. He has gained experience in PCR (polymerase chain reaction), exfoliative cytology and immunohistochemistry at Rajiv Gandhi Center for Biotechnology, Thiruvananthapuram. He is Editorial Board Member of Journal of Oral Surgery, Oral Medicine, Oral Pathology and Oral Radiology, Innovative Publishers and Journal of Medical and Dental Research, Maharaj Vinayak Global University. He is Organizing Secretary of National Conference of IAOMP, 2015. His main objective is to be part of an environment that promotes team effort and provides opportunity for value-based growth as well as career advancement while making a significant contribution to the organization.

Available at all medical bookstores
or buy online at www.jaypeebrothers.com

JAYPEE BROTHERS
Medical Publishers (P) Ltd.
www.jaypeebrothers.com

Join us on facebook.com/JaypeeMedicalPublishers

Shelving
Recommendation
DENTISTRY

ISBN 978-93-5250-040-6

9 789352 500406