laryngology books, visit our website **www.jaypeebrothers.com,** for detailed information on otolaryngology books

Made Easy®

ENT Practicals

Made Easy®

Sujatha S

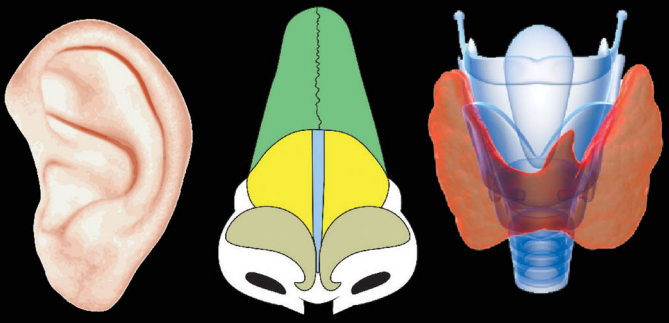

Foreword
Viswanathan N

JAYPEE

Contents

1. History Taking **1**

Presenting Complaints *2*
History of Presenting Complaints *2*
History of Past Illness *8*
Personal History *8*
Family History *8*
Menstrual History in Females *9*
Treatment History *9*

2. ENT Examination **10**

Examination of Ear *11*
Examination of Nose *23*
Examination of Oral Cavity and Oropharynx *26*

3. X-rays in ENT **30**

X-ray Mastoid *30*
Some X-rays of Mastoid Lateral Oblique View (Law's View) *32*
Nose and Paranasal Sinuses *35*
Nasopharynx *42*
X-ray Neck *44*

4. Instruments in ENT **50**

Instruments in Ear *50*
Instruments for Nose *56*

Instruments for Adenotonsillectomy *65*
Tracheostomy Tubes *71*
Rigid Endoscopes *75*

5. Operative Surgery in ENT **85**
Ear *85*
Nose *97*
Tracheostomy *102*
Adenoidectomy *107*
Tonsillectomy *109*

6. Objective Structured Clinical Examination **113**
Spotters *113*
Audiograms *121*

Index *131*

CHAPTER 4

Instruments in ENT

The instruments commonly asked in viva and objective structured clinical examination (OSCE) only are discussed here.

INSTRUMENTS IN EAR

Simpson's Aural Syringe (Fig. 4.1)



Fig. 4.1 Simpson's aural syringe

Q1. What are the uses?

Ans:

- Removal of foreign body ear
- Removal of wax ear.

Q2. What are the contraindications?

Ans:

- Perforated tympanic membrane as in acute suppurative otitis media (ASOM)/chronic suppurative otitis media (CSOM)

- Hygroscopic foreign body (FB) (Vegetable FB like peanut)
- Cerebrospinal fluid (CSF) otorrhea
- Otitis externa.

Q3. What are the complications of aural syringing?
Ans:
- Canal trauma
- Tympanic membrane rupture
- Activation of latent otitis media
- Vasovagal attack
- Vertigo due to stimulation of labyrinth.

Q4. What are the precautions to be taken while syringing?
Ans:
- Water should be at body temperature (37°) to prevent stimulation of labyrinth
- Direction of water should be towards posterosuperior canal wall in order to protect tympanic membrane from force of water and also to push the FB from behind
- Tip of syringe should be blunt
- *Always do dry mopping after syringing*, so as to prevent superadded fungal infections of the canal.

Q5. How will you syringe an ear?
Ans: Patient seated in front of examiner. Kidney tray is kept below the ear and sheet put around the shoulder of the patient to avoid soiling with water. Fill the syringe with saline at body temperature and push with tip directed towards posterosuperior canal wall.

Q6. What are the causes of impaction of FB?
Ans:
- Curvature of external auditory canal (EAC) is S shaped
- Presence of Anterior tympanic recess in the canal
- Edema EAC due to instrumentation/release of toxins from FB.

Q7. Which is the narrowest part of EAC?
Ans: It is the isthmus which lies 5 mm away from tympanic membrane.

Q8. What is the capacity of syringe?
Ans: 150 mL in adult.

Hartmann's Ear Forceps (Fig. 4.2)

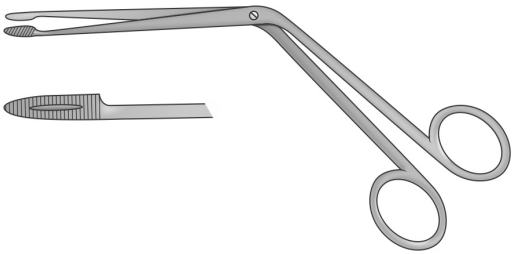

Fig. 4.2 Hartmann's ear forceps
Note the serrations inside the tip to increase the grip

Uses

1. For ear-packing
2. Removal of FB from ear.

Mollison's Self-retaining Hemostatic Mastoid Retractor (Fig. 4.3)

Q1. Enumerate the uses of this.
Ans:

- Used in surgeries to harvest temporalis fascia
- In all mastoid surgeries
- Laryngofissure surgery
- Tracheostomy

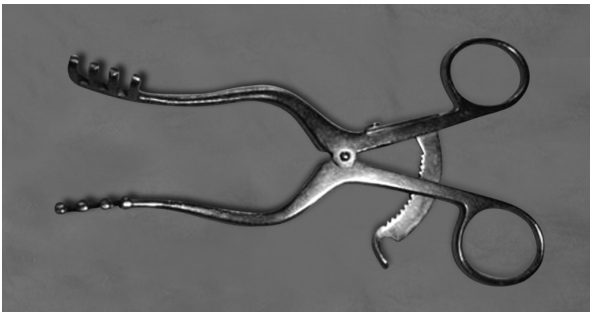

Fig. 4.3 Mollison's self-retaining mastoid retractor

- External ethmoidectomy (Lynch Howarth's)
- Frontal trephining.

Q2. What are the advantages of this instrument?
Ans:
- As it is self-retaining, no assistance is needed to hold this instrument
- Secure hemostasis by lateral pressure over the tissues.
- It retracts the tissues away from the field of surgery.

Jobson Horne's Probe and Ring Curette (Fig. 4.4)

Q1. What are the uses?
Ans: With the curette end we can remove wax, foreign body, granulation tissue, etc. Probe end is used as cotton swab carrier to clean external auditory canal and also to probe nasal masses.

Siegle's Pneumatic Speculum (Fig. 4.5)

Q1. What are the uses?
Ans:
- To get a magnified view (X 2.5) of tympanic membrane
- To assess the mobility of TM



Fig. 4.4 Jobson Horne's probe of different sizes

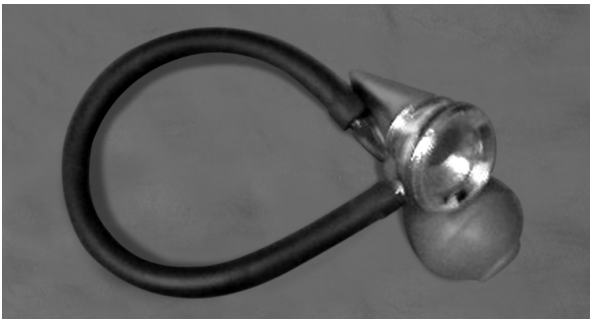

Fig. 4.5 Siegle's pneumatic speculum

- To increase and decrease the pressure of external canal in doing fistula test.
- To elicit Browne's sign in glomus tumor and in Gelle's test
- To differentiate perforation from retraction pocket.

Gardiner Brown Tuning Fork (Fig. 4.6)

Q1. Name the parts of tuning fork.

Ans: Prongs, free end, shoulder, base, stem and foot piece.

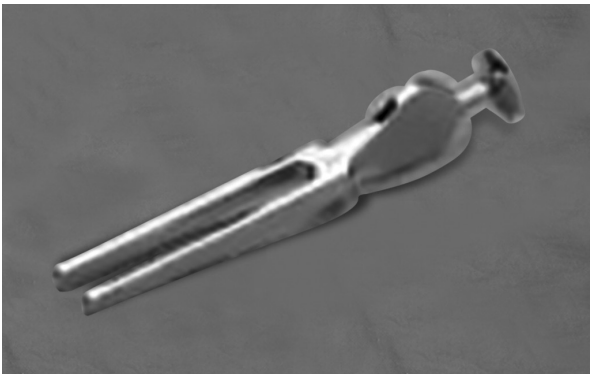

Fig. 4.6 Tuning fork

Q2. Which frequency is used commonly? Why?
Ans: Given along with ENT examination (Chapter 2).

Q3. What are the uses of tuning fork?
Ans: Used to assess the type and degree of hearing loss.

Different types of tuning fork test and methods to do, so is already discussed in examination of ear.

Jenkin's Mastoid Gouge (Figs 4.7A and B)

Used in Caldwell-Luc operation, submucous resection (SMR), mastoid surgery, etc. Nowadays, its use is limited because of high speed drill.

Gouge: Single bevel, edge is curved
Chisel: Single bevel
Osteotome: Double bevel.



Figs 4.7A and B Jenkin's mastoid gouge. Note the edge

INSTRUMENTS FOR NOSE

Thudicum's Nasal Speculum (Figs 4.8 to 4.10)



Fig. 4.8 Thudicum's nasal speculum

Pilcher's Nasal Speculum (Fig. 4.9)



Fig. 4.9 Pilcher's nasal speculum

Q1. What are the uses?
Ans: To do anterior rhinoscopy, septal surgeries, anterior nasal packing, removal of foreign body nose, antral wash out.

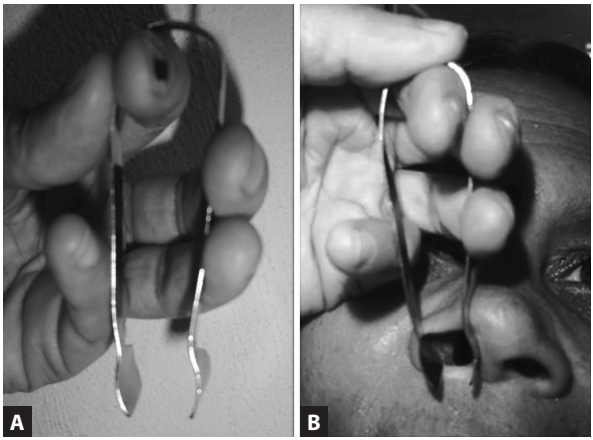

Figs 4.10A and B Thudicum's speculum held in left hand. Close blades before introduction and removal

St Clair Thompson's Long-bladed Nasal Speculum (Fig. 4.11)

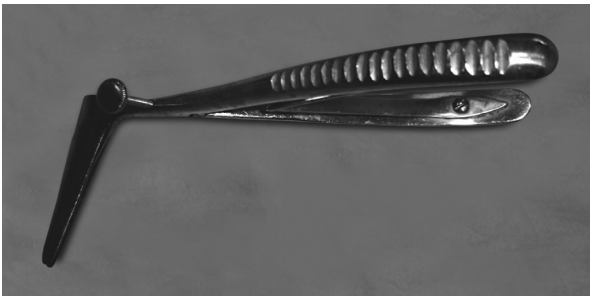

Fig. 4.11 St Clair Thompson's nasal speculum

This is used only after anesthetizing the nose as it can cause pain and discomfort to the patient. Used in surgeries of nose like septoplasty, SMR, polypectomy, etc.

Rose Eustachian Tube Catheter (Fig. 4.12)



Fig. 4.12 Eustachian tube catheter. It is 12–15 cm long metallic catheter

Q1. What are the uses?

Ans:

- Removal foreign body nose
- To know the patency of Eustachian tube (not done nowadays)
- Used as suction cannula.

Q2. Name tests of eustachian dysfunction?
Ans:
- Valsalva's maneuver
- Toynbee's maneuver
- Frenzel maneuver
- Politzerization
- Siegalization
- ET cannulation
- Radiopaque dye injected and X-ray
- Nasal endoscopy
- ET endoscopy
- Sonotubometry
- Impedence audiometry
- CT scan
- 3D CT scan
- MRI scan.

Q3. How will you do Valsalva maneuver?
Ans: Ask the patient to blow out with mouth and nostril closed and note the outward movement of tympanic membrane.

Q4. How will you do Toynbee maneuver?
Ans: Ask the patient to swallow after closing nostril and mouth. TM will move inwards.

Q5. How will you do Frenzel's maneuver?
Ans: Ask the patient to move the tongue up against the palate after closing nose and mouth. TM will move inwards. This is the ideal method to test ET function among the three.

Tilley Lichtwitz Antrum Puncture Trocar and Cannula (Fig. 4.13)

Q1. What are the uses?
Ans:
- To drain pus from maxillary sinus in case of chronic maxillary sinusitis

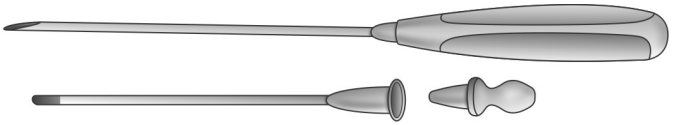

Fig. 4.13 Tilley Lichtwitz trocar and cannula

- Proof puncture in case of malignancy maxilla (this is to diagnose early malignancy by aspirating the fluid inside the sinus for malignant cells).

Q2. Name the contraindications of antral wash.

Ans:

- Acute sinusitis/rhinitis: Age below 3 years
- Bleeding disorders
- Clotting disorders.

Q3. What are the complications?

Ans:

- Puncture of orbital wall resulting in orbital injury or cellulitis (during washing ask to keep the eyes open and note any swelling/emphysema.
- Air embolism
- Bleeding
- Puncture of soft tissues resulting in swelling cheek.

Q4. How will you do antral wash?

Procedure: Patient position is semi-sitting/supine. Anesthetize inferior meatus with 4% xylocaine-dipped cotton pledgets. Hold the trocar and cannula in right hand in pen-holding fashion. Position it 1.5 cm behind the anterior end of inferior turbinate. Direction of trocar is kept towards the ipsilateral ear tragus. By screwing motion of hand, puncture the bone. A give away feel is got on puncturing the medial wall of maxillary sinus. The trocar is withdrawn and cannula-placed properly in the sinus cavity. Irrigate sinus cavity with normal saline at body temperature.

Water flows out through mouth and nose and collected in the kidney tray placed below chin.

- If sinus ostium is blocked washed out fluid will not come out of nose. In that case a second opening is made along the side of the first one.
- *Watson William's* trocar and cannula is used for sphenoid sinus washing.

Higginson's Rubber Syringe (Fig. 4.14)

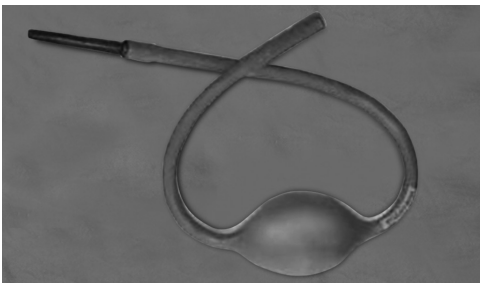

Fig. 4.14 Higginson's rubber syringe

Q1. What are the uses?

Ans: For saline nasal douche, as postoperative care after FESS, atrophic rhinitis and for antral washing after antral puncture

- Made of red rubber
- Capacity is 50 mL
- *Parts:* Bulb, rubber tubing with valve end and nozzle end
- There are *two valves* inside syringe; one at valve end and another inside the bulb.

Ballenger's Swivel Knife (Fig. 4.15) (Swivel = Swing/Like a Giant Wheel)

It is used in submucous resection (SMR) of septum. Cutting blade rotates around two bars for 360 degrees. So during surgery, it can

for detailed information on otolaryngology books, visit our website **www.jaypeebrothers.com,** for detailed inform

ENT Practicals
Made Easy®

Salient Features

- It is an excellent pocket companion for undergraduate and postgraduate medical students in ENT preparing for practicals and viva
- Covers history taking, clinical examinations, X-rays, instruments, operative surgery, audiology and objective structured clinical examination (OSCE) stations with detailed explanation
- Concise and comprehensive coverage of all topics in an easy-to-learn Question-Answer format.



Sujatha S MBBS DLO DNB MNAMS PhD is working as an Associate Professor (ENT), Government Medical College, Thiruvananthapuram, Kerala, India. She has been actively engaged in teaching and training of undergraduate and postgraduate students for the past 12 years. She has several publications to her credit and her areas of professional interest are Endoscopic Sinus Surgery and Rhinoplasty.

Available at all medical bookstores
or buy online at www.jaypeebrothers.com



JAYPEE BROTHERS
Medical Publishers (P) Ltd.
www.jaypeebrothers.com

Join us on facebook.com/JaypeeMedicalPublishers

Shelving Recommendation
OTOLARYNGOLOGY

