rothers.com, for detailed information on radiology books, visit our website www.jaypeebrothers.com, for detailed information on radiology books

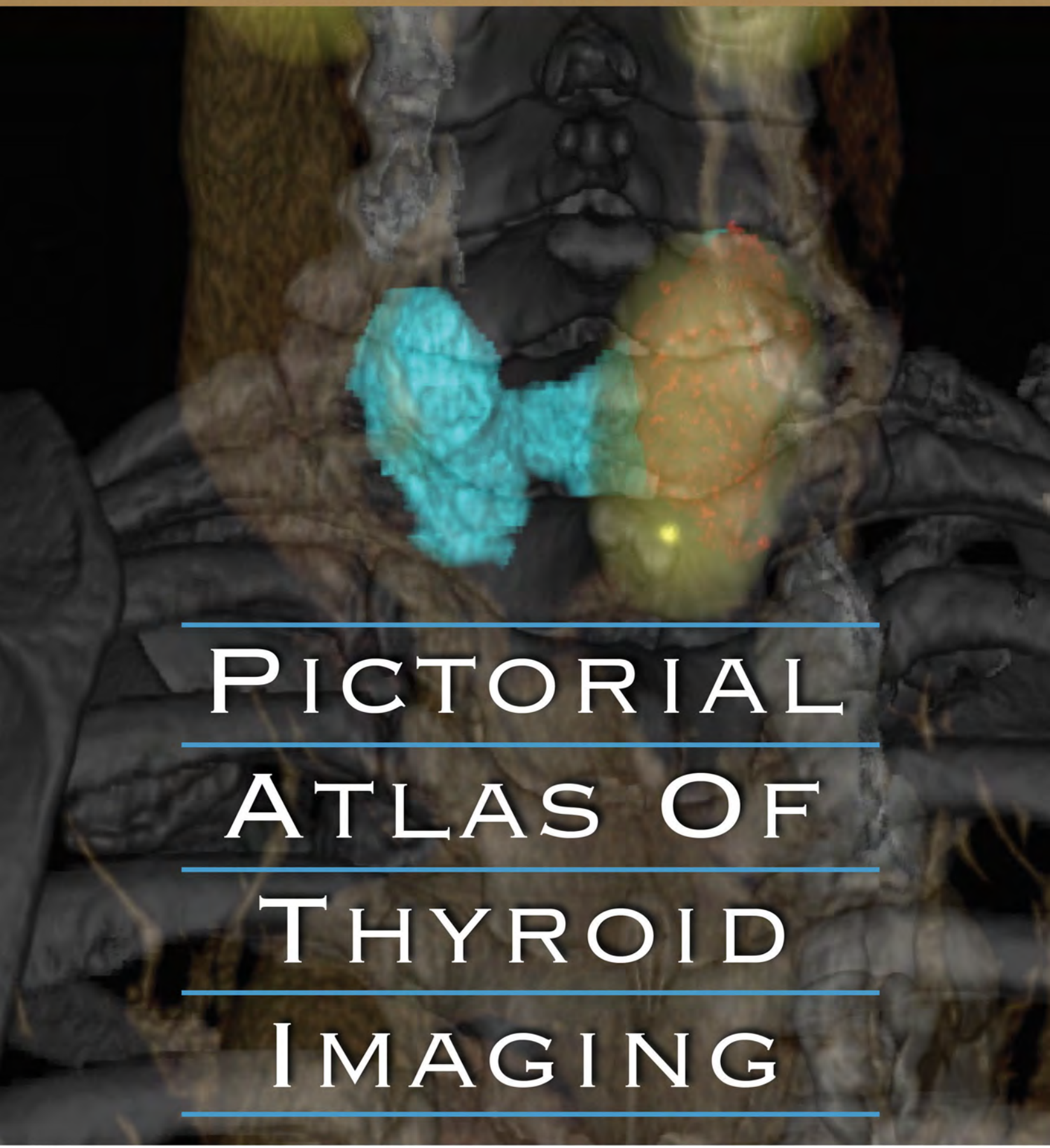

Pictorial Atlas Of Thyroid Imaging

Rajanikant Bhatt • Huda Ezzeddin Mustafa

JAYPEE

Table of Contents

1: The Thyroid Gland 2
- 1.1: Normal Thyroid 3
- 1.2: Post-Thyroidectomy Changes 11

2: Congenital Disorders Of The Thyroid 18

3: Goiter 30

4: Nodular Disease Of The Thyroid 42
- 4.1: Benign Looking Nodules 43
- 4.2: Suspicious Nodules 72
- 4.3: Lymph Nodes 114
- 4.4: Thyroid Cancer Residual / Recurrent Disease 126

5: Thyroiditis 144

6: Hyperthyroidism 160

7: Parathyroid Glands 176

8: Miscellaneous 204

Index 222
- A: Ultrasound Vascularity Grading For Thyroid Nodules 223
- B: Elastography Scoring For The Thyroid Nodules 224

Chapter 2:

Congenital Disorders Of The Thyroid

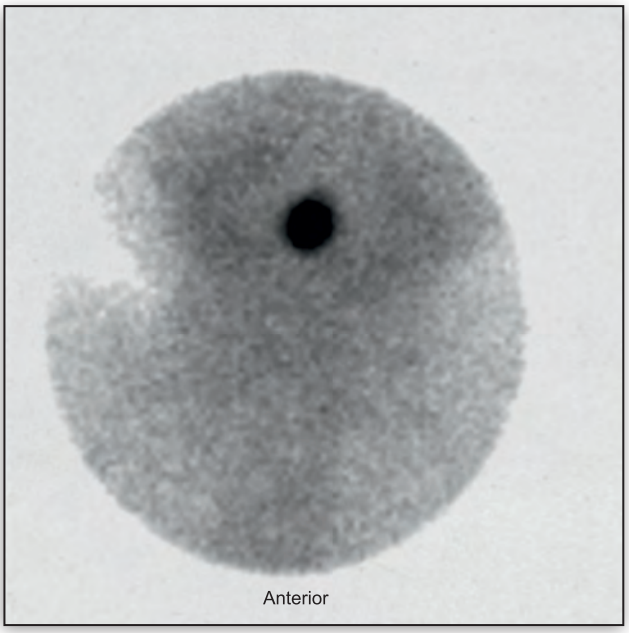

Img. 2.01 a

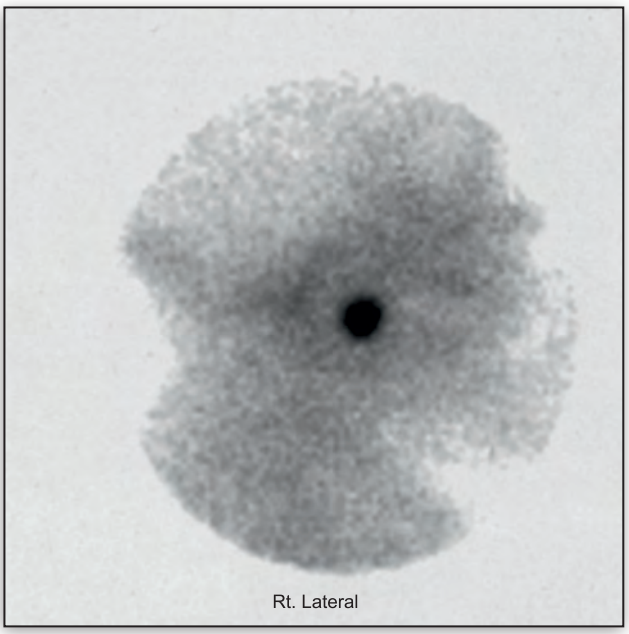

Img. 2.01 b

Img. 2.01 a/b: Anterior/Rt. Lateral US views of Sodium 99m-Tc Pertechnetate scintigraphy demonstrating an increased tracer uptake at the base of the tongue with complete absence of up take at the thyroid bed, suggestive of a ***lingual thyroid with concomitant agenesis of the thyroid gland.***

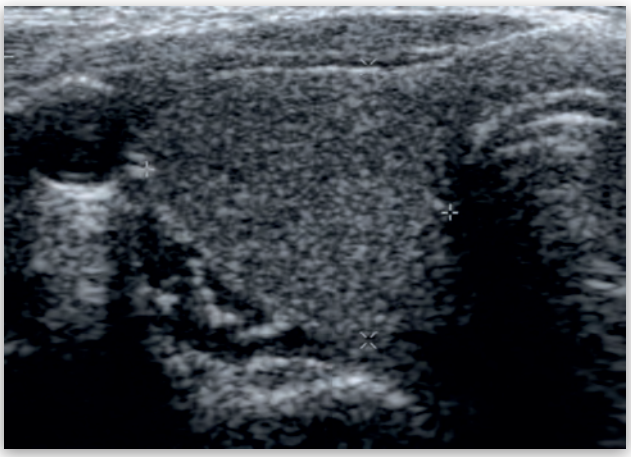

Img. 2.02 a

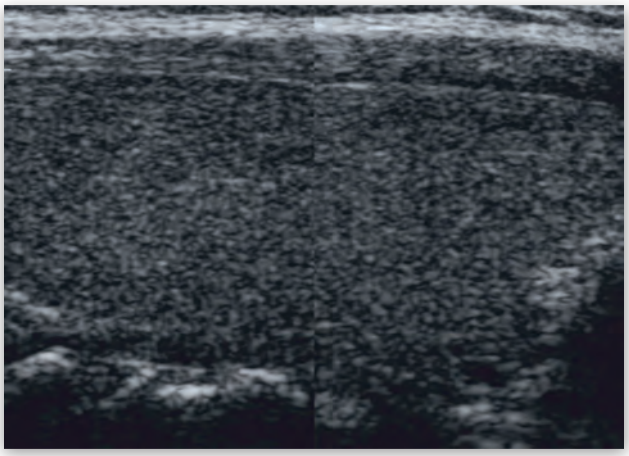

Img. 2.02 b

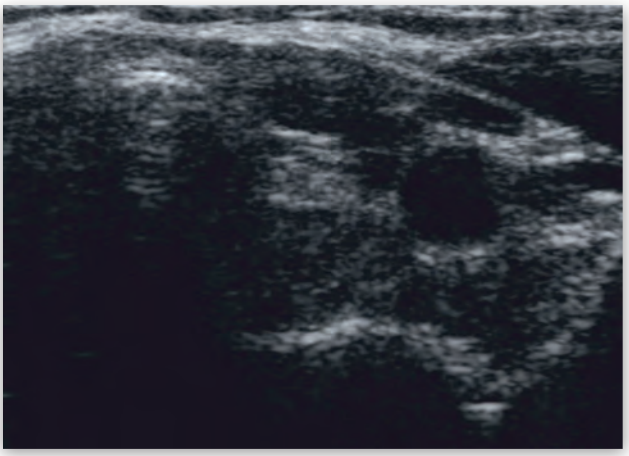

Img. 2.02 c

Img. 2.02 a/b: Transverse / Longitudinal US view of a normal Rt. Lobe of thyroid.

Img. 2.02 c: Corresponding Lt. Lobe of thyroid is absent in a non-thyroidectomised patient.

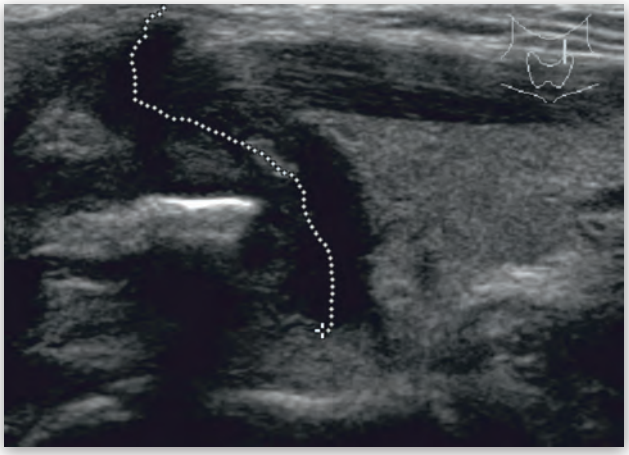

Img. 2.03 a

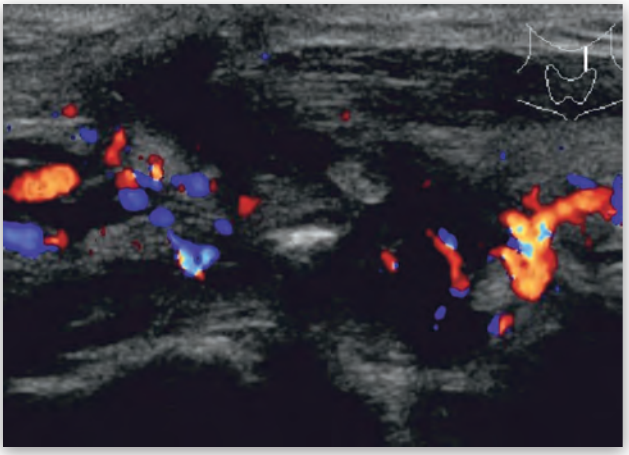

Img. 2.03 b

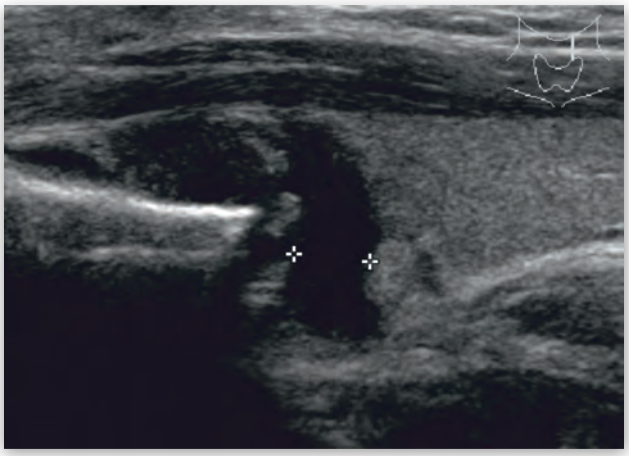

Img. 2.03 c

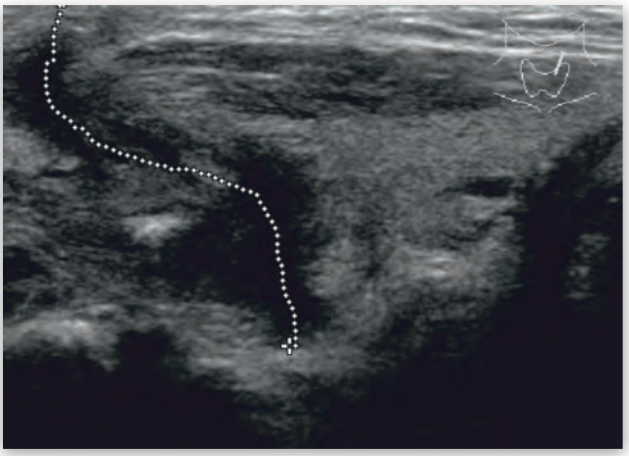

Img. 2.03 d

Img. 2.03 a/b/c/d: Longitudinal US view of the upper pole of the Lt. thyroid lobe, shows a tubular curvilinear tract-like lesion. It appears to be anteromedial to the sternohyoid muscle reaching superficially to the skin surface. The entire tract approximately measures 3 cm in length, and 0.4 cm in width. The lesion has no increased vascularity by color Doppler. The thyroid gland itself appears normal.

Finding suggests a third branchial cleft anomaly on the left side forming a fistula. The internal communication of the fistula's tract couldn't be established or defined.

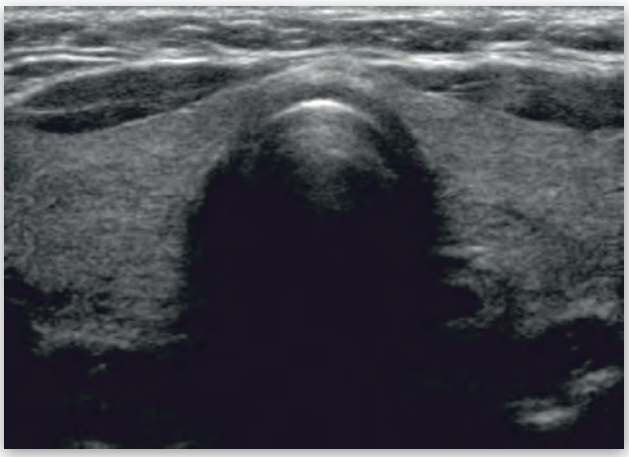

Img. 2.04 a

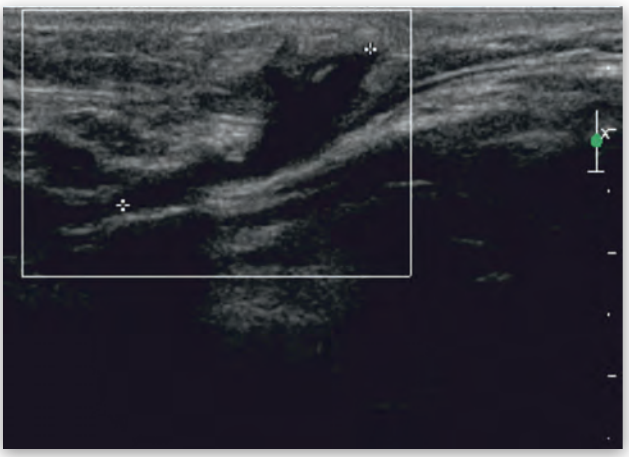

Img. 2.04 b

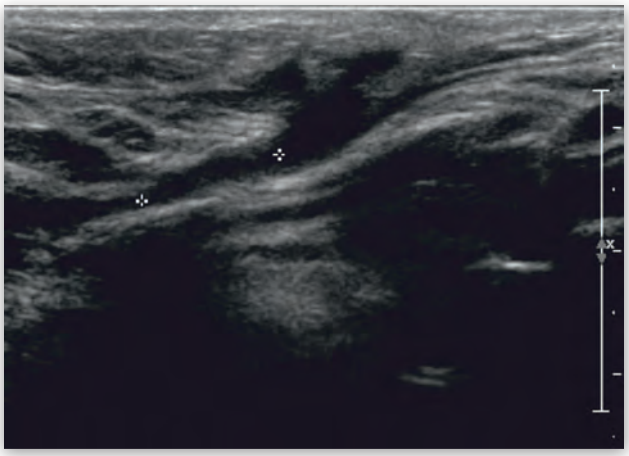

Img. 2.04 c

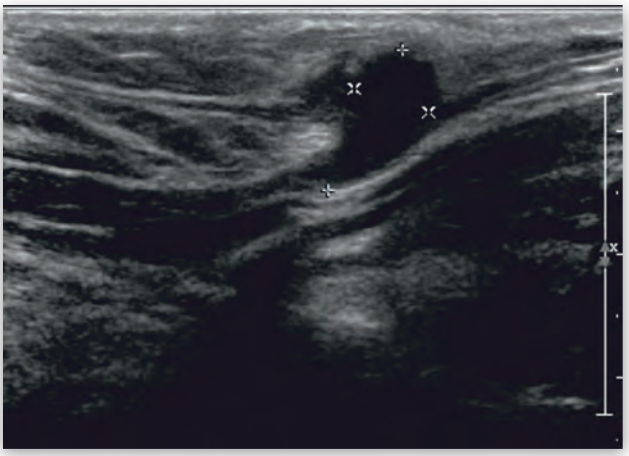

Img. 2.04 d

Img. 2.04 a: Transverse US section of the thyroid gland showing normal architecture.

Img. 2.04 b/c/d: Transverse / Longitudinal view of Lt. submandibular region showing an irregular hypoechoic/cystic swelling below the hyoid level. It has an angulated margins and depicts a linear hypoechoic track coursing deeper and medially. The cystic lesion measure 1.29 x 0.63 cm. Mild posterior acoustic enhancement is noted.

Findings are suggestive of a Lt. paramedian thyroglossal duct cyst.

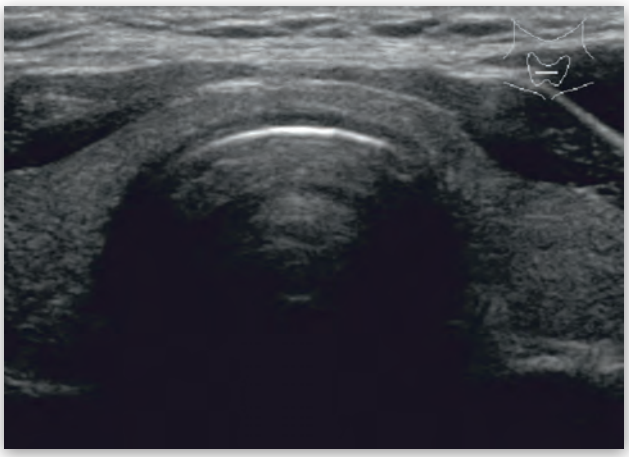

Img. 2.05 a

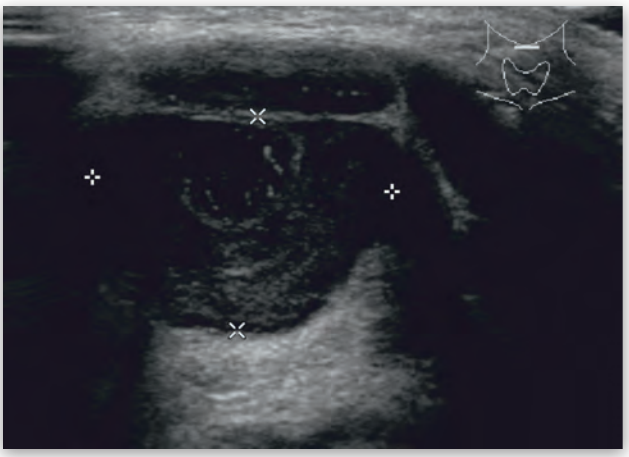

Img. 2.05 b

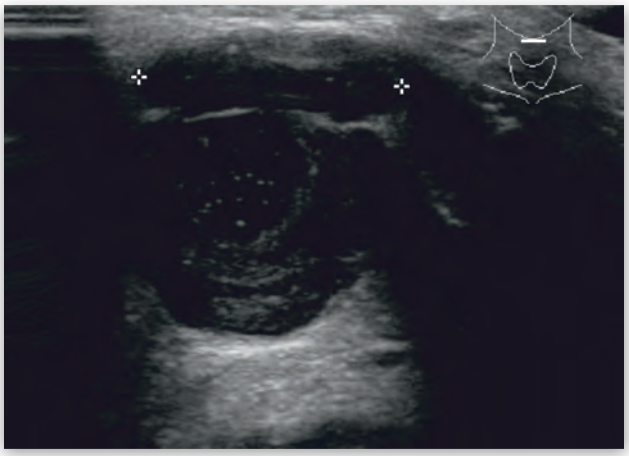

Img. 2.05 c

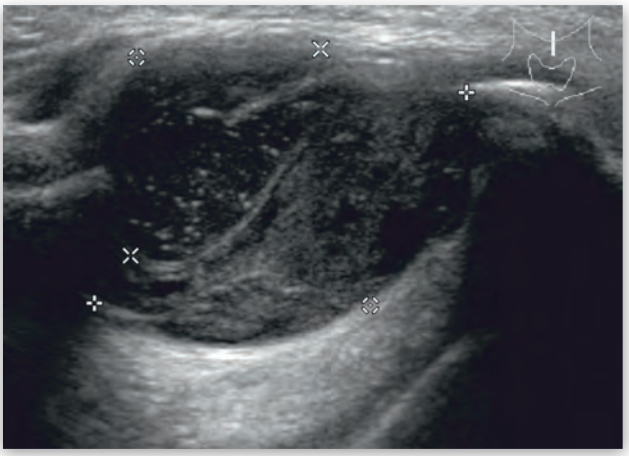

Img. 2.05 d

Img. 2.05 a: Transverse US section of the mid thyroid region showing a normal looking thyroid gland. In a young man with a painful midline swelling of the neck.

Img. 2.05 b/c: Transverse view of upper neck showing large compound cyst with superficial cystic component measuring 2.5 cm in its curved length, separated from a rather dense semisolid deeper component with echogenic particles and posterior enhancement.

Img. 2.05 d: Longitudinal view of the central upper neck cyst showing both the cystic and the heterogeneous component measuring 2.71 x 2.16 x 1.90 cm.

Findings suggest an infected thyroglossal duct cyst.

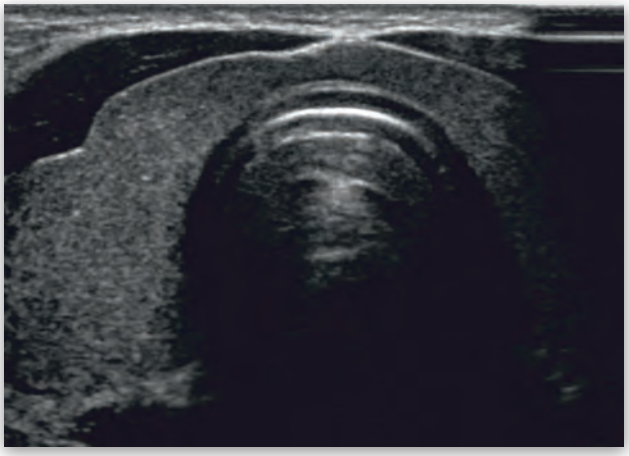

Img. 2.06 a

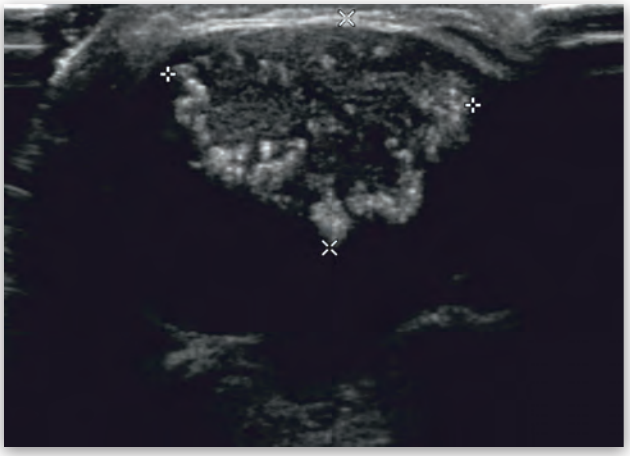

Img. 2.06 b

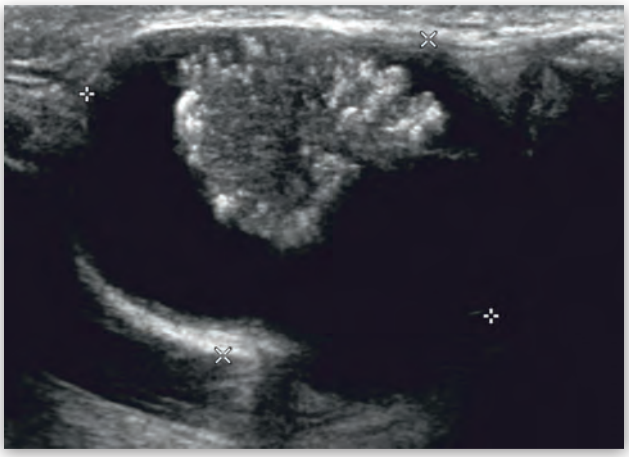

Img. 2.06 c

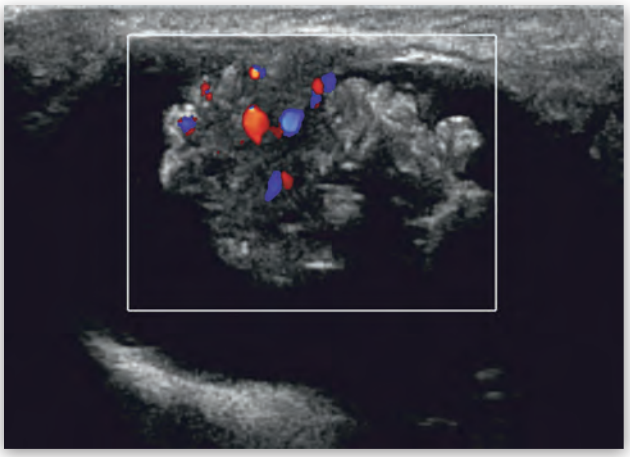

Img. 2.06 d

Img. 2.06 a: Transverse US view of a normal thyroid gland of a 21-year-old patient who presented with long-term history of anterior midline swelling of the neck.

Img. 2.06 b: Transverse US view of the midline neck swelling showing a large well defined cyst measuring 3.45 x 2.82 cm superior to the normal thyroid gland. Most likely a thyroglossal cyst.

Img. 2.06 c/d: The cyst shows a well defined irregular, lobulated solid mass measuring 2.27 x 1.7 cm arising from the anterior border of the Thyroglossal cyst. The mass shows punctate calcifications and traces of internal vascularity.

Fine Needle Aspiration biopsy of the solid component of the thyroglossal cyst was suggestive of Papillary Thyroid Carcinoma, which was confirmed after total excision of the cyst.

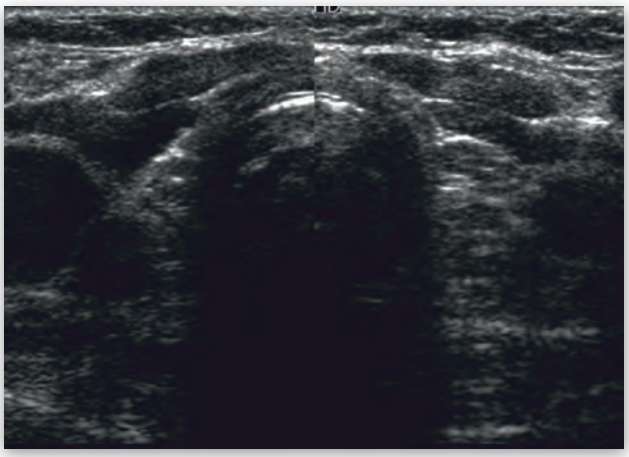

Img. 2.07 a

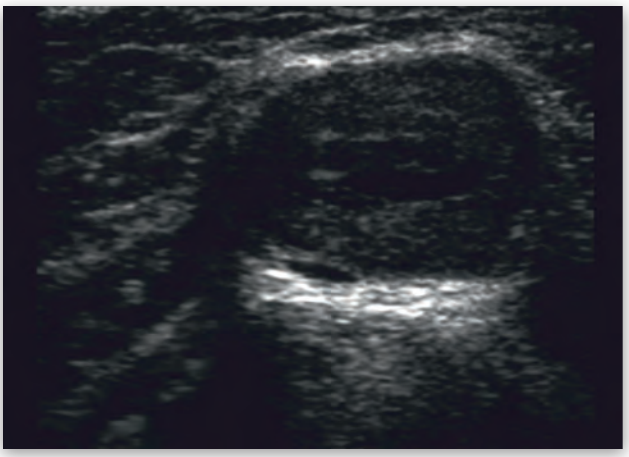

Img. 2.07 b

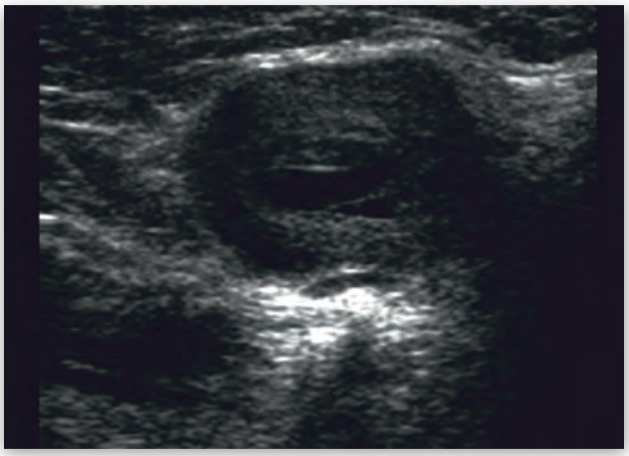

Img. 2.07 c

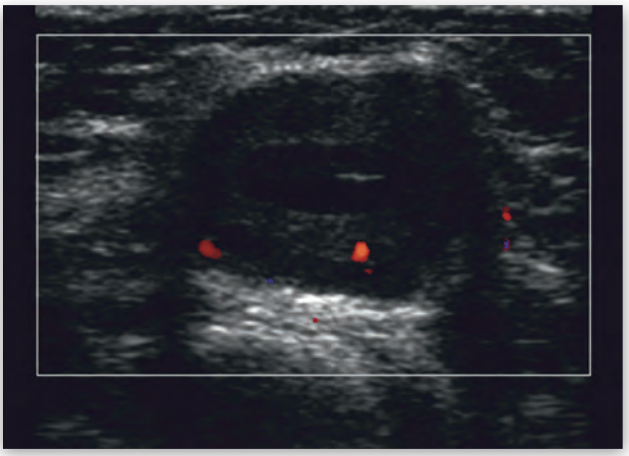

Img. 2.07 d

Img. 2.07 a: Transverse US view of the thyroid gland area showing absence of both lobes of the thyroid.

Img. 2.07 b/c: Transverse / Longitudinal view of a midline showing thick-walled cystic lesion with posterior enhancement at the level of the hyoid bone.

Img. 2.07 d: Power Doppler showing minimal vascularity in the cyst wall.



Img. 2.07 e

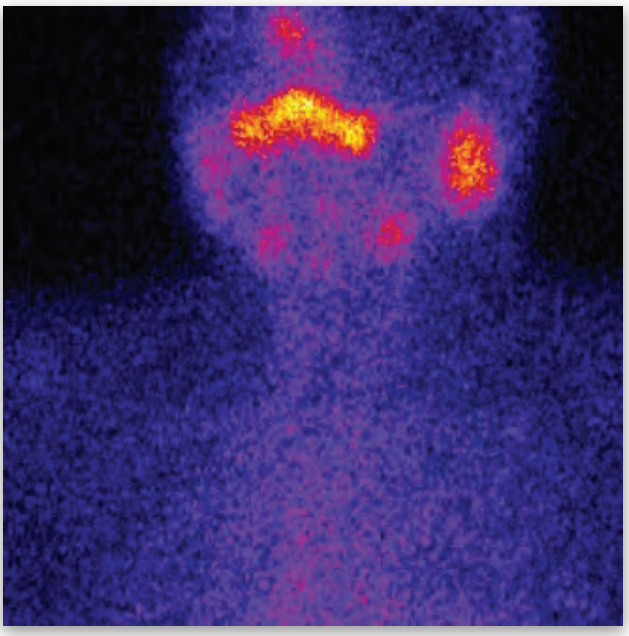

Img. 2.07 f

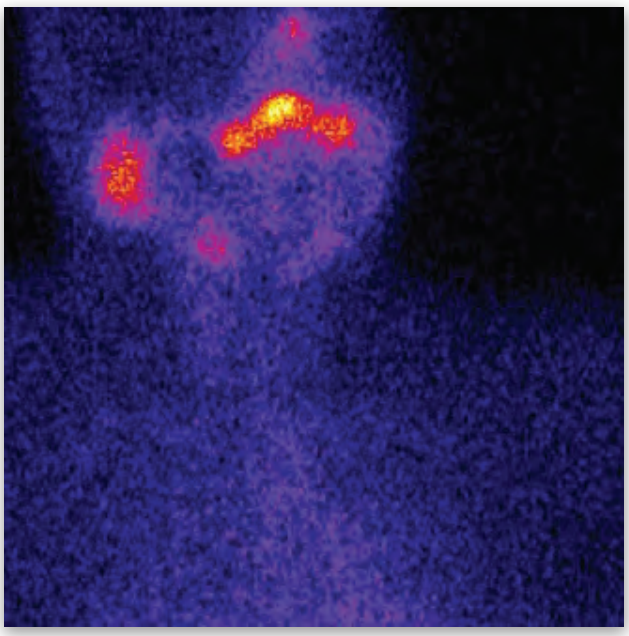

Img. 2.07 g

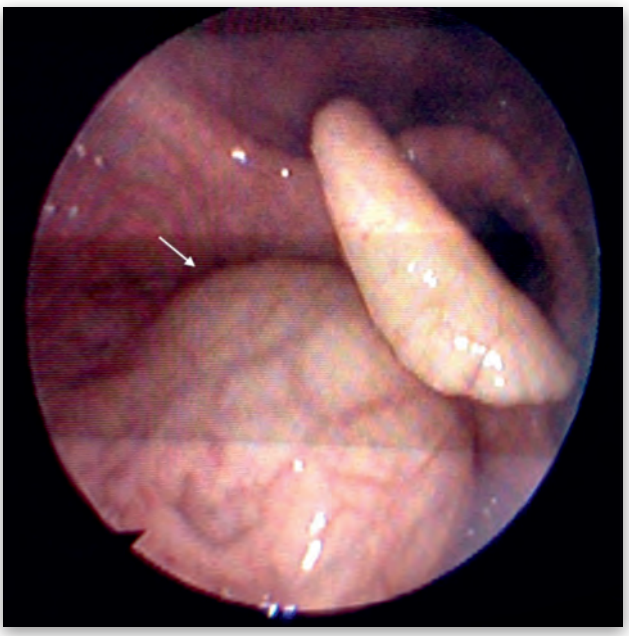

Img. 2.07 h

Img. 2.07 e/f/g: Thyroid Scintigraphy with Tc-99m Pertechnetate showing no evidence of tracer uptake in the thyroid bed area with a localized tracer uptake in the upper neck suggestive of ectopic thyroid nodule and agenesis of the thyroid gland.

Img. 2.07 h: Direct laryngoscopy shows a soft tissue swelling at the base of the tongue below the epiglottis.

A case of Lingual thyroid as well as Thyroglossal duct cyst in a patient with agenesis of the thyroid.

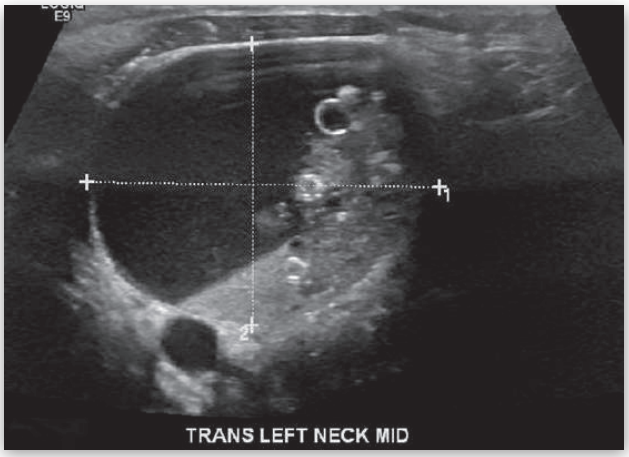

Img. 2.08 a

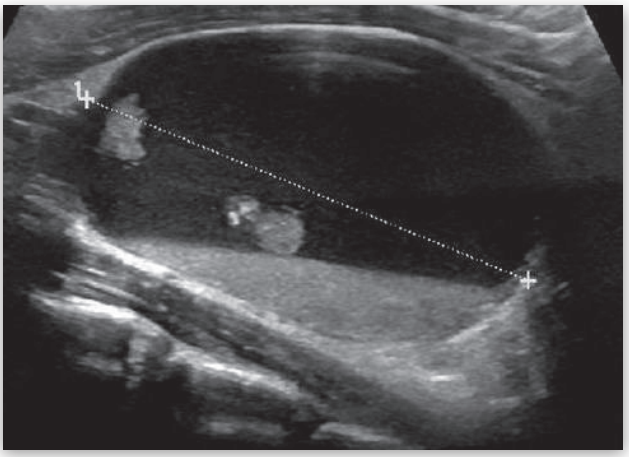

Img. 2.08 b

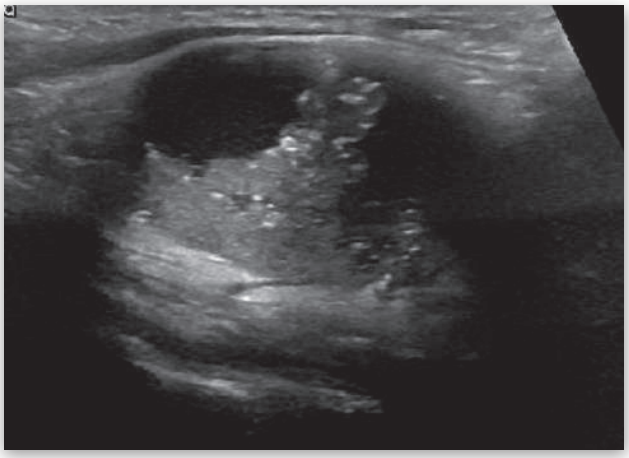

Img. 2.08 c

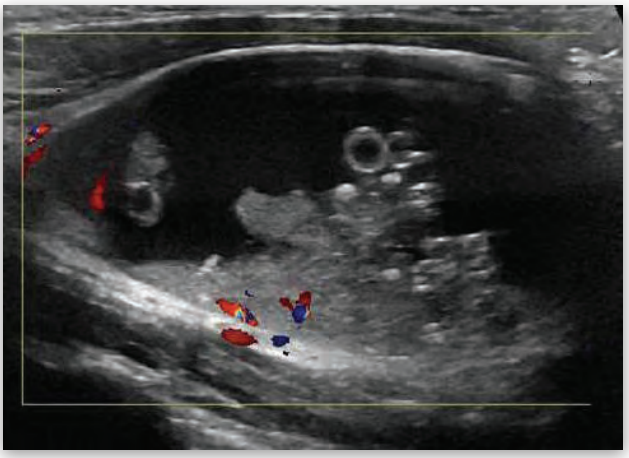

Img. 2.08 d

Img. 2.08 a/b,c: Transverse / Longitudinal US views of a long-standing, large well-defined cystic lesion in an 18-year-old gentleman, measuring 4.5 x 3.7 x 3.0 cm located in the Lt. cervical region anterior to the lt. sternocleidomastoid muscle and just lateral to the Lt. carotid artery. Note the presence of layers of dense internal echoes and multiple small rounded echogenic lesions within the cyst. The solid component contains punctate calcifications within the irregular borders.

Img. 2.08 d: Color Doppler shows minimal vascularity within the solid wall.

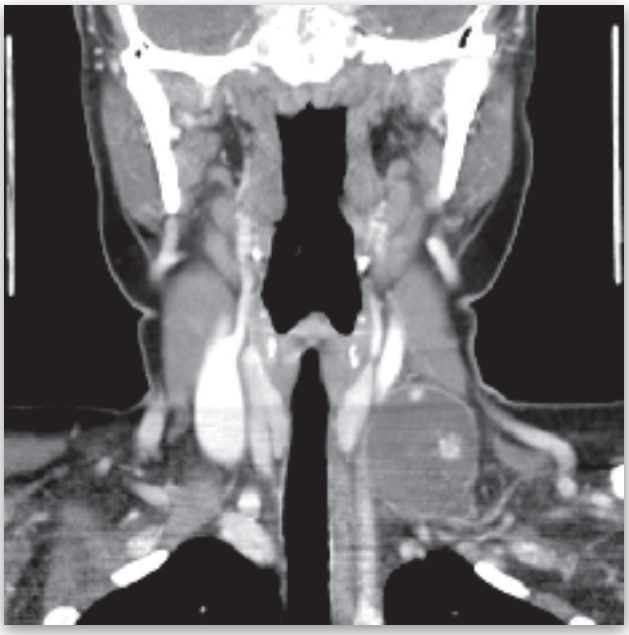

Img. 2.08 e: Coronal CT

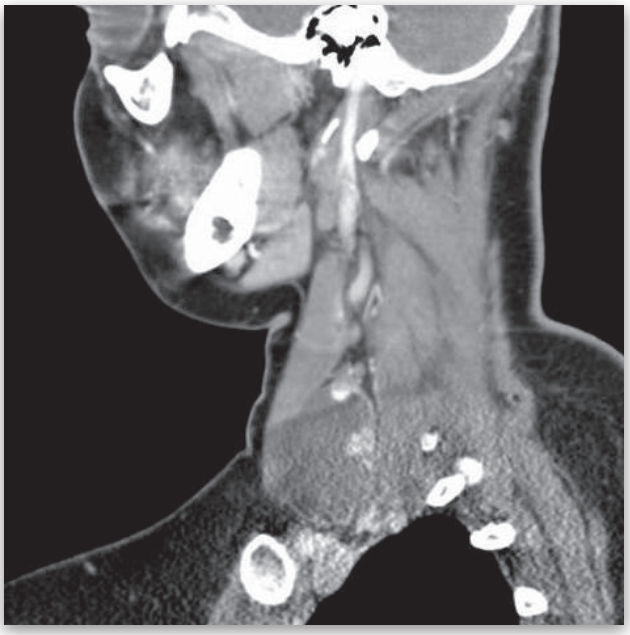

Img. 2.08 f: Sagittal CT

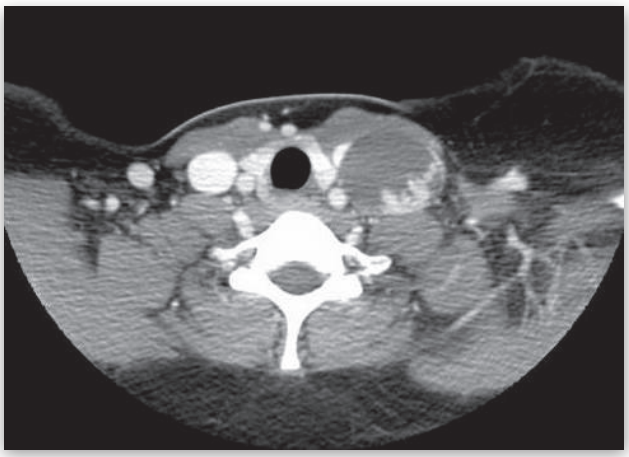

Img. 2.08 g: Axial CT

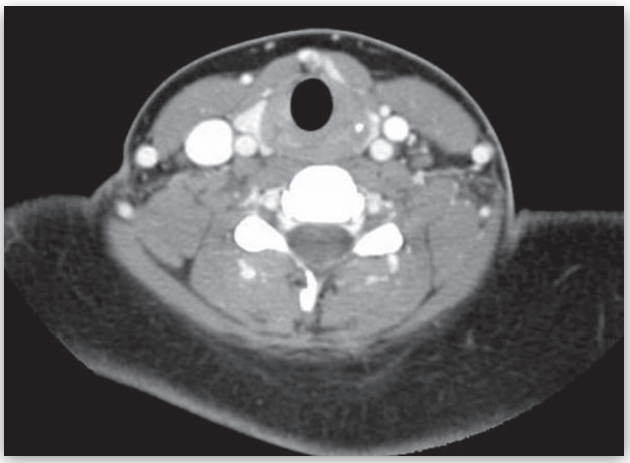

Img. 2.08 h: Axial CT

Img. 2.08 e/f/g: Coronal / Sagittal / Axial CT scan with enhancement shows a well defined predominantly cystic lesion seen at the Lt. lateral neck base, with smaller villiform lt lateral polypoid enhancement is detected. The lesion is seen abutting the Lt. common carotid artery with mild attenuation of the calibre of the Lt. internal Jugular vein. It is seen in posterior relationship to the Lt. sternocleidomastoid muscle.

Img. 2.08 h: Axial CT scan showing a well defined enhancing soft tissue lesion at the midline about the hyoid bone level. The enhancement pattern is typical of the thyroid gland and a small Lt. lateral enhancing tract connecting towards the Lt. thyroid lobe.

Features are highly suggestive of ectopic thyroid tissue in the midline. The primary differential diagnosis of the case would be a brachial cyst vs. Thyroglossal duct cyst with possible superimposed infection, in addition to the ectopic thyroid tissue in the midline. Nonetheless, postoperative histopathology was consistent with Papillary thyroid carcinoma within the large cyst.

for detailed information on radiology books, visit our website **www.jaypeebrothers.com,** for detailed information on radiology books, visit our webs

PICTORIAL ATLAS OF THYROID IMAGING

Salient Features

- This is a comprehensive imaging atlas of the thyroid gland and related structures. It represents a quick reference for Radiologists, Endocrinologists, Head & neck surgeons, and residents in training interested in thyroidology.
- This atlas covers a wide spectrum of thyroid pathology through a unique compilation of high quality Ultrasound, CT, MRI, Nuclear Isotope, and PET scan images all in one book.
- "Pictorial Atlas of Thyroid Imaging" is a fundamental resource for clinicians sitting for Board examination in Radiology or Professional Certification in neck Ultrasonography.
- With its simple colorful layout, browsing through is just an enjoyable educational experience.

Available at all medical bookstores or buy online at www.jaypeebrothers.com

JAYPEE BROTHERS
Medical Publishers (P) Ltd.
www.jaypeebrothers.com

Join us on facebook.com/JaypeeMedicalPublishers

Shelving Recommendations
RADIOLOGY
ENDOCRINOLOGY

ISBN 978-93-5250-128-1