r website **www.jaypeebrothers.com,** for detailed information on neurology books, visit our website **www.jaypeebrothers.com**

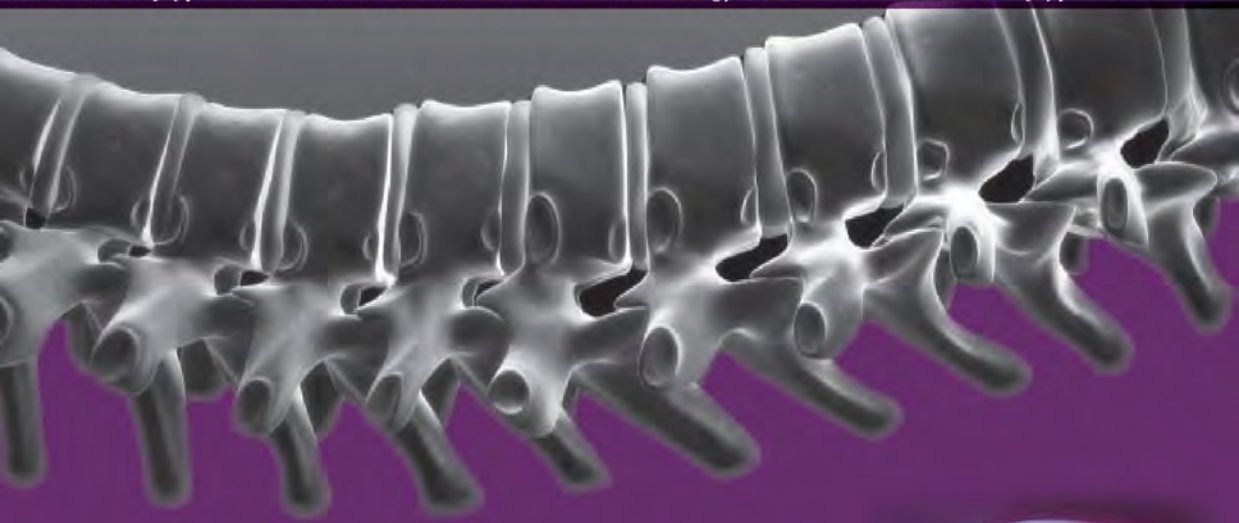

# Neuro Spinal Surgery Operative Techniques

## Anterior Cervical Discectomy and Fusion






**JKBC Parthiban**

*Forewords*
**KR Suresh Bapu**
**RR Ravi**

JAYPEE

# Contents


**1. Basics** **1**
- Anatomy of Cervical Disc and Prolapse *1*
- Applied Anatomy of Neck *3*
- Important Anatomy at Different Level *5*

**2. Approaches** **8**
- Surface Marking and Reality *8*
- Transcervical Extrapharyngeal Approach *9*
- Anterolateral Approach to Lower Cervical Disc *21*

**3. Decompression of Nerve Root and Cord** **33**
- Microsurgical Unilateral Osteophytectomy and Discectomy *33*
- Microsurgical Discectomy Alone *40*
- Microsurgical Excision of Wide Osteophyte with Thickened Annulus *41*

**4. Technique of Interbody Grafting** **54**
- Standard Tricortical Iliac Crest Graft Interbody Grafting *54*
- Titanium Interbody Cage Fusion *59*

**5. Technique of Harvesting Tricortical Iliac Crest Bone Graft** **83**

**6. Corpectomy and Fusion** **91**

**7. Closure** **102**

**8. Instruments** **103**

*Index* *111*

# Chapter 2

# Approaches

## SURFACE MARKING AND REALITY

In general, there are surface markings to locate the disc/vertebral body levels viz-Hyoid bone is at the level of C2/3 vertebra, Thyroid at C4 /5 vertebra and Cricoid at C6 vertebra and supraclavicular area at C7/T1 **(Fig. 2.1)**. They are approximate markers and may vary and hence this is not beneficial in practice due to the fact that the neck be placed extended during surgery and more over there are so many varieties of neck we encounter in practice. There are thin and long necks, thick, short and bulky ones, rigid necks with loss of lordosis and with congenital anomalies like Klippel Feil syndromes and hence I do not recommend surgeons to go by them to make the skin incision. It is practical to locate desired level with image intensifiers after positioning the patient. For corpectomies a midpoint be chosen skin incision. For example, for C5 corpectomy mark over C5 vertebral body, for C6 and C7 corpectomies mark at C6/7 disc level. The natural horizontal creases (Langer's line) can be used for cosmetic result.

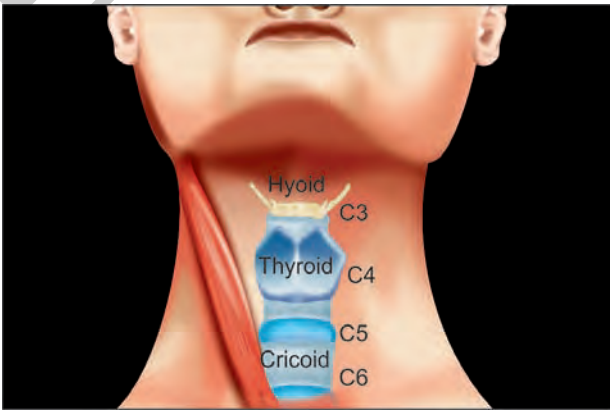


**Fig. 2.1** Approximate surface marking

JAYPEE BROTHERS

## TRANSCERVICAL EXTRAPHARYNGEAL APPROACH

This is an excellent approach to address a lot of disorders that affect anterior part of C1/2/3. CI/2 anterior screw stabilization, Odontoidectomy, C2/3 cervical discectomy, C2/3 stabilization, Ventral screw fixation for odontoid fracture can be performed through this approach. For C2/3 discectomy fusion and ventral screw fixation of odontoid it is simple than for odontoidectomy. For the later, it may look deeper but good illumination with microscope make it possible. The incision is wide and the dissection is meticulous and large to get the best exposure. Surprisingly, the incision marks never a great cosmetic problem after healing since it is placed submandibular.

*Step 1—Position:* After general anesthesia using a flexometallic endotracheal tube the patient is placed supine on the operation table with the neck extended by placing a pillow or cylindrical soft rest below the scapula and head rest over a soft head rest. The head is turned to opposite side of exposure by 30° to keep the mandible away for free surgical approach. A skull tong placed if necessary when traction is necessary in managing fracture dislocations. For ACDF, we do not require traction. The ET tube should be secured and an image intensifier is used to check the position of the cervical spine on table **(Fig. 2.2)**.

*Step 2—Skin incision marking and preparation:* Skin incision is marked 1 cm inferior to lower mandible from midline to the angle as shown in the picture **(Fig. 2.3A)**. The surgical area is prepared with aseptic methods and draped **(Fig. 2.3B)**. Subcutaneous injection of 2% lignocaine and adrenalin solution is then given.



**Fig. 2.2** Operative position

JAYPEE BROTHERS




**Figs 2.3A and B** (A) Submandibular skin incision mark; (B) Surgical area draped

*Step 3—Platysma:* The skin incised and the platysma is widely exposed. Meticulous fascia opening like in cadaveric dissection is made **(Fig. 2.4A)**. The muscle is then split vertically between mandibular symphysis and median notch of superior thyroid cartilage **(Fig. 2.4B)**.

*Step 4—Subplatysma dissection:* The platysma muscle is then cut horizontal to mandibular border all along the incision to expose the strap muscle from

JAYPEE BROTHERS

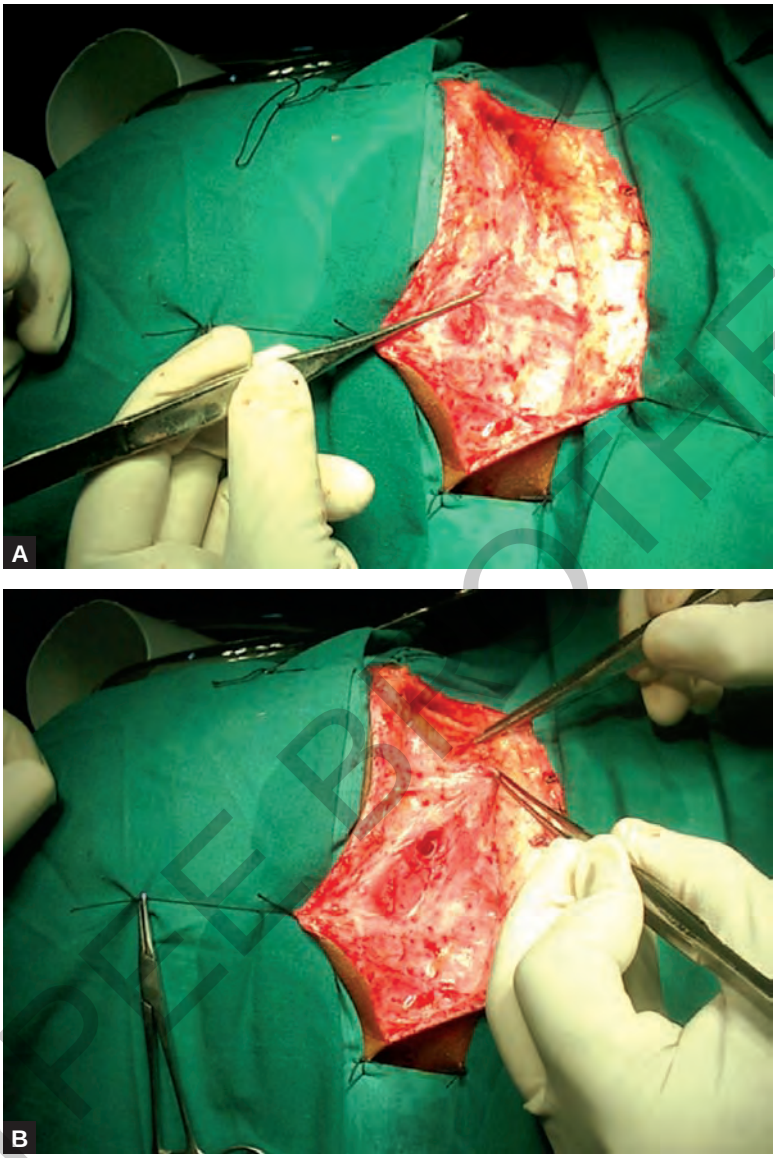


**Figs 2.4A and B** (A) Platysma exposed; (B) Platysma split

hyoid to mandilble, the deep cervical fascia, facial vessels near the angle of mandible just posterior and inferior to the submandibular gland **(Fig. 2.5)**.

*Step 5—Submandibular gland:* The fascia need to be cleared and the platysma lifted well till the mandibular border to expose the submandibular gland. Often the gland is large and in some incidences it may need to be rarely excised. Normally, the gland can be retracted with a right angled retractor superiorly **(Fig. 2.6)**.

JAYPEE BROTHERS

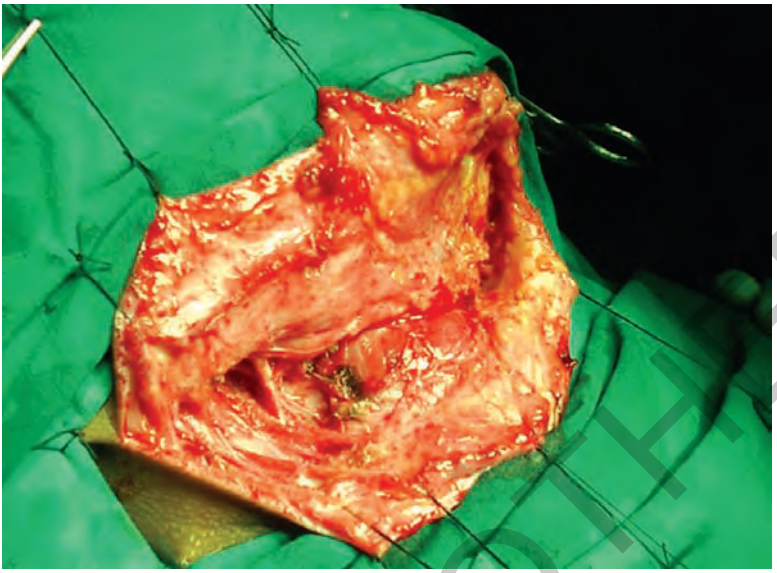

**Fig. 2.5** Subplatysma dissection. Note the facial vessels

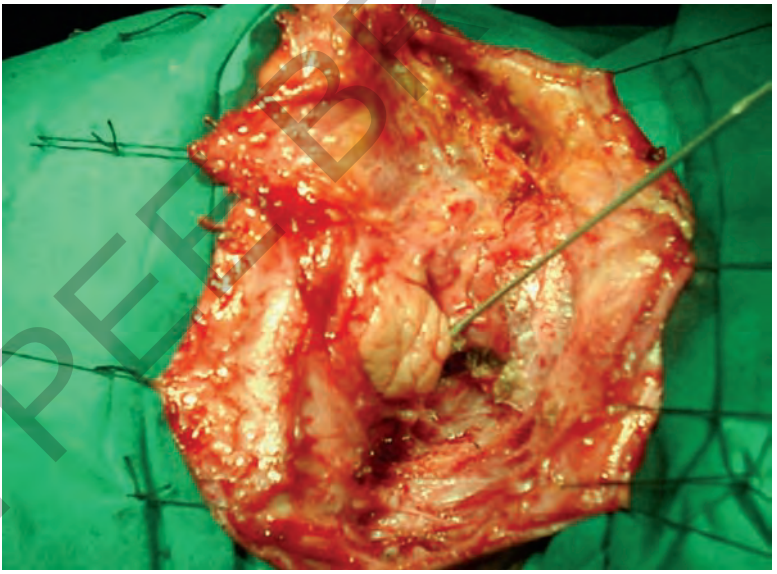

**Fig. 2.6** Submandibular gland

*Step 6—Digastric tendon:* At this stage, one can visualize the hyoid bone and the facial sling attached to greater wing of hyoid holding the tendon of digastric muscle **(Fig. 2.7A)**. The sling is then cut to release the digastric muscle, which facilitate easier retraction of larynx and pharynx away from midline and carotid sheath **(Fig. 2.7B)**. The fascia between hyoid and the carotid sheath is dissected and a groove is well seen lateral to hyoid and

JAYPEE BROTHERS

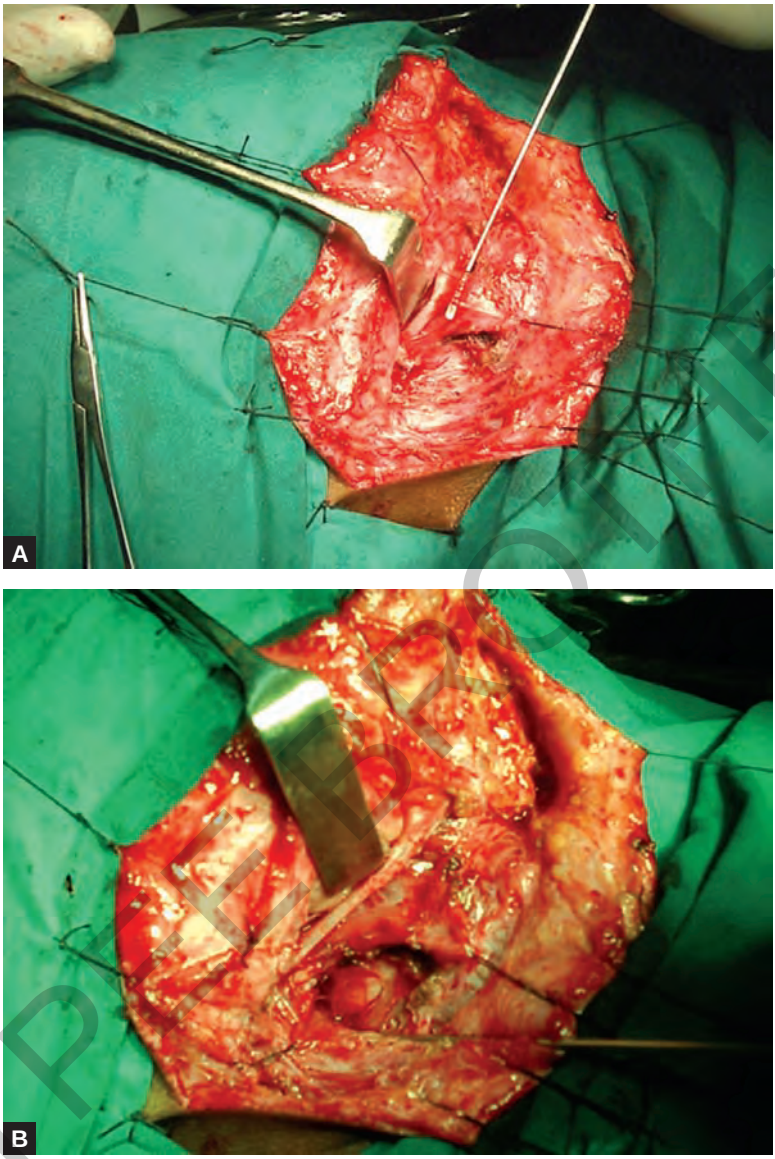


**Figs 2.7A and B** (A) Facial sling holding digastric tendon; (B) Digastric tendon released

upper thyroid cartilage. The hypoglossal nerve is deeper, inferior and parallel to digastric tendon. No attempt is made to search for it. Digastric tendon release may not be needed in simple ACDF at C2/3, but essential when higher regions need exposure.

*Step 7—To retropharyngeal space:* Using simple right angle retractors a path is created to reach C2/3 disc space by retracting the hyoid at its greater cornu and deeper down the superior phayngeal constrictor muscle away from carotid artery. The carotid artery should be palpated and that marks the

JAYPEE BROTHERS

lateral most dissection. Using cotton peanuts on a long thin forceps the loose area between the said structures the prevertebral area is reached. Remember the pharyngeal muscles are very thin and need gentleness in retraction. The superior laryngeal nerve is caudal and lateral to this approach. No attempt is made to dissect it **(Fig. 2.8)**.

*Step 8—Final procedure:* Cervical retractor is placed and appropriate procedure done. In this picture, anterior cervical plate stabilization of C2/3 is shown **(Fig. 2.9)**.

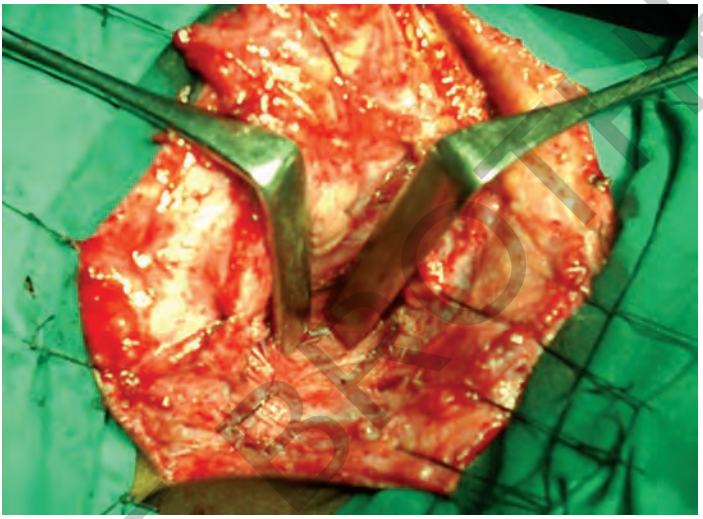

**Fig. 2.8** Dissection between carotid artery laterally and hyoid medially en route to retropharyngeal space

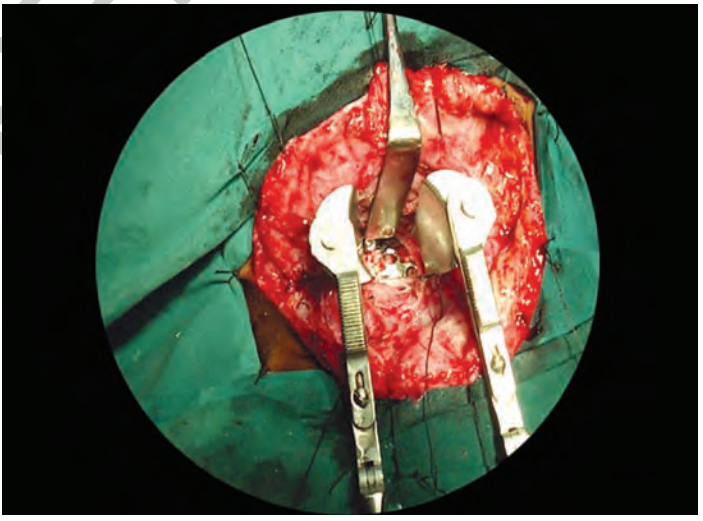

**Fig. 2.9** Exposure at C2/3 place

JAYPEE BROTHERS

Note simple set of retractors used. To achieve exposure above C2/3 a Beever's retractor is used to lift the pharynx above and retract to the opposite side and superiorly. Now the surgeon can recollect the step of neck positioning. The lateral rotation of 30° help in easy retraction and keep the mandibular notch away.

*Step 9—Closure:* A prevertebral drain is placed and the platysma is approximated using 2 '0' vicryl, and the skin closed with subcutaneous sutures using 3 '0' monocryl cutting needle **(Figs 2.10A and B)**.

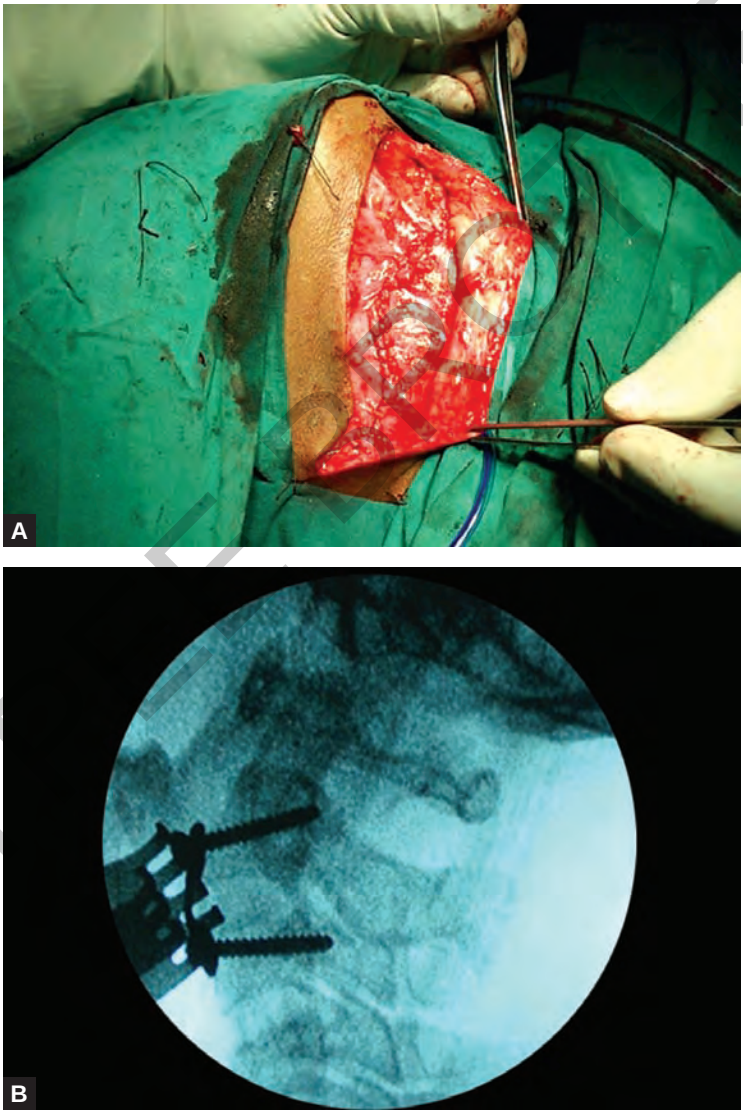


**Figs 2.10A and B** (A) Closure. Platysma approximated; (B) X-ray lateral view showing the fixation

JAYPEE BROTHERS

## Illustrative Cases for Transcervical Retropharyngeal Approach

The technique of discectomy and fusion will be discussed in following chapter. It will be appropriate if I can show few illustrative case at this point. Before that go through one more series of pictures to show the steps in a different patient where C2/3 stabilization done for Hangman's fracture.

**Case 1**—Hangman's fracture

*Picture 1*—Wide exposure with the submandibular gland well exposed **(Fig. 2.11)**.

*Picture 2*—Submandibular gland retracted and fascial dissection done **(Fig. 2.12)**.

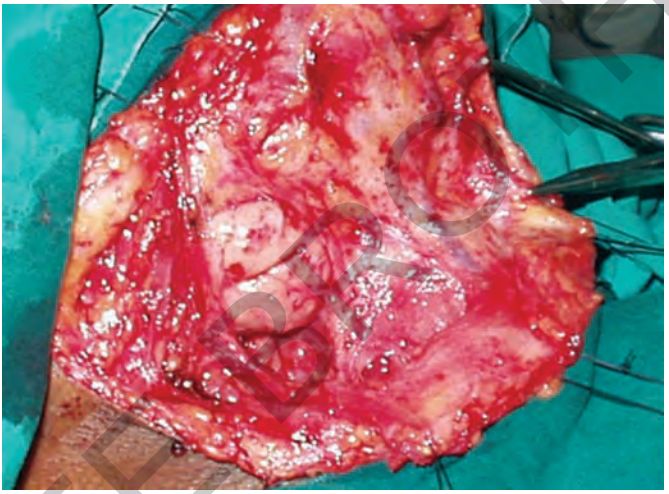

**Fig 2.11** Wide exposure

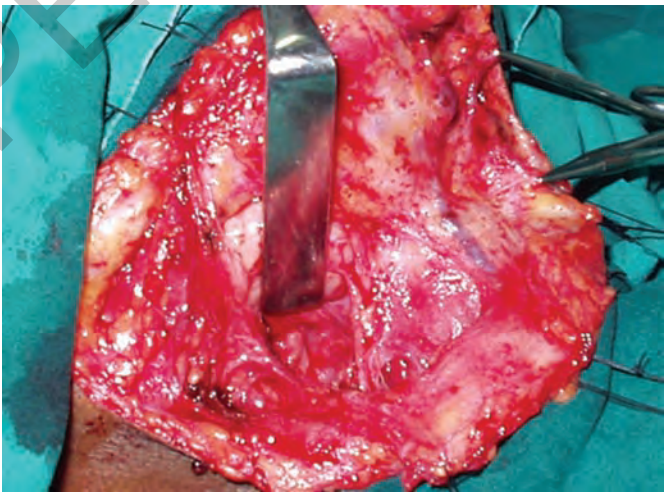

**Fig. 2.12** Retraction of submandibular gland

JAYPEE BROTHERS

*Picture 3*—Hyoid retracted and the loose space dissected to retropharyngeal region **(Fig. 2.13)**.

*Picture 4*—The prevertebral area exposed over C2/3 **(Fig. 2.14)**.

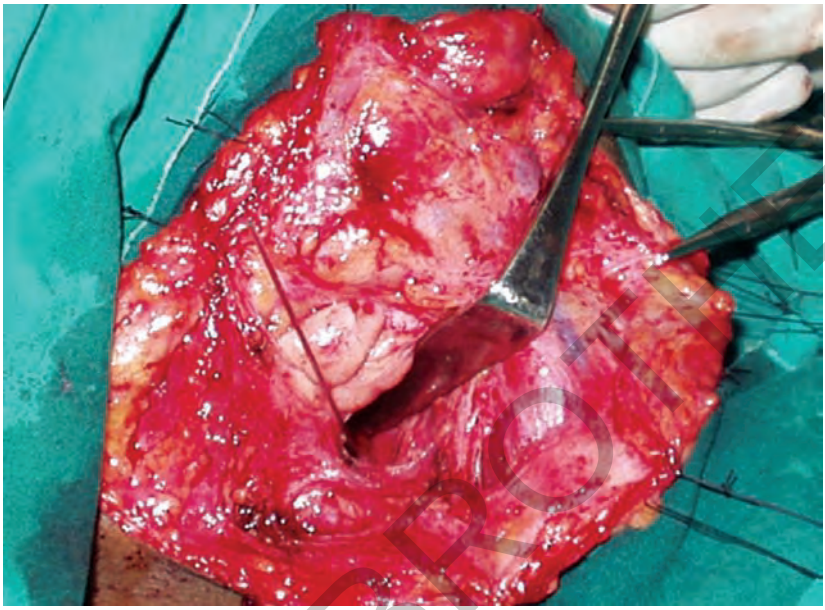

**Fig. 2.13** Hyoid retracted from carotid artery

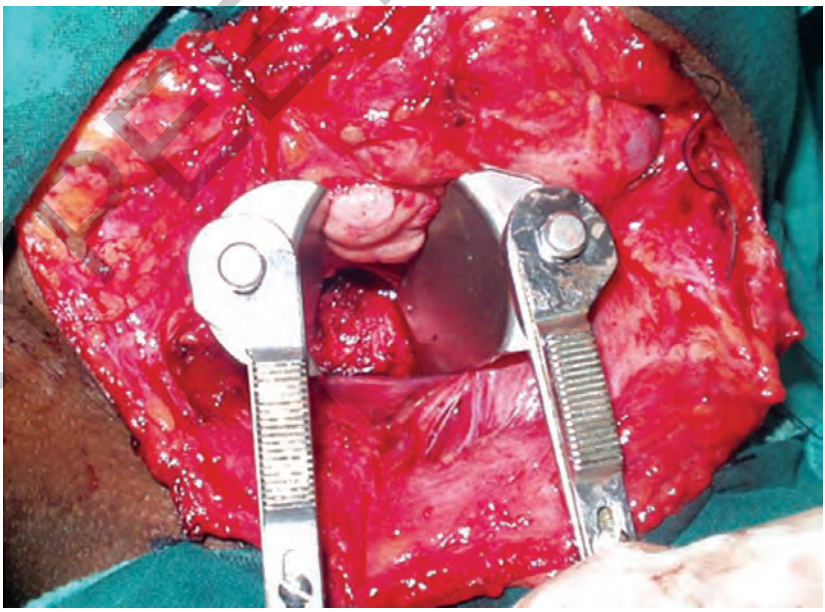

**Fig. 2.14** Retractor placed to expose prevertebral space

JAYPEE BROTHERS

*Picture 5*—Anterior instrumentation and fixation of C2/3 **(Fig. 2.15A)**.

*Picture 6*—Image intensifier view of C2/3 stabilization in Hangman's fracture. **(Fig. 2.15B)** and the preoperative status of C2/3 complex **(Fig. 2.15C)**.

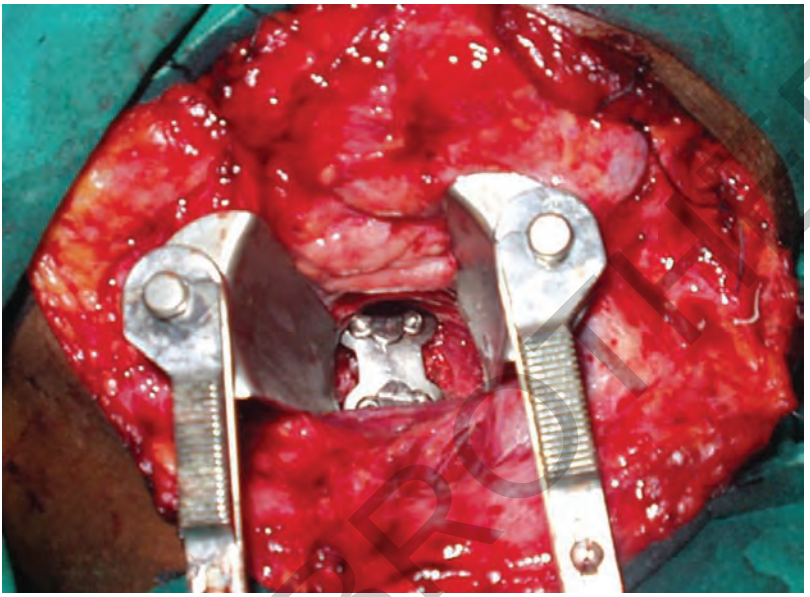

**Fig. 2.15A** Cervical plate in position

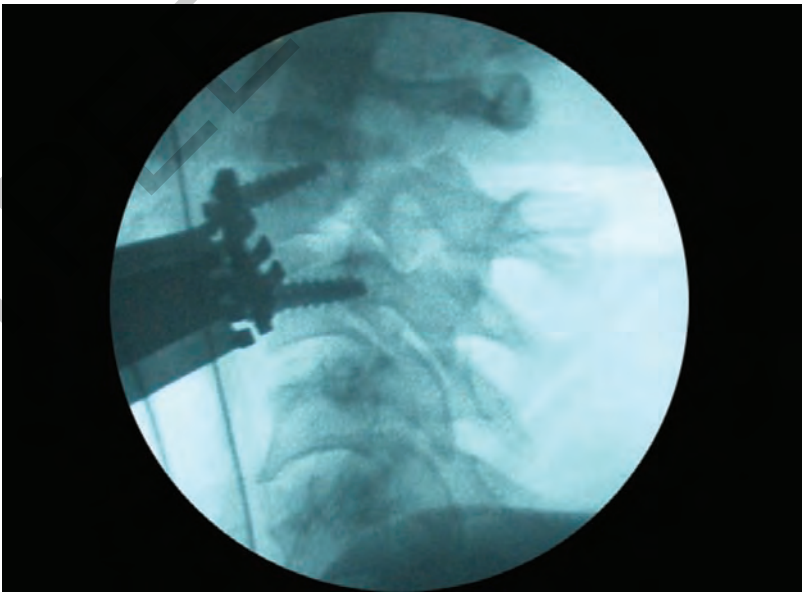

**Fig. 2.15B** Lateral II view of C2/3

JAYPEE BROTHERS



**Fig. 2.15C** Pars fracture and dislocation

**Case 2**—C3/4 cervical discectomy and interbody cage **(Fig. 2.16)**.



**Fig. 2.16** X-ray lateral view showing C3/4 interbody rectangular titanium cage. Note hyoid cartilage in line with the disc level

JAYPEE BROTHERS

for detailed information on neurology books, visit our website **www.jaypeebrothers.com,** for detailed information on neurology

# *Neuro Spinal Surgery Operative Techniques*

## Anterior Cervical Discectomy and Fusion

### *Salient Features*

- Gives the insight of various steps in performing anterior cervical discectomy and fusion
- Depicts the applied anatomy, surgical approach and detailed microsurgical techniques as done during live operative surgery
- Case illustrations are unique for the readers to understand the indications in various complex situations
- It is an ideal book for young neuro and spinal surgeons to read, understand and perform the technique in cervical spine.



**JKBC Parthiban** MCh (Neurosurgery) FNS Japan (Fujita) is Senior Consultant (Neurosurgeon and Spine Neurosurgery), Kovai Medical Center and Hospital, Coimbatore, Tamil Nadu, India. With relentless commitments, he has convened and coordinated various spine conferences, participated in many live operative and cadaver workshops and has taught numerous young neuro and spine surgeons. A prolific cricketer during his college days and an artist, he is now the Editor-in-Chief, Journal of Spinal Surgery, and was the Past President of Neuro Spinal Surgeons' Association (NSSA) of India. He is also one of the Founder Members of NSSA. He is an academician and a shrewd surgeon. He is also an active member of various associations, and has published many scientific articles in renowned national and international journals. The chapters on posterior cervical fusion techniques, fusion techniques in lumbar spine and pedicle screw fixation in *Textbook of Operative Neurosurgery* are a few among many to mention.

He is the inventor of double hook retractor in microlumbar discectomy, and he is a regular teaching faculty in the field of spinal surgery. He also conducts fellowship programs for young neuro and orthopedic surgeons in spinal surgery since 2001.

**Available at all medical bookstores**
**or buy online at www.jaypeebrothers.com**

**JAYPEE BROTHERS**
**Medical Publishers (P) Ltd.**
**www.jaypeebrothers.com**

Join us on facebook.com/JaypeeMedicalPublishers

Shelving Recommendations
**NEUROLOGY, SURGERY**

ISBN 978-93-5250-130-4