thers.com, for detailed information on dental books, visit our website www.jaypeebrothers.com, for detailed information on dental book



Exam Preparatory Manual for Undergraduates

Periodontology

KV Arun
A Talwar

Contents

Section I: Basic Tissues

1. Gingiva **3**

Marginal gingiva or free gingiva or unattached gingiva 4
Attached gingiva 4
Papillary gingiva, interdental gingiva 4
Gingival epithelium 5
Gingival connective tissue 6

2. Cementum **10**

Chemical composition 10
Acellular cementum 11
Cellular cementum 11

3. Periodontal Ligament **14**

Ground substance 14

4. Alveolar Bone **18**

Alveolar bone proper/cribriform plate/lamina dura 18
Supporting alveolar bone 19
Cortical plates 19

Section II: Defence Mechanism

5. Immune Response **27**

Macrophages (mononuclear cells) 28

6. Saliva **31**

Saliva 31

7. Gingival Crevicular Fluid **33**

Properties of gingival crevicular fluid 33
Methods of estimating gingival crevicular fluid 34

8. Classification of Periodontal Disease **38**

1999 classification of periodontal disease and conditions 38

9. Epidemiology **40**

Classification of index systems 40
Gingival index 40

Section III: Etiopathogenesis

10. Dental Plaque **47**
Composition of plaque 47
Formation of dental plaque 48
Nonspecific plaque hypothesis 49

11. Calculus and other Plaque Retentive Factors **51**
Classification of calculus 51
Composition of calculus 52

12. Risk Factors **54**
Risk factors 54
Risk determinants 54
Risk indicators 54
Risk markers 55
Mechanism of stress 57

Section IV: Gingival Diseases

13. Plaque-induced Gingival Inflammation **61**
Stage I: Gingivitis—the initial lesion 61
Stage II: Gingivitis—the early lesion 61
Stage III: Gingivitis—the established lesion 62
Stage IV: Gingivitis—the advanced lesion 62

14. Nonplaque-induced Gingivitis (Acute Conditions of Gingiva) **64**
Bacterial origin 64
Gingival diseases of viral origin 66
Physical, chemical and thermal injury 67

15. Gingival Enlargement **68**
Classification of gingival enlargement 68

16. Desquamative Gingivitis **73**
Etiology 73
Diagnosis 74
Treatment plan 74

17. Transition from Gingivitis to Periodontitis **75**
Transition from gingivitis to periodontitis 75

Section V: Periodontal Diseases

18. Periodontal Pocket **79**
Terminologies 79
Classification of periodontal pocket 80

19. Bone Loss and Patterns of Bone Destruction **83**

20. Trauma from Occlusion **87**
Acute and chronic trauma from occlusion 87
Primary and secondary trauma from occlusion 87
Treatment considerations 90

21. Chronic Periodontitis **92**
Etiology 92
Radiographic features in chronic periodontitis 93
Progression of chronic periodontitits 94
Treatment considerations 94

22. Aggressive Periodontitis **96**
Etiology 96
Diagnosis 97
Localized aggressive periodontitis 97
Generalized aggressive periodontitis 98

23. Periodontitis as a Manifestation of Systemic Disease **101**
Associated with hematological disorders 101
Associated with genetic disorders 101
Not otherwise specified 102

24. Necrotizing Periodontal Disease **103**
Definition 103
Classification of necrotizing periodontal disease 103
Necrotizing ulcerative periodontitis 103

25. Periodontal Manifestation of HIV Infection **105**
Gingivitis in HIV patients 105
HIV-associated periodontitis 105

26. Abscesses of the Periodontium **106**
Gingival abscess 106
Periodontal abscess 106

27. Periodontitis Associated with Endodontic Lesions **108**
Ways of communication 108

Section VI: Diagnosis

28. Clinical Diagnosis of Periodontal Disease **115**
Recording the history 115
Clinical examination 115
Additional diagnostic techniques 117

29. Advanced Diagnostic Techniques **119**
Periodontal probing 119
Microbial diagnostic aids 121
Diagonstic aids-host response 122

30. Determination of Prognosis **123**
Factors affecting the overall prognosis 123
Factors affecting individual teeth prognosis 124

31. Rationale of Periodontal Therapy and Treatment Planning **126**
Phases of periodontal therapy 127

Section VII: Nonsurgical Treatment

32. Periodontal Instrumentation **131**
Classification of periodontal instrument 131
Power driven instruments 137

33. Mechanical Plaque Control **141**
Home care dental cleansing aids 142
Dentifrices 144
Composition 144

34. Chemical Plaque Control **147**
Chlorhexidine 148

35. Systemic and Local Antimicrobials in Periodontal Therapy **151**
Flouroquinolones 153
Macrolides 154
Local drug delivery 154

36. Host Modulation Therapy **155**
Inflammatory mediators 156
Anti-MMPS 157

Section VIII: Surgical Treatment

37. Gingivectomy **161**
Indications 161
Contraindications 161
Healing after gingivectomy 162

38. Access Flap Surgery **163**
Classification of periodontal flaps 163

39. Resective Osseous Surgery **167**
Rationale and objective 168

40. Reconstructive Osseous Surgery **171**
Classification of bone grafts 171
Autogenous grafts 172

41. Root Biomodification **176**
Mechanical biomodification 176
Chemical biomodification 177

42. Management of Furcation Involvement **179**
Classification of furcation 179
Therapeutic objectives 180
Furcation odontoplasty 180
Furcation involvement in periodontal-endodontal therapy 183

43. Mucogingival Surgery **185**
Classification of gingival recession 185
Free grafts 190

44. Supportive Periodontal Therapy **193**
Therapeutic goals 193

45. Periodontal Medicine **196**
Periodontal medicine 196

46. Periodontal Management of Medically Compromised Patients **198**
Infective endocarditis/rheumatic heart disease 198
Bleeding disorders 200

47. Splinting **201**
Rationale of splinting 201

48. Symptoms of Periodontal Disease **203**
Causes of halitosis 203
Hypersensitivity 204
Mobility 205
Food impaction 205

49. Dental Implants: Diagnosis and Treatment Planning **207**
Types of dental implant 207
Implant design 207
Patient evaluation 208
Diagnostic aids 209
Treatment planning 209
Peri-implant disease 209

50. Recent Advances in Periodontal Therapy **211**
Lasers in periodontics 211
Microsurgery 212
Piezosurgery 213

Index *215*

Chapter 2

Cementum

Chapter Outline

- Definition
- Composition
- Development
- Types of cementum
- Clinical relevance

Q: Define cementum.

Cementum is the mineralized avascular mesenchymal tissue that covers the anatomic roots of teeth and provides attachment or anchorage for the periodontal ligament fibers. Cementum is characterized by continuous deposition throughout life and has a very slow rate of continuous synthesis and thereby irregularities on its surface are attended to. Cementum shares some physical, chemical and structural characteristics with compact bone but differs from it in that it is avascular, more resistant to resorption and remodeling.

Q: What is the thickness of cementum?

- Cementum is thinnest at the cementoenamel junction (20–50 micrometers) and thickest at the apex of the root and furcation (200–300 micrometers).
- It is thicker in distal surface than in mesial surface, probably due to functional stimulation.

Q: What is the composition of cementum?

CHEMICAL COMPOSITION

Cementum being a mineralized connective tissue has both an organic and an inorganic phase. On a dry weight basis, 40–50% is inorganic substances mainly in the form of calcium phosphate as hydroxyapatite ($Ca_{10}[Po_4]_6[OH]_2$). The other 50–55% is organic substance which is primarily collagen type-I and proteoglycans/glycoproteins.

Q: Describe development of cementum.

Cementum develops from the dental sac in particular from area within it called the dental follicle. Undifferentiated mesenchymal cells of the follicle transform to cementum forming cell,

JAYPEE BROTHERS

cementoblast under the influence or enamel matrix proteins possible secreted by the cells of the Hertwig's epithelial root sheath.

Cells of Cementum

The primary cell is the cementoblast, which is responsible for laying down the acellular cementum. This cell may be distinct in origin from the cementoblasts giving rise to the cellular cementum. Cellular cementum is formed by cementoblasts that may originate in the perivascular space of the periodontal ligament. This is possibly one reason why acellular is not predictably regenerated as yet.

Fibers of Cementum

Extrinsic Fibers of Cementum

These fibers are portions of the principal fibers of the periodontal ligament (Sharpey's fibers), which are embedded in the cementum. They are usually oriented perpendicular to the root surface. These fibers are also inserted into the alveolar bone (Figure 2.1).

Intrinsic Fibers

These fibers belong to the cementum matrix and are formed by the cementoblast. They are oriented more or less parallel to the long axis of root surface. They reinforce the inserting extrinsic fibers.

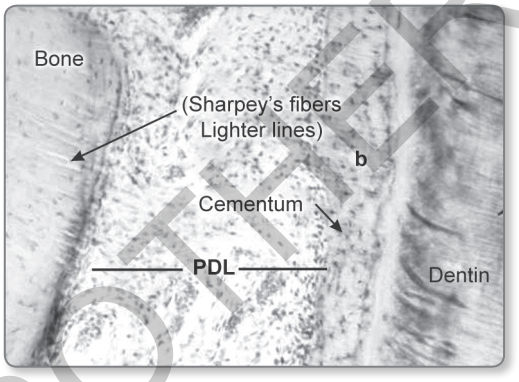

Figure 2.1: Cementum

Q: Classify and describe the various subtypes of cementum.

There are two main types of cementum: Acellular (primary) and cellular (secondary) (Figure 2.2).

ACELLULAR CEMENTUM

Acellular cementum usually forms at the time of root formation and tooth eruption. It covers the cervical third of the root and contains no cells in the matrix (no cementocytes). It is usually lamellated and has incremental lines (Salter) suggesting periods of synthesis followed by periods of rest.

CELLULAR CEMENTUM

Cellular cementum is present at the apical third of the root and is characterized by the presence of embedded cells (cementocytes).

Schroeder has classified cementum as follows:

1. Acellular afibrillar cementum
2. Acellular extrinsic fiber cementum
3. Cellular mixed stratified cementum
4. Cellular intrinsic fiber cementum
5. Acellular intrinsic fiber cementum.

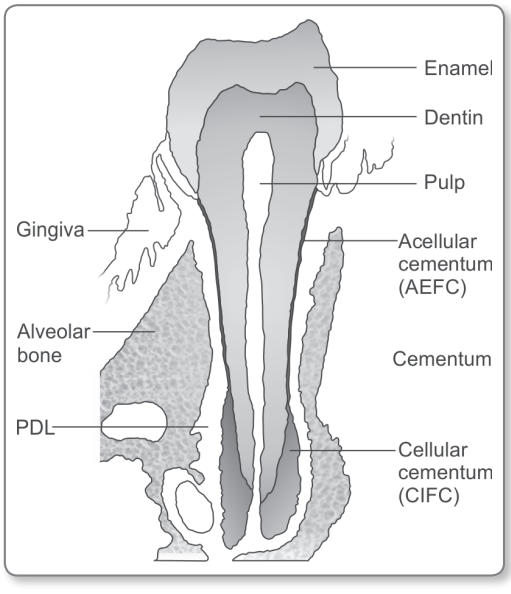

Figure 2.2: Parts of tooth

JAYPEE BROTHERS

1. *Acellular afibrillar cementum (AAC):* It is found generally on mature enamel surfaces close to the CEJ. It is thought to form when the reduced enamel epithelium disintegrates and the dental follicle interacts with the exposed enamel matrix leading to cementum deposition.
2. *Acellular extrinsic fiber cementum (AEFC):* It is the most important support apparatus on the root surface. It consists of densely arranged collagen fiber bundles placed perpendicularly to the long axis of the tooth root projecting into the periodontal ligament. Acellular extrinsic fiber cementum (AEFC) formation proceeds at a rate of 5 to 7 μm per day during the development of the tooth root.
3. *Cellular mixed stratified cementum (CMSC):* It is formed when the root development is about two thirds completed. This type of cementum contains a mixture of collagen fibers including the intrinsic fibers running parallel to the root surface and some extrinsic fibers running perpendicular to the root surface. Cellular mixed stratified cementum is usually deposited on the root surfaces lining furcations and apical portions.
4. *Cellular intrinsic fiber cementum (CIFC):* Cellular intrinsic fiber formation occurs when cementoblasts secrete the matrix rapidly and become entrapped in the matrix as cementocytes. CIFC attaches to the still non-mineralized dentin through intermingling of collagen fibrils and subsequent mineralization. In addition, being a component of cellular mixed stratified cementum, the CIFC is also considered to be a form of reparative cementum.
5. *Acellular intrinsic fiber cementum (AIFC):* AIFC is an acellular variant of cellular intrinsic fiber cementum that is deposited during adaptive responses to external forces and forms without leaving cells behind.

Q: Differences between cellular and acellular cementum.

Acellular cementum	Cellular cementum
First formed or primary cementum	Secondary cementum
It is formed up to the stage when tooth reaches its antagonist in occlusion	It is formed after tooth has obtained its occlusal position
Present in the cervical 2/3rd of the root	Present in the apical 1/3rd of the root
Devoid of cells	Presence of cementoblasts
Exhibits greater mineralization in association with maximal tooth support	Comparatively less mineralized. Continuous deposition to make up for mechanical wear down such as attrition.

Q: What are the types of cementoenamel junction?

The junction where cementum and enamel meet at the cervix of the tooth is referred to as the cementoenamel junction or (CEJ). There are three possible types of CEJ.

1. Cementum meets enamel at the cervical end of enamel (30% of all teeth)
2. Cementum and enamel do not meet (10% of all teeth)
3. Cementum overlaps enamel (60% of all teeth).

Q: Write briefly on the various changes observed in cementum following disease.

- Cementum resorption: It may be caused by both local and systemic conditions.
  - Local conditions include trauma from occlusion, orthodontic movement, pressure from malaligned erupting teeth, cysts, periapical disease, transplanted teeth and occasionally in periodontal disease.
  - Systemic conditions include calcium deficiency, hypothyroidism, hereditary fibrous osteodystrophy, and Paget's disease.

JAYPEE BROTHERS

- Cemental spurs (tears) occur as excrescences of cementum usually in teeth subjected to heavy functional or parafunctional forces.
- Hypercementosis or cemental hyperplasia—usually seen at the apical areas of the roots, sometimes to the extent that root morphology may be altered. Low grade persistent periapical infection is thought to be one of the most common reasons for its occurrence.
- Repair and regeneration—cementum has limited capacity to regenerate. Reparative capacity is largely a result of continuous deposition of cementum. There is very little evidence of regeneration of AEFC.

JAYPEE BROTHERS

for detailed information on dental books, visit our website www.jaypeebrothers.com, for detailed information on dental books, visit our w

Exam Preparatory Manual for Undergraduates

Periodontology

This book is meant to serve as a guide to the undergraduate students to obtain a comprehensive overview of periodontology. It covers all the topics necessary for the BDS students to not only help understanding the subject but also face the final year exam. As a preparatory manual, it is written in an easy-to-follow and reproduce format.

KV Arun MDS is Professor in the Department of Periodontics, Ragas Dental College and Hospital, Chennai, Tamil Nadu, India. He is the author of a textbook titled *Molecular Biology of Periodontium* written for postgraduate students. He has written several articles in national and international journals. He has also extensively lectured on the subject in various national forums.



A Talwar MDS is currently Reader in the Department of Periodontics, AB Shetty Dental College, Mangaluru, Karnataka, India. He has written several articles in national and international journals.



Available at all medical bookstores or buy online at www.jaypeebrothers.com

JAYPEE BROTHERS
Medical Publishers (P) Ltd.
www.jaypeebrothers.com
Join us on facebook.com/JaypeeMedicalPublishers

Shelving Recommendation
DENTISTRY

ISBN 978-93-5250-145-8