r website **www.jaypeebrothers.com,** for detailed information on dental books, visit our website **www.jaypeebrothers.co**

Handbook of Forensic Odontology and Medical Jurisprudence



Richik Tripathi

Foreword
RK Misra

JAYPEE

Contents

1. Practice of Forensic Odontology **1-6**
Introduction 1
Pink Teeth 2
Radiography 3
Bite Marks 3
Charting of Teeth 4
Animal Bites 5
Sex 5
Occupation, Habits and Social Position 6
Case 6

2. Methods of Dental Identification **7-21**
Introduction 7
Reconstruction Method 8
Comparative Method 8
Dental Identification 10
Comparative Group 12

3. Age Determination **22-27**

4. Bite Marks Analysis **28-38**
Agents Producing Bite Marks 28
Substances and Materials Presenting Bite Marks 30
Methods of Recording Bite Marks 33

5. Introduction to Medical Jurisprudence **39**

6. Medical Records **40-42**
Contents 40
In Medicolegal Cases 41
Property Rights 41
Patients Rights 41
Medical Records in Court 41
Government and Other Agencies 42
Disposal of Medical Records 42

7. Doctor-Patient Relationship **43-46**
Duties of Registered Dental Practitioner 43
Second Opinion (Also Known as Consultations with Another Doctor) 44
Rights of Registered Medical Practitioner (RMP) 45
Rights of a Patient 45
Duties of Patient 46

8. Professional Misconduct and Negligence **47-56**
Definition 47
Procedure for Action 47
Action for Professional Misconduct 47
Appeal against Action 48
Professional Negligence (Malpractice) 49
Procedure for Action 50
Action for Professional Negligence and Appeal 50
Types and Examples of Professional Negligence 50
Contributory Negligence 52
Vicarious Responsibility 52
Defenses against Professional Negligence 53
Precautions against Professional Negligence 54
Prevention against Complaint of Professional Negligence 54
Nine Rs of Malpractice Prevention 55

9. Professional Indemnity Insurance **57-62**
Professional Indemnity Insurance 57
Doctors and Medical Practitioners (Guidelines) 59
Exclusions 61

10. Anesthetic and Operative Deaths **63-65**
Causes of Death due to Anesthesia 63
Deaths Associated with Surgery 65

11. Professional Secrecy and Privileged Communication **66-68**
Professional Secrecy 66
Privileged Communication 67
Action for Divulging Professional Secrets 68

12. Consent in Medical Examination and Treatment **69-72**
Definition 69
Types of Consent 69
Presence of a Third Party 70
Compulsory Medical Examination 70
Legally Valid Consent 71
Consent in Special Circumstances 71

13. The Autopsy Protocol **73-80**
Model Autopsy Protocol 73

14. Doctor As Witness to Medical and Dental Evidences **81-83**
Guidelines for Presenting Medical Evidence 82

Appendices *85-94*

Suggested Reading *95*

Index *97-98*

2
CHAPTER

METHODS OF DENTAL IDENTIFICATION

INTRODUCTION

A dentist could be called upon to give an expert opinion on the victim, deceased person or a culprit by magistrate or jury which will help the court to build the evidence against crime. However to a clinical dental surgeon it is like full clinical examination to ascertain the diagnosis and justifying the association of clinical, radiological and other advanced technique in identification of the individual. Following methods are now in current practice (Table 2.1):

Table 2.1: Features examined during the comparative dental identification

Teeth present
a. Erupted
b. Unerupted
c. Impacted
Missing teeth
a. Congenitally
b. Lost antemortem
c. Lost postmortem
Tooth type
a. Permanent
b. Deciduous
c. Mixed
d. Retained primary
e. Supernumerary
Tooth position
a. Malposition
Crown morphology
a. Size and shape
b. Enamel thickness
c. Contact points
d. Racial variations
Crown pathology
a. Caries
b. Attrition, abrasion, erosion
c. Atypical variations, enamel pearls, peg laterals etc.
d. Dentigerous cyst
Root morphology
a. Size
b. Shape
c. Number
d. Divergence of roots
Root pathology
a. Dilaceration
b. Root fracture
c. Hypercementosis
d. Root resorption
e. Root hemisections
Pulp chamber/root canal morphology
a. Size, shape and number
b. Secondary dentine
Pulp chamber/root canal pathology
a. Pulp stones, dystrophic calcification
b. Root canal therapy
c. Retrofills
d. Apicectomy
Periapical pathology
a. Abscess, granuloma or cysts
b. Cementomas
c. Condensing osteitis

JAYPEE BROTHERS

Dental restorations
1. Metallic
a. Non-full coverage
b. Full coverage
2. Non-metallic
a. Non-full coverage
b. Laminates
c. Full coverage
3. Dental implants
4. Bridges
5. Partial and full removable prosthesis tissues
Gingival morphology and pathology
a. Contour, recession, focal/diffuse, enlargements, interproximal craters
b. Color—inflammatory changes, physiological (racial) or pathological pigmentations
c. Plaque and calculus deposits
Periodontal ligament morphology and pathology
a. Thickness
b. Widening
c. Lateral periodontal cysts
Alveolar process and lamina dura
a. Height, contour, density of crestal bone
b. Thickness of interradicular bone
c. Exostoses, tori
d. Pattern of lamina dura
e. Bone loss (horizontal/vertical)
f. Trabecular bone pattern and bone islands
g. Residual root fragmentsmical features

Maxillary sinus
a. Size, shape, cysts
b. Foreign bodies, fistula
c. Relationship to teeth
Anterior nasal spine
a. Incisive canal (size, shape, cyst)
b. Median palatal suture
Mandibular canal
a. Mental foramen
b. Diameter, anomalous
c. Relationship to adjacent structures
Coronoid and condylar processes
a. Size and shape
b. Pathology
Temporomandibular joint
a. Size, shape
b. Hypertrophy/atrophy
c. Ankylosis, fracture
d. Arthritic changes
Other pathologies
a. Developmental cysts
b. Salivary gland pathology
c. Reactive/neoplastic
d. Metabolic bone disease
e. Focal or diffuse radiopacities
f. Evidence of surgery
g. Trauma—wires, surgical pins, etc.

RECONSTRUCTION METHOD

a. Anthropometric measurement height weight, sex
b. Computer generated graphics and superimposition (Figs 2.1A to C)
c. Plaster of Paris reconstructed models (Fig. 2.2).

COMPARATIVE METHOD

- Use of substantial evidences
- Place of crime
- Associated injury, mode of crime
- Motive of crime.

JAYPEE BROTHERS

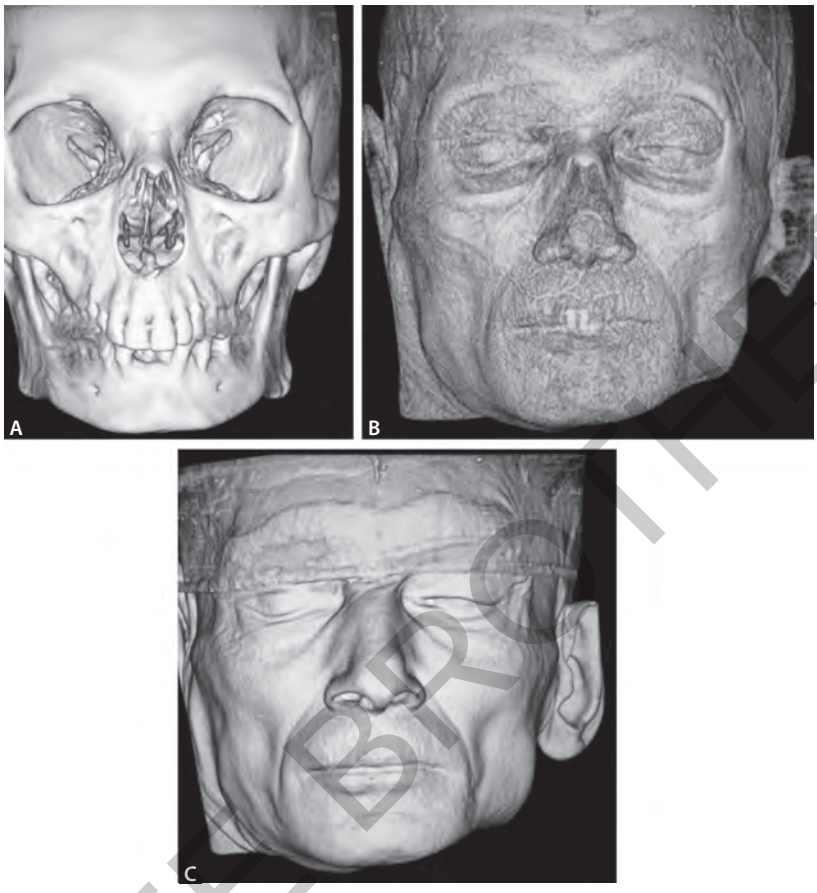

Figures 2.1A to C: 3D computed tomography scan guided reconstruction of skull and facial superimposition *(For color version see Plate 1)*

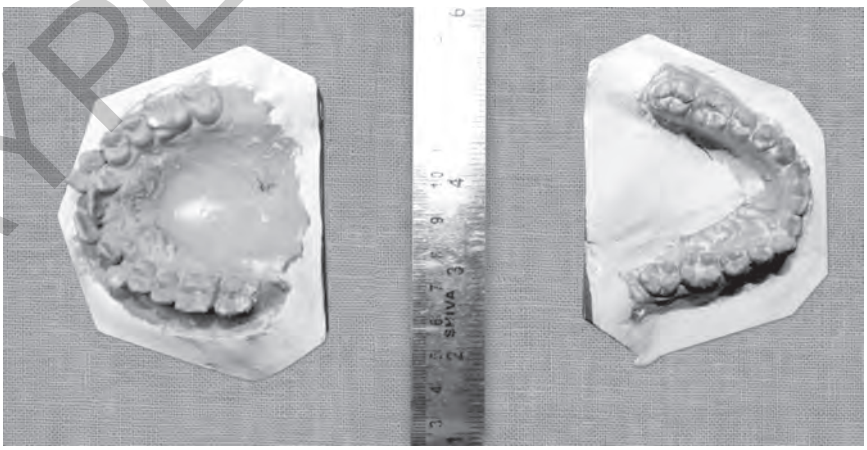

Figure 2.2: Plaster of paris models for analysis *(For color version see Plate 1)*

JAYPEE BROTHERS

DENTAL IDENTIFICATION

The justification for the identification of dead bodies, especially those resulting from mass disasters, has been constantly argued in the past, with opinion varying from such identifications being a public duty to the reference to Article 6 of the United Nations' Universal Declaration of Human Rights adopted by the United Nations General Assembly in 1948. The article states that 'everyone has the right to recognition everywhere as a person before the law'. The interpretation of one authority is that it is held to imply that a citizen of a United Nation member state has a right 'to possess his personal identity unquestioned', even after death, and the said article considered as an international law prescribes that the identification of the dead must be carried out whenever possible.

In general terms, the question of justification may be considered under the legal, social and forensic aspects. The legal aspect presumes that it is part of the law of most countries that a dead body must be identified prior to its disposal. Without a valid identity one must consider the ensuing legal problems of death certification, the disposal of the deceased's estate, and the considerable period of time before relatives can claim the accrued money on insurance policies or make claim for compensation where negligence may be involved in transportation accidents. In air disasters evidence is sought relating to the laws concerning simultaneous death or commorientes.

The social aspect of dental identification is concerned with the prevention of unreliable visual identifications being made by distressed and shocked relatives; that the deceased may be accorded the appropriate marks of respect in relation to religion, tradition, or custom; and that the period of natural grief suffered by the relatives may be considerably lessened.

Majority of identifications are made by visual means but it has been found even in normal circumstances that relatives are sometimes unable to identify the deceased person when their facial features are in repose in sleep. The advantage of dental identification is that the calcified dental tissues and the jaws appear to withstand a great deal more insult or trauma than the rest of the body can and comparisons are made on specific antemortem dental data, which obviate the necessity of relatives having to view a mutilated or fragmented body. When the body is correctly identified then the relatives are assured that the deceased is accorded the appropriate funeral rites demanded by religion, custom or tradition, or even superstition. The relatives reaction to grief may be prolonged if identity is not established and related to the period of time that the loved-one is 'missing' in the belief that one day he or she will return home or the disbelief that the loved-one is buried in a mass grave of unknowns. The psychological effects of prolonged grief are well reported and often it is the dental identification that convinces relatives and averts the possibility of the tendency to identify an unknown body.

The forensic aspect of dental identification includes homicide in which an early identification of the victim will lead to a prompt discovery of the associates of the victim. It is commonly stated that the majority of homicides are domiciliary and once the identity of the victim is established criminal charges may be brought in good time on apprehension of the perpetrator. In transportation accidents the positive identification can establish who is in charge of the vehicle or aircraft and where the passengers are seated whose injuries may provide evidence as to the cause of the incident. Furthermore dental identification plays an important role in bite mark investigation in cases of homicide, sexual assault and rape, non-accidental injury to children, burglary and housebreaking, and other incidents in which teeth marks are left at the scenes of crime.

Any identification procedure demands the accurate recording of the physical attributes of the unknown body or individual, together with the acquisition and detail of the personal effects associated with the unknown individual. From this evidence a full physical description of the unknown race,

JAYPEE BROTHERS

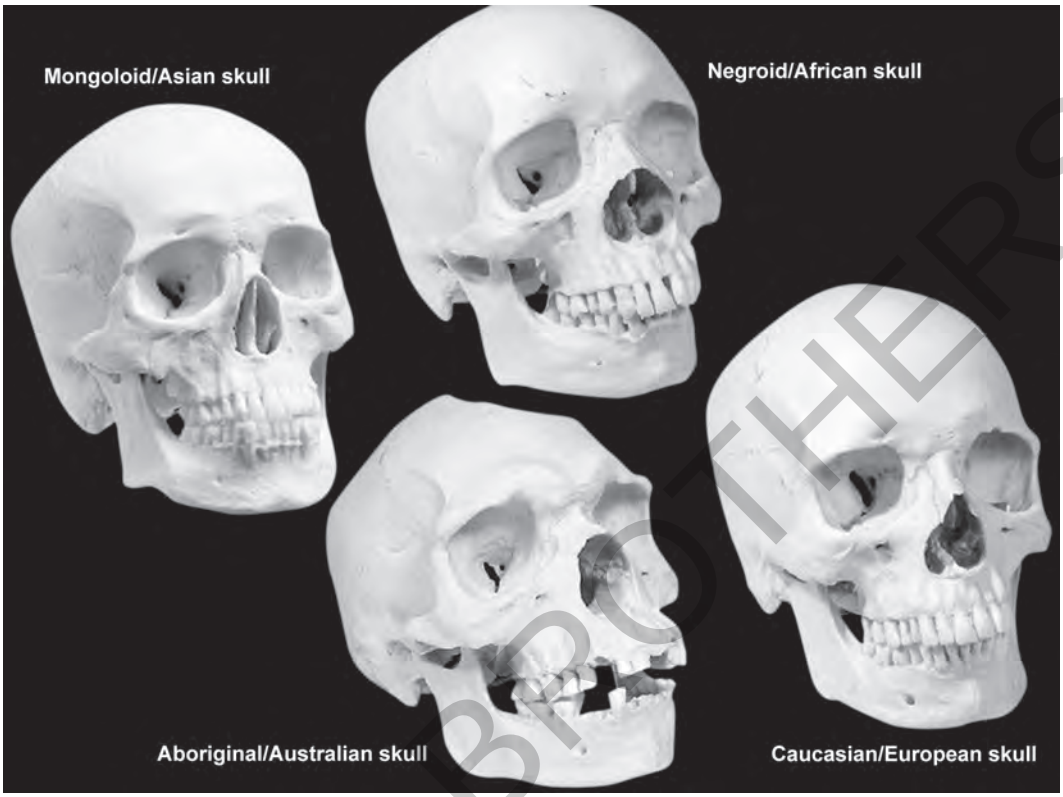

Figure 2.3: Racial characteristics of different skulls *(For color version see Plate 1)*

age anatomical abnormalities and pathological conditions, occupational and personal habits. It must be remembered, however, that clothing, documents, jewelery and other personal effects, although associated with a particular body, may be misleading in some circumstances especially in major incidents and mass disasters. The most distinctive features of the physical attributes are the personal characteristics of fingerprints and teeth and by these features alone a positive identification can be made.

The techniques of identification, therefore, can be divided into two groups—that of the reconstructive group and that of the comparative group.

The anatomist or forensic anthropologist will achieve an accuracy of 98% if the skeleton is complete, an accuracy of 95% on the pelvic bones alone, and an accuracy of 90% on the skull alone. Recovery of the long bones will result in 80% accuracy in sexing. In conjunction with sex determination is the evaluation of racial characteristics and there is copious information concerning the measurements, proportions and traits of Europi-from, Negroid, Mongoloid, Indian, Eskimo groups, etc. (Fig 2.3).

Individual skeletal characteristics, such as congenital and acquired abnormalities including acromegaly, achondroplasia, cleidocranial dysostosis and rickets may be present in the bones as may the presentation of healed fractures or 'spontaneous' fractures due to hyperparathyroidism or osteomyelitis, which may aid in the identification of the skeletal remains. This is the particular field of study of the forensic anthropologist as a member of the investigating team being somewhat

JAYPEE BROTHERS

neglected at present in may construe although being well recognized in the United States. The duties of such an expert extend from a site may have no forensic investigations, to the evaluation of sex and race when immature remains are recovered. There have been frequent occasions when art has been applied to science in the attempt to reconstruct facial soft tissues from the underlying bone in order to establish a visual means of identification. Various methods have been evolved over the years using the tables of soft tissue thickness of numerous authorities to establish the soft tissue reconstruction. An experiment often referred to is that of Krogman, in association with a sculptress, used modeling clay to mould facial features on a dried skull. It is not established how well the appearance of the model compared with the features of the known person in life but such a procedure was considered futile in predicting facial form from skeletal remains by one authority. However, with recent experience in the United States of a demonstration of similar methods being applied to homicide cases with some success, it would appear to provide a procedure to be considered when other methods of identification have failed.

It has been found in practice that the chronology of dental development is less variable than bone development and that the methods applied to particular periods of life provide more accurate indications of age. The three periods referred to are related to the dental development 'in utero' until just after birth, secondly up to the age of 14 years, which includes the deciduous and permanent dentitions and the replacement of the former by the latter, and thirdly from 14 years until the loss of all teeth and old age to the death of an individual. The assessment of age is inter-related with the sex and the race of the individual, and on comparison of dental development with osseous development of the hand it has been found that if the dental and osseous ages were similar then the individual was male, and if the osseous age was in advance of the dental age then the individual was most likely female. Skeletal development in the female can be in advance of the male up to one year while dental development may differ only from one to four months.

COMPARATIVE GROUP

Having established the prime characteristics of sex, race, age and the full physical description of the recently dead unknown body, or as much as skeletal remains will allow, the next phase of the procedure is to apply this information for comparison with ante-mortem data retrieved from various sources. In the circumstances of an air disaster the passenger list will provide a provisional schedule of identification from which relatives and concerned persons can give full descriptions and personal details of their loved-ones to the relevant authorities.

As a part of the normal police procedure that the entire scene is recorded photographically to relate the position of the body or bodies to particular locations and to each other. A plan or survey will be drawn which will indicate the relationship and distances of the bodies to other objects at the scene especially if those objects are of forensic interest such as weapons, articles of jewellery, clothing, utensils, displaced dentures, or fragments of natural teeth. Each can be placed in suitable plastic bags and labeled, and their position marked on the plan. This part of the procedure is usually under the direction of the senior police officer who is advised by the forensic pathologist. When the forensic pathologist has carried out his preliminary examination it may be possible for the forensic dentist to complete a dental charting prior to removal of the remains to the mortuary and evaluate the singificance of any displaced dental evidence associated with the remains. Occasionally, portable X-ray units may be available which will have the dual purpose of locating metal objects in the body if death by firearms or explosive devices is suspected, and the acquisition of standard radiographic views of the teeth and jaws, with the charting may lead to an early identification. Frequently the

JAYPEE BROTHERS

detnal examination may have to be delayed until the body arrives at the mortuary where conditions are more suitable and radiographic examination takes place subsequently in the laboratory or department where a fixed X-ray unit is available. The human remains are removed from the scene in a sealed plastic body bag in a special container so that any evidence associated with the body is not lost in transit to the mortuary. In the past it has been found that bodies recovered in water are not easily introduced into a body bag and should be wrapped and then sealed in plastic sheeting. When bodies are removed from sites or shallow graves an attempt is made to introduce a large wooden board to a depth of 6 inches under the body so that it remains relatively undistrubed on its earth surface in transit to mortuary and after the autopsy the earth can be shifted and examined for teeth, bone fragments and detached restorations. The site from which the body is recovered is carefully examined and searched for similar evidence that may have become detached from the body. The recovery of evidence from a scene is a highly specialized task and is usually the responsibility of a particular police officer who has considerable experience and training but who relies on the advice of the forensic pathologist, the forensic dentist, and other forensic experts who may have been called by the investigating officer. When bodies have been immersed for a considerable period of time the single rooted front teeth are lost irretrievably, unlike bodies from hard or earth sites where missing teeth may be recovered on careful search after removal of the body. Bodies which have been subjected to intense heat present charring of the facial bones and jaws, which may present a progression of damage from loss of enamel from the labial surfaces of the front teeth which are embedded in the substance of the tongue to extreme damage in which the entire anterior portion of the jaws is burnt away depending on the degree of intensity of heat. In some fire victims it is not always possible to dissect the facial tissues to expose the teeth to a normal dental inspection as manipulation will fragment the brittle or calcined bone and examination of this material is best left to radiographic investigation. At this stage of the investigation, if provisional identities of the human remains are known, the preliminary dental charting may confirm the identities from recent information concerning previous dental treatment submitted by relatives or friends during police enquiries. If a provisional identity is suspected it is relatively easy to establish either a positive identification or eliminate a possible identity. On some occasion the elimination of suspected identities is as useful as achieving a positive identification. With the completely unknown body it may take a number of years to retrieve the relevant information to establish a positive identification. In mass disasters exclusion processes are helpful in separating the known features of victims and therefore lessening the number of other bodies to be identified and on a few occasions have established positive identifications by the presence of physical peculiarities.

Another method that has been frequently used in the past is that of superimposition. However, it is not always possible to recover suitable photographs of individuals to compare with skulls or radiographs of unknown bodies and it is difficult to relate accurately anatomical landmarks to such photographs of the living. It has been found more appropriate recently to superimpose the irregularities of anterior teeth as presented in photographs with the anterior standing teeth of an unknown skull (Fig. 2.4).

Deontological system of identification has become fully recognized since the end of the second world war and in the experience of many authorities has provided the most consistent and accurate single means of identification. The classic example in which dental identification played an important role was the systematic identification of 118 bodies recovered from the fire on board the SS Noronic in Toronto Harbour in 1949. The routine procedure described has been found to be suitable for the investigation of single individuals and multiple victims and has probably formed the basis of the procedures adopted by disaster victim identification teams throughout the world since that time.

JAYPEE BROTHERS

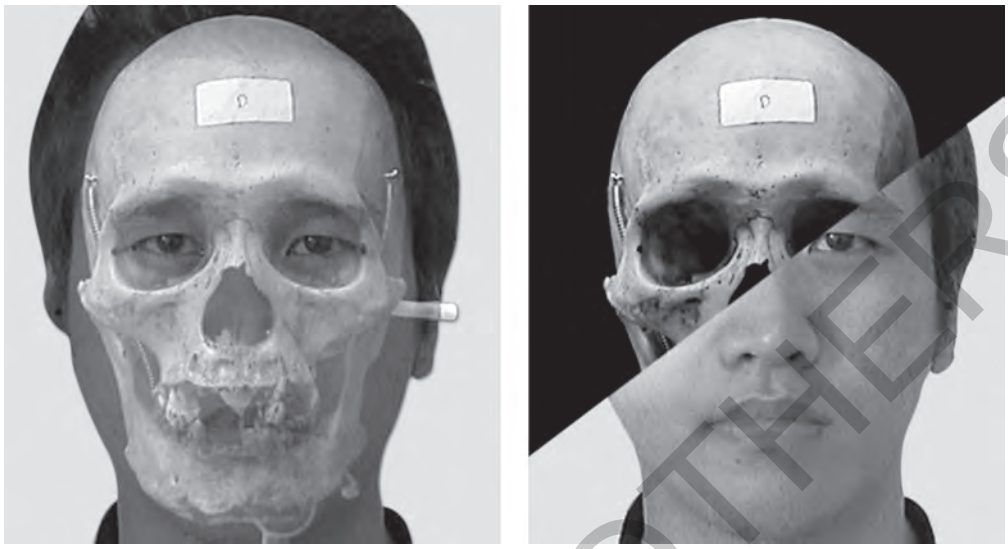

Figure 2.4: Comparison of skull of a person with the photograph
(***Source***: Jayaprakash et al, Health and Environmental Journal 2010)

The Scandinavian countries, and most notably Denmark, advocated the standing unit of the police officer, the forensic pathologist and the forensic dentist to be readily available at the very beginning of the investigation, having already adopted a system whereby the medical and dental records of missing person were collected after a specified period of time and retained at a central agency as precautionary registration of comparative data in the event of unknown bodies being recovered during routine investigations. More recently in the United Kingdom, the Metropolitan police have introduced a system in which a copy of a missing person's dental chart is obtained from that person's last known dental practitioner and to provide their original dental records in order to obtain a positive identification of the unknown body at best, or eliminate a number of suspected identities at worst. Obviously there is some concern within the professions regarding the confidentiality of medical and dental records when used for identification purposes. When practitioners are confronted with requests to provide original records of patient's treatment they seek guidance from their professional associations and protection societies, who will generally advise that if the records are to be used solely for identification purposes and no other than the practitioner's duty to society outweights a refusal to comply with the request on the grounds of confidentiality.

The routine procedure of the dental examination does not differ greatly from that carried out in normal dental practice other than the location in which the forensic examination takes place. It requires a meticulous attention to detail and the observations and findings must be reproduced in a form that is comprehensible to the police authorities, forensic colleagues and subsequently to Courts of Law. The forensic dentist may be requested to carry out the examination at the locus or scene in some circumstances but most often in the mortuary facility and subsequently in the laboratory if specialized techniques are required.

In order to carry out a dental examination for all situations that may be anticipated in forensic investigations it is necessary to provide oneself with a portable diagnostic set to be kept in readiness. The requirements of such sets have been described by a number of experts based on their personal

JAYPEE BROTHERS

requirements in the field. The basic set of instrument and equipment should be easily transportable by hand and weight should be kept to a minimum as some scenes may be inaccessible to all other means of travel other than on foot. Additional instruments and equipment may be readily available in the armamentarium of the mortuary if saws, knives and skull T-bar chisel are required, or may be borrowed from the forensic pathologist's set of instruments or that of the scenes-of-crime officer or his equivalent if resection of the jaws is contemplated. The simplest collection of diagnostic instruments and materials required for all forensic examinations include :

Normal diagnostic instruments, uiz., mirrors, probes and small forceps. In the past dental mirrors with a screw-in mirror face have proved useful since the mirror face can be mounted on the obtuse angle side of the mirror head for normal inspection of the oral cavity and on the acute angle side of the mirror head when the buccal surfaces of the upper molars are to be examined and access is limited by rigor mortis or 'heat stiffening' of burnt facial tissues. Another useful type of mirror is that supplied as part of a patient's oral hygiene kit (Privdent patients' mouth mirror). It provides a relatively large surface area and is cheap to buy and is disposable.

A diagnostic torch or illuminated mouth mirror. Conventional diagnostic torches are difficult to sterilize after use in forensic investigations and are relatively expensive to replace. There are diagnostic torches available at the present time which incorporate a miniature bulb on a flexible extension from a sealed battery container (Hoyt flexible examination light). This torch provides an adequate source of light in difficult areas of access without obstruction of vision. Sterilization is no problem as this torch is disposable and inexpensive to replace. Similarly disposable illuminated mouth mirrors are available as part of patient's oral hygiene kits. However, it has been found that the latter are of limited use as the mirror fitment slides too easily over the barrel of the torch.

Printed work cards. It is necessary to keep a reasonable supply of 6×4 inch cards commercially printed with the standard dental grid for use as work cards in the conditions which prevail at the locus or scene and in the mortuary. It is not always possible to have a colleague fill in the details at one's dictation and therefore keep the card unfilled. During the course of the examination the single operator will transfer blood, frat and other noxious material and will therefore contaminate the card as he fills in the dental data.

Polythene specimen bags and labels. The polythene bags should be of suitable size for individual teeth, bone fragments, dental impressions, and preferably self-sealing. In criminal cases and on some occasions in mass disasters labels will be supplied by police authorities but it is useful to maintain a personal supply of adhesive and tie-on labels.

Disposable impression trays and silicone or rubber base impression materials. Disposable trays weight considerably less than conventional metal trays and the use of impression materials incorporating a setting catalyst are preferable to the use of alginate which requires the availability of water. In addition, the setting time of alginate impression material is considerably prolonged in a cold cadaver.

Modelling wax, wax knife and spirit lamp. Modeling wax can sometimes be adequately softened by warming it in the hands and this materials is most commonly used in obtaining wax bite registrations in bite mark cases.

A polished metal tongue depressor. This instrument can be used as a wedge to gently ease open jaws in rigor, or reflect light into the oral cavity, or be used as a spatula to mix the impression materials.

JAYPEE BROTHERS

A plastic ruler. Graduated in inches and centimeters and of approved standard measurement and graduated 'Scotch tape' for photographic scales.

Protective clothing, viz., gown, disposable gloves and disposable plastic over-shoes. Ideally the self-contained operator should include a single lens reflex camera with flashlight and capable of close-up focussing, a small battery operated tape recorder, a battery operated ultraviolet lamp for bite mark investigation, and a portable X-ray unit, mains and battery operated (Bendix-Ray model 105). Polaroid land film and other types of self-processing radiographic film can be used with the aforementioned apparatus on site. Access to an automatic developer, or the use of dental radiographic film incorporating a filter dye allowing development in subdued light, are variations of processing which will produce speedy results.

In the mortuary

When the human remains have been removed to the post-mortem room, the body or bodies are carefully removed from their sealed recovery bags in order to begin the external examination. In investigations in which there is only a single body to examine this procedure and the subsequent autopsy will take place in an established facility of a public mortuary or a hospital mortuary. In major incidents and mass disasters the facility may only be a temporary one comprising of premises which have been commandeered for the purposes of coping with multiple bodies in an emergency. The premises may include school halls, aircraft hangars, warehouses, military and Red Cross tents, and even ice skating rinks. Such premises therefore may not be able to provide all the apparatus one would expect in a well-equipped mortuary and provision must be made to remove material and specimens for radiological and other investigations to more convenient places of study in forensic departments and laboratories. In a mass disaster investigation all the bodies must be retained in the one place until all the comparison procedures have been completed and the coroner or his equivalent has given permission for disposal.

The routine dental examination can take place at any time that is convenient during the course of the external examination providing that it does not impede the requirements of the forensic pathologist or the investigating officer. A dental charting may be obtained at the time the documents and clothing are removed prior to photography, radiography, or after autopsy, when specimens of the teeth and jaws may be removed for laboratory investigations. On numerous occasions the dental procedure can take place in body reception or in the laying out facility well away from the scene of other activity so that a detailed examination can take place by the operator and colleagues in undisturbed circumstances. The principle of making a dental identification is to record all the details of dental treatment, morphology and pathology, and oral characteristics, for comparison with the dental records of missing persons and reconstructive data from information from relatives if dental records are unavailable. The dental examination must take into account the following factors and oral characteristics :

Conservation and restorative dental work. Conservative dental work or fillings provides one of the most reliable means of identification and includes fillings of various materials, root fillings, inlays and crown and bridge work. These restorations are relatively permanent fixtures in the teeth and are generally well recorded on chartings and by radiographs.

When dental records of missing persons are retrieved it is hoped that they will include dental radiographs which will complete the details missing from the attenuated form of dental charting or provide visual additional information to unfamiliar forms of charting from other countries. It is

JAYPEE BROTHERS

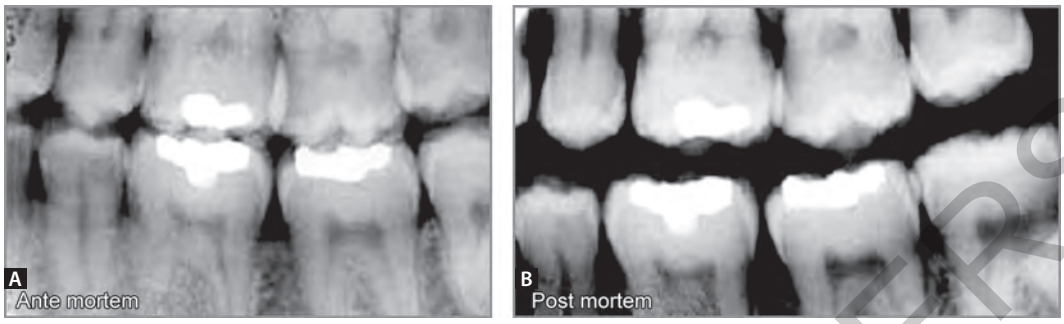

Figures 2.5A and B: (A) Ante mortem and (B) post mortem comparison of dental radiographs

generally found that the most useful radiographic evidence either in quality or quantity accompanies the dental records of patients who have received more complicated types of dental treatment. A single radiograph may present significant features which will positively identify an individual (Figs 2.5A and B) even though it has been recommended that a minimum of 12 concordant features be found on comparisons before a firm positive identification is accepted. A further example can be cited in which a radiograph presented root fillings in three roots of a single tooth which could be matched to the treatment of a known individual and the positive identity established. The success rate of comparative methods of identification depends upon the existence and retrieval of the ante-mortem dental records. In India no such regulation exists, however in the United Kingdom the period of time a dental surgeon is obliged to keep his records varies from four years in Scotland, to less than two years in England and Wales. In Sweden a dental surgeon must retain dental records for at least 10 years. Dental records are retained considerably longer in private practice, the dental schools of teaching hospitals, and the armed forces, but less than 18 months in the Dental Estimates Board of the National Health Service in England, due mainly to the almost astronomical numbers of records the authority has to deal with in each year.

Even if this process results in the recovery of the attenuated form of charting the name of the dental surgeon providing treatment will be included to whom application can be made to provide his practice records, which may provide considerably more information. If the body or bodies are completely unknown the police investigation will commence by interviewing dental practitioners in the local area in which the remains were found and then extending their search by collaboration with other police authorities in this country and abroad. The International Criminal Police Organization complies with constant requests for dental information concerning missing persons throughout the world and communicates the appropriate dental data using the FDI two-digit system. Other methods whereby dental information is requested are by the publication of the physical and dental features of unknown bodies in international dental journals and other professional publications and by the use of television media. Recently considerable interest has been expressed in the use of the standard telecopier and telephoto equipment for the rapid transmission of a wide variety of ante-mortem data. Many legal authorities will accept the ante-mortem data acquired by these methods for the purpose of identification and repatriation of the victims to their countries of origin but may require the Court Presentation of original records subsequently.

Partial dentures. Partial dentures are specifically designed to fit and augment a particular individual natural dentition. The denture teeth replaces the known missing teeth (by extraction) as presented on the charting and records of a particular person. In common with full dentures the construction

JAYPEE BROTHERS

of the partial denture can be described with regard to the material used for the base, either metal or acrylic plastic, and the material used for the teeth, either porcelain or acrylic plastic and of particular mold shape and shade. The metals used in the construction of partial dentures of skeletal design are chrome/cobalt alloys, gold alloys, and now less commonly dental plates of stainless steel, and will include the valuable identifying features of occlusal rests clasps and with modern technique, precision attachments. These latter features can be specifically related to individual teeth even if the partial denture is found separate from a fragmented jaw in the circumstances of an air disaster. The plastic material used in the construction of a denture base and gum work may be colorless, pink or stippled. Therefore, the description of the partial denture taken in conjunction with the dental charting of the restorative work provides an important means of establishing the identity of an individual.

The case relates to the murder of a 27-year-old lady in an isolated rural area while she was going for work on 09.09.2002.The postmortem report revealed deep injuries to head and neck due to stabbing. The investigation could not make any break through as there were no eyewitnesses or scientific evidence. The only object obtained from the scene of crime was a partial denture. The suspect was a 59-year-old neighbor who used to accompany her quite often. The Crime branch approached the Government Dental College, Calicut on information of possible identification of the partial denture wearer using forensic odontology methods.

The Department of Prosthodontics made impressions and study models of the suspect's jaws.

Detailed intraoral clinical examination of the suspect revealed missing upper right central incisor. Upon construction of plaster model of suspects arch and comparing it with missing partial denture it was found that the denture perfectly adapted in his missing tooth space and the impression of gingival cleft which was present in denture was also found to be matching with suspects gingival clefts. Suspect was identified and sent for custody.

Full dentures. The provision of a full denture implies the artificial replacement of teeth in an edentulous jaw but does not obviate the possibility of the presence of buried roots or unerupted teeth in that jaw which may only be suspected during the radiographic investigation. Individuals can present combinations of full dentures opposed by natural teeth, or full dentures opposed by partial dentures and natural teeth, total full dentures, or no dentures at all. Full dentures are constructed with the same metal and plastic materials already described, and the possibility of being faced with a vulcanite plate with porcelain teeth in the mortuary nowadays is quite remote. Other identifying features will include the presence of gumwork or its absence anteriorly if the denture was an immediate insertion on extraction of anterior teeth, and the presence of relief areas on the palatal fitting surface of the upper denture. In contrast with partial dentures a degree of suspicion must be reserved when full dentures are found separate from the unknown body. In the edentulous person the alveolar processes are being constantly resorbed during life and therefore the original fit of a full denture deteriorates. The period of time that elapses before the denture apparently becomes loose and ill fitting to the wearer varies with each individual and in fact the effective life of a full denture is considerably less than the patient supposes. The living person tends to cope with the increasing looseness quite automatically and unconsciously until the patient is fully aware of the looseness and seeks provision of a new denture. When the separate full denture is placed in the mouth of the unknown body it may appear to have no relationship in the first instance and it is advisable at this juncture to take impression of the jaw in order to produce a dental stone study model. By this method the morphology of the alveolar process of the jaw can be compared with the fitting surface of the denture to evaluate a favorable or unfavorable match. In the experience of many dental practitioners

JAYPEE BROTHERS

it is not a rare situation to be told by a patient that they are wearing another person's denture, or that some unfortunate patients have been fitted with the wrong dentures without apparent ill-effects. To prevent the latter occurrence it has become established procedure in busy dental laboratories to inscribe a work number or some indication of the patients' name on the stone production model which is then transferred in processing to the plastic material of the denture. This mark therefore provides a valid identifying feature if found on the denture of an unknown person but many dentures have had the mark erased due to irritation to the wearer when placed on an unsuitable fitting surface. The possibility of marking all dentures for the purpose of identification has been fully discussed over many years. The materials recommended vary from metal tape (originally dental matrix band) on which the identifying mark can be typed on a typewriter set on stencil cutting, to absorbable tapes of linen, nylon or paper which become incorporated in the denture during processing. Metal tape has the disadvantage of having to be inserted into the finished denture and, apart from causing mechanical weakness, the process of insertion may be unacceptable to the patient.

The marking of teeth has now extended into the field of conservation and restorative techniques. One method describes the insertion of a personal dental identifier or information carrier composed of alumina substrate approximately 1.27 mm^2 in dimension with the data recorded in a microminiature mode. The carrier is placed in the prepared tooth cavity prior to the insertion of the filling and its presence can be indicated to the investigator subsequently by a radiographic disclosure pin placed elsewhere in the tooth. The disclosure pin must be suitably modified to prevent its confusion with normal restorative pin techniques. It is claimed that the disclosure pin is easily recognisable during the radiographic investigations in mass disasters and eliminates the lengthy procedures of conventional examination and ante mortem and postmortem comparisons. Another method describes the placement of an encoded information chip sealed within the tooth enamel by a fire resistant filling of red composite material. The information chip consists of a small gold disc approximately 2 mm in diameter on which alphanumeric characters are engraved by an electro-mechanical engraver using the memory facility of a microprocessing unit. The colored composite and fire-resistant filling visually indicates the presence of the gold disc to the forensic expert during oral examination of the unknown body.

All of these methods of marking dentures and natural teeth are potentially useful especially when intact and untraumatized bodies are recovered but in the conditions which prevail in high-speed transportation accidents most bodies present extreme trauma to the facial tissues and facial skeleton and sometimes only single teeth and portions of dentures are recovered. The possibility of recovery of the specimens carrying the identifying marker on all occasions and on all bodies is extremely remote and therefore the basic method of full dental examination and comparison of postmortem findings with antemortem data is still the most reliable method of dental identification.

Sex. Until recently the sexing of teeth has had to be assessed in relationship to the bones of the jaw in which they are attached but various techniques are now utilised in sexing individual teeth remote from the jaws. It has been reported that the mandibular canine tooth exhibits the greatest sex difference by reason of its overall greater dimension in the male when compared to the female. By assessment of the width alone measurement permitted a 74% accuracy of sex determination. Attempts have been made to determine sex by the histological examination of the neonatal line in group sections of the permanent first molar teeth, and by chromosome staining methods in order to identify the male F body in the Y chromosome of pulp cell nuclei even months after extraction. The dental pulp findings can be supplemented by cellular material recovered from saliva since F bodies are consistently shown in a high percentage of trapped male cells in contrast with few cellular remnants recovered from female saliva.

JAYPEE BROTHERS

Race. A general knowledge of the florid racial characteristics of teeth are an asset to the forensic dental expert but it is in reality the specific field of the forensic anthropologist. Probably the most distinctive racial characteristic is the 'shovel-shaped' incisor. This feature occurs in 95% of American Indians, 91% of Chinese, and approximately 50% of the Palestinian Arab population. The Mongoloids present enamel pearls on the occlusal surfaces of premolar teeth, while Prima Indians present paramolar protostylid cusps. Australoid and South African populations exhibit a high proportion of tall pulpal chambers or taurodontism. Mandibular exostoses are present in a high proportion of Aleuts and maxillary exostoses are present in high percentages of Icelanders and Eskimos.

Age. The importance of the role of age assessment in dental identification is well recognised and is a specific field of study that is best left to laboratory techniques and methods. However, during the course of the dental examination at the scene or locus or in the mortuary, a provisional age assessment can be made based on the clinical experience of the dental expert in relating attrition and level of gingival attachment and other factors in patients of known age.

Morphology. There are normal variations in the shape of teeth which have to be appreciated during the dental examination of separate individual teeth. In most circumstances it is relatively easy to identify a particular tooth and conclude whether it is mandibular or maxillary and from which side of the jaw. On examination of the natural teeth in situ some teeth may be missing as a result of a condition termed as partial anodontia in which certain tooth groups, viz., upper lateral incisors, lower second premolars, and third molars, may usually be accounted for by a history of previous extraction or not erupted. On many occasions the cuspal pattern of molars can be misleading if some molars are missing or not present in sequence. It is advisable to request a dental colleague to express his opinion on the identification of first, second and third molars as minor discrepancies are often encountered on comparison of the postmortem charting with the ante-mortem records submitted by dental surgeons. The presence of unerupted or impacted third molars can be determined by the radiographic investigation. Other congenital defects encountered are those produced by osteogenesis imperfecta and the related amelogenesis imperfecta and dentinogenesis imperfecta. Upper lateral incisors are often peg-shaped, and congenital syphilis presents defects in the upper central incisors which are broader at the cervix at gum level than at the incisal edge, and which usually exhibit an elliptical notch (Hutchinson's incisors) and multicuspal molars (Moon's molars). On some upper first molars there is an accessory cusp on the palatal surface which is termed the Cusp of Carabellia and is an identifying feature of the upper first permanent molar.

Acquired defects may be accounted for by habits and occupation of the individual. Notched incisors can be attributed to hairdressers opening hairpins with their teeth or seamstresses opening hairpins with their teeth or seamstresses biting thread, and formerly cobblers and carpenters constantly gripping nails or tacks between their teeth. Pipe smokers produce marked attrition on opposing teeth on the side of the mouth where they prefer to grip the pipestem for maximum comfort.

Pathology. Individuals who persistently hold boiled sweets or peppermints in the buccal sulcus adjacent to the upper molar teeth present marked cervical decay whilst workers in sugar refining factories present marked cervical decay on the labial cervical surfaces of the upper front teeth. Drug addicts are reported to exhibit marked decay on all teeth as a result of craving for sweet things on removal of the source of their addiction and similar marked decay is attributed to over indulgence of highly sweetened cordials and soft drinks as well as ice lollies or Popsicles. The acid erosion of teeth is encountered as a presenting symptom of hiatus hernia, as well as that caused to the teeth of workers in chemical factories where acid concentrates are produced. Systemic disturbances

JAYPEE BROTHERS

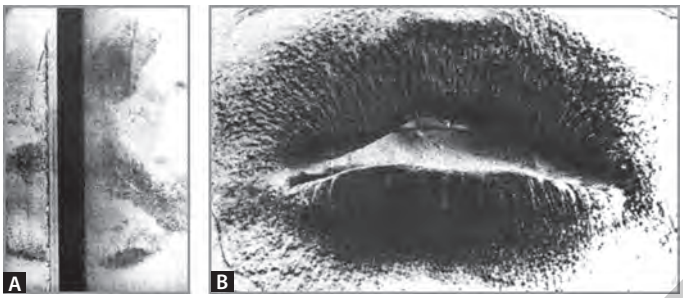

Figures 2.6A and B: Photograph of lip print on a door frame (A); Compared to an impression of the lips the accused person (B)

following infection by measles or mumps in childhood often affect the normal development of the permanent teeth and hypoplastic pits in pairs of teeth or opposing teeth.

Color. Teeth have a natural coloration that appears to darken with age which may be intensified by poor oral hygiene, tobacco staining and tartar. However intrinsic and extrinsic factors are responsible for producing a wide variation of colors. Of the intrinsic factors the presence of pink teeth is worthy of note. It was first recorded by Bell and its significance was not fully appreciated until 1953 when a murder victim presented this sign and a relationship was suspected with carbon monoxide poisoning. The question was not resolved at that time and the cause of the pinkness of teeth in the cervical region was thought to be a post-mortem breakdown of red blood corpuscles within the pulp chamber and the altered blood diffusing through the dentinal tubules to appear on the surface of the tooth. Pink teeth have been attributed to asphyxial causes of death but it has been observed on many occasions in the post mortem room with no significance attached to the cause of death. It is also observed in bodies removed from moist conditions and recent research has been in progress to identify specific substances causing the pink color.

In areas of the country where natural fluoride is in high proportion in the water supply endemic fluorosis produces brown stains in the teeth.

A yellow discoloration is sometimes observed on the anterior teeth of children and can be related to tetracycline treatment at the time of development of the crown of the tooth. Purple or blue-stained teeth have been reported in cases of leprosy.

Extrinsic factors include poor oral hygiene with the build-up of dental plaque and subsequent formation of stained tartar which incorporates numerous substances. Tobacco, tea and coffee contribute to dark staining and mercury poisoning is reported to produce a green stain below gum level due to the presence of sulpho-methalmoglobin.

Palatal rugae; rugoscopy. The pattern of the palatal rugae was at one time considered to be of great importance in identification, especially if study models or photographs were taken of the pattern as precautionary registration of data. This procedure was carried out in a number of South American countries and the details of the rugae entered on the odontogram of an individual's criminal records.

Lips; cheiloscopy. The fissures and grooves on the lips are claimed to be characteristic of the individual and a number of experts believe that lip prints can be of value in identification. However in a recent murder investigation in Essex, lip prints were found on a door frame at a murder scene. In spite of exhaustive studies by photography, rubber base impressions of the lips of the suspect, and further lip prints of the suspect, no similarities could be demonstrated in the fissures and grooves but only in the general outline and dimension of the lips of the suspect (Figs 2.6A and B).

JAYPEE BROTHERS

for detailed information on dental books, visit our website **www.jaypeebrothers.com,** for detailed information on dental b

Handbook of Forensic Odontology & Medical Jurisprudence

The *Handbook of Forensic Odontology and Medical Jurisprudence* is a concise handbook for dental undergraduates and practitioners which provides brief and up-to-date information involving important facets of forensic odontology and medical jurisprudence. Important topics covered in this book are described in a very simple language along with discussion of a few related medicolegal cases.



Richik Tripathi BDS MDS (Oral and Maxillofacial Surgery) is Research Scholar, Faculty of Dental Sciences, Institute of Medical Sciences, Banaras Hindu University, Varanasi, India. He was Consultant Oral and Maxillofacial Surgeon at Heritage Hospitals, Varanasi and Service Senior Resident, Division of Oral and Maxillofacial Surgery, Faculty of Dental Sciences, Banaras Hindu University, Varanasi. He has attended several workshops; presented papers in national and international conferences; and also attended several national and international conferences. He has written several articles in national and international journals and one chapter in a book.

Available at all medical bookstores
or buy online at www.jaypeebrothers.com

JAYPEE BROTHERS
Medical Publishers (P) Ltd.
www.jaypeebrothers.com

Join us on facebook.com/JaypeeMedicalPublishers

Shelving Recommendation
DENTISTRY

ISBN 978-93-5250-152-6