brothers.com, for detailed information on anatomy books, visit our website www.jaypeebrothers.com, for detailed information on anatomy boo

Jaypee Gold Standard Mini Atlas Series®

EMBRYOLOGY



2nd Edition

Roopa Kulkarni
Varsha S Mokhasi

JAYPEE

Foreword
HR Krishna Rao

JAYPEE GOLD STANDARD® MINI ATLAS SERIES

Contents

1. Human Embryology **1**

• Terms Used in Embryology *1* • Spermatogenesis *3* • Oogenesis *6* • Uterine Cycle *10* • Corpus Luteum (Corpora Lutea) *12* • Capacitation or Activation of Sperm *15* • Fertilization *16* • Blastocyst *18* • Trophoblast *19* • Implantation *21* • Decidua *22* • Twin Pregnancy *26*

2. Fetal Membranes **30**

• Amnion *30* • Yolk Sac *32* • Extraembryonic Celom *35* • Allantois *36* • Connecting Stalk *38* • Umbilical Cord *39* • Chorion *41* • Placenta *44*

3. Development of Third Week of Life **50**

• Primitive Streak *50* • Development of Notochord *54* • Formation of Neural Tube *55* • Neural Crest *56* • Somites *59* • Embryonic Folding *61* • Derivatives of Germ Layers *64*

4. Developments in Fourth Week and Onwards **67**

• Branchial Apparatus *67* • Pharyngeal Arches *68* • Pharyngeal Pouches *69* • Development of Face *73* • Development of Palate *79* • Development of Tongue *81* • Development of Respiratory System *82* • Development of Heart *89* • Aortic Arches and Derivatives *99* • Fetal Circulation *103* • Gut Development *108* • Urogenital Sinus *118*

• Urinary System *119* • Female Reproductive Organs: Fallopian Tubes, Uterus, Vagina and Ovary *124*
• Development of External Genitalia *133*
• Development of Nervous System and Special Senses *137*
• Histogenesis of Nervous Tissue *139*
• Basal Lamina *147* • Alar Lamina *148*
• Special Senses *150* • Development of Endocrine Glands *158*

Index *165*

Chapter 2

Fetal Membranes

Fetal membranes include the following:

- Amnion
- Yolk sac
- Extraembryonic celom
- Allantois
- Connecting stalk/Umbilical cord
- Chorion
- Placenta.

AMNION

Amnion is a thin, tough, fluid filled, membranous sac that surrounds the embryo and the fetus. It is attached to the margins of the embryonic disc.

The amniotic sac contains the **amniotic fluid**, which help keep the baby warm and keeps the baby's growing body parts from fusing together.

To **begin with**, the amniotic fluid is a **transudate** of the maternal plasma and becomes more like the fetal fluids only in the presence of the fetus. When the fetus is removed, the fluid remains similar to maternal plasma.

JAYPEE BROTHERS

The origin of amnion is controversial:

Whether it develops from **embryoblast** as **amniogenic cells** and these cells separate out from epiblast and surround the space called amnion or the **trophoblastic cells differentiate into amniogenic** cells or due **delamination of embryoblast and trophoblast from each other** to enclose a slit which becomes amnion.

As amnion enlarges, it gradually obliterates the chorionic cavity (extraembryonic celom) and forms epithelial covering of umbilical cord.

Amniotic fluid plays major role in fetal growth and development.

The fluid is initially secreted by amniotic cells fluid is derived from the maternal tissue and by diffusion across amnio chorionic membrane from decidua parietalis. This is followed by diffusion of fluid through chorionic plate from blood in the intervillous space of placenta.

Before keratinization of the skin, diffusion of water and solutes from fetus to amniotic cavity is through skin, thus the fluid is similar to tissue fluid. The other sources of amniotic fluid are:

- Respiratory tract
- Excreted urine by the fetus (about 300–400 mL).

  By late pregnancy half a liter of urine is added daily.

  The volume of amniotic fluid—30 mL at 10 weeks.

  350 mL at 20 weeks. And about a liter by full term.

Composition of amniotic fluid:

- 99% water
- 1% organic and inorganic substances.

Half of the organic constituents are proteins, the remaining half consist of carbohydrate, fat, enzyme, hormones, pigments and desquamated epithelial cells.

JAYPEE BROTHERS

Applied Anatomy

- Amniocentesis
- Oligohydramnios
- Polyhydramnios.

YOLK SAC (FIGS 2.1 AND 2.2)

Formation and Boundaries

It is the cavity of the **blastula (blastocele)**, after the formation of the first germ layer called the **hypoblast**. It begins as primordial or **primary yolk sac (Fig. 2.1)**.

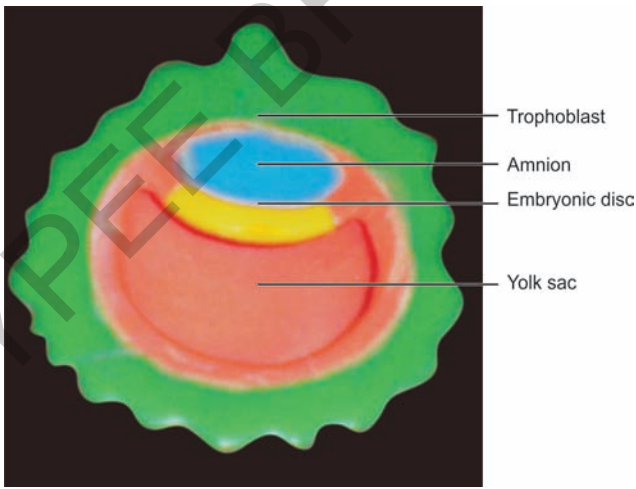

Fig. 2.1: Yolk sac (primary)

JAYPEE BROTHERS

The primary yolk sac becomes smaller when the extra-embryonic mesoderm is formed and is called **secondary yolk sac**.

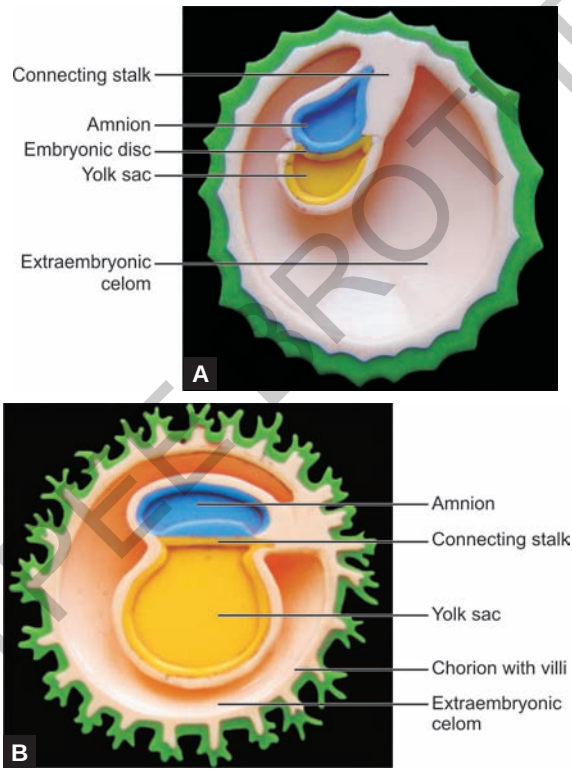

Figs 2.2A and B

JAYPEE BROTHERS

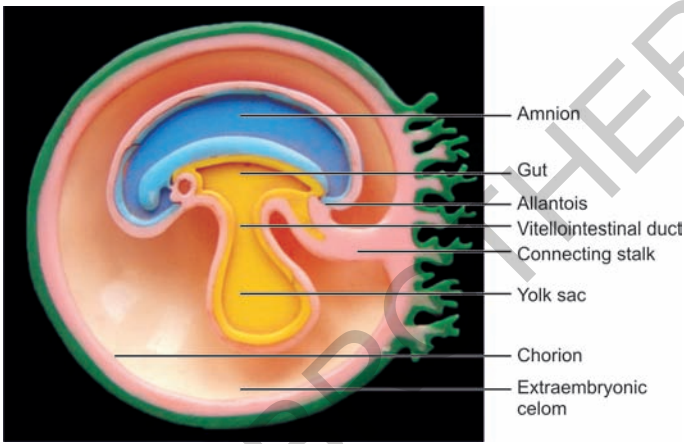

Fig. 2.2C

Figs 2.2A to C: Extraembryonic celom, yolk sac, amniotic cavity and connecting stalk

After the formation of the extraembryonic celom, the secondary yolk sac is further reduced in size. Part of the secondary yolk sac is pinched into the mid gut when the foldings of the embryo and formation of gut tube take place. It is then called the **definitive yolk sac**. The narrow, compressed part of the yolk sac which connects the distal small yolk sac and the mid gut is termed the **vitellointestinal duct (Figs 2.2A to C)**.

Functions

- Nutrition
- Primordial germ cells formation

JAYPEE BROTHERS

- Production of blood in the wall of the yolk sac
- Takes part in the formation of primitive gut tube.

Fate of Yolk Sac

- By the 10th week, it is very small and lies between amniotic and chorionic sacs.
- It atrophies as the pregnancy advances.
- In abnormal conditions, the yolk stalk may persist and give rise to **Meckel's diverticulum**.

EXTRAEMBRYONIC CELOM (FIGS 2.2A TO C)

It is the space in the extraembryonic mesoderm, which is also called **chorionic sac**.

Number of small, isolated spaces appear in the mesoderm, increase in size and all of them rapidly fuse to form a large, isolated cavity—the **extraembryonic celom** (EEC).

This fluid filled extraembryonic celom gradually surrounds the embryonic disk, yolk sac and amnion except where they are attached to the chorion by connecting stalk. Due to the increasing size of the extraembryonic celom, the primary yolk sac decreases in size and a smaller secondary yolk sac is formed **(Figs 2.2A to C)**. The EEC splits the extraembryonic mesoderm into an **outer** layer called **extraembryonic somatopleuric mesoderm** and an **inner** layer called the **extraembryonic splanchnopleuric mesoderm**.

Extraembryonic splanchnopleuric mesoderm surrounds the yolk sac.

The extraembryonic somatopleuric mesoderm lines the trophoblast and amnion. Along with trophoblast it forms **'Chorion'**.

JAYPEE BROTHERS

Thus, the chorion forms the wall of the chorionic sac within which embryo, amnion and yolk sac are suspended by connecting stalk. Therefore, extraembryonic celom is called chorionic cavity.

Transvaginal ultrasound (endovaginal sonography) is used to measure chorionic sac diameter. This measurement is valuable in evaluating early embryonic development and pregnancy.

Gradually amnion grows in size and expands into extra-embryonic celom.

ALLANTOIS (FIGS 2.3A TO C)

Formation

On 16th day, a sausage shaped diverticulum arises from the **caudal wall of yolk sac**, which extends into the connecting stalk. This is called **allantois**.

It remains very small in human embryos.

During the 2nd month, the extraembryonic part of the allantois degenerates and a portion extends into connecting stalk **(Figs 2.3A to C)**.

The allantois gets incorporated into ventral wall of hind gut after the foldings of the embryo.

The postallantoic part of the hind gut forms cloaca.

Functions

- Blood formation between 3rd and 5th week of IUL.
- Development of umbilical vessels.
- In reptiles, birds and mammals it has respiratory function and acts as reservoir for urine.

JAYPEE BROTHERS

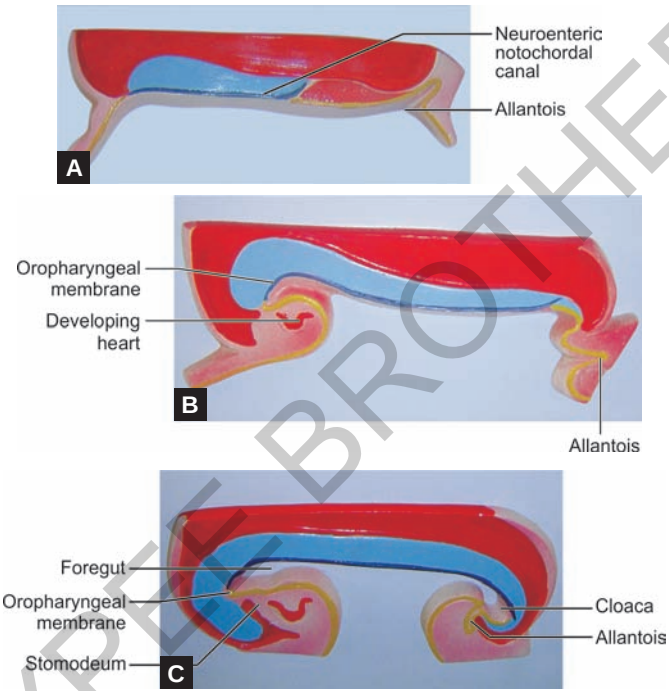

Figs 2.3A to C: Allantois

Fate

It extends between urinary bladder and umbilicus. As the bladder enlarges, the allantois involutes to form urachus. Later on, the urachus degenerates to form median umbilical ligament.

JAYPEE BROTHERS

CONNECTING STALK (FIG. 2.4)

On 14th day, the embryonic disc with its amnion and yolk sac becomes suspended in the chorionic cavity by a thick layer of mesoderm, which elongates to form the connecting stalk **(Fig. 2.4)**. The mesoderm consists of both parietal and visceral extra-embryonic mesoderm. It is gradually lined by the extraembryonic celomic epithelium. It elongates and forms umbilical cord that connects the fetus to the mother.

The umbilical cord begins to form in about 5 weeks after conception.

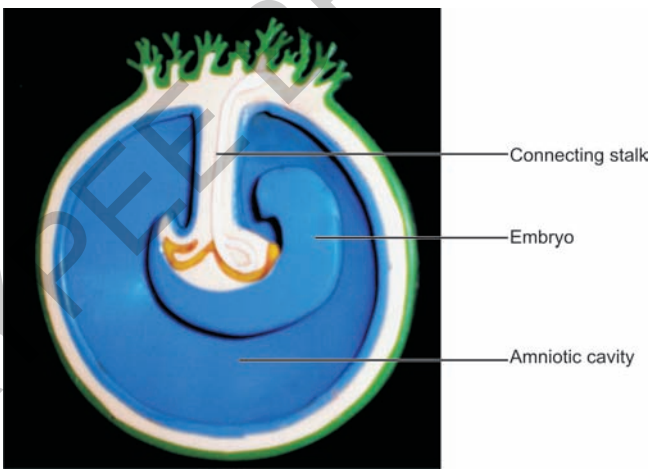

Fig. 2.4: Amniotic cavity and connecting stalk

JAYPEE BROTHERS

UMBILICAL CORD

The connecting stalk becomes progressively longer until about 28 weeks of pregnancy, reaching an average length of 22 inches. As it gets longer, the cord generally twists around itself and becomes coiled. Gradually the allantois gets incorporated. The umbilical vessels, vitelline vessels are incorporated. The mesoderm will have contribution from both intraembryonic and extraembryonic mesoderm.

It is the cord that connects the fetus to the mother. It is a twisted cord, which carries blood to and from the placenta.

Length: 50 cm (Ranges from 20 cm to 120 cm).

Diameter: 1 to 2 cm.

The umbilical cord is a narrow, tube-like structure that connects the developing fetus to the placenta.

The umbilical cord delivers nutrients and oxygen for the normal growth and development. It also removes waste products.

It consists of:

An outer covering of amniotic membrane.

An interior mass of mesoderm derived from:

- Somatopleuric extraembryonic mesoderm covering amniotic membrane.
- Splanchnopleuric extraembryonic mesoderm of yolk sac.
- Splanchnopleuric extraembryonic mesoderm of allantoic duct and umbilical vessels.
- Yolk duct and allantoic duct.
- Vitelline and umbilical vessels.
- Remains of extraembryonic celom.

The amniotic membrane is made up of epithelial cells which are simple squamous or cuboidal cells.

JAYPEE BROTHERS

The mesodermal core, from different sources, fuses and gradually transformed into viscid, mucoid connective tissue which is called 'Wharton's jelly'.

It consists of:

- Widely spaced fibroblasts (with branching processes) separated by extensive intercellular space which is filled with
- Copious matrix consisting of delicate, three dimensional meshwork of fine collagen fibers surrounded by
- Dilute ground substance (with a variety of hydrated mucopolysaccharides).

Yolk and allantoic ducts slowly degenerate and disappear. Only interrupted cords of cells may be seen.

Vitelline vessels atrophy in the region of the umbilical cord.

Umbilical vessels are—2 arteries and 2 veins—right and left.

The right umbilical vein disappears in the early months of gestation.

The vessels are twisted- in right or left handed cylindrical helix **(Fig. 2.5)**.

The number of twists or turns may exceed 300.

They are due to unequal growth of vessels and torsion forces imposed by fetal movements.

The arteries are medium sized, muscular arteries.

The external layers of tunica media of the arteries pursue oblique/spiral course.

Contraction produces shortening of vessels and thickening of tunica media. The pulsations of the umbilical arteries assist venous return to fetus through umbilical vein. This leads to folding/bulging of tunica intima which narrows the lumen and act as valves during pulsation.

JAYPEE BROTHERS

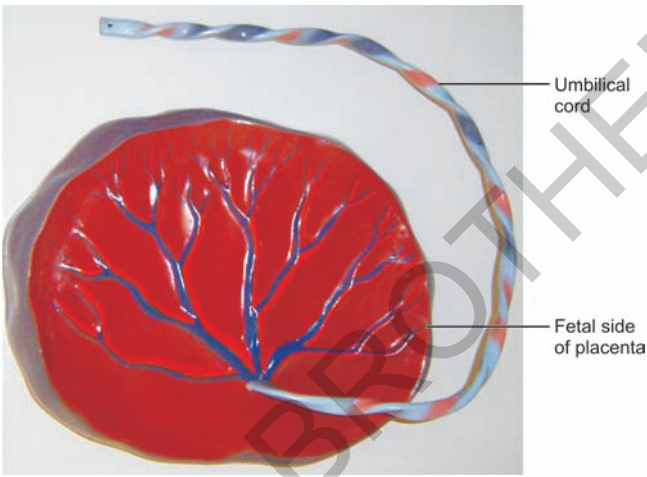

Fig. 2.5: Umbilical cord and placenta

These foldings are called 'Valves of Hoboken'.
Cord exhibits knots. They are:

- **True knots**—due to fetal movements.
- **False knots**—due to sharp variation in contour due to excess accumulation of Wharton's jelly.

CHORION

Formation

The trophoblast and the somatopleuric extraembryonic mesoderm is called the 'chorion'.

JAYPEE BROTHERS

for detailed information on anatomy books, visit our website www.jaypeebrothers.com, for detailed information on anatomy books, visit our we

Jaypee Gold Standard Mini Atlas Series®

EMBRYOLOGY

Salient Features

- It is a very simple book for medical and paramedical undergraduates
- Contains simple and lucid language, which helps students from other medium of instructions for easily understanding the basics of embryology
- Includes the photographs associated with anatomy for students to understand, remember and reproduce in both theory and practical examinations
- It is very useful book, easy to understand and easily reproducible.



Roopa Kulkarni completed MBBS (1976) from Mahadevappa Rampure Medical College, Kalaburagi, Karnataka, India. She joined the Department of Anatomy, Mahatma Gandhi Institute of Medical Sciences, Sevagram, Wardha, Maharashtra, in 1978 and completed postgraduation in1981. She joined as Lecturer, MS Ramaiah Medical College, Bengaluru. Teaching is her passion and enjoys every moment of teaching, favorite subjects being Histology, Embryology, Osteology, and Neuroanatomy. She is Member, Editorial Board of International Journal of Anatomy and Research; Life Member, Indian Medical Association; Anatomical Society of India; Karnataka Chapter of Anatomists; Academy of Medical Specialties; Indian Society of Human Genetics; Society of Clinical Anatomists. She has been published more than 40 scientific papers in the international, national and state journals. She is Reviewer for a few international and national journals. She is a recognized Teacher and Guide for MD (Anatomy) and PhD (Anatomy) by Rajiv Gandhi University of Health Sciences (RGUHS), NTR University of Health Sciences (NTRUHS), Maharashtra University of Health Sciences (MUHS), Pondicherry University, and many more deemed universities in and out of Karnataka. She was awarded twice as Best Teacher on Doctors' Day and on World Women's Day in the college.



Varsha S Mokhasi completed MBBS (1986) from Karnataka Medical College, Hubballi and postgraduation (1994) from Bangalore Medical College, Bengaluru, Karnataka, India. She has served in various capacities from Lecturer to Professor, MS Ramaiah Medical College, Bengaluru, and presently working as Professor and Head, Department of Anatomy, Vydehi Institute of Medical Sciences and Research Center, Bengaluru. She has many publications to her credit. She is Life Member, Indian Medical Association; Anatomical Society of India; Karnataka Chapter of Anatomists; Academy of Medical Specialties; Indian Society of Human Genetics; Society of Clinical Anatomists. She is a recognized Teacher and Guide for MD (Anatomy) and PhD (Anatomy) by Rajiv Gandhi University of Health Sciences (RGUHS), NTR University of Health Sciences (NTRUHS), Maharashtra University of Health Sciences (MUHS), Pondicherry University, and many more deemed universities in and out of Karnataka.

Available at all medical bookstores
or buy online at www.jaypeebrothers.com

JAYPEE BROTHERS
Medical Publishers (P) Ltd.
www.jaypeebrothers.com

Join us on facebook.com/JaypeeMedicalPublishers

Shelving Recommendation
ANATOMY

ISBN 978-93-5250-159-5