medicine books, visit our website **www.jaypeebrothers.com,** for detailed information on medicine books

Made Easy®

2nd Edition

CLINICAL MEDICINE

Made Easy®

TV Devarajan
L Vijayasundaram



JAYPEE

Contents

1. Introduction to Clinical Medicine..... 1

2. General Examination..... 3

Examination of the Skin..... 3
Hirsutism..... 5
Madarosis..... 5
Flag Sign..... 5
Hypertelorism..... 6
Low-set Ears..... 6
High-arched Palate..... 7
Eyes..... 7
Characteristic Facies..... 9
Stature..... 10
Hands..... 10
Legs..... 14
Painless Ulcer of Foot..... 14
Nourishment..... 14
Chest..... 15
Self-assessment Questions for Clinical Medicine..... 16

3. Cardiovascular System Examination..... 20

Case Recording Format..... 20
I Preliminary Data..... 20
II Chief Presenting Complaints..... 20
III History Presentation in Detail..... 20
IV Physical Examination..... 28
V Diagnosis..... 32
VI Management..... 33
Cardiovascular System..... 33
Quick Review of Signs and Symptoms..... 42

Anatomical Landmarks in Cardiovascular System 42
Physiological Events that May Alter Cardiovascular System Findings 44
Cardiac Cycle 45
Symptomatology 46
Prophylaxis 51
Arterial Pulsations 52
Blood Pressure 54
Jugular Venous Pulse 56
Jugular Venous Pressure 58
Apical Impulse 59
Left Parasternal Impulse 61
Added Sounds 65
Murmurs 65
Important Things to be Known 70
Common Clinical Conditions 70
Mitral Stenosis 70
Aortic Regurgitation 77
Self-assessment Questions for Clinical Medicine 79

4. Respiratory System Examination 86
Case Recording Format 86
I Preliminary Data 86
II Chief Presenting Complaint 86
III History in Detail 86
IV Physical Examination 89
V Diagnosis 97
VI Management 97
Quick Review of Signs and Symptoms 104
Surface Landmarks in Respiratory System 104
Symptomatology of Respiratory System 108
Percussion 122
Auscultation 124

Respiratory Failure 128
Common Clinical Conditions 130
Self-assessment Questions for Clinical Medicine 147

5. Abdomen Examination 151
Case Recording Format 151
I Preliminary Data 151
II Chief Presenting Complaint 151
III History Presentation in Detail 151
IV Physical Examination 154
V Diagnosis 159
VI Management 160
Quick Review of Signs and Symptoms 160
Edema 160
Fever 162
Other Symptoms 164
Surface Marking for Organs 175
Self-assessment Questions for Clinical Medicine 177

6. Central Nervous System Examination 182
Case Recording Format 182
I Preliminary Data 182
II Chief Presenting Complaints 182
III History Presentation in Detail 182
IV Physical Examination 185
V Diagnosis 190
VI Management 210
Actions of the Extraocular Muscles 210
Quick Review of Signs and Symptoms 211
Upper Motor Neuron 211
Lower Motor Neuron 212
Extrapyramidal System 212
Cerebellum 213

Spinal Cord 215
Segmental Orientation of Sensory System 216
Representation of Motor Segments 217
Neurological Profile 218
Lucid Interval 218
Important Signs/Symptoms 218
General Examination in Central Nervous System Diseases 221
Specific Examination 225
Examination of Spinal Motor System 240
Self-assessment Questions for Clinical Medicine 251

7. Spotters 255
Scabies 255
Fungal Infections of Skin 256
Psoriasis 260
Leprosy 264
Herpes Zoster (Shingles) 269
Molluscum Contagiosum 271
Anemia with Koilonychia 272
Clubbing 273
Oral Candidiasis 275
Jaundice 275
Gynecomastia 276
Ascites 277
Precipitating Factors for Hepatic Encephalopathy 280
Major Complications of Portal Hypertension 280
Rheumatoid Arthritis 281
Bell's Palsy 283
Horner's Syndrome 285
Small Muscle Wasting of Hands 286
Parkinson Disease 287

Hypothyroidism 289
Hyperthyroidism 292
Goiter 293
Chickenpox 294
Common Electrocardiograms 295

8. Chest X-rays 304

9. Instruments 317
Ambu Bag 317
Endotracheal Tube 317
Tracheostomy Tube 317
Ryle's Tube 317
Stomach Wash Tube 321
Sengstaken-Blakemore Tube 322
Bone Marrow Biopsy Needle 323
Menghini Aspiration Biopsy Needle, Vim-Silverman Needle and Tru-Cut Needle 323
Pleural Aspiration Needle 326
Lumbar Puncture Needle 329
Urinary Catheters 331
Ascitic Fluid Aspiration (Paracentesis) 335

10. Problem-oriented Charts with Probable Clinical Diagnosis 337

Appendices 345
Appendix I: WHO Criteria for Diagnosis of Diabetes Mellitus 345
Appendix II: Risk Factors for Atherosclerosis 347
Appendix III: Relative Contraindications for Thrombolytic Therapy 348
Appendix IV: Sites of Aspiration of Fluid 349
Appendix V: Various Cuff Sizes for Blood Pressure Measurements 350
Appendix VI: Normal Pressure in Heart 351

Appendix VII: Obesity 352
Appendix VIII: Glasgow Coma Scale 353
Appendix IX: JNC VII Classification for Diagnosis of Hypertension (18 Year and Above) 354
Appendix X: Cardiac Arrest 355
Appendix XI: Revised National Tuberculosis Control Program 358
Appendix XII: Reference Values of Common Laboratory Tests 365

Index 373

2
Chapter

General Examination

EXAMINATION OF THE SKIN

1. Generalized absence of skin pigmentation: Albinism.
2. Patchy absence of skin pigmentation: Vitiligo, also helps to rule out diabetes mellitus and other autoimmune disorders, etc. (Figs 2.1A to C).
3. Circumscribed hypopigmented lesions: Hansen's disease, tinea versicolor, etc.
4. Generalized hyperpigmentation: Hemochromatosis, Addison's disease, etc.
5. Patchy pigmentation: Pellagra, scleroderma, certain drug reactions, etc.
6. Pigmentation of mucous membrane of oral cavity: Peutz-Jeghers syndrome (perioral pigmentation with polyposis of colon) and Addison's disease.
7. Café-au-lait spots: Neurofibroma (Fig. 2.2).



Figure 2.1A: Hypopigmented patches (vitiligo)

JAYPEE BROTHERS

8. Xanthomas (Figs 2.3A to C).
9. Erythema marginatum and erythema nodosum.
10. Subcutaneous nodules.
11. Hemangiomas, purpura and spider nevi.





Figures 2.1B and C: Hypopigmented patches (vitiligo)

JAYPEE BROTHERS



Figure 2.2: Neurofibroma

HIRSUTISM

- Cushing's syndrome
- Adrenal hyperplasia
- Virilizing ovarian tumors
- Drugs: Minoxidil
- Familial.

MADAROSIS

Loss of hair over the eyebrow:

- Myxedema
- Hansen's disease
- Syphilis.

FLAG SIGN

Patchy brownish discoloration of hair in protein-energy malnutrition (PEM).

JAYPEE BROTHERS





Figures 2.3A to C: Xanthomas forearm, ankle and gluteal region due to hyperlipidemia

HYPERTELORISM

- Wide-spaced eyes: Intercanthal distance is more than half of interpupillary distance
- To rule out congenital heart diseases.

LOW-SET EARS

Diagnosed when only less than one third of pinna is present above the horizontal line drawn from the outer canthus of eye.

JAYPEE BROTHERS



Figure 2.4: High-arched palate (common in Marfan's syndrome)

HIGH-ARCHED PALATE

High-arched palate said to be present when the roof of palate is not seen when the examiner's eyes are kept at the level of patient's upper incisor teeth (Fig. 2.4).

Note: High-arched palate, low-set ears and hypertelorism may be associated with the congenital anomalies of the heart.

EYES

Examined for:

- Ptosis (Fig. 2.5)
- Jaundice (Fig. 2.6)
- Cyanosis
- Anemia
- Kayser-Fleischer rings

JAYPEE BROTHERS



Figure 2.5: Ptosis right eye—III cranial nerve palsy (drooped eyelid, dilated pupil, divergent squint and diplopia)

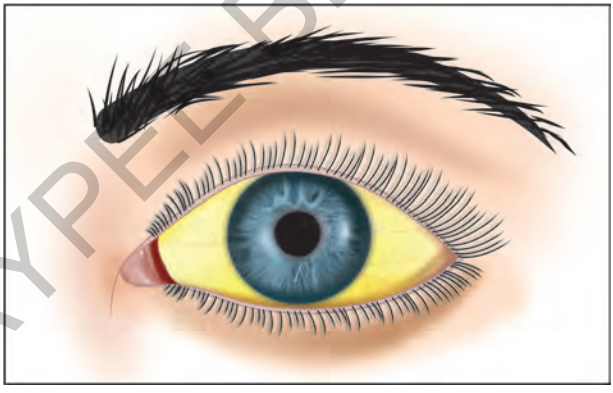

Figure 2.6: Jaundice eye

- Corneal opacities
- Cataract
- Subconjunctival hemorrhage
- Bitot's spots

JAYPEE BROTHERS

- Ectopic lentis
- Arcus senilis
- Xanthelasma (over eyelids).

CHARACTERISTIC FACIES

1. Acromegalic prominent lower jaw, large nose, lips and ears, and prominent forehead.
2. Cushing's syndrome moon face.
3. Myxedema: Puffy faces with swollen eyelids and loss of hairs over eyebrows with dry skin.
4. Hyperthyroid face with exophthalmic starring of eyes (Fig. 2.7).
5. Leonine face: Leprosy.
6. Systemic lupus erythematosus (SLE): Butterfly rash seen over upper cheeks and nasal bridge, sparing the nasolabial fold.



Figure 2.7: Exophthalmos

JAYPEE BROTHERS

7. Parkinsonian face: Expressionless, mask-like face.
8. Early morning periorbital edema seen in the face: To rule out renal diseases.

STATURE

1. Arm span > height by at least 5 cm—Marfan's syndrome.
2. Lower segment > upper segment by at least 5 cm—Marfan's syndrome (Fig. 2.8).
3. Metacarpal index > 8.4 cm calculated from average length of four metacarpals/average midwidth of four metacarpals.

HANDS

1. Clinodactyly: Single palmar crease with incurving of distal phalanx of little finger—Down syndrome (Fig. 2.9).
2. Arachnodactyly: Long thin fingers seen in Marfan's syndrome.
3. Koilonychia: Spoon-shaped nail seen in iron deficiency anemia.
4. White nails: Commonly seen in anemia and hypoalbuminemic states such as cirrhosis of liver and nephritic syndrome (Fig. 2.10).
5. Heberden's nodes seen in distal interphalangeal joints are sign of osteoarthritis (Fig. 2.11).
6. Swelling of proximal interphalangeal joints: Suggestive of rheumatoid arthritis (Fig. 2.12).
7. Cyanosis and clubbing (Fig. 2.13) is dealt in detail in the section of systemic examination and also in the spotters.

JAYPEE BROTHERS



Figure 2.8: Marfan's syndrome (note arm span more than height of patient)



Figure 2.9: Dwarf with mother

JAYPEE BROTHERS



Figure 2.10: White nails

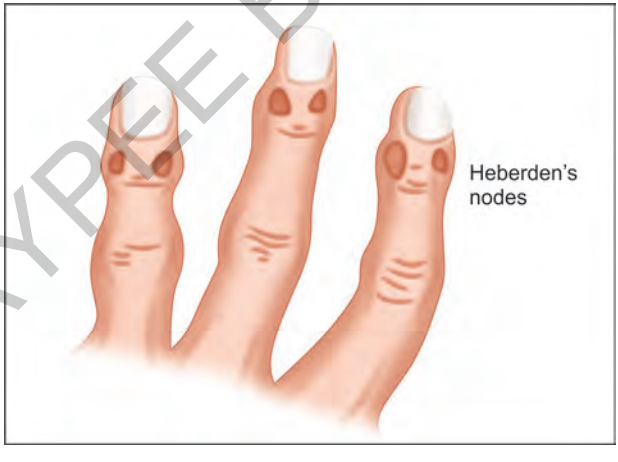

Figure 2.11: Heberden's nodes in osteoarthritis

JAYPEE BROTHERS

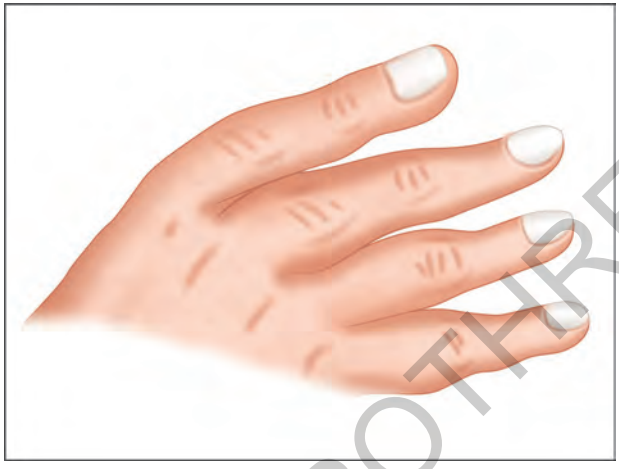

Figure 2.12: Rheumatoid arthritis with swelling of proximal interphalangeal joints



Figure 2.13: Clubbing

JAYPEE BROTHERS

LEGS

Polydactyly (Fig. 2.14)



Figure 2.14: Right foot polydactyly

PAINLESS ULCER OF FOOT (Fig. 2.15)

- Diabetic foot
- Hansen's disease
- Tabes dorsalis.

NOURISHMENT

1. Usually assessed by body mass index (BMI):

$$\text{BMI} = \frac{\text{Weight in kg}}{\text{Height in m}^2}$$

JAYPEE BROTHERS

for detailed information on medicine books, visit our website **www.jaypeebrothers.com,** for detailed info

CLINICAL MEDICINE
Made Easy®

Salient Features

- More clinical photographs with explanation, charts, X-rays and ECGs have been added
- Self-assessment questionnaire at the end of chapters
- Serves as a ready reference
- Included common disease patterns and symptomatology in each chapter
- Helps in better understanding the significance of common signs and symptoms
- Helps in making good case record at the bedside
- Enables to be familiar with the mode of clinical examination by various universities
- Is small and handy to put into student's coat pocket.



TV Devarajan BSc MD FCIP FACM FCCP (USA) FRCP (Glasgow) DSc (Hons) is Emeritus Professor of Medicine, Aarupadai Veedu Medical College and Hospitals, Puducherry, India. He served as a teacher in Madras Medical College, Chennai, Tamil Nadu, under the guidance of Padma Shri Professor KV Thiruvengadam for 28 years. He is also a Senior Consultant Physician at Apollo Hospitals, Chennai since 1986. He has 28 publications to his credit. He is the author of books titled *Medicine in Nutshell, Aids to Clinical Medicine* and the book for patients *Medical Advice for Healthy Life* translated to many languages. He has served as a medical examiner for undergraduate and postgraduate students for few universities. He is a recipient of Dr BC Roy National Award as an eminent medical teacher, Padma Shri from Honorable President of India, FRCP by University of Glasgow, UK, DSc Honors by The Tamil Nadu Dr MGR Medical University, and FICP from IMA, APICON and Indian College of Physicians. He was appointed as a Jury by British Medical Journal to select doctors for Oscar awards in India.



L Vijayasundaram MD is at present working as Senior Professor of Medicine and Senior Consultant Physician, Sri Lakshmi Narayana Institute of Medical Science and Medical College, Puducherry, India. He completed his postgraduate course in the prestigious Madras Medical College under the dynamic guidance of internationally reputed physician, Professor KV Thiruvengadam, Dr BC Roy awardee for the eminent medical teacher. He had been as a teacher in the faculty of medicine in various Tamil Nadu Government medical colleges and got vast experience of teaching for about 30 years. He also published many papers. He served as University Examiner for undergraduate and postgraduate examinations in various universities since 1994. He has served as a senate Member and also as a Member of Board of Studies for MBBS course in The Tamil Nadu Dr MGR Medical University for a total duration of 6 years.

Available at all medical bookstores
or buy online at www.jaypeebrothers.com

JAYPEE BROTHERS
Medical Publishers (P) Ltd.
www.jaypeebrothers.com

Join us on facebook.com/JaypeeMedicalPublishers

Shelving Recommendation
MEDICINE

ISBN 978-93-5250-161-8