ophthalmology books, visit our website **www.jaypeebrothers.com,** for detailed information on ophthalmology books

Gonioscopy

A Video Assisted Skill Transfer Approach

(Including Intraoperative Procedures and Self-assessment Video Quiz)

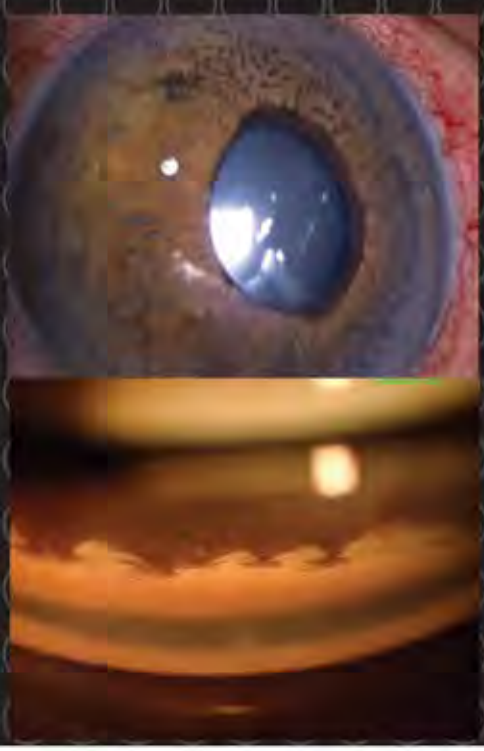

Tanuj Dada
Talvir Sidhu
Amit Kumar
Ajay Sharma

JAYPEE

Foreword
Tin Aung

Including Interactive DVD-ROM
Containing 137 Videos
Duration 45 Minutes

CONTENTS

Developmental Anomalies

Video 1. Anterior Insertion of Iris on to Trabecular Meshwork
Video 2. Anteriorly Displaced Schwalbe's Line with Iris Attachment
Video 3. Anteriorly Displaced Band Like Schwalbe's Line
Video 4. Anteriorly Displaced Schwalbe's Line (High Magnification)
Video 5. Anterior Insertion of Iris on to Pigmented Trabecular Meshwork
Video 6. Posterior Embryotoxon with Iris Attachments
Video 7. Axenfeld–Reiger Syndrome with Anteriorly Inserted Iris Occluding Trabeculum
Video 8. Prominent Schwalbe's Line with Anterior Insertion of Iris
Video 9. Late Onset Congenital Glaucoma with Prominent Iris Processes
Video 10. ICE Syndrome with Peripheral Anterior Synechiae (PAS) Attaching to Corneal Endothelium
Video 11. Sectoral Anterior Insertion of Iris with Adjacent Normal Angle
Video 12. Prominent Iris Processes in Juvenile Glaucoma
Video 13. Anterior Insertion of Iris
Video 14. PAS in ICE Syndrome
Video 15. Prominent Iris Processes in JOAG
Video 16. Fine Filiform Prominent Iris Processes
Video 17. Anterior Segment in Cogan-Reese Syndrome
Video 18. Cogan-Reese Syndrome with Iris Nodules
Video 19. Cogan-Reese Syndrome with Closed Angles
Video 20. Koeppe's Lens used during Examination under Anesthesia
Video 21. Swan-Jacob Lens View of Angle
Video 22. Swan-Jacob Lens View of Primary Congenital Glaucoma
Video 23. Prominent Iris Processes in Inferior Angle
Video 24. Prominent Iris Processes Attached to Trabeculum

Open Angle Glaucoma

Video 25. Open Angle in Primary Open Angle Glaucoma
Video 26. Heavy Pigmentation of Angle in PDS
Video 27. Open Angle in JOAG
Video 28. Open Angle with Heavy Pigmentation
Video 29. Open Angle at High Magnification
Video 30. Open Angle with Continuous Slit Beam from Cornea to Iris
Video 31. Open Angle with Ciliary Body Band Visible
Video 32. Pigment Dispersion Syndrome
Video 33. Heavily Pigmented Angle in Pigment Dispersion
Video 34. Heavily Pigmented Angle

Video 35. Mid Peripheral Iris Defects in Pigmentary Glaucoma
Video 36. Pigment Blocking Angle View in Pigmentary Glaucoma
Video 37. Superior Angle View (Open)
Video 38. Open Angle with Pigment Clumps in Uveitis
Video 39. Open Angle with Pigment Clumps in Uveitis
Video 40. Wide Open Angle with Ciliary Body Band
Video 41. Wide Open Angle with Anterior Pigmentation
Video 42. Wide Ciliary Body Band (Inferior Angle)
Video 43. Wide Ciliary Body Band (Superior Angle)
Video 44. Pigment Dispersion Syndrome

Angle Closure Glaucoma

Video 45. Indentation Gonioscopy
Video 46. Slit Beam Parallax-Manipulation
Video 47. Closed Angle
Video 48. Corneal Wedge-Level of Schwalbe's Line
Video 49. Angle Opening on Manipulation in a Primary Angle Closure (PAC) Patient
Video 50. Angle Opening on Manipulation in a PACS Patient
Video 51. Pigments Anterior to Schwalbe's Line and on Trabeculum in PAC
Video 52. Primary Angle Closure with Partially Open Angle
Video 53. Closed Angle in PACG
Video 54. Angle Opening on Manipulation
Video 55. Corneal Wedge with Slit Beam Parallax
Video 56. Partly Closed Angle with Goniosynechiae
Video 57. Pseudo-TM; Pigmentation Anterior to Schwalbe's Line
Video 58. Steep Iris with Parallax
Video 59. Partial Angle Closure (High Magnification)
Video 60. Corneal Wedge
Video 61. Manipulation in Primary Angle Closure (Over a Steep Iris)
Video 62. Primary Angle Closure with Iridotrabecular Contact in Primary Position
Video 63. Angle Closure Angle Opening on Manipulation
Video 64. Primary Angle Closure with Iridotrabecular Contact and Pigment Clumps

Secondary Glaucoma

Video 65. Angle Recession with Wide Ciliary Body Band
Video 66. Angle Recession with Wide Ciliary Body Band (High Magnification)
Video 67. Angle Recession with Iridodonesis
Video 68. Angle Recession with Wide Ciliary Body Band in Superior Angle
Video 69. Angle Recession with Blood in Schlemm's Canal
Video 70. Angle Recession with Blood in Schlemm's Canal (High Magnification)

Video 71. Post-Trauma Heavy Angle Pigmentation with GS
Video 72. Hyperoleon (Emulsified Silicone Oil)
Video 73. Iridodialysis with Ciliary Processes Visible
Video 74. Post-traumatic Iridodialysis
Video 75. Iris Neovascularization with Synechial Angle Closure
Video 76. Iris Neovascularization with Angle Closure
Video 77. Hyperpigmented Angle in Ocular Melanosis
Video 78. Hyperpigmented Angle in Ocular Melanosis
Video 79. Iris and Scleral Hyperpigmentation in Melanosis
Video 80. Broad-based PAS
Video 81. Iridodialysis with Goniosynechiae
Video 82. Broad-based PAS in Uveitic Glaucoma
Video 83. Pigment Clumps in Angle
Video 84. PAS and Cyclodialysis
Video 85. Broad-based PAS in Uveitic Glaucoma
Video 86. Iridodialysis with Ciliary Processes (High Magnification)
Video 87. Iridodialysis with Ciliary Processes
Video 88. Hyperpigmented Angle in Ocular Melanosis
Video 89. ACIOL Haptics in Angle
Video 90. ACIOL Haptics in Angle (High Magnification)
Video 91. ACIOL Haptics Touching Endothelium
Video 92. Bleed from Schlemm's Canal
Video 93. Vitreous Tag Bridging Angle
Video 94. Pseudoexfoliation on Iris
Video 95. Pseudoexfoliation on Lens
Video 96. Pseudoexfoliation in Anterior Segment (Corneal Endothelium)
Video 97. Pseudoexfoliation Material Clumps in Angle
Video 98. Pseudoexfoliation in Angle with Heavy Pigmentation
Video 99. Cyclodialysis View with Koeppe Goniolens

Intraoperative Techniques

Video 100. Patent Trabeculectomy Ostium
Video 101. Iris Plugging Trabeculectomy Ostium
Video 102. Tube of Glaucoma Shunt Device
Video 103. Trabeculectomy Ostium Partially Blocked by Iris
Video 104. Patent Trabeculectomy Ostium
Video 105. Fibrosed Trabeculectomy Ostium
Video 106. Fiberoptic Illuminator in Schlemm's Canal in Congenital Glaucoma
Video 107. Goniosynechiolysis in PACG
Video 108. Gonioscopy Using Goldmann 2 Mirror
Video 109. Canaloplasty
Video 110. Patent Large Trabeculectomy Ostium
Video 111. Goniosynechiolysis Techniques: Different Gonioscopes

26 Videos of Self-assessment Quiz

Developmental Anomalies

Video 1: Anterior Insertion of Iris on to Trabecular Meshwork

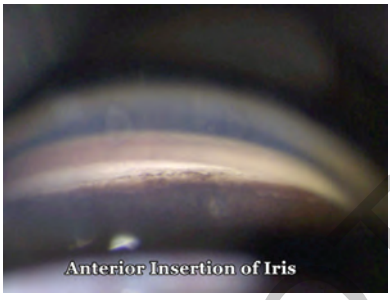

This is a case of developmental glaucoma. Anterior insertion of iris seen partly covering the sclera spur and trabecular meshwork. Normal iris insertion is usually seen behind the sclera spur.

Video 2: Anteriorly Displaced Schwalbe's Line with Iris Attachment



This is a case of Axenfeld-Rieger syndrome showing anteriorly displaced band like pigmented Schwalbe's line (called posterior embryotoxon) with abnormal iris attachment to the Schwalbe's line. These iris adhesions can later contract to cause secondary angle closure leading to glaucoma.

Video 3: Anteriorly Displaced Band Like Schwalbe's Line

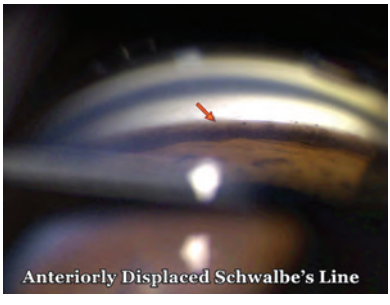

JAYPEE BROTHERS

This is a case of developmental glaucoma showing a band like anteriorly displaced Schwalbe's line. Unlike Axenfeld-Rieger syndrome, no abnormal iris attachment is seen at the Schwalbe's line.

Video 4: Anteriorly Displaced Schwalbe's Line (High Magnification)



This is a case of developmental glaucoma showing a band like anteriorly displaced Schwalbe's line in high magnification.

Video 5: Anterior Insertion of Iris on to Pigmented Trabecular Meshwork



This is a case of developmental glaucoma showing anterior insertion of iris partly covering the sclera spur and the trabecular meshwork. Normal iris insertion is usually seen behind the sclera spur.

Video 6: Posterior Embryotoxon with Iris Attachments



This is a case of Axenfeld-Rieger syndrome showing anteriorly displaced band like pigmented Schwalbe's line (called posterior embryotoxon) with abnormal iris attachment to the Schwalbe's line.

JAYPEE BROTHERS

Video 7: Axenfeld–Reiger Syndrome with Anteriorly Inserted Iris Occluding Trabeculum

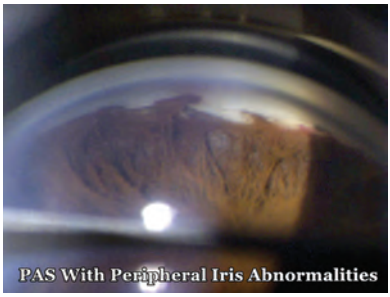

This is a case of Axenfeld-Rieger syndrome with anteriorly inserted iris occluding trabecular meshwork with peripheral iris abnormalities seen in a case of Axenfeld-Rieger syndrome with secondary angle closure.

Video 8: Prominent Schwalbe's Line with Anterior Insertion of Iris



This is a case of developmental glaucoma. Gonioscopy shows band like prominent Schwalbe's line with anterior insertion of iris with peripheral iris abnormalities.

Video 9: Late Onset Congenital Glaucoma with Prominent Iris processes



Gonioscopy in a late onset congenital glaucoma shows prominent iris processes and featureless angle. Trabecular meshwork and other structures are not distinct.

JAYPEE BROTHERS

Video 10: ICE Syndrome with Peripheral Anterior Synechiae (PAS) Attaching to Corneal Endothelium



This is a case of Iridocorneal Endothelial Syndrome. Gonioscopy shows iris discoloration with peripheral anterior synechiae in one part of iris. Some of the syndromes can present with milder features of the same.

Video 11: Sectoral Anterior Insertion of Iris with Adjacent Normal Angle



This is case of developmental glaucoma showing sectoral anterior insertion of iris on gonioscopy. Part of iris is seen covering the sclera spur and the trabecular meshwork with adjacent normal angle.

Video 12: Prominent Iris Processes in Juvenile Glaucoma



This is a case of Juvenile Open Angle Glaucoma showing prominent iris processes on gonioscopy. Small thread like extensions seen extending from the iris to the angle. It is very important to distinguish iris processes from goniosynechiae.

JAYPEE BROTHERS

Video 13: Anterior Insertion of Iris

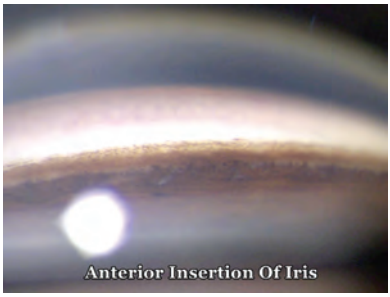

This is a case of Juvenile Open Angle Glaucoma showing anterior insertion of iris on gonioscopy in high magnification.

Video 14: PAS in ICE Syndrome



This is a case of Iridocorneal Endothelial Syndrome showing broad based peripheral anterior synechiae on gonioscopy.

Video 15: Prominent Iris Processes in JOAG



This is a case of Juvenile Open Angle Glaucoma showing prominent iris processes on gonioscopy. Small thread like extensions seen extending from the iris to the angle. It is very important to distinguish iris processes from goniosynechiae.

JAYPEE BROTHERS

Video 16: Fine Filiform Prominent Iris Processes



This is a case of Juvenile Open Angle Glaucoma showing prominent iris processes on gonioscopy. Small thread like extensions seen extending from the iris to the angle. It is very important to distinguish iris processes from goniosynechiae.

Video 17: Anterior Segment in Cogan-Reese Syndrome



This is a case of Cogan-Reese Syndrome. The anterior segment photograph shows iris nodules with ectropion uveae with corectopia.

Video 18: Cogan-Reese Syndrome with Iris Nodules

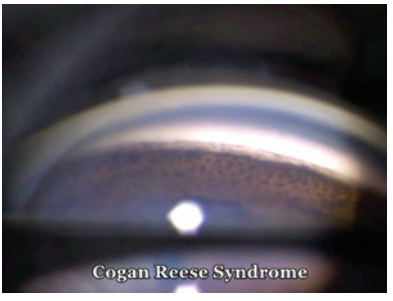

This is a case of Cogan Reese Syndrome showing completely closed angle with iris nodules. None of the angle structures are visible. Some pigmentation is seen anterior to Schwalbe's line.

JAYPEE BROTHERS

Viedeo 19: Cogan-Reese Syndrome with Closed Angles



This is a case of Cogan Reese Syndrome showing completely closed angle with iris nodules. None of the angle structures are visible. Some pigmentation is seen anterior to Schwalbe's line.

Video 20: Koeppe's Lens used during Examination under Anesthesia

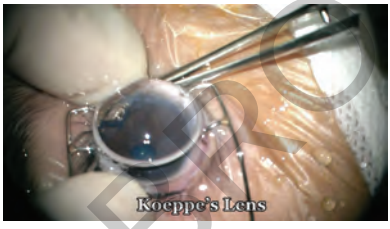

Koeppe's lens is placed on the eyeball of a primary congenital glaucoma using viscoelastic material. Direct gonioscopy is performed. Featureless angle is seen with indistinct angle structures and prominent iris processes.

Video 21: Swan-Jacob Lens View of Angle



This is a case of primary congenital glaucoma. Direct gonioscopy is performed using Swan-Jacob gonioprism placed on the eyeball using viscoelastic material. Featureless angle is seen with indistinct angle structures and prominent iris processes.

JAYPEE BROTHERS

Video 22: Swan-Jacob Lens View of Primary Congenital Glaucoma



This is a case of Primary Congenital Glaucoma. Direct gonioscopy is performed using Swan-Jacob gonioprism placed on the eyeball using viscoelastic material. Featureless angle is seen with indistinct angle structures and prominent iris processes.

Vidoe 23: Prominent Iris Processes in Inferior Angle

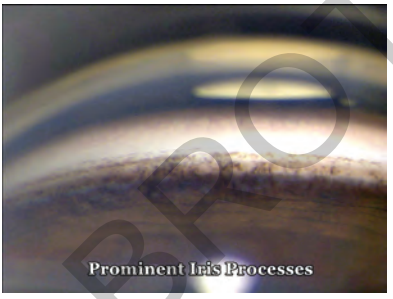

This is a case of Juvenile Open Angle Glaucoma showing prominent iris processes with anterior insertion of the iris at low magnification

Video 24: Prominent Iris Processes Attached to Trabeculum

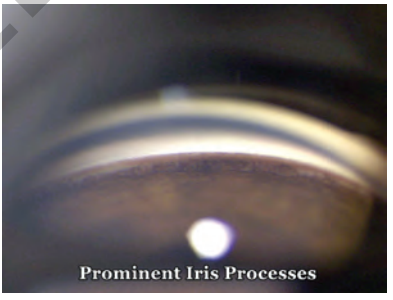

This is a case of Juvenile Open Angle Glaucoma showing prominent iris processes extending upto trabeculum with anterior insertion of the iris at low magnification.

JAYPEE BROTHERS

Self-assessment Quiz

Question Video 1: 35-year-old male presented with both eyes myopia with glaucomatous disc damage. Comment on the gonioscopy of his left eye.

Question Video 2: 11-year-old male with both eyes iris abnormalities with both eyes elevated intraocular pressures. Both eyes have glaucomatous disc damage. Comment on the gonioscopy.

Question Video 3: 47-year-old male presented with right eye iris abnormalities with left eye appearing normal. Comment on the video of the anterior segment of the right eye.

Question Video 4: 47-year-old male presented with right eye iris abnormalities with left eye appearing normal. Comment on the gonioscopy of the right eye.

Question Video 5: 50-year-old male, operated trabeculectomy one year back. Comment on the gonioscopy of the operated eye.

Question Video 6: 32-year-old female presented with right eye iris abnormalities with left eye normal appearing iris. Comment on the gonioscopy of the right eye.

Question Video 7: 22-year-old male presented with trauma to the left eye with a ball. Patient had normal intraocular pressure. Comment on the gonioscopy of this patient.

Question Video 8: 52-year-old male presented with both eyes glaucomatous disc damage with raised intraocular pressure. Comment on the gonioscopy of the same.

Question Video 9: 35-year-old female presented with intermittent blurring of vision. Comment on the gonioscopy of this patient.

Question Video 10: 50-year-old female presented with recurrent halos in front of eyes; on examination her intraocular pressure was 32 mmHg in her right and 28 mmHg in her left eye, both eyes showing glaucomatous disc damage. Comment on the gonioscopy of her left eye.

Question Video 11: 28-year-old male presented with bilateral chronic anterior uveitic with raised intraocular pressures. Comment on the gonioscopy of the same.

Question Video 12: 30-year-old male with bilateral glaucomatous disc damage has fluctuating intraocular pressures. Comment on the gonioscopy of the same.

Question Video 13: 37-year-old male presented with near vision difficulty with both eyes healthy disc. Comment on the gonioscopy of the same.

Question Video 14: 30-year-old male with closed globe injury has raised intraocular pressures. Comment on the gonioscopy of the same.

JAYPEE BROTHERS

Answers

Answer Video 1: This patient is a case of juvenile open angle glaucoma. It is seen that in primary ocular position, all angle structures are seen, from ciliary body band—scleral spur- trabecular meshwork- Schwalbe's line. Few prominent iris processes are present.

Answer Video 2: This is a case of Axenfeld Rieger Syndrome abnormal iris attachment anterior to the Schwalbe's line. None of the angle structures are visible. These iris adhesions contract to cause secondary angle closure leading to glaucoma.

Answer Video 3: Anterior segment shows ectropion uveae with iris nodules with pupil and iris abnormalities. Also unilateral abnormality suggests Cogan Reese Syndrome.

Answer Video 4: This is a case of Cogan Reese Syndrome. The angle shows peripheral anterior synechiae extending anterior to Schwalbe's line covering all the angle structures in one quadrant. Rest of the angle shows all angle structures- scleral spur and trabecular meshwork.

Answer Video 5: The gonioscopy shows a large peripheral iridotomy with ciliary processes visible through it. No ostium is seen. Therefore this is a fibrosed trabeculotomy ostium.

Answer Video 6: Young female with unilateral iris abnormalities suggest Irido-corneal endothelial syndrome. This video shows completely closed angle with peripheral anterior synechiae extending anterior to Schwalbe's line. None of the angle structures are visible. Zipper angle closure is seen in such cases.

Answer Video 7: This video shows Iridodialysis with ciliary processes visible through it. Rest of the angle shows pigmentation of the trabecular meshwork.

Answer Video 8: This video shows open angle. All angle structures are visible: ciliary body band, scleral spur, trabecular meshwork and schwalbe's line.

Answer Video 9: This is a case of primary angle closure. On gonioscopy, no angle structures are visible in primary gaze, but angle opens on manipulation to reveal the angle structures (trabecular meshwork) with few goniosynechiae.

Answer Video 10: This is a case of primary angle closure glaucoma. The angle is seen to have multiple goniosynechiae with blotchy pigmentation anterior to Schwalbe's line.

Answer Video 11: Gonioscopy shows broad-based peripheral anterior synechiae extending upto the Schwalbe's line. Trabecular meshwork is visible in some parts of angle

Answer Video 12: This is a pigment dispersion syndrome. Angle on gonioscopy shows heavily pigmented trabecular meshwork with a wide angle recess.

JAYPEE BROTHERS

for detailed information on ophthalmology books, visit our website www.jaypeebrothers.com, for detailed informati

Gonioscopy

A Video Assisted Skill Transfer Approach

(Including Intraoperative Procedures and Self-assessment Video Quiz)

A unique video assisted skill transfer module comprising of 137 diagnostic and surgical gonioscopy videos including:

- Primary Open Angle Glaucoma
- Primary Angle Closure Disease
- Primary Congenital Glaucoma
- Juvenile Open Angle Glaucoma
- Pigmentary Glaucoma
- Pseudoexfoliation Glaucoma
- Silicone Oil Glaucoma
- Neovascular Glaucoma
- Angle Recession Glaucoma
- Cyclodialysis
- Cogan-Reese Syndrome
- Axenfeld Reiger Syndrome
- Trabeculectomy
- Glaucoma Drainage Devices
- Intraoperative Goniosynechiolysis
- Minimally Invasive Glaucoma Surgery
- Dynamic Gonioscopy Techniques
- Rectam Gonioscopy
- Gonioscopy Video Quiz



Tanuj Dada MD MAMS is Professor, Department of Ophthalmology, Dr Rajendra Prasad Centre for Ophthalmic Sciences, All India Institute of Medical Sciences, New Delhi, India. He completed his undergraduate and postgraduate training from the All India Institute of Medical Sciences (AIIMS), New Delhi and was awarded the gold medals for best undergraduate and best postgraduate in ophthalmology, the Ophthalmic Research Association award for the Best Senior Registrar and the Mohan Lal Wig gold medal for the best clinical research under the age of 35 years at AIIMS. He has authored 4 textbooks on glaucoma, a gonioscopy photo atlas and has over 220 publications in peer reviewed indexed journals. He has been conducting the course on gonioscopy at the World Glaucoma Congress over the last 10 years. He is currently the Secretary General of the International Society of Glaucoma Surgery, Chair of the Associate Advisory Board of the World Glaucoma Association and Editor-in-Chief of the Journal of Current Glaucoma Practice.



Talvir Sidhu MD is currently working as a Senior Resident, Dr Rajendra Prasad Centre for Ophthalmic Sciences, All India Institute of Medical Sciences, New Delhi, India. She completed her undergraduation and postgraduation from All India Institute of Medical Sciences, New Delhi. She has 5 indexed publications.



Amit Kumar MBBS is Assistant Divisional Medical Officer, Indian Railways. An outstanding undergraduate of Grant Medical College, Mumbai, Maharashtra, India, and currently a Junior Resident at Dr Rajendra Prasad Centre for Ophthalmic Sciences, All India Institute of Medical Sciences, New Delhi, India.



Ajay Sharma MSc Optom is Senior Optometrist and Senior Technical Officer of the glaucoma clinical and research facility at Dr Rajendra Prasad Centre for Ophthalmic Sciences, All India Institute of Medical Sciences, New Delhi, India. He has 17 indexed publications in peer reviewed journals and has authored a textbook on basic glaucoma investigations.

Available at all medical bookstores or buy online at www.jaypeebrothers.com



JAYPEE BROTHERS
Medical Publishers (P) Ltd.
www.jaypeebrothers.com

Join us on facebook.com/JaypeeMedicalPublishers

Shelving Recommendation
OPHTHALMOLOGY

