etailed information on obstetrics & gynecology books, visit our website **www.jaypeebrothers.com,** for detailed information on obstetrics & gynecology books, visit our website **www.jaypeebrothers.com**

Advanced Vaginal Surgery

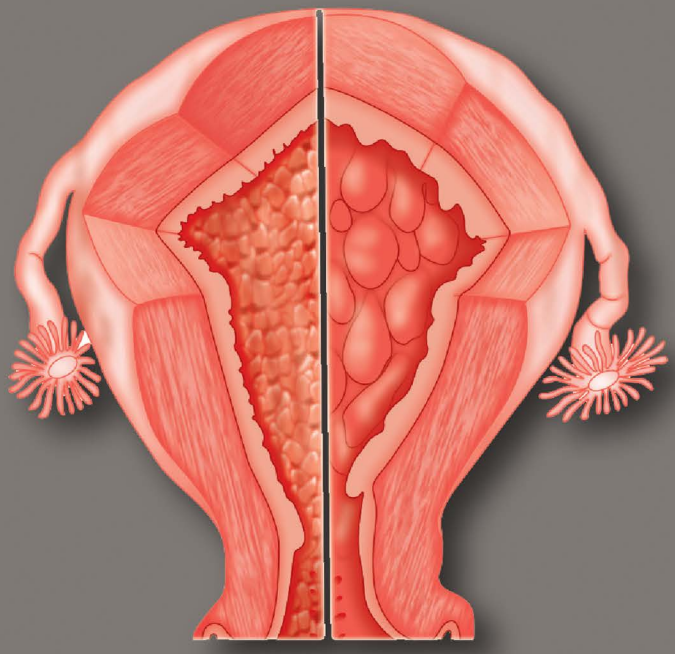





Shirish S Sheth
Carl W Zimmerman
Seth Finkelstein

Foreword
Prof Alan D Hewson

JAYPEE

Contents

Section 1: Vaginal Hysterectomy with Uterine Debulking

Introduction *3*
Case 1: Vaginal Hysterectomy (VH) with Uterine Debulking 8
Case 2: Vaginal Hysterectomy (VH) with Uterine Debulking Plus Bilateral Salpingo-oophorectomy (BSO) (CA125: 516) 9
Case 3: Vaginal Hysterectomy with Uterine Debulking Plus Ovarian Cystectomy 10
Case 4: Vaginal Hysterectomy with Massive Uterine Debulking Plus Bilateral Salpingo-oophorectomy (Right Hydrosalpinx) 11
Case 5: Vaginal Hysterectomy with Debulking Plus Bilateral Salpingo-oophorectomy with H/O Two Caesarean Sections 13
Case 6: Vaginal Hysterectomy with Uterine Debulking Plus Bilateral Salpingo-oophorectomy and Laparoscopic Cholecystectomy 14
Case 7: Nullipara: Large Debulking and Adnexectomy 17
Case 8: Nullipara and Obese: Debulking with Bilateral Salpingectomy 19
Case 9: Massive Debulking of Kilogram Uterus with Bilateral Salpingectomy-1 20
Case 10: Massive Debulking of Kilogram Uterus with Bilateral Salpingectomy-2 21
Case 11: Debulking of Large Adenomyoma, Bilateral Salpingectomy-1 22
Case 12: Debulking of Large Adenomyoma, Bilateral Salpingectomy-2 23
Case 13: Large Debulking with Bilateral Salpingectomy for Recurrent Postmenopause Bleeding 24
Case 14: Early Debulking with the Aid of Vasopressin 25

Section 2A: Vaginal Hysterectomy with History of Caesarean Section(s)

Introduction *29*
Case 15: VH with Left Ovarian Cystectomy 30
Case 16: VH Plus Stress Urinary Incontinence (SUI) Repair 32
Case 17: VH with Uterine Debulking 33
Case 18: VH with Right Ovarian Cystectomy Plus ?Endometrial Hyperplasia 34
Case 19: VH with Left Salpingo-oophorectomy for Ovarian Endometrial Cyst in a Morbidly Obese Patient 35
Case 20: VH with BSO for Right Ovarian Endometriotic Cyst 37
Case 21: VH with BSO for Abnormal Uterine Bleeding (AUB) with History of Caesarean Sections and Rupture Uterus 39
Case 22: VH Plus Vaginal Cuff with BSO for Postmenopausal Bleeder in a Morbidly Obese and Diabetic Patient 41
Case 23: VH with Altered Approach to Vesicouterine Peritoneum (VUP) 42
Case 24: VH in Heavy Cigarette Smoker with H/O Two Classical Caesarean Sections via Midline Vertical Laparotomy 46
Case 25: VH with Uterine Debulking Plus Bilateral Salpingectomy of Tubal Remnants after Four Caesarean Sections and No Vaginal Births 47
Case 26: VH Plus Bilateral Salpingectomy after One Caesarean and No Vaginal Births 48
Case 27: VH with Uterine Debulking after Six Midline Vertical Laparotomies (Five Caesarean Sections and One Ectopic Pregnancy) in a Morbidly Obese Cigarette Smoker 49

Section 2B: Vaginal Hysterectomy with History of Uterine Surgery in Past

Case 28: VH in Nullipara with H/O Abdominal Myomectomy 53
Case 29: VH Plus Salpingectomy in Primipara with H/O Abdominal Myomectomy and Recurrent Large Fibroids 54

Section 3: Vaginal Hysterectomy with Adnexal Pathology

Introduction *57*
Case 30: VH with BSO for Large Bilateral Hydrosalpinx 60
Case 31: VH with Left Salpingo-oophorectomy for Ovarian Endometrial Cyst in Morbidly Obese with Past History of Two Caesarean Sections 62
Case 32: VH with BSO for Left Ovarian Endometrial Cyst and Right Ovarian Teratoma with H/O Two Caesarean Sections 64
Case 33: VH with BSO for Bilateral Ovarian Endometrial Cysts with Positive "Dimple Sign" 66
Case 34: VH with BSO for a Solid Ovarian Tumor 68
Case 35: VH with BSO for ?Endometrial Polyp with an Ovarian Solid Tumor 69
Case 36: VH with BSO followed by Laparotomy for Ovarian Cyst (Failed "Trial Vaginal Route" because of Ovarian "CA") 70
Case 37: VH with BSO and Right Broad Ligament Myomectomy for Right Broad Ligament Fibroid (BLF) 71
Case 38: VH with BSO for Twisted Left Ovarian Cyst 73

Section 4: Nullipara and Vaginal Hysterectomy

Case 39: VH in Nullipara with Intact Hymen 77
Case 40: VH with Uterine Debulking 79
Case 41: VH with Uterine Debulking Plus Right Ovarian Endometrial Cystectomy (H/O Myomectomy) 80
Case 42: VH with BSO for Bilateral Large Hydrosalpinx 81
Case 43: VH Plus Vaginal Cuff with BSO in Obese, Diabetic with Endometrial Cancer 82
Case 44: VH with BSO for Twisted Left Ovarian Cyst 83

Section 5: Vaginal Hysterectomy for Endometrial Cancer

Introduction *87*
Case 45: VH Plus Vaginal Cuff with BSO: Postmenopausal Bleeder with Endometrial Complex Hyperplasia with Atypia 91
Case 46: VH Plus Vaginal Cuff with BSO: Postmenopausal Bleeder with Corpus Cancer Syndrome for Endometrial Cancer (CA) 93
Case 47: VH Plus Vaginal Cuff with BSO for Endometrial CA 95
Case 48: VH Plus Vaginal Cuff with BSO: Postmenopausal Bleeder with Corpus Cancer Syndrome. Failed "Trial Vaginal Route". Abdominal Surgery for LNR for Endometrial CA 96
Case 49: VH Plus Vaginal Cuff with BSO for Endometrial Complex Hyperplasia with Atypia. Corpus CA Syndrome Plus a History of Cardiac Bypass 98
Case 50: VH Plus Vaginal Cuff with BSO for Well-differentiated Endometrial Adenocarcinoma 99
Case 51: VH Plus Vaginal Cuff with BSO: Postmenopausal Bleeder with Endometrial CA with History of Two Caesarean Sections Followed by Incisional Hernia Repair 100
Case 52: VH Plus Vaginal Cuff with BSO Plus Laparoscopic Cholecystectomy for Postmenopausal Bleeder with Multiple Gallstones 101
Case 53: Laparoscopic Cholecystectomy and VH Plus Vaginal Cuff with BSO: "Failed Trial Vaginal Route Case" Abdominal LNR for Endometrial CA 102

Section 6: Failed Trial Vaginal Hysterectomy/Trial Vaginal Route

Case 54: Undiagnosed Uteroabdominal Band 107
Case 55: Uterocervical Adhesions with Abdominal Wall 108
Case 56: Diminished "Uterus-free" Space (Altered Uterocervical Angle) 110
Case 57: Ovarian Endometriosis with Positive "Dimple Sign" 111
Case 58: Large-sized Uterus 112
Case 59: Ovarian Malignancy 113

Case 60: Uterine Bulk Impedes Descent 115
Case 61: Extensive Adhesions from PID (Pelvic Inflammatory Disease) Limits Descent for VH 116
Case 62: Unanticipated Uterine Adhesions to Abdominal Wall-1 117
Case 63: Unanticipated Uterine Adhesions to Abdominal Wall-2 118
Case 64: Unanticipated Uterine Adhesions to Abdominal Wall-3 119
Case 65: Parasitic Myoma and Inaccessible Adnexa Leads to Laparoscopic Completion of VH 120

Section 7: Special Cases: Vaginal Hysterectomy

Case 66: VH Plus H/O Rupture Uterus and Two Caesarean Sections 123
Case 67: VH Plus Broad Ligament Myomectomy without Laparoscopy Plus Contralateral Endometriotic Cyst 125
Case 68: VH for CIN III 126
Case 69: VH for Metastatic Breast Cancer Plus Uterine Adenomyosis 127
Case 70: VH: Prophylactic for Hydatidiform Mole 128
Case 71: VH with BSO for Twisted Ovarian Cyst 129
Case 72: VH for Uterine Fibroids with H/O Failed Abdominal Hysterectomy 130
Case 73: VH under Local Anesthesia for Pulmonary Fibrosis 132
Case 74: VH with Altered Approach to VUP (VH with BSO) 134
Case 75: VH with Bicornuate Uterus 135
Case 76: Bladder Stone Removal at VH Plus Anterior and Posterior Repair 136
Case 77: Vaginal Hysterectomy as Emergency Procedure for Cornual Ectopic Pregnancy 138
Case 78: Vaginal Supracervical Hysterectomy 10 Years after Mesh Hysteropexy 139
Case 79: Vaginal Hysterectomy (VH): Incarcerated Prolapse due to Cervical Leiomyoma and an Intramural Myoma 140
Case 80: VH in Nullipara with Ongoing Chemotherapy for Non-gynecologic Malignancies 141
Case 81: VH for Endometrial Carcinoma in Morbidly Obese with History of Caesarean Section 142

Index *143*

4 Section

NULLIPARA AND VAGINAL HYSTERECTOMY

"Being ignorant is not so much a shame, as being unwilling to learn."
—Benjamin Franklin

CASES

Dr Shirish S Sheth

Case 39: VH in Nullipara with Intact Hymen
Case 40: VH with Uterine Debulking
Case 41: VH with Uterine Debulking Plus Right Ovarian Endometrial Cystectomy (H/O Myomectomy)
Case 42: VH with BSO for Bilateral Large Hydrosalpinx
Case 43: VH Plus Vaginal Cuff with BSO in Obese, Diabetic with Endometrial Cancer
Case 44: VH with BSO for Twisted Left Ovarian Cyst

JAYPEE BROTHERS

CASE 39: VH IN NULLIPARA WITH INTACT HYMEN

Name: Miss X
Age: 22 years
Parity: Nullipara

The parents complained that it was impossible to take care of menstruation and maintain menstrual hygiene of their mentally compromised 22-year-old daughter. The menstrual cycles were regular and normal. They were keen to have her uterus removed if possible.[1-4]

She was mentally compromised with IQ (intelligence quotient) of 24 and mental age corresponding to 3 years. Systemic findings were normal though it was not easy to examine her. Clinically, the pelvic examination was not done. Pelvic findings were expected to be normal as abdominopelvic sonography findings were normal. Uterine volume was 35 cm^3. The desire to perform hysterectomy vaginally is important, as the uterine size and other pelvic findings were normal, favoring a vaginal route for hysterectomy.

Diagnosis: Mentally compromised patient.
Operation: Vaginal hysterectomy (VH).
Facts which deter/dissuade VH: Nulliparity with intact hymen (Fig. 1).



Fig. 1: Two young women with mental age of 2 years and 4 years, respectively, with intact hymen.[7]

First pelvic examination that she had was under anesthesia. A small speculum was inserted and rotated through 360° twice or thrice to break the intact hymen, to increase the introital dimension and facilitate vaginal laxity. This was followed by pelvic examination under anesthesia (EUA) to confirm normalcy and absence of any contraindication to VH. This was the first pelvic examination the patient ever had. There was less space for hysterectomy but sufficient enough to start. Thereafter, hysterectomy was carefully and gradually proceeded with. One needs to exercise both extra care and gentleness with the use of a small Sim's speculum instead of the bigger self-retaining large Auward's speculum, small vaginal wall retractors and bladder retractor, an experienced assistant, and the appropriate technique for securing the pedicles. The author secures pedicles with sutures by the clampless technique, which makes it easier because space is at a premium and it is a technique that he regularly practices (Figs. 2A and B).[5-6] Thus, without difficulty the hysterectomy was completed. The tubes and ovaries were normal. As expected, naked eye examination of the cut uterus was normal. Hemostasis was checked and vaginal closure done. Blood loss was less than 50 cc. Blood transfusion was not needed. Postoperatively, the patient was put in a special bed to restrict her movements. The same evening, liquids were started orally and she was made to walk. As the abdomen was intact, the parents were very happy and very cooperative, without any anxiety of wound care. The hospital stay was 3 days as desired by her parents. She made an uneventful, speedy recovery.

Histopathology (HP): Uterus weighed 35 g. Endometrium secretory. No pathology found.

The author has by now performed more than 125 vaginal hysterectomies without a single failure for mentally compromised or disabled patients with intact hymen except in two. When more space is needed, there should be no hesitation in giving a mini-episiotomy or small Schuchardt's incision to enlarge the available space. This was done by the author in the initial period, in 8 out of the first 20 cases and thereafter never needed.[5,7]

What inspired: Past experience.

JAYPEE BROTHERS

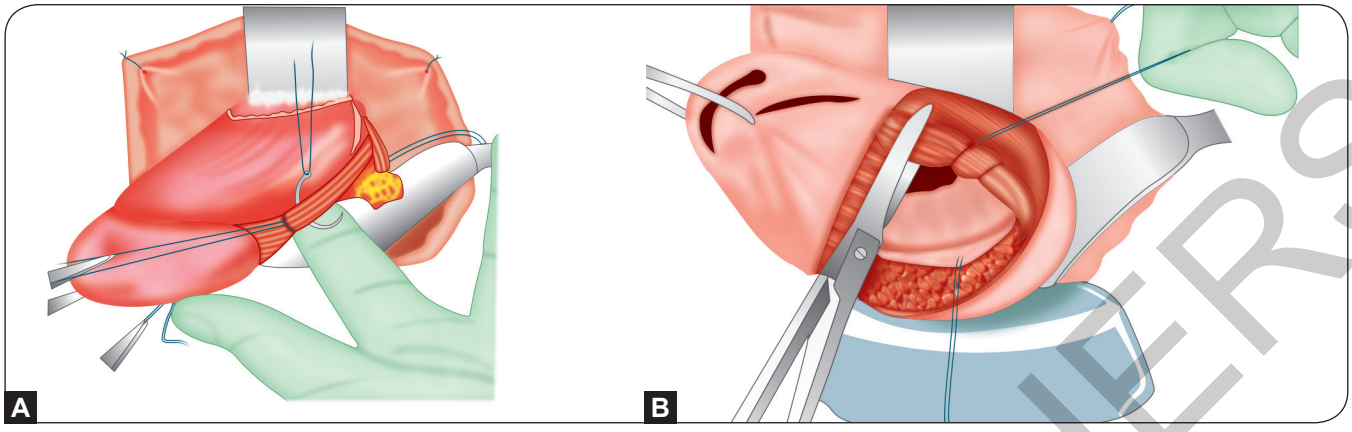

Figs. 2A and B: Suture technique (clampless method): Needle with the suturing material that goes around the tissue to secure, shows finger hooking around uterosacral ligament.[6]

LESSONS

- Intact hymen and therefore nulliparity should never dissuade VH.
- It gives immense experience and serves as a morale booster to remove "nulliparity" as a deterring factor from the mind.

The author demonstrated the above surgery on a similar patient at a VH workshop at Shimoga, Karnataka, India which was very well received.

The parents, mother in particular, was very troubled and overstrained during the daughter's menstrual cycles. The mother moved like her shadow to ensure that her daughter was not physically attacked and harassed by outsiders. To spare her from unwanted pregnancy, laparoscopic tubal sterilization[1] can be done but that does not solve the main problem of menstrual hygiene. The topic of sterilization of such mentally retarded or disabled women is also controversial. Experience in some countries favors hysterectomy[4] as it will eradicate the major problem, i.e. menstrual hygiene care and improve the quality of life. In psychiatry, individual with IQ of 25 or less is called IDIOT and with IQ between 26 and 50 as IMBECILE.

Nullipara and particularly with an intact hymen induce most gynecologists to perform total laparoscopic hysterectomy (TLH) or open the abdomen for hysterectomy. However, for a normal size uterus without pelvic pathology and obstetric trauma in the past, the vaginal route should be an ideal choice. It will spare the abdomen and thus reduce postoperative wound dressing, etc. in a highly disturbed, non co-operative patient.

Zeal and, enthusiasm on the part of the gynecologist and absence of contraindications favors the vaginal route for hysterectomy. To convince parents for a vaginal approach is extremely easy as they want hysterectomy for their child with minimum postoperative care and anxiety, shorter hospital stay, rapid recovery without an external cut and minimal wound care and they get those advantages.[8,9] With numerous mentally challenged women, the least invasive VH can become a boon for India and China and to gynecologists interested in the vaginal route for hysterectomy to master. It will also provide a great boost to deal with VH in nullipara in the future.

JAYPEE BROTHERS

CASE 40: VH WITH UTERINE DEBULKING

Name: Mrs. X
Age: 46 years
Parity: Nullipara.

Not obese with no history of (H/O) hypertension or diabetes.

Uterus 18–20 weeks size, nodular with large fibroid. Cervix was favorable for attempting VH. Fornices were clear.

Sonography: It gave uterine volume of 688 cm^3 with 14 cm × 10.7 cm × 8.5 cm uterine dimensions,[10] multiple fibroids with a large posterior wall fibroid. Tubes and ovaries were normal. Taken as "Trial VH" case.[11]

Diagnosis: Uterine fibroids.

Operation: VH.

What deters or dissuades VH: Large uterus in a nullipara.

Vaginal hysterectomy started as usual, after uterines were secured and cervix well bisected followed by morcellation-n-enucleation of small and large fibroids and morcellation of uterine adenomyotic walls without difficulty.[7,9,10,12-15] Thus, hysterectomy was completed. Normal tubes and ovaries were preserved.

Hemostasis was checked and vaginal closure was done. Blood transfusion was not needed. Hospital stay was 2 days with an uneventful speedy recovery.

Histopathology: It showed uterus weighed 840 g with multiple fibroids and severe adenomyosis.

What inspired:

- Physiological cervical descent plus experience of debulking.

LESSONS

- Nulliparity with large uterus
- Success leads to progress.

JAYPEE BROTHERS

CASE 41: VH WITH UTERINE DEBULKING PLUS RIGHT OVARIAN ENDOMETRIAL CYSTECTOMY (H/O MYOMECTOMY)

Name: Mrs. X
Age: 38 years
Parity: Nullipara
H/O: Abdominal myomectomies
Complains of (C/O): Heavy and painful menses with lower abdominal pain.

Clinically freely mobile uterus of 16 weeks size without nodularity. Healthy cervix with favorable descent to attempt VH. Fornices were clear except right with a soft to firm mass. ?Endometriotic ovarian cyst.
Sonography: It showed uterus with 8.4 cm × 9.8 cm × 9.2 cm uterine dimensions, volume 409 cm^3. Right ovarian cyst 4 cm × 3 cm, endometriotic. Rest of the abdominopelvic findings were normal. CA125 was 266.
Diagnosis: Severe adenomyosis with right ovarian endometrial cyst.
Operation: VH with bilateral salpingectomy and right ovarian cystectomy.
What deters or dissuades VH: Nulliparity plus endometriotic cyst.

After uterines were secured, the cervix was bisected and adenomyotic uterus was debulked. Chocolaty material exuded also from the serosal surface of the uterine walls. Debulking of adenomyotic uterine walls was totally by morcellation with nothing to enucleate.[12,14] Surely, morcellating is tougher than enucleating a fibroid. Small intestines and omentum were adherent to the uterine fundus because of myomectomies in the past. Adhesions were carefully separated to free the uterus, tube and ovary all-round.[15-17] Uterus was distinctly adenomyotic without fibroids.

Right ovary with the small endometriotic cyst was excised and remaining healthy ovary was preserved.

Both tubes were hematosalpinx (missed on sonography), which needed bilateral salpingectomy. Thus, vaginal hysterectomy, right ovarian cystectomy and bilateral salpingectomy was done.[17-19] Left normal ovary was also preserved. She was keen to preserve the ovaries, if healthy. After checking hemostasis, vaginal closure was done. Hospital stay was 3 days. Postoperatively she had uneventful speedy recovery with normal CA125 after 4 weeks.[20]
Histopathology: It showed uterus weighed 470 g with severe adenomyosis and endometriotic cyst of right ovary. Left tube was endometriotic and right tube without pathology. No malignancy.
What inspired: Experience of hysterectomies in nullipara and concomitant salpingo-oophorectomy at VH.

LESSONS

- Large uterus, nullipara and endometriotic cyst dealt with.
- Raised CA125 mainly due to severe adenomyosis and partly due to ovarian endometriotic cyst.

JAYPEE BROTHERS

CASE 42: VH WITH BSO FOR BILATERAL LARGE HYDROSALPINX

Name: Mrs. X
Age: 58 years
Parity: Nullipara
C/O: Postmenopausal spotting for 2 months and pain in lower abdomen.
Last menstrual period (LMP): 8 years back
Mildly obese (BMI 31) with no H/O hypertension or diabetes. She had a normal size uterus with restricted mobility and a normal cervix which had physiological descent to favor VH. Cystic swellings in both lateral fornices, tender and free.
Sonography: Revealed a normal size uterus with volume 38 cm^3, endometrial thickness of 3 mm plus bilateral hydrosalpinx (right 4.6 cm × 3 cm and left 8 cm × 3 cm). Both ovaries normal.
Diagnosis: Bilateral hydrosalpinx.
Operation: VH with bilateral salpingo-oophorectomy (BSO).
What deters/dissuades VH: Nulliparity.
Examination under anesthesia: It confirmed that she was fit for a 'Trial vaginal route' case as VH appeared possible.[10,19] After the uterines were secured, normal size uterus was easily fully bisected into two halves, each with intact upper pedicle including the hydrosalpinx on both sides.

Both tubes and ovaries were mildly adherent to each other but free from surrounding area. This was lysed to free both the tubes and ovaries.

Head high and gravity with suprapubic pressure helped to deliver and exteriorize the hydrosalpinx. The surgical field was well isolated with a sterile plastic sheet. The large left hydrosalpinx was reduced in size by aspiration. Traction on the left half of the uterus gave easy access to the infundibulopelvic ligament (IPL) to perform left salpingo-oophorectomy. This provided ample-free space to complete contralateral salpingo-oophorectomy with traction on the remaining right half of the uterus in a similar fashion and thus complete the hysterectomy with BSO.[16-19] Cut open uterus showed normal endometrium. Both salpingo-oophorectomies included the tubes with hydrosalpinx. In both, the round ligaments were cut as laterally as possible to facilitate traction on the bisected half uterus. Blood transfusion was not needed. Hospital stay was 2 days followed by an uneventful, speedy recovery.
Histopathology: It showed bilateral hydrosalpinx (4+ cm and 8+ cm size) without malignancy. The uterus, cervix and both ovaries were normal. The uterus weighed 46 g. No malignancy.
What inspired: Experience of concomitant salpingo-oophorectomy at VH and hysterectomies in nullipara.

LESSONS

1. Nulliparity should never dissuade VH.
2. Close to completion of hysterectomy, ample free space becomes available to deal with adnexal pathology.

JAYPEE BROTHERS

CASE 43: VH PLUS VAGINAL CUFF WITH BSO IN OBESE, DIABETIC WITH ENDOMETRIAL CANCER

Name: Mrs. X
Age: 54 years
Parity: Nullipara
LMP: 2 years back
C/O: Recurrent postmenopausal bleeding.

The patient was obese [body mass index (BMI) 35] with H/O diabetes but not hypertension. Clinically uterus 6 weeks size, healthy cervix with physiological descent to attempt VH and fornices were clear. She needed "superflexion" position for careful speculum examination to reduce the effects of morbid obesity[21] (Fig. 1).

Sonography findings: It showed uterine volume of 110 cm^3, endometrial thickness 10 mm and normal pelvic findings.

She was referred after H/O hysteroscopy plus dilatation and curettage (D&C) and diagnosis of well-differentiated endometrioid adenocarcinoma for further treatment.

Invariably, advice would have been to have abdominal access, laparotomy or laparoscopic surgery. Hoping for less myometrial invasion, accentuated by the presence of diabetes and obesity favored an attempt to do VH.[6,19,22] Management was discussed at length, pros and cons explained including sparing of opening the abdomen or need to open it, if frozen HP study of the uterus indicated.

Diagnosis: Well-differentiated endometrial carcinoma.
Operation: VH with vaginal cuff plus BSO.
What deters/dissuades: If myometrial invasion is half or more.

Vaginal hysterectomy with vaginal cuff of 3 cm and hysterectomy with unilateral salpingo-oophorectomy was performed and sent for frozen HP study. Fluid from pouch of Douglas was taken for cytology study. Further management depended on frozen HP report of myometrial invasion by malignancy in the hysterectomized uterus. Meanwhile, contralateral salpingo-oophorectomy was completed (Age: 54 years.). Frozen HP study reported 2 mm invasion out of 15 mm myometrial wall/thickness,

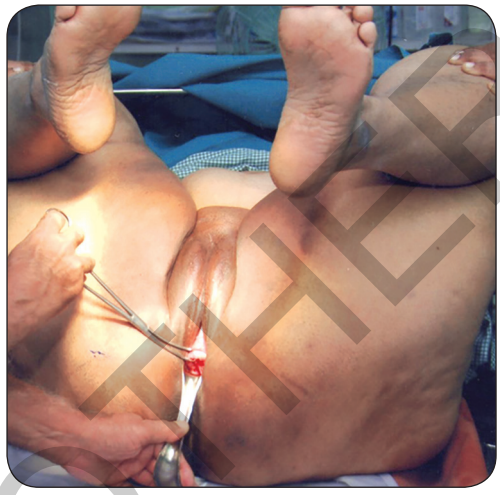

Fig. 1: Superflexion position. The patient's hands keep both feet apart and thus provide a clear view of the vulva and vaginal area.[21]

much less than 50%. This ruled out lymph node removal and therefore, laparotomy or laparoscopic surgery and spared her from the greater invasion of opening the abdomen or 4–5 punctures and resultant greater morbidity in an obese, diabetic woman.[8,23-27] After checking hemostasis, vaginal closure done.

Blood transfusion was not needed. Hospital stay was 2 days with an uneventful postoperative speedy recovery. Later, the radiotherapist opined that she did not need any postoperative radiotherapy.

Histopathology: It showed uterus of 136 g, showed small unhealthy endometrial area, otherwise normal. Myometrial invasion of barely 3 mm out of 15 mm uterine wall. Tubes, ovaries and vaginal cuff were normal.
What inspired: High risk for abdominal surgery.

LESSON

- Trial vaginal route and frozen HP report were immensely useful.

JAYPEE BROTHERS

CASE 44: VH WITH BSO FOR TWISTED LEFT OVARIAN CYST

Please See on page 73 Under Section 3: Vaginal Hysterectomy with Adnexal Pathology, Case 38.

JAYPEE BROTHERS

REFERENCES

1. Van Der Merwe JV, Roux JP. Sterilisation of mentally retarded person. Obstet Gynecol Surv. 1987;42:489-93.
2. Passer A, Rauh J, Chamberlain A, et al. Issues in fertility control for mentally retarded female adolescents: II. Parental attitudes toward sterilization. Pediatrics. 1984;73(4):451-4.
3. Kaunitz AM, Thompson RJ, Kaunitz KK. Mental retardation: a controversial indication for hysterectomy. Obstet Gynecol. 1986;68(3):436-8.
4. Wheeless CR. Abdominal hysterectomy for surgical sterilization in the mentally retarded: a review of parental opinion. Am J Obstet Gynecol. 1975;122(7):872-5.
5. Sheth SS, Malpani AN. Vaginal hysterectomy for the management of menstruation in mentally retarded women. Int J Gynecol Obstet. 1991;35:319-21.
6. Sheth SS. Vaginal hysterectomy. Best Pract Res Clin Obstet Gynaecol. 2005;19(3):307-32.
7. Sheth SS. The nulliparous patient. In: Sheth SS (Ed). Vaginal Hysterectomy, 2nd edition. New Delhi, India: Jaypee Brothers Medical Publishers (P) Ltd; 2014. pp. 63-71.
8. Nieboer TE, Johnson N, Lethaby A, et al. Surgical approach to hysterectomy for benign gynecological disease. Cochrane Database Syst Rev. 2009;(3):CD003677.
9. Agostini A, Bretelle F, Cravello L, et al. Vaginal hysterectomy in nulliparous women without prolapse: a prospective comparative study. BJOG. 2003;110:515-8.
10. Sheth SS, Shah NM. Preoperative sonographic estimation of uterine volume: an aid to determine the route of hysterectomy. J Gynecol Surg. 2002;18:13-22.
11. Sheth SS. Vaginal hysterectomy. In: Studd J (Ed). Progress in Obstetrics and Gynaecology, 10th edition. London, UK: Churchill Livingstone; 1993. pp. 317-40.
12. Tohic AL, Dhainaut C, Yazbeck C, et al. Hysterectomy for benign uterine pathology among women without previous vaginal delivery. Obstet Gynecol. 2008;111:829-37.
13. Kovac RS. Intramyometrial coring as an adjunct to vaginal hysterectomy. Obstet Gynecol. 1986;67:131-6.
14. Sheth SS. Rathi MR. Uterine fibroids. In: Sheth SS (Ed). Vaginal Hysterectomy, 2nd edition. New Delhi, India: Jaypee Brothers Medical Publishers (P) Ltd; 2014. pp. 72-89.
15. Benedetti-Panici P, Maneschi F, Cutillo G, et al. Surgery by minilaparotomy in benign gynecologic disease. Obstet Gynecol. 1996;87(3):456-9.
16. Sheth SS. Concomitant salpingo-oophorectomy at vaginal hysterectomy. In: Sheth SS (Ed). Vaginal Hysterectomy, 2nd edition. New Delhi, India: Jaypee Brothers Medical Publishers (P) Ltd; 2014. pp. 137-49.
17. Sheth SS. Adnexectomy for benign pathology at vaginal hysterectomy without laparoscopic assistance. Br. J Obstet Gynecol. 2002;109:1401-5.
18. Sheth SS. Adnexal pathology at vaginal hysterectomy. In: Sheth SS (Ed). Vaginal Hysterectomy, 2nd edition. New Delhi, India: Jaypee Brothers Medical Publishers (P) Ltd; 2014. pp. 150-62.
19. Sheth SS, Paghdiwalla KP, Hajari AR. Vaginal route: a gynaecological route for much more than hysterectomy. Best Pract Res Clin Obstet Gynaecol. 2011;25(2):115-32.
20. Sheth SS, Ray SS. Severe adenomyosis and CA125. J Obstet Gynecol. 2014;34:79-81.
21. Sheth SS. Superflexion position for difficult speculum examination. Int J Gynaecol Obstet. 2013;121:92-3.
22. Sheth SS. Vaginal hysterectomy as primary route for morbidly obese women. Acta Obstet Gynecol. 2010;89:971-4.
23. Massi G, SaVino L, Susni T, et al. Vaginal hysterectomy vs abdominal hysterectomy for the treatment or stage 1 endometrial adenocarcinoma. Am J Obstet Gynecol. 1996;174:1320-26.
24. ASTEC Study group Efficacy of systematic pelvic lymphadenectomy in endometrial cancer (MRC ASTEC trial): a randomized study. Lancet. 2009;373:125-36.
25. Jones HW. New developments in the surgical management of early endometrial cancer. Obstet Gynecol. 2009;114:2-3.
26. Zanagnolo V, Magrina JF. Carcinoma of the endometrium treated only by vaginal route. Best Pract Res Clin Obstet Gynaecol. 2011;25:239-45.
27. Zanagnolo V, Magrina JF. Vaginal hysterectomy for carcinoma of the endometrium. In: Sheth SS (Ed). Vaginal Hysterectomy, 2nd edition. New Delhi, India: Jaypee Brothers Medical Publishers (P) Ltd; 2014. pp. 216-24.

JAYPEE BROTHERS

for detailed information on obstetrics & gynecology books, visit our website **www.jaypeebrothers.com,** for detailed information on obstetrics & gynecology books, visit our website **www.jaypeebroth**

Advanced Vaginal Surgery

This book—*Advanced Vaginal Surgery*—is featured to take full advantage of vaginal route surgery in gynecology. As demonstrated by the Cochrane database, this is the route long standing and overwhelming evidence supports as the choicest route of hysterectomy 'whenever feasible'. There is no iota of doubt that one's experience impacts surgical ability and outlook as to what this term 'feasible' actually means. Experienced surgeons can furthermore, to the benefit of their patients, selectively expand vaginal route surgery indications to other gynecologic pathologies traditionally managed only by more invasive surgical means.

The book classically depicts the pathological conditions for which, almost as a rule, gynecologists decline vaginal route and choose abdominal access either laparoscopically or by opening the abdomen. No doubt, it needs zeal, enthusiasm and indulgence to initiate and pursue and persevere in the best interests of patients.

The authors strongly feel that when, by highly experienced gynecologists, a large size of one kilo plus uterus can be removed vaginally, why can young colleagues not attempt hysterectomy vaginally, at least, on uterus of 12 weeks' size or less than 300 gms and little larger? Similarly, if the uterus with large cervical myoma can be dealt with patiently via vaginal route, why can several other conditions not be dealt with vaginally? If a woman with history of C-sections plus rupture uterus in the past was dealt with vaginally for hysterectomy, why can straightforward cases of women with one C-section in the past not be dealt vaginally and gradually progress further?

The book gives A to almost Z contents of dealing with pathological conditions vaginally, keeping the abdomen intact and keeping invasion the least.

Shirish S Sheth MD FRCOG (Ad Eundem) FACOG (Hon) FACS FICS FCPS FICOG FAMS FSOGC (Hon) was Hon'ble Professor, Obstetrician and Gynecologist, King Edward Memorial Hospital and Seth GS Medical College, Mumbai, Maharashtra, India for more than 30 years. At present, he is Consultant Gynecologist at Breach Candy and Saifee Hospitals, Mumbai. Dr Sheth was Past President, International Federation of Gynecology and Obstetrics (FIGO). He has lectured in 50 countries.



Dr Sheth has performed vaginal surgery for the operative workshops—London (UK) 6 times, Malaysia and Egypt—2 times each, and China, South Africa, Singapore and Lithuania once each plus several cities in India. He has more than 8 original contributions to the literature.

Dr Sheth is conferred with the Honorary Fellowship by Royal College of Obstetricians & Gynaecologists (RCOG), UK; American College of Obstetricians and Gynecologists (ACOG), USA; Canada; Brazil; Chile; Yugoslavia; Nigeria; Poland, and Australasian Gynaecological Endoscopy & Surgery (AGES), Australia. He served as District Governor, Rotary International from 1983 to 1984.

Carl W Zimmerman MD is Frances and John C Burch Professor of Obstetrics and Gynecology at Vanderbilt University School of Medicine in Nashville, Tennessee, USA.



Dr Zimmerman was Diplomate of the American Board of Obstetrics and Gynecology (ABOG) (1977) and Fellow of the American College of Obstetrics and Gynecology (ACOG) (1978). In 2000, he was elected to the membership of the Society of Gynecologic Surgeons.

Seth Finkelstein MD FACOG FPMRS Diplomate, American Board of Obstetrics and Gynecology (ABOG), Fellow of the American College of Obstetricians and Gynecologists (FACOG) and FPMRS (Female Pelvic Medicine and Reconstructive Surgery), lives in New Jersey, USA with his wife Neela, son Wolff, and dog Maxx. He practices privately in New York City from two facilities—Lenox Hill Hospital in Manhattan, New York, USA, and Kingsbrook Jewish Medical Center in Brooklyn, New York.



His passion for studying and teaching both vaginal surgery and anatomy (interest in either topic invariably will spark deep appreciation for the other) was fostered in large part by the mentorship of the two other authors of this book, along with that of Kovac SR (retired surgeon, Emory University, Atlanta, Georgia), Robert M Rogers (Northwest Women's Healthcare, Montana, USA), and Richard Reid (retired surgeon, Sydney, Australia) to all of whom he wishes to express heartfelt gratitude.

Available at all medical bookstores
or buy online at www.jaypeebrothers.com

JAYPEE BROTHERS
Medical Publishers (P) Ltd.
www.jaypeebrothers.com

Join us on facebook.com/JaypeeMedicalPublishers

Shelving Recommendations
GYNECOLOGY & SURGERY

ISBN 978-93-5270-017-2