ation on orthopedics book, visit our website **www.jaypeebrothers.com,** for detailed information on orthopedics book, visit our website **www.jaypeebrothers.com**

Techniques in ACL Surgery



Sachin Tapasvi

Foreword
Philippe Neyret

JAYPEE

Contents

1. **Placing Correct Portals for Transportal ACL Reconstruction** 1
   Nilesh Kamat
2. **Harvesting and Preparing an Ideal Bone Patella Tendon Bone Graft** 7
   Arumugam S, Prakash Ayyadurai, Suresh Perumal
3. **Harvesting Hamstring Tendons** 16
   Patrick Djian
4. **Cosmetic Harvesting of the Hamstring Tendons** 28
   Wolfgang Franz
5. **Preparation of 5- and 6-Strand Hamstring Tendon Grafts for Single-Bundle Hamstring Anterior Cruciate Ligament Reconstruction** 33
   Charles H Brown Jr
6. **Quadriceps Tendon Autograft in ACL Reconstruction** 47
   Andrew de Vlieg
7. **Harvesting Peroneus Longus Tendon** 53
   Sanjay Trivedi
8. **Clinical Evaluation and Imaging for a Patient with ACL Injury** 62
   Ricardo Bastos, Renato Andrade, Rogério Pereira, Ernesto Pinho, Sérgio Rodrigues-Gomes, Hélder Pereira, João Espregueira-Mendes
9. **Arthroscopic Diagnosis and Injury Patterns of Anterior Cruciate Ligament** 75
   Anshu Shekhar, Sachin Tapasvi, Chirag Thonse, Vikram Kakatkar
10. **How to Perform Notchplasty during ACL Surgery?** 84
    Parag Sancheti, Sunny Gugale, Ashok Shyam
11. **Identifying the Femoral Footprint** 92
    Freddie H Fu, Soheil Sabzevari, Marcio Albers, Thierry Pauyo
12. **Creating a Transportal Femoral Tunnel** 98
    Freddie H Fu, Soheil Sabzevari, Marcio Albers, Thierry Pauyo
13. **Creating Transportal Femoral Tunnel Using Flexible Reamers** 103
    Anant Joshi, Bhushan Sabnis, Sajeer Usman
14. **Creating an Outside-in Femoral Tunnel** 110
    Raju Easwaran
15. **Creating a Transtibial Femoral Tunnel** 118
    Arumugam S, B Bhupesh Karthik, Sadem Amer

16. Identifying the Tibial Footprint 125
Mao Weijia David, Lee Yee Han Dave

17. Creating a Tibial Tunnel 133
Lim Wei-an Joel, Lee Yee Han Dave

18. Suspensory Femoral Fixation Using a Fixed Loop Device 143
Raju Easwaran

19. Adjustable-Loop Suspensory Fixation Device 151
SR Sundararajan, Balaji Sambandam, Amit Kumar Jha, S Rajasekaran

20. Tibial Fixation 159
Sagar Kakatkar, Jonathan Herald

21. Graft Tensioning and Conditioning 166
Miten Sheth, Sachin Tapasvi

22. All-inside ACL Reconstruction 180
SR Sundararajan, Amit Kumar Jha, Balaji Sambandam, S Rajasekaran

23. Anterior Cruciate Ligament Reconstruction in Skeletally Immature Patients 196
Michael P McClincy, Mininder S Kocher

24. Remnant Preservation Techniques in Anterior Cruciate Ligament Reconstruction 209
Sanesh Vijay Tuteja, Bertrand Sonnery-Cottet

25. Anterior Cruciate Ligament Augmentation 223
Humza Shaikh, Marcio Albers, Weimin Zhu, Freddie H Fu

26. Primary ACL Repair 234
Sachin Tapasvi, Anshu Shekhar, Prashanth Gorur

27. Fixation of ACL Avulsion with Screws 244
Abhay Narvekar

28. Fixation of ACL Avulsion Using a Suture-bridge Technique 253
Roshan Wade, Chaitanya Waghchoure

29. Lateral Extra-articular Tenodesis 263
Pederzini LA, Cheli AF, Serafini F, Nicoletta F

30. Minimally Invasive Anterolateral Ligament Reconstruction 279
Sachin Tapasvi, Anshu Shekhar, Shantanu Patil

31. Double Bundle Anterior Cruciate Ligament Reconstruction 295
Deepak Chaudhary, Deepak Joshi, Ankit Goyal

32. Anterior Cruciate Ligament Reconstruction Bone Tunnel Placement Using Intraoperative Fluoroscopy 303
Thomas Harlem, Eivind Inderhaug, Charles H Brown Jr

33. Rehabilitation after Anterior Cruciate Ligament Reconstruction: Optimizing Outcomes by Restoring Dynamic Knee Stability 322
John Nyland, Jun Matsuno

34. Improving Outcomes of ACL Reconstruction: Pharmacological Measures 344
Anshu Shekhar, Sachin Tapasvi

Index 351

CHAPTER

4 Cosmetic Harvesting of the Hamstring Tendons

Wolfgang Franz

INTRODUCTION

Arthroscopic anterior cruciate ligament (ACL) reconstruction has become a routine elective procedure in sports medicine. The most commonly used grafts for ACL reconstruction are the bone-patellar tendon-bone graft, the quadriceps tendon, and the hamstring tendon (HT) graft.[1-4] But harvesting the tendon graft is one of the most challenging aspects of hamstring ACL reconstruction.

Several reports have demonstrated fewer donor-site-related problems, so HT reconstruction has gained increasing popularity in recent years.[5-7] However, some studies have reported permanent postoperative paresthesia in the distribution of the saphenous nerve with the use of HT grafts.[6,8,9] HT harvest is commonly performed with a longitudinal anterior skin incision directly over the pes anserinus on the proximal tibia.[9] Paraesthesia over the anterolateral aspect of the leg postoperatively due to an injury to the saphenous nerve is a well-known complication linked to this approach.[10] Sanders et al. found that up to 74% of their patients reported reduced sensation in the distribution of the saphenous nerve with the anteromedial approach.[10] Identifying and releasing the HTs at their distal insertion can be technically demanding sometimes.[11]

To avoid these issues related to the anteromedial approach we have been using a minimal invasive technique for harvesting the HTs from a posteromedial incision in the popliteal fossa since 2001 and have performed this procedure in over 5,000 patients. The surgical technique was first published in 2004 and has subsequently been described by Kodkani and later, with an additional anterior incision, by Prodromos.[12-14]

Last but not least, it yields superior cosmetic results, since the scar will be nearly invisible in the backside of the knee.

SURGICAL TECHNIQUE

With the help of an assistant, the knee is flexed to approximately 40° and the hip maximally externally rotated (Fig. 4.1). The assistant must not hold the leg at the calf but only at the foot and thigh. A small transverse incision about 20–30 mm, in line with the skin crease, is made directly over the semitendinosus (ST) tendon in the posteromedial aspect of the popliteal fossa. At this location, the tendon lies subcutaneous and can easily be palpated. The site of the incision is visible as a small dimple overlying the tendon—this landmark has previously been named "Jobert's groove" in Pernkopf's topographical anatomy atlas.[15] Subcutaneous tissue overlying the tendon is usually scarce, even in obese patients.

JAYPEE BROTHERS



Fig. 4.1: Positioning of the leg and skin incision.

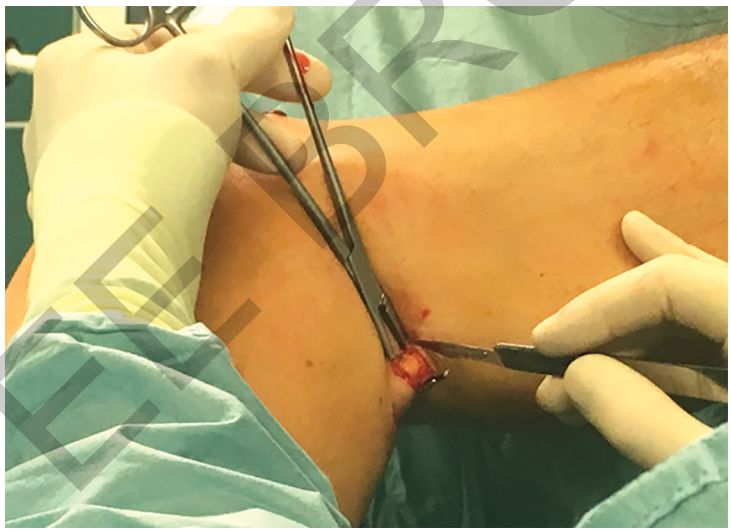

Fig. 4.2: Hooking the tendon and releasing surrounding tissue.

Once the skin incision is made, the fascia covering the tendon is cut longitudinally over the tendon under direct vision. A curved artery clip is hooked around the tendon and a FiberTape® (Arthrex, Naples, FL) suture is pulled through and looped around the tendon to grip the graft (Fig. 4.2).

With the knee flexed to 90° the tendon is mobilized and pulled out with a quite powerful motion to distal and proximal.

An open tendon stripper is threaded over the tendon and pushed proximally to release the tendon of its muscular attachment. The stripper has to go forward with minimum force. Otherwise there will be an

JAYPEE BROTHERS

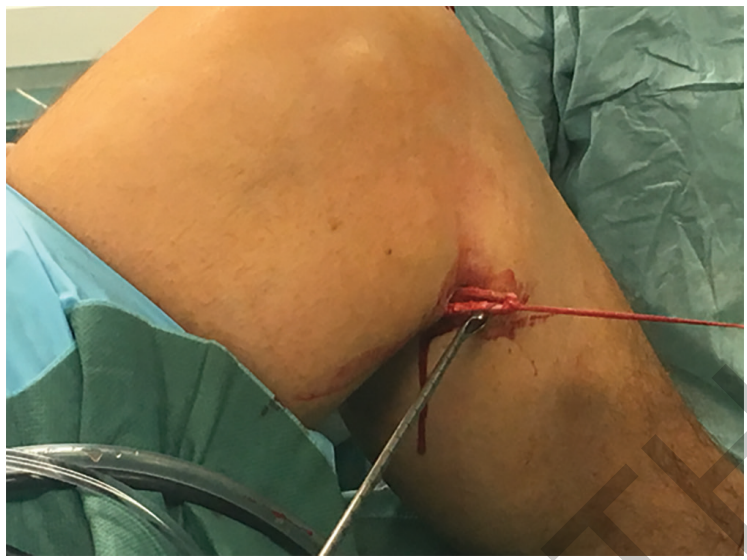

Fig. 4.3: Pulling out the tendon and applying the open stripper.

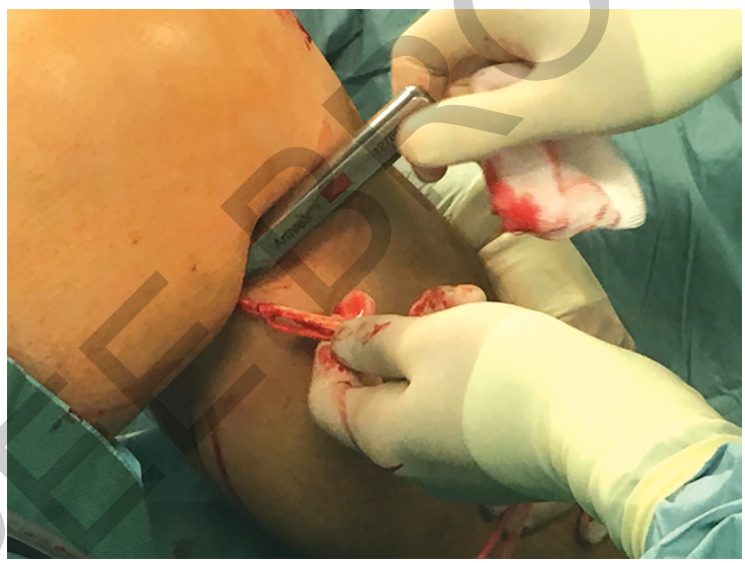

Fig. 4.4: Releasing the tendon proximally.

obstacle by the fascia and the fascial incision should be slightly increased (Fig. 4.3). It must also be ensured that there are no fascial bands which may lead to premature tendon amputation.

The free end of the tendon is then delivered out of the wound. At this point we scrape remaining muscular tissue off the proximal tendon to facilitate passage of a closed tendon stripper (Fig. 4.4).

The closed tendon stripper is then advanced distally while a controlled pull on the tendon is maintained. With slow careful twisting motions the tendon harvester is pushed further distal to release the tendon from its insertion on the tibia. Distally, the stripper can be seen through the skin over the medial aspect of the proximal tibial crest (Fig. 4.5).

JAYPEE BROTHERS

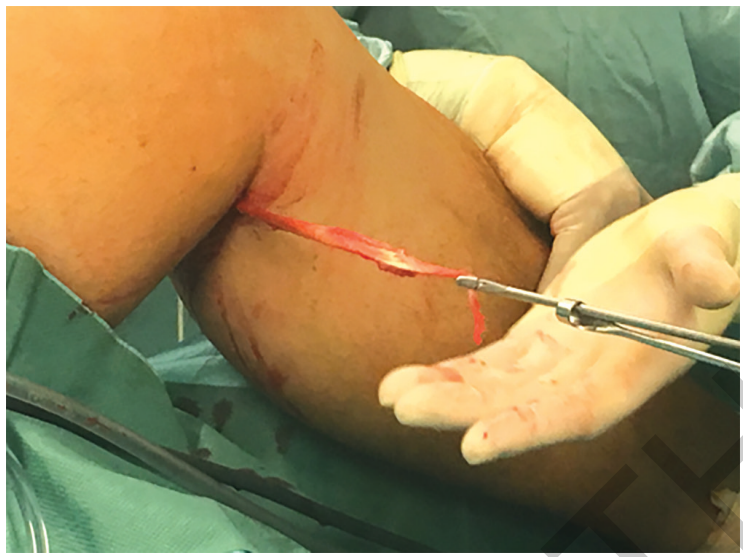

Fig. 4.5: Applying the closed stripper.

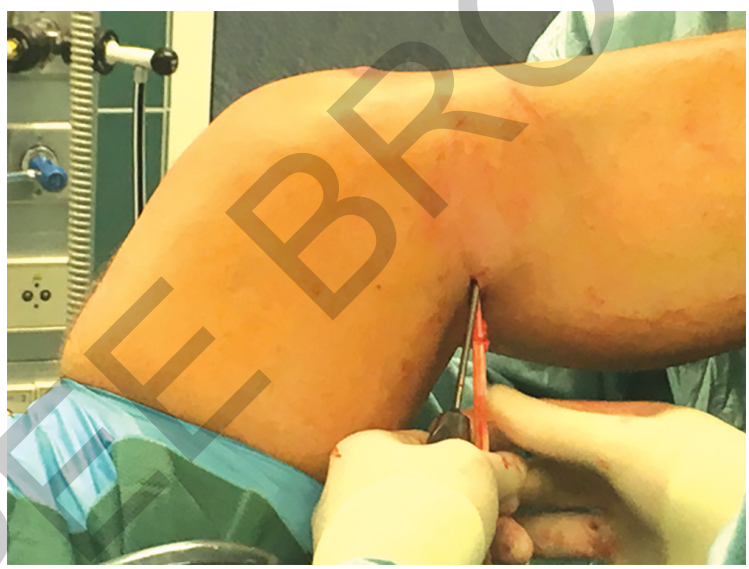

Fig. 4.6: Releasing the tendon distally.

If required, the gracilis tendon can be harvested in the same way. It lies approximately 10 mm medial to the ST tendon and can be delivered through the same skin incision.[14] The skin is closed with interrupted nonabsorbable sutures. Care has to be taken not to catch deeper tissues with the needle (Fig. 4.6). It is not necessary to close the sartorius fascia.

In a study published in 2016, we assessed the incidence of iatrogenic injury to branches of the saphenous nerve, the length of the harvested ST tendon and the time needed to harvest the tendon graft comparing our posteromedial approach to the conventional anteromedial approach.[16] This study confirmed our hypothesis that ST tendon harvesting through a small incision in the popliteal fossa is

JAYPEE BROTHERS

quicker, needs a smaller incision, and avoids the risk of injury to the saphenous nerve. We, therefore, recommend its routine use for hamstring graft harvesting.

https://www.arthrex.com/resources/video/5C9KtJqFiUW5uAFGkEs1lA/minimally-invasive-postero-medial-hamstring-graft-harvesting

PEARLS AND PITFALLS

The positioning of the leg is essential for this technique. The assistant should hold the foot and the distal thigh, but not any soft tissues. If the tendon cannot be palpated through the skin, especially in obese patients, the skin incision should be made right over the medial dimple of the fossa. By this way the tendon always can be found. Then it is important to cut the fascia over the tendon in parallel. This incision should be large enough to prevent the stripper from adhering there. Finally, when using the closed stripper to release the tendon from the pes anserinus, it should be done with controlled force. First the closed stripper should go ahead with the tendon and then the pulling force should be slightly increased while turning the stripper back and forth and by this way approaching to the tibial attachment of the tendon.

REFERENCES

1. Eichhorn HJ, Birkner W. Aktuelle Trends zur Rekonstruktion des vorderen Kreuzbandes. SFA Arthroskopie Aktuell. 2006;19:5-8.
2. Aglietti P, Buzzi R, Zaccherotti G, et al. Patellar tendon versus doubled semitendinosus and gracilis tendons for anterior cruciate ligament reconstruction. Am J Sports Med. 1994;22(2):211-7;discussion 217-8.
3. Feller JA, Webster KE. A randomized comparison of patellar tendon and hamstring tendon anterior cruciate ligament reconstruction. Am J Sports Med. 2003;31(4):564-73.
4. Pinczewski LA, Lyman J, Salmon LJ, et al. A 10-year comparison of anterior cruciate ligament reconstructions with hamstring tendon and patellar tendon autograft: a controlled, prospective trial. Am J Sports Med. 2007;35(4):564-74.
5. Rubinstein RA Jr, Shelbourne KD, VanMeter CD, et al. Isolated autogenous bone-patellar tendon-bone graft site morbidity. Am J Sports Med. 1994;22(3):324-7.
6. Yasuda K, Tsujino J, Ohkoshi Y, et al. Graft site morbidity with autogenous semitendinosus and gracilis tendons. Am J Sports Med. 1995;23(6):706-14.
7. Feller JA, Webster KE, Gavin B. Early post-operative morbidity following anterior cruciate ligament reconstruction: patellar tendon versus hamstring graft. Knee Surg Sports Traumatol Arthrosc. 2001;9(5):260-6.
8. Simonian PT, Harrison SD, Cooley VJ, et al. Assessment of morbidity of semitendinosus and gracilis tendon harvest for ACL reconstruction. Am J Knee Surg. 1997;10(2):54-9.
9. Brown CH Jr, Steiner ME, Carson EW. The use of hamstring tendons for anterior cruciate ligament reconstruction. Technique and results. Clin Sports Med. 1993;12(4):723-56.
10. Sanders B, Rolf R, McClelland W, et al. Prevalence of saphenous nerve injury after autogenous hamstring harvest: an anatomic and clinical study of sartorial branch injury. Arthroscopy. 2007;23(9):956-63.
11. Pagnani MJ, Warner JJ, O'Brien SJ, et al. Anatomic considerations in harvesting the semitendinosus and gracilis tendons and a technique of harvest. Am J Sports Med. 1993;21(4):565-71.
12. Franz W, Ulbrich J. Eine neue Technik zur Entnahme der Semitendinosussehne für den Kreuzbandersatz. Arthroskopie. 2004;17(2):104-7.
13. Kodkani PS, Govekar DP, Patankar HS. A new technique of graft harvest for anterior cruciate ligament reconstruction with quadruple semitendinosus tendon autograft. Arthroscopy. 2004;20(8):e101-4.
14. Prodromos CC, Han YS, Keller BL, et al. Posterior mini-incision technique for hamstring anterior cruciate ligament reconstruction graft harvest. Arthroscopy. 2005;21(2):130-7.
15. Pernkopf E. Topographische Anatomie des Menschen. Lehrbuch und Atlas, II. Urban und Schwarzenberg. 1941.
16. Franz W, Baumann A. Minimally invasive semitendinosus tendon harvesting from the popliteal fossa versus conventional hamstring tendon harvesting for ACL reconstruction: A prospective, randomised controlled trial in 100 patients. Knee. 2016;23(1):106-10.

JAYPEE BROTHERS

tailed information on orthopedics book, visit our website **www.jaypeebrothers.com,** for detailed information on orthopedics book, visit our website **www.jaypee

Techniques in
ACL Surgery

Salient Features

- Thorough description of each aspect of ACL surgery
- Over 300 surgical images and illustrations
- Expert surgeons' Tips and Tricks for a particular technique
- Separate section on Pears and Pitfalls of each technique
- Detailed section on Rehabilitation and Return to sport assessment
- A technical guide and comprehensive text for every knee arthroscopist.



Sachin Tapasvi MS (Ortho) DNB (Ortho) FRCS (Glasgow) graduated top of his class from Byramjee Jeejeebhoy Medical College, Pune, Maharashtra, India in 1991 and is today one of the leading arthroscopy and joint replacement surgeons in India. He served his fellowship in Adelaide, Australia where he acquired extensive training in the science and art of orthopedic surgery. At 47, he has behind him 19 years of extensive experience in sports medicine, arthroscopic surgery and arthroplasty. He is an astute clinician who renders his services across multiple hospitals in Pune and Nashik. His passion in sharing his knowledge and experiences sees him constantly engaged with his fellows and as a faculty in academic events around the globe. His zeal for research is reflected in multiple peer-reviewed publications in scientific journals and his involvement in numerous clinical trials. He also serves at official positions in several regional, national and international academic bodies. He has special love for wildlife photography and has trekked many a mile in harsh weather and difficult terrains to capture those elusive shots.

Available at all medical bookstores
or buy online at www.jaypeebrothers.com

JAYPEE BROTHERS
Medical Publishers (P) Ltd.
www.jaypeebrothers.com

Join us on facebook.com/JaypeeMedicalPublishers

Shelving Recommendations
ORTHOPEDICS AND SURGERY

ISBN 978-93-5270-036-3