it our website **www.jaypeebrothers.com,** for detailed information on endocrinology books, visit our website **www.jaypeebrothers.com**

Cutaneous Manifestations *of* DIABETES





Emilia Noemí Cohen Sabban

Foreword
Ana Kaminsky

JAYPEE

Contents

1. **Definition, Classification and Diagnosis of Diabetes Mellitus** **1**
   Félix Miguel Puchulu

2. **Introduction to Cutaneous Manifestations of Diabetes Mellitus** **11**
   Emilia Noemí Cohen Sabban

3. **Cutaneous Barrier and Diabetes** **15**
   Patricia Troielli, Lucrecia Juárez

4. **Cutaneous Markers of Diabetes Mellitus** **31**
   Emilia Noemí Cohen Sabban

5. **Skin-Thickening Syndrome** **53**
   Emilia Noemí Cohen Sabban, Horacio Antonio Cabo

6. **Acanthosis Nigricans and Other Cutaneous Manifestations of Insulin Resistance and Metabolic Syndrome** **73**
   Emilia Noemí Cohen Sabban

7. **Cutaneous Infections in Diabetics** **83**
   Part 7A: Fungal Infections in Diabetics ***83***
   Roberto Arenas, César Iván Eugenio-González

   Part 7B: Bacterial Infections in Diabetics ***92***
   Emilia Noemí Cohen Sabban

8. **Dermatoses Most Frequently Related to Diabetes** **105**
   Emilia Noemí Cohen Sabban

9. **Cutaneous Manifestations Induced by Antidiabetic Treatment** **137**
   Emilia Noemí Cohen Sabban, Marina Luz Margossian

10. **Cutaneous Manifestations due to Vasculopathy, Neuropathy and Diabetic Foot Syndrome** **149**
    Emilia Noemí Cohen Sabban

11. **Diabetes, Non-Enzymatic Glycation and Aging** **167**
    Emilia Noemí Cohen Sabban, Denise Steiner

12. Nail Alterations in Diabetic Patients **177**
Judith Dominguez-Cherit, Michelle Gatica-Torres

13. Ulcers and Wound Healing in Diabetics **187**
Patricia Troielli, Lucrecia Juárez

14. Multidisciplinary Approach in Managing Wound Healing **201**
Anahi Belatti, Noelia Capellato, Maria Gala Santini Araujo

Index *221*

CHAPTER

4

Cutaneous Markers of Diabetes Mellitus

Emilia Noemí Cohen Sabban

INTRODUCTION

Diabetes mellitus (DM) has a wide array of cutaneous manifestations which constitute, on the whole, a variety of disorders resulting mostly from long-lasting diabetes, and which impact significantly the patient's morbidity and mortality.

Many theories have been proposed to explain the way in which hyperglycemia can produce neuronal and vascular disorders which are a landmark of this disease. They can be separated into those that emphasize the direct toxic effect of hyperglycemia and its derivatives on the tissue (i.e. oxidants, hyperosmolarity or glycosylated products), where the skin would not be an exception; and those that give pathophysiological importance to a sustained disturbance of cell signaling pathways (i.e. changes in phospholipids or kinases) induced by products of the glucose metabolism.[1,2]

Cutaneous markers of DM are a heterogeneous group of skin diseases (dermatoses) that help us to rule out an underlying DM. Even though, there is still controversy in the literature regarding which of these cutaneous disorders present more frequently in one or another type of diabetes; no statistically significant differences were found between them in different studies of a wide series of cases.[3,4]

What is uniformly established is the fact that some of these cutaneous manifestations increase their incidence in longlasting DM, such as, diabetic dermopathy (DD) and spontaneous diabetic blister (DB), diabetic foot and gangrene.[5,6]

NECROBIOSIS LIPOIDICA

Necrobiosis lipoidica (NL) is a chronic granulomatous skin disease that affects 0.3–1.2% of type I and II diabetic patients. Lesions favor young women between 30 years and 40 years, are asymptomatic and are characteristically found on anterior and lateral surfaces of lower legs (i.e. pretibial region); although they may also be present on arms, on the trunk, the face and the scalp (Fig. 1). In 60% of the cases, it occurs in individuals with diagnosed DM. In case the diagnosis is not confirmed, it is necessary to follow up on a yearly basis for a DM diagnosis, since NL can be the first manifestation of this condition.

JAYPEE BROTHERS

Different causative factors have been proposed for NL: microangiopathy, endarteritis obliterans, vasculitis, immunological mechanisms, delayed hypersensitivity, nonenzymatic glycation (NEG), trauma, platelet aggregation, alteration of neutrophil mobility and vascular occlusion with subsequent venous insufficiency. Vascular compromise is one of the main causative factors, with vessels thickening and occlusion due to glycoprotein deposits. The upregulation of GLUT-1 (glucose transporter of erythrocytes) receptor in fibroblasts, detected through immunohistochemistry, indicates that the abnormalities in glucose transportation in these cells could explain some NL findings.[7]

Clinically, they start as small erythematous well-defined nodules, which slowly enlarge forming plaques with elevated edges whereas the center is flattened and atrophic, through their surface, the underlying vessels are visible (Figs. 2 to 4). These lesions can be single or multiple, unilateral or bilateral (Figs. 5 to 7).[8]



Fig. 1: Multiple plaques of necrobiosis lipoidica on pretibial region.



Fig. 2: Erythematous nodules. Initial form of necrobiosis lipoidica.

JAYPEE BROTHERS

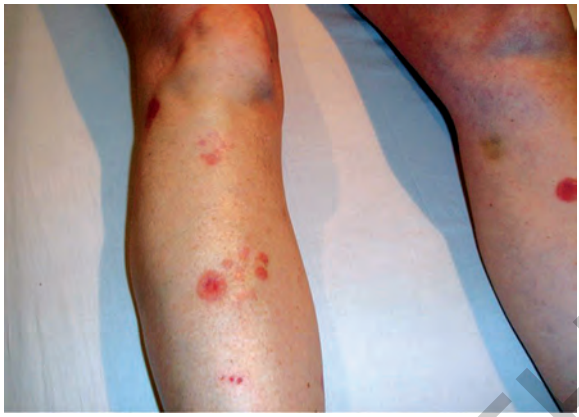

Fig. 3: Erythematous lesions and nodules of necrobiosis lipoidica.



Fig. 4: On the right leg, the lesion shows an elevated edge and atrophic center; while on the left, the lesion has appeared more recently.

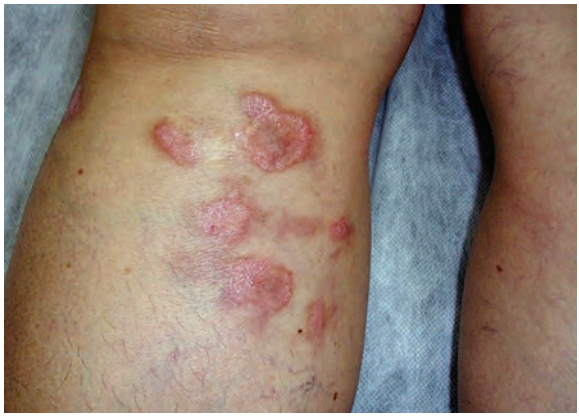

Fig. 5: Multiple plaques of necrobiosis lipoidica.

JAYPEE BROTHERS



Fig. 6: Active plaque of necrobiosis lipoidica, with erythematous and elevated edges. Note the hair loss.



Fig. 7: Bilateral multiple plaques of necrobiosis lipoidica on both lower extremities.

Different clinical forms are described: morpheiform, ulcerated, granuloma annulare-like (GA), nodular and a transepidermal elimination variant.[9,10] The ulcerated form, spontaneous or due to trauma, comprises 15% to 35% of the cases and unlike the other variants, it is painful.[11]

Necrobiosis lipoidica can get pigmented in its essentially chronic evolution and once settled, it does not disappear (Figs. 8 and 9).

From a histological point of view (HP), a normal or atrophic epidermis is observed; in the dermis a palisade granuloma formed by a central zone with disrupted collagen bundles, spaced apart, enucleated and amorphous, surrounded by a lymphohistiocytic crown and epithelioid and giant cells (Fig. 10). The vessels present typical thickening of the base membrane distinctive of DM and endothelial cell proliferation. The histopathology helps

JAYPEE BROTHERS

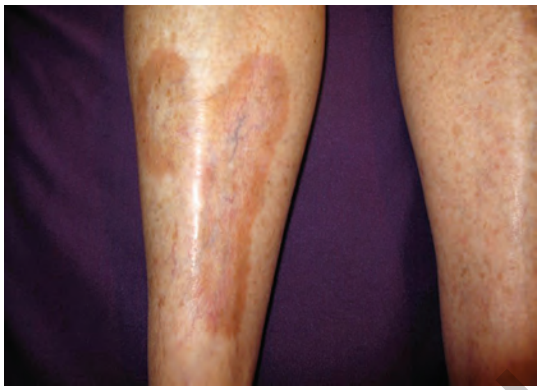

Fig. 8: Plaque of necrobiosis lipoidica with pigmented edges, while in the atrophic center the vessels are visible.



Fig. 9: Plaque of necrobiosis lipoidica with pigmented edges and atrophic center where vessels can be seen through transparency.

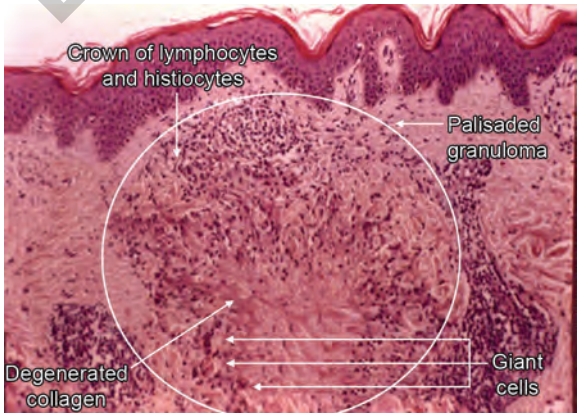

Fig. 10: Histopathology of necrobiosis lipoidica and granuloma annulare. Palisaded granuloma.

JAYPEE BROTHERS

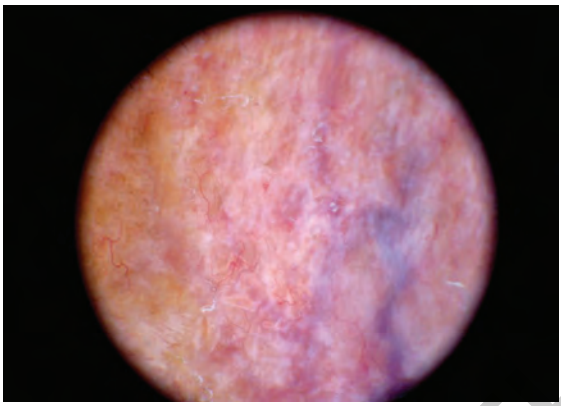

Fig. 11: Dermoscopic image of a plaque of necrobiosis lipoidica. Vascular pattern: arborizing telangiectasia on a yellowish background.

differentiate NL (where extracellular lipids are observed) from GA (where granulomas are more superficial and with abundant deposits of mucin in the central area).[12,13]

Bakos et al. revealed dermoscopic findings related to recent NL that show a vascular pattern with arborizing telangiectasias and hairpin vessels on a yellowish background (Fig. 11).[14,15]

Among differential diagnosis for NL, we cannot forget to mention GA lesions lacking atrophia and the yellowish color; sarcoidosis, necrobiotic xanthogranuloma, morphea and initial forms of leprosy (undetermined leprosy), among others.

The most important complications of NL are ulceration, which can be observed in 30% of the cases, spontaneous or due to minor trauma; an evolution towards squamos cell carcinoma is even weirder, especially in the case of chronic and ulcerated lesions.[16]

There is still no effective treatment for NL and although there are many reports on cases with diverse degrees of therapeutic success, we are still missing controlled and randomized studies that include an important amount of patients.

Due to its antiinflammatory properties, the mainstay of treatment for NL includes topical, intralesional and short courses of systemic corticosteroids. If intralesional corticosteroids are the chosen modality, the application has to be done on the edge due to two reasons. Firstly, the central part is atrophic or will evolve towards atrophy, so these agents are contraindicated. Secondly, the edge is the active part and these agents reduce inflammation and will avoid progression.

The hyperglycemic effect of corticosteroids is well known, so their indication in diabetic patients must be accompanied by a strict control of glucose blood levels, especially when applied on extensive areas or for a long period of time.[17]

JAYPEE BROTHERS

Among topical therapies, the calcineurin inhibitors act inhibiting the activation of T-cells and consequently the production of interleukins (IL) and also their proliferation, resulting in an antiinflammatory and immunomodulatory effect.[18]

Another antiinflammatory therapy is phototherapy, applying both psoralen + ultraviolet A (PUVA) and UVA-1 which apparently are more beneficial in early stages of the disease.[19,20]

Other options include drugs that act on hemostasis (vascular thrombosis) like, for example, the combination of aspirin (40–80 mg a day) and dipiridamol (200 mg a day), which inhibit platelet aggregation and decrease blood viscosity; pentoxifylline, a methylated xanthine that further acts on blood cell aggregation and decrease the production of tumoral necrosis factor alpha (TNF-α), enhancing the blood flow. Dose: 400 mg, 3 times a day.[21]

Antimalarials (hydroxychloroquine and chloroquine) inhibit chemotaxis of macrophages that participate in the formation of granulomas, although their effects are not immediate. Additionally, chloroquine inhibits platelet aggregation avoiding occlusion of cutaneous blood vessels.[22,23]

Fumaric acid esters inhibit inflammatory cytokines and prevent lymphocyte-T proliferation. Even though the outcomes are encouraging, it is poorly tolerated due to nauseas, dose-dependent adverse events and lymphopenia present in almost half of the patients. Start with a dose of 30 mg of dimethyl fumarate, increasing progressively until you reach 240 mg.[24,25]

Cyclosporine, an immunosuppressive drug, is indicated in cases of refractory ulcerated NL, because it inhibits lymphocyte production of IL-2 avoiding proliferation of these cells and thus, their immune response. A dose of 2–4 mg/kg a day is responsible for a fast improvement with healing of the ulcer in 2–4 months approximately, but generally presenting recurrence when discontinued. Due to its adverse effects related to nephrotoxicity, it is contraindicated in diabetic patients with previous nephropathy. It is necessary to closely monitor blood pressure, potassium, blood count and renal function.[26] Mycophenolate mofetil is another immunosuppressant which has cytostatic effects on lymphocytes. As cyclosporine, it is effective, but recurrences are common after discontinuation of therapy.

Recently, glitazones and photodynamic therapy (PDT) have been successfully implemented. Based on the role of TNF-alpha in the formation of granulomas, biological agents like anti-TNF-alpha (etanercept and infliximab), have been used to treat cases of refractory NL.[27]

Considering that NL is a benign skin disease, it is not unreasonable to be careful anyway. In order to avoid complications and promote wound healing in ulcerated cases, it is important to modify certain lifestyle habits like quit smoking, avoid traumas and apply compression in case of lymphedema and venous stasis (Table 1).

JAYPEE BROTHERS

TABLE 1: Group 1. Cutaneous markers of diabetes mellitus.

	NL	*GGA*	*DD*	*AD*	*Xanthosis*
Incidence	0.3–1.6%	Generally low	70%	<1%	+or- 10%
Age	Higher percentage between 25 and 40	50 years	More frequent in adult diabetic patients (its frequency increases with age).	Its frequency increases with age	Adults
Gender	80% women	2:1 Women/Men	70% men	Same	Same
Relationship with diabetes	15% precedes diabetes 25% simultaneous 60% in diabetic Patients 10% in Non-diabetic patients.	30% to 40% of the generalized form is associated with diabetes	80% in diabetic patients 20% in non-diabetic patients	Only diabetic patients	In diabetic and non-diabetic patients
Importance	An early diagnosis can contribute to therapeutic outcome	Search for association with diabetes	One of the most frequent markers and signal for the early diagnosis of complications	Indicator of poor prognosis	Related to advanced glycation products (AGEs)

GENERALIZED GRANULOMA ANNULARE

The relationship between GA and DM, especially its generalized form (GGA), is weaker if compared with other cutaneous markers. It is a skin disease which occurs more frequently in adult diabetic type 1 or 2 women.[28]

It is clinically characterized by erythematous, pink or skin colored papules, which coalesce forming annular, arcuate or polycyclic, well-defined plaques (Figs. 12 to 15). They are asymptomatic or slightly pruritic. Even though their etiology is not defined, it has been said that a delayed hypersensitivity reaction to a certain unknown antigen could be the cause.[29]

The following clinical forms have been described: localized GA (75%) (Figs. 16 and 17), generalized GA–accounts for 8.5–15% of GAs and is the one associated with DM (Figs. 18 and 19), subcutaneous nodules more common during childhood; perforating and macular erythematous, which are very rare. There also exist atypical variants: lichenoid and verrucous.

The generalized form can persist for years, unlike the localized variety, which, in general, spontaneously involves.[30,31]

In histological terms, the epidermis is normal. The upper half of the dermis is featured by degenerated collagen bands, a lymphohistiocytic infiltrate that surrounds it forming a palisade or with an interstitial distribution, and abundant mucin which is the key to distinguish it from other granulomatous diseases like NL, rheumatoid nodule, sarcoidosis, etc.[32,33]

JAYPEE BROTHERS



Fig. 12: Plaque formed by confluence of papules with a polycyclic or round shape.



Fig. 13: Plaque of granuloma annulare on both armpits.



Fig. 14: Granuloma annulare. Plaques on dorsum of hands.

JAYPEE BROTHERS



Fig. 15: Granuloma annulare on anterior side of a wrist.



Fig. 16: Localized granuloma annulare.



Fig. 17: Localized granuloma annulare.

JAYPEE BROTHERS



Fig. 18: Generalized granuloma annulare.



Fig. 19: Generalized granuloma annulare.

A greater incidence of DM than expected has been observed in patients with generalized and perforating GA. Other associations that have been described include alterations of lipid metabolism, malignancies and paraneoplastic syndromes (lymphomas, leukemia and solid lung and breast cancers frequently), thyroid disorders, infections (hepatitis C virus, hepatitis B virus and human immunodeficiency virus) and sarcoidosis. There are also some curious reports of cases with coexisting NL and GA.[34,35]

The chosen therapy will depend on the severity of the disease, comorbidities, possible adverse effects and the patients' preferences. Many patients with the

JAYPEE BROTHERS

localized form of the disease are frequently interested in getting treatment for cosmetic reasons. Both, topical corticosteroids and IL are their first option. Other therapies include calcineurin inhibitors and cryotherapy.[36]

Even if there is no successful treatment for all GGA cases, systemic corticosteroids and DAPS® (diamino-diphenyl sulfone) in a dose of 100 mg/day would be the first line of choice.[37,38]

Retinoids, pentoxifylline, antimalarials, PUVA and PDT are some of a long list of treatment options for the generalized form.[39]

Sporadically, but with a certain therapeutic success, are colchicines and potassium iodide alone or combined with nicotinamide, among others (Table 1).[40]

DIABETIC DERMOPATHY

It is also known as pretibial pigmented patches.[41] DD appears in type 1 and 2 diabetics, predominantly in males and patients around the age of 50. Present in 60% of diabetic patients, its incidence increases along with age and duration of DM. Of all the patients with pretibial patches, 80% are diabetics, 20% are not, therefore it is not considered a specific manifestation of DM. Its pathogenesis is mixed and simultaneous to the following processes: microangiopathy, inflammatory processes and fibrosis. In clinical terms, it consists of small brownish plaques with demarcated limits, round or oval in shape, with a smooth surface, without scales or crusts, organized in groups or alone, sometimes even in a linear pattern.[42]

The lesions appear preferably on lower extremities (pretibial zone), although some have been described in other areas; they are usually bilateral, but not simmetrical. They are asymptomatic, their evolution is chronic and they do not improve with diabetes control (Figs. 20 to 23).



Fig. 20: Diabetic dermopathy.

JAYPEE BROTHERS

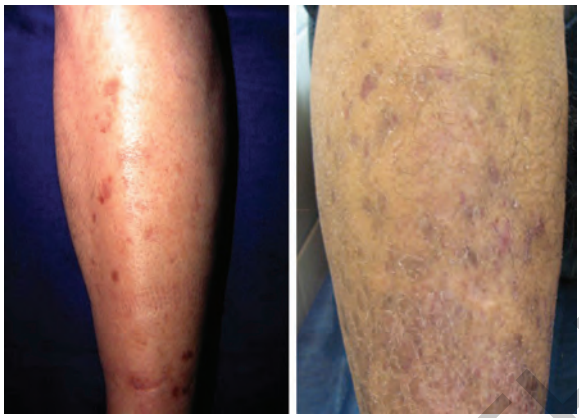

Fig. 21: Diabetic dermopathy.



Fig. 22: Diabetic dermopathy.

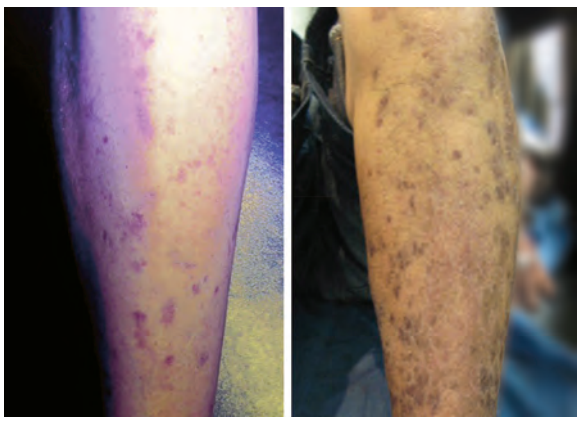

Fig. 23: Diabetic dermopathy.

JAYPEE BROTHERS

Some can evolve towards a light atrophy that together with its brownish color has been given formerly the name of "circumscribed brown atrophy".[43]

Histopathologically, one can observe epidermal atrophy and thickening of the wall of microcapillary with microhemorrhage in the dermis. Its pigmentation can be explained by the hemosiderin and to a lesser extent, melanin distribution in the perivascular histiocytes.[44]

There is an unfavorable association between DD and serious microvascular complications of DM (neuropathy, retinopathy and nephropathy). Its correlation with the rise of glycosylated hemoglobin (HbA1c) and long-lasting DM has also been confirmed; therefore, the presence of DD should be considered a warning sign.[45,46]

Generally, there is no need for treatment, nor is there an effective one; some lesions resolve spontaneously (Table 1).[47]

DIABETIC BLISTER (BULLOSIS DIABETICORUM)

It happens in less than 1% of the patients, but it is the only pathognomonic marker of diabetes; that is to say, it appears only in diabetic patients and in both genders equally. Its incidence increases with age. Its pathogenesis is still to be clarified, but the following possible pathophysiological mechanisms have been considered: the skin of diabetic patients is less resistant to blister formation, in part, due to cutaneous fragility that results from diabetic angiopathy, and NEG of anchor fibers.[48,49]

Clinically, it consists in one or more tense blisters with serous or serohematic content and firm consistency, not related to trauma or friction. The blisters are painless, do not have signs of inflammation and they tend to heal spontaneously, not leaving any scars (Figs. 24 to 29).[50,51]



Fig. 24: Diabetic blister on normal skin of lower extremity with serous content.

JAYPEE BROTHERS



Fig. 25: Diabetic blister with serous content settled on erythematous skin.



Fig. 26: Diabetic blister.



Fig. 27: Diabetic eroded blister with serohematic content.

JAYPEE BROTHERS



Fig. 28: Intact diabetic blister.

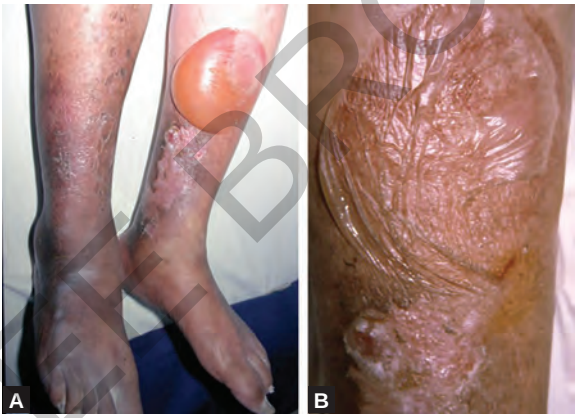

Figs. 29A and B: Large diabetic blister on lower extremity. (A) Intact blister. Note the vascular compromise on both extremities; (B) Aspiration of the content leaving the blister roof to avoid secondary infection.

Their short duration, plus their fast healing without treatment, would suggest a minor clinical situation; nevertheless, it is related to long-lasting diabetes and microvascular complications, specially peripheral neuropathy of lower extremities, so its presence is considered an indicator of poor prognosis.[52]

Histologically, most of them are intraepidermal blisters without acantholysis which explains why they heal without leaving scars (Fig. 30). In other less frequent cases, the blister appears below the dermoepidermal junction in the area of the lamina lucida. Direct or indirect immunofluorescence (IF) are negative.[53]

JAYPEE BROTHERS

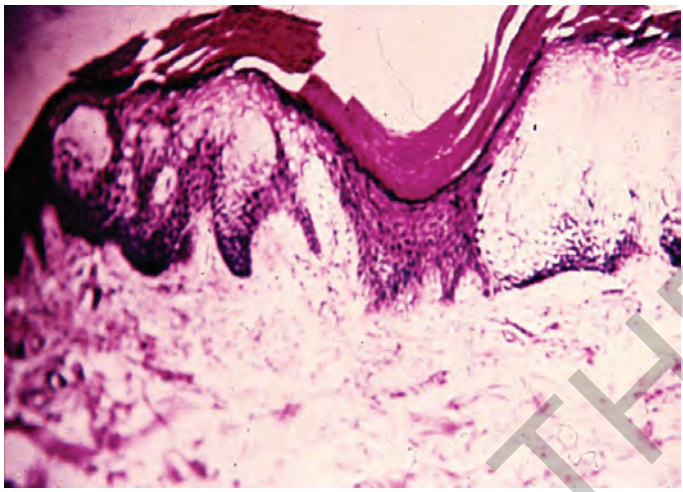

Fig. 30: Histological image of an intraepidermal diabetic blister.

Among the most feared complications are ulceration and bacterial superinfection, especially if the blisters are located on the feet—which can produce osteomyelitis, areas of necrosis and finally amputation. In case of doubt, a magnetic resonance imaging can rule out osteomyelitis.[54]

The diagnosis is suspected on a clinical basis, based on the evolution and sometimes even on histopathology to discard other bullous diseases. We should suspect of DB with the appearence of bullous lesions with direct negative IF and absence of porphyrins in urine.[55]

Taking into account that in most of the cases healing is spontaneous, the treatment should be conservative. It is important to keep the upper part of the blister intact and aspirate the fluid with a syringe to avoid superinfection. The preventive application of a topical antibiotic should not be ruled out. On the contrary, in case of ulcerated lesions, the treatment should be aggressive and supported by a multidisciplinary team (Table 1).[56]

XANTHOSIS OR YELLOW SKIN

It is characterized by yellowish skin, generally on the palms of hands, soles, nasolabial folds and armpits. The sclera allows for a differential diagnosis with jaundice. Its incidence in DM is around 10% of the cases, more frequent in adults and affecting both genders equally (Figs. 31 and 32).

It can also be observed in patients that ingest an excessive amount of vegetables rich in carotenoids, like diabetic patients.[57]

Carotenoids are deposited in the intercellular lipids of corneal cells, so the yellowish-orange color is more prominent in those areas where this layer of the epidermis is thicker.[58]

JAYPEE BROTHERS



Fig. 31: Yellowish-orange coloration of the palms.



Fig. 32: Comparison of the yellowish-orange coloration of the palm of a patient (left) versus the control palm (right).

Hypercarotenemia and, in consequence, the yellowish color of the skin can be the result of the following three mechanisms:

- An increase in the intake of foods rich in carotenoids
- An increase in serum lipids
- Slowing down of the carotenoid metabolism into retinol.

In the case of diabetic patients, the yellowish color of their skin appears in spite of having normal carotenoid levels in blood and all three mechanisms previously mentioned participate; a bad conversion of beta-carotene into retinol and an increase of blood lipids, apart from a diet rich in vegetables.

JAYPEE BROTHERS

That is why today it is believed that the yellow coloration of the skin of these patients, like many other cutaneous manifestations, is largely driven by the NEG process, in which delayed-release yellow-colored products are formed (AGE) (2-furoyl)-4(5)-(2-furanyl)-1H0 imidazole (6H), which accumulated in proteins like collagen, produce that characteristic color on the skin and the nails (*see* Table 1).[59]

Moreover, some authors confirm that diabetic patients with elevated glycemia and HbA1c levels and without a food intake rich in carotenoids ameliorate their dermatosis with a strict control of DM. This would support the theory of NEG participation in the yellow color, since it increases glucose in blood.[60]

REFERENCES

1. Sheetz MJ, King GL. Molecular understanding of hyperglycemia's adverse effects for diabetic complications. JAMA. 2002; 288(20):2579-88.
2. Farshchian M, Farshchian M, Fereydoonnejad M, et al. Cutaneous manifestations of diabetes mellitus: a case series. Cutis. 2010;86(1):315.
3. Shahzad M, Al Robaee A, Al Shobaili HA, et al. Skin manifestations in diabetic patients attending a diabetic clinic in the Qassim region, Saudi Arabia. Med Princ Pract. 2011;20(2):137-41.
4. Van Hattem S, Bootsma AH, Thio HB. Skin manifestations of diabetes. Cleveland Clinic Journal of Medicine.2008;75(1):772-87.
5. Dissemond J. Images in clinical medicine. Necrobiosis lipoidica diabeticorum. N Engl J Med. 2012;366(26):2502.
6. Kota SK, Jammula S, Kota SK et al. Necrobiosis lipoidica diabeticorum: a case-based review of literature. Indian J Endocrinol Metab. 2012;16(4):614-20.
7. Holland C, Givens V, Smoller BR. Expression of the human erythrocyte glucose transporter Glut-1 in areas of sclerotic collagen in necrobiosis lipoidica. J Cutan Pathol 2001;28:287-90.
8. Erfurt-Berge C, Seitz AT, Rehse C, et al. Update on clinical and laboratory features in necrobiosis lipoidica: a retrospective multicenter study of 52 patients. Eur J Dermatol. 2012;22(6):770-5.
9. Penny HL, Faretta M, Rifkah M, et al. Selective case study describing the use of Apligraf on necrobiosis lipoidica associated with diabetes. J Wound Care. 2014;23(2): S12-5.
10. Ianoşi SL, Tutunaru C, Georgescu CV, et al. Specific features of a rare form of disseminated necrobiosis lipoidica granuloma annulare type: a case report. Rom J Morphol Embryol. 2014; 55(4):1455-61.
11. Franklin C, Stoffels-Weindorf M, Hillen U, et al. Ulcerated necrobiosis lipoidica as a rare cause for chronic leg ulcers: case report series of ten patients. Int Wound J. 2013. doi: 10.1111/iwj.12159.
12. Alonso ML, Riós JC, González-Beato MJ, et al. Necrobiosis lipoidica of the glans penis. Acta Derm Venereol. 2011;91(1):105-6.
13. Hawryluk EB, Izikson L, English JC 3rd. Non-infectious granulomatous diseases of the skin and their associated systemic diseases: an evidence-based update to important clinical questions. Am J Clin Dermatol. 2010;11:171-81.
14. Bakos RM, Cartell A, Bakos L. Dermatoscopy of early-onset necrobiosis lipoidica. J Am Acad Dermatol. 2012;66:e143-4.

JAYPEE BROTHERS

15. Conde-Montero E, Aviles-Izquierdo JA, Mendoza-Cembranos MD, et al. Dermoscopy of necrobiosis lipoidica. Actas Dermosifiliogr. 2013;104: 534-7.
16. Pătrașcu V, Giurca C, Ciurea RC, et al. Ulcerated necrobiosis lipoidica to a teenager with diabetes mellitus and obesity. Rom J Morphol Embryol. 2014;55(1): 171-6.
17. Grillo E, Rodriguez-Muñoz D, González-Garcia A, et al. Necrobiosis lipoidica. Aust Fam Physician. 2014;43(3):129-30.
18. Binamer Y, Sowerby L, El-Helou T. Treatment of ulcerative necrobiosis lipoidica with topical calcineurin inhibitor: case report and literature review. J Cutan Med Surg. 2012;16:458-61.
19. De Rie MA, Sommer A, Hoekzema R, et al. Treatment of necrobiosis lipoidica with topical psoralen plus ultraviolet A. Br J Dermatol. 2002;147:743-7.
20. Beattie PE, Dawe RS, Ibbotson SH, et al. UVA1 phototherapy for treatment of necrobiosis lipoidica. Clin Exp Dermatol. 2006;31:235-8.
21. Basaria S, Braga-Basaria M. Necrobiosis lipoidica diabeticorum: response to pentoxiphylline. J Endocrinol Invest. 2003;26:1037-40.
22. Kavala M, Sudogan S, Zindanci I, et al. Significant improvement in ulcerative necrobiosis lipoidica with hydroxychloroquine. Int J Dermatol. 2010;49: 467-9.
23. Nguyen K, Washenik K, Shupack J. Necrobiosis lipoidica diabeticorum treated with chloroquine. J Am Acad Dermatol. 2002;46:S34-6.
24. Eberle FC, Ghoreschi K, Hertl M. Fumaric acid esters in severe ulcerative necrobiosis lipoidica: a case report and evaluation of current therapies. Acta DermVenereol. 2010;90:104-6.
25. Kreuter A, Knierim C, Stucker M, et al. Fumaric acid esters in necrobiosis lipoidica: results of a prospective non controlled study. Br J Dermatol. 2005;153: 802-7.
26. Stanway A, Rademaker M, Newman P. Healing of severe ulcerative necrobiosis lipoidica with cyclosporin. Australas J Dermatol. 2004;45:119-22.
27. Reid SD, Ladizinski B, Kachiu L, et al. Update on necrobiosis lipoidica: A review of etiology, diagnosis, and treatment options JAAD. 2013;69(5):783-91.
28. Goucha S, Khaled A, Kharfi M, et al. Granuloma annulare. G Ital Dermatol Venereol. 2008;143(6):359-63.
29. Wollina U, Langner D. Treatment of disseminated granuloma annulare recalcitrant to topical therapy: a retrospective 10-year analysis with comparison of photochemotherapy alone versus photochemotherapy plus oral fumaric acid esters. JEADV. 2012;26(10):1319-21.
30. Souza FH, Ribeiro CF, Pereira MA, et al. Simultaneous occurrence of ulcerated necrobiosis lipoidica and granuloma annulare in a patient: case report. An Bras Dermatol 2011;86(5):1007-10.
31. Avitan-Hersh E, Sprecher H, Ramon M, et al. Does infection play a role in the pathogenesis of granuloma annulare? JAAD 2013; 68(2):342-3.
32. Jang EJ, Lee JY, Kim MK, et at. Erythematous granuloma annulare. Ann Dermatol. 2011;23(3):409-11.
33. Maschio M, Marigliano M, Sabbion A, et al. A rare case of granuloma annulare in a 5-year-old child with type 1 diabetes and autoimmune thyroiditis. Am J Dermatopathol. 2013;35(3):385-7.

JAYPEE BROTHERS

34. Travassos AR, Soares-De-Almeida L. Residents'corner February 2014. DeRmpath& Clinic: Differential diagnosis in palisading non-infectious granulomas. Diagnosis: Case 1: Granuloma annulare. Case 2: Necrobiosis lipoidica. Eur J Dermatol. 2014;24(1):139-40.
35. Rupley KA, Ryan R, Riahi RR, et al. Granuloma annulare and necrobiosis lipoidica with sequential occurrence in a patient: report and review of literature. Dermatol Pract Concept. 2015;5(1):29-34.
36. Davison JE, Davies A, Moss C, et al. Links between granuloma annulare, necrobiosis lipoidica diabeticorum and childhood diabetes: a matter of time? Pediatr Dermatol. 2010;27(2):178-81.
37. Keimig EL. Granuloma Annulare. Dermatol Clin. 2015;33(3):315-29.
38. Martín-Sáenz E, Fernández-Guarino M, Carrillo-Gijón R, et al. Efficacy of dapsone in disseminated granuloma annulare: a case report and review of the literature. Actas Dermosifilogr. 2008;99(1):64-8.
39. Piaserico S, Zattra E, Linder D, et al. Generalized granuloma annulare treated with methylaminolevulinate photodynamic therapy. Dermatology. 2009;218(3):282-4.
40. Pătraşcu V1, Giurcă C, Ciurea RN, et al. Disseminated granuloma annulare: study on eight cases. Rom J Morphol Embryol. 2013;54(2):327-31.
41. Binkley GW. Dermopathy in diabetes mellitus. Arch Dermatol. 1965;92:106-7.
42. Murphy-Chutorian B, Han G, Cohen SR. Dermatologic Manifestations of Diabetes mellitus: a review. Endocrinol Metab Clin North Am. 2013;42(4):869-98.
43. Duhm G. Atrofia parda circunscrita pretibial y diabetes. Trabajo original 1 y 2 años de la docencia complementaria. UBA, Facultad de Medicina. 1970.
44. McCash S, Emanuel PO. Defining diabetic dermopathy. J Dermatol. 2011;38(10): 988-92.
45. Abdollahi A, Daneshpazhooh M, Amirchaghmaghi E, et al. Dermopathy and retinopathy in diabetes: is there an association?. Dermatology. 2007;214(2): 133-6.
46. Shenavandeh S, Anushiravani A, Nazarinia MA. Diabetic muscle infarction and diabetic dermopathy two manifestations of uncontrolled prolong diabetes mellitus presenting with severe leg pain and leg skin lesions. J Diabetes Metab Disord. 2014;13(1):38.
47. Morgan AJ, Schwartz RA. Diabetic dermopathy: A subtle sign with grave implications. J Am Acad Dermatol. 2008;58(3):447-51.
48. Demirseren DD, Emre S, Akoglu G, et al. Relationship between skin diseases and extracutaneous complications of diabetes mellitus: clinical analysis of 750 patients. Am J Clin Dermatol. 2014;15(1):65-70.
49. Lipsky BA, Baker PD, Ahroni JH. Diabetic bullae: 12 cases of a purportedly rare cutaneous disorder. Int J Dermatol. 2000;39(3):196-200.
50. El Fekih N, Zéglaoui F, Sioud A, et al. Bullosis diabeticorum: report of ten cases. Tunis Med. 2009;87(11):747-9.
51. Chatterjee N, Chattopadhyay C, Sengupta N, et al. An observational study of cutaneous manifestations in diabetes mellitus in a tertiary care Hospital of Eastern India. Indian J Endocrinol Metab. 2014;18(2):217-20.
52. H Riad, H Al Ansari, K Mansour, et al., "Pruritic vesicular eruption on the lower legs in a diabetic female," Case Reports in Dermatological Medicine, vol. 2013, Article ID 641416, 4 pages, 2013.

JAYPEE BROTHERS

53. Murphy-Chutorian B, Han G, Cohen R. Dermatologic manifestations of diabetes mellitus: a review. Endocrinol Metab Clin N Am. 2013;42:869-98.
54. Kurdi AT. "Bullosis diabeticorum," Lancet. 2013;382(9907):e31.
55. Mota ANCM, Nery NS, Barcaui CB. Case for diagnosis. An Bras Dermatol. 2013;88(4):652-4.
56. Gupta V, Gulati N, Bhal J, et al. Bullosis Diabeticorum: rare presentation in a common disease. Case Rep Endocrinol. 2014;2014. Article ID 862912, 3 pages.
57. Hoerer E, Dreyfuss F, Herzberg M. Carotenemia, skin color and diabetes mellitus. Acta Diabetol Lat. 1975;12:202-7.
58. Haught JM, Patel S, English JC, III. Xanthoderma: a clinical review. J Am Acad Dermatol. 2007;57:1051-8.
59. Julka S, Jamdagni N, Verma S, et al. Yellow palms and soles: a rare skin manifestation in diabetes mellitus. Indian J Endocrinol Metab. 2013;17(Suppl1): S299-S300.
60. Jiun-Nong Lin. Yellow palms and soles in diabetes mellitus. N Engl J Med. 2006; 355:1486.

JAYPEE BROTHERS

for detailed information on endocrinology books, visit our website **www.jaypeebrothers.com,** for detailed information on endocrinology

Cutaneous Manifestations *of* DIABETES

Salient Features

- An easy-to-read book with essential concepts about diabetes and its manifestations on the skin
- Very useful in daily practice for those who treat the diabetic patients, whatever their specialty
- Brings together a wide spectrum of information on diabetes mellitus in one single book
- Includes chapters written by dermatologists and diabetologists of high academic level
- Each chapter contains the latest knowledge on each topic, with tables, graphs, etc.
- More than 180 clinical images have been incorporated.



Emilia Noemí Cohen Sabban MD is currently Deputy-Chief of the Dermatology Division at 'A Lanari' Medical Research Institute, University of Buenos Aires (UBA), and Associate Professor of Dermatology at the University of Buenos Aires (UBA), Buenos Aires, Argentina and member of the Board of the Ibero-Latin American College of Dermatology, Buenos Aires, Argentina.

She is also the author of the book 'Diabetes y Piel', Ed Journal 2013. Dr Cohen Sabban is the co-author in 19 national books and 12 abroad, with more than 90 scientific papers in Argentina and abroad.

She is the speaker on 'Cutaneous Manifestations of Diabetes Mellitus' at the American Academy of Dermatology, 2015 and 2016.

Dr Cohen Sabban is the speaker in more than 130 national and international dermatological congresses and meetings.

Available at all medical bookstores or buy online at www.jaypeebrothers.com

JAYPEE BROTHERS
Medical Publishers (P) Ltd.
www.jaypeebrothers.com

Join us on facebook.com/JaypeeMedicalPublishers

Shelving Recommendations
ENDOCRINOLOGY
DERMATOLOGY

ISBN 978-93-5270-039-4