Angio OCT

in Everyday Ophthalmic Practice

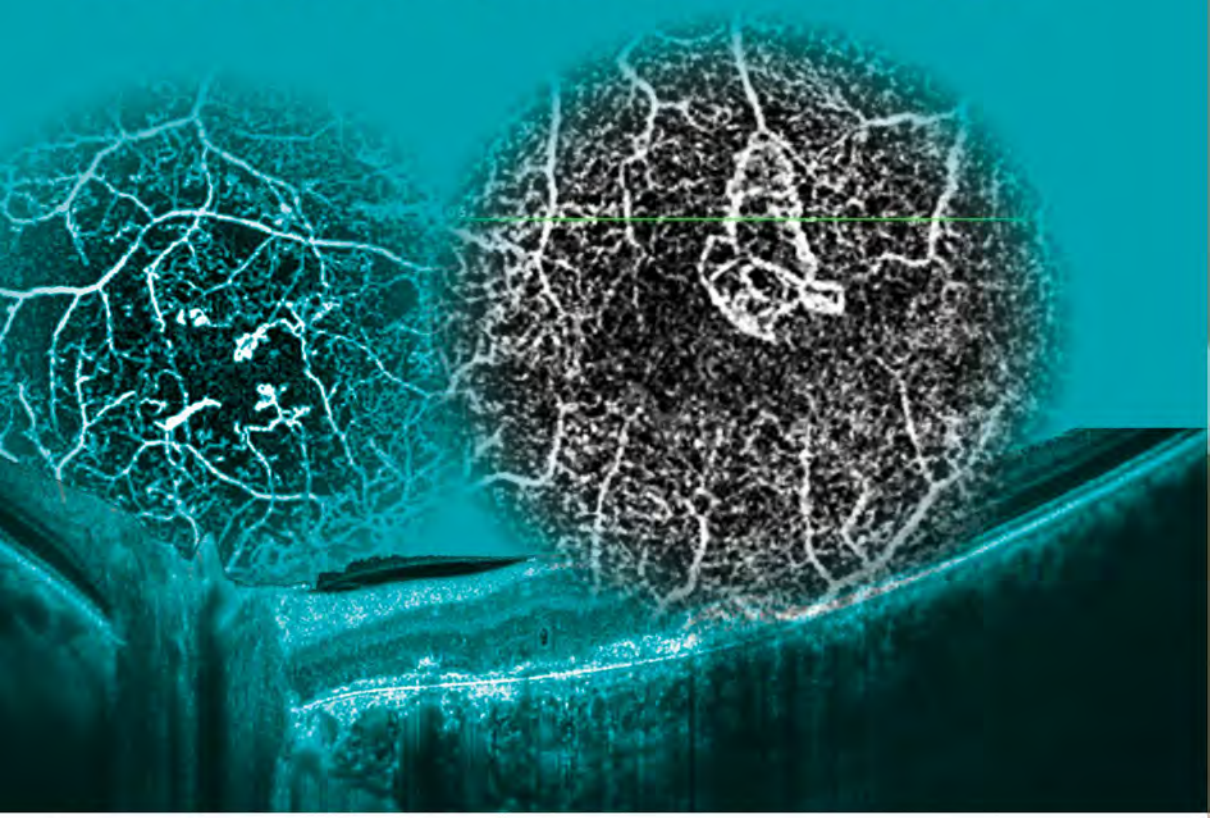

Bruno Lumbroso
David Huang
Marco Rispoli

NOVARTIS

CONTENTS

PART 1

1. Principles and Technology 1
David Huang, Yali Jia

- Optical Coherence Tomographic Angiography Methods 1
- Split-Spectrum Amplitude-Decorrelation Angiography 1
- Optovue Angiovue Technology 1
- Clinical Applications of OCTA Technology 2

2. Terminology 3
David Huang, Yali Jia

- Structural Optical Coherence Tomography 3
- Quantification of Neovascularization 6

3. Practical Problems of OCT Angiography: Tips and Tricks 8
Marco Rispoli

- Practical Tips for Everyday OCTA Examination 8
- Mistakes to be Avoided 9
- How to Fix Some Practical Problems: Concepts and Rules 12

4. Artifacts in OCT Angiography 18
Marco Rispoli

- Movement Artifacts 18
- Flow Projection Artifacts 21
- Segmentation Errors 21
- False-positive Flow 24
- False-negative Flow 24
- Low-intensity Imaging 26
- Nonvascular Flow Signal 26

5. OCT Angiography of Normal Retinal Vascular Structure 29
Maria Cristina Savastano, Bruno Lumbroso

- Retinal Vascular Networks 31

6. OCT Angiography Quantitative Assessment 36
Marco Rispoli

- Flow Area 37
- Nonflow Area, Vascular Dropout Area 37

- Flow-density Map 38
- Flow Speed 41
- Other Optical Coherence Tomography Angiography Quantitative Parameters 41

7. Choroidal Neovascularization in Age-related Macular Degeneration (Exudative and Nonexudative Choroidal Neovascularization) **42**
Bruno Lumbroso, Marco Rispoli

- Optical Coherence Tomography Angiography in Everyday Clinical Use for Choroidal Neovascularization 42
- Classification 42
- Choroidal Neovascularization Evaluation 45
- Exudative Choroidal Neovascularization: Type 1, Type 2, Type 3 and Type 4 (Mixed) Choroidal Neovascularization 45
- Exudative Choroidal Neovascularization Evolution 61
- Nonexudative Choroidal Neovascularization 65
- Choroidal Neovascularization Management 72

8. Exudative Choroidal Neovascularization Monitoring after Treatment **75**
Bruno Lumbroso, Marco Rispoli

- Immediate Evolution after Treatment 75
- Maturation 81
- Recurrences 83
- Vascularized Fibrous Scar 85
- Management of Choroidal Neovascularization 90

9. Optical Coherence Tomography Angiography in Dry Age-related Macular Degeneration **92**
Maria Vittoria Cicinelli, Eric Souied, Francesco Bandello, Giuseppe Querques

- Drusen 93
- Reticular Pseudodrusen 95
- Geographic Atrophy 95
- Prognostic Implications 97

10. Choroidal Neovascularization Activity Features **101**
Bruno Lumbroso, Marco Rispoli

- Exudative Choroidal Neovascularization: Active or Quiescent? 101
- Nonexudative Choroidal Neovascularization: Active or Quiescent? 110

CHAPTER

4

Artifacts in OCT Angiography

JAYPEE BROTHERS

INTRODUCTION

To operate optical coherence tomography (OCT) angiography devices and to give a correct imaging interpretation, it is mandatory to have a good knowledge of all possible artifacts, as they induce false information leading to incorrect diagnosis. Any imaging of ocular tissue (fluorescein angiography and structural OCT) may be affected by artifacts. However, due to its technological complexity, OCT angiography may give more distortion and warping; it has an increased possibility of artifacts and inability to detect blood flow, if and when pulsating or when too fast or too slow.

Progresses in software technology are fixing fast a large part of these artifacts.

Artifacts can be related to image acquisition and processing, ocular movements, eye anatomic features, operator errors, and display strategies. Each of these main classes of artifacts produces typical and recognizable image abnormalities.

Richard Spaide, James Fujimoto and Nadia Waheed[1] (2015) have classified and defined the artifacts and we hereby follow their indications in this chapter (Boxes 1 and 2).

Optical coherence tomography angiography (OCTA) operators, imaging experts, as well as the one who writes the imaging report must be acquainted to a great number of artifacts that are possible to observe in any clinical case. We list the main artifacts that are frequently seen and the less common ones, beginning with the most habitually present and then describing the less frequently observed.

MOVEMENT ARTIFACTS

As a matter of fact, OCTA devices now added eye tracking systems to avoid this kind of artifacts. At the moment, a significant part of those artifacts have been fixed by applying new strategies and algorithms, and are seen less frequently than at the first times of OCTA. Motion artifacts are now less common and usual. They happen when the

BOX 1: Optical coherence tomography angiography artifacts 1

Can be related to
- Image acquisition and processing
- Ocular movements
- Eye anatomic features
- Operator errors
- Display strategies

BOX 2: Optical coherence tomography angiography artifacts 2

- Flow projection artifacts
- Segmentation errors
- False-positive flow
- False-negative flow
- Low intensity
- Nonvascular flow signal
- Movement artifacts

operator does not use control software to reduce the effects of eye motion. We can divide motion artifacts in several classes described below: Richard Spaide, James Fujimoto, Nadia Waheed[1] (2015) thus classify movement artifacts.

White Line Artifacts

With eye movement during an image frame, one region is imaged and is then juxtaposed with a noncontiguous region because of the movement. At the interface is a region with high decorrelation, which is rendered white. As a consequence, this type of movement artifact is called a *white line artifact* (Figs 1A and B).

Quilting Defect

The checkerboard defect or quilting defect occurs when the two horizontal and vertical raster sequences are quite different from one another due to eye movements and of saccades during the acquisition of each but the motion control software forces them to show alignment.

Stretch Artifact

This is due to two images that are not exactly of the same region being combined and results in an area, typically at the edge of the image to be stretched or smeared in appearance. Stretch artifact can result from eye movement as well (Fig. 1C).

JAYPEE BROTHERS

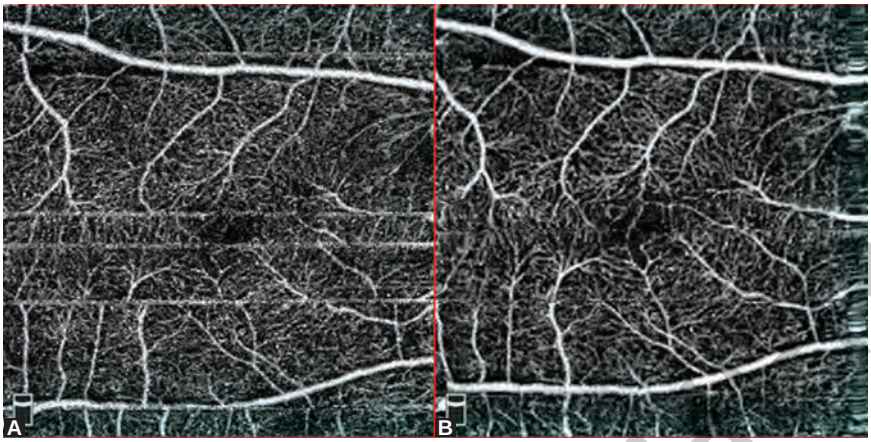

Figs 1A and B: Movement artifacts. (A) White line artifacts. With eye movement during an image frame, one region is imaged and is then juxtaposed with a non-contiguous region because of the movement; (B) Artifact corrected by software (Optovue, AngioVue)

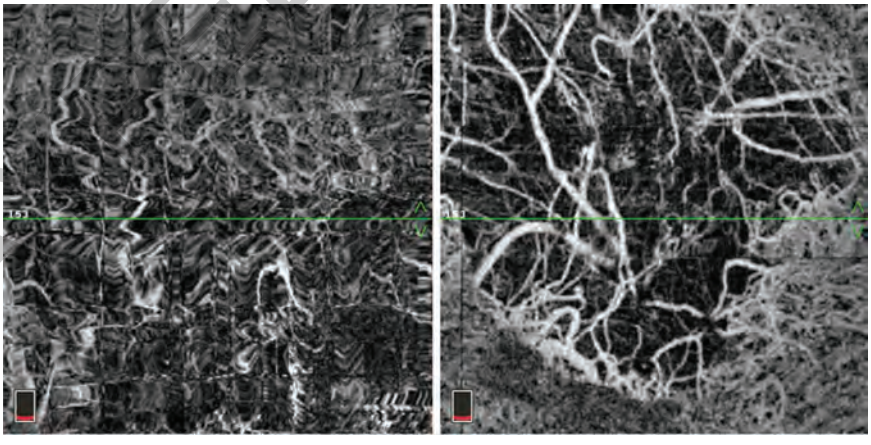

Fig. 1C: Stretch artifact: Two images that are not exactly of the same region are being combined and result in an area, typically at the edge of the image that is stretched or smeared in appearance. Right hand side: artifact corrected by software (Optovue, AngioVue)

JAYPEE BROTHERS

Vessel Doubling

This is a problem linked to the motion correction technology (MCT) alignment system that causes some vessels to be seen doubled, side by side (Fig. 1D).

Gap Defect

While the motion control software can reposition segments of the image to align more accurately with some eye movements, there is going to be missing information. The missing information can appear as a gap in a blood vessel (Fig. 1E).

FLOW PROJECTION ARTIFACTS

Flow projection artifacts are the most frequently observed artifacts. They are seen on all imaging and with all OCTA devices. They are due to fluctuating shadows cast by flowing blood in superficial vasculature that cause reflectance variations in deeper layers, where they are detected as a flow signal by the OCTA algorithm. Inner retinal vessels filter the light passing through them and with motion contrast, processing may cause the appearance of the same vessels at the level of the plexiform layers and retinal pigment epithelium (RPE).

The flow projection artifact is most noticeable in deep reflective structures, such as the RPE and can be recognized by the replication of a superficial vascular pattern on the en face angiogram of a deeper layer.

On cross section, OCTA artifact manifests as *tails* below blood vessel and the replication of superficial vascular pattern on *en face* OCTA of deeper slabs.

Flow Projection Artifact Removal

Several algorithms have been applied to fix this issue. The most common strategy is to cancel or attenuate all flow signals that appear below the main flow signal along the same Z axis. Projection-resolved optical coherence tomography angiography (PR-OCTA) uses a post-processing algorithm to resolve the ambiguity between flow signal due to *in situ* flow (real vessels) and projected flow, thereby removing tails and providing clean visualization of vessels in deeper slabs (Fig. 2).

SEGMENTATION ERRORS

Accurate segmentation is easy in normal or slightly deformed retina and choroid, segmentation highlights show minor errors in one or more layers.

JAYPEE BROTHERS

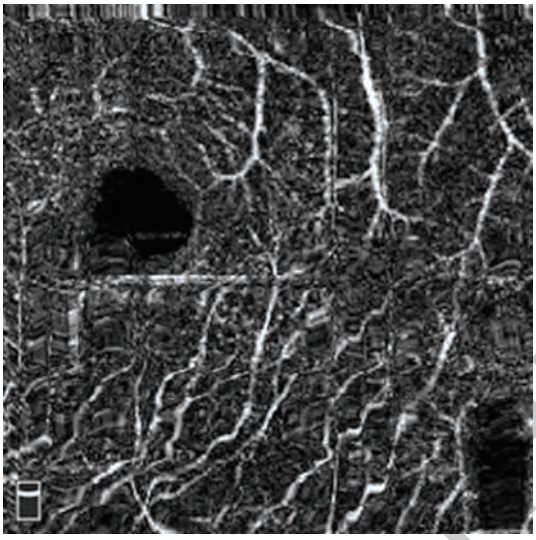

Fig. 1D: Vessel doubling: This problem is linked to the motion correction technology alignment system that cause some vessels to be seen doubled (Optovue, AngioVue)

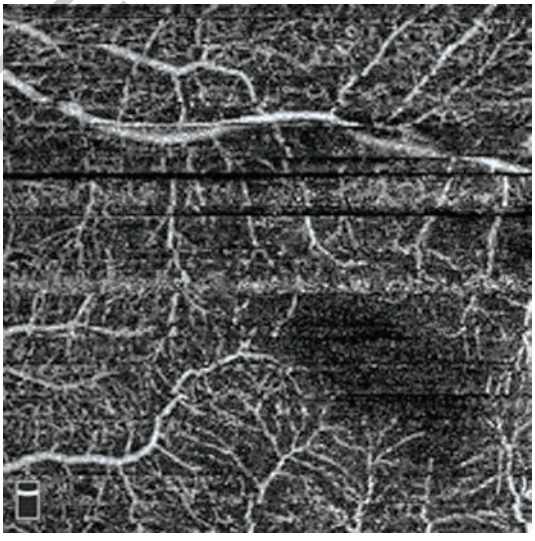

Fig. 1E: Gap defect: While the motion control software can reposition segments of the image to align more accurately with some eye movements, there is going to be missing information that leaves a gap in the resulting image (Optovue, AngioVue)

JAYPEE BROTHERS

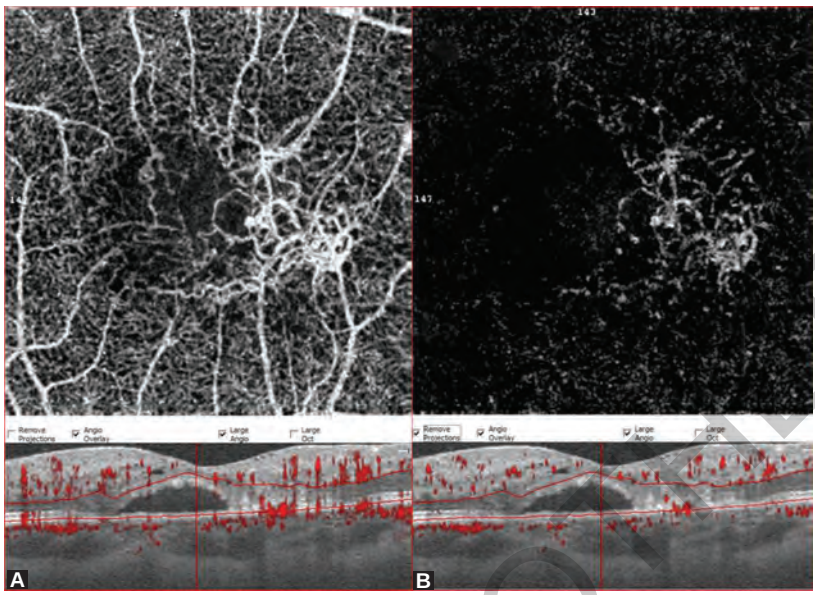

Fig. 2: Projection artifact. (A) Left hand side: Projection artifacts are seen in the en face angiography image and on the B-scan. They are due to fluctuating shadows cast by flowing blood in superficial vasculature that cause reflectance variations in deeper layers, where they are detected as a flow signal by the optical coherence tomography angiography algorithm. On B-scan, note the tails projecting from vessels; (B) Right hand side: Projection artifact has been removed by the software (Optovue, AngioVue)

If, as in geographic atrophy or high myopia, retina and choroid are much thinner than normal, we are not sure that the automatically selected slab is located at the correct position. Some retinal diseases cause the retina to become much thinner, and selection of standard thickness layers results in too much tissue being selected. High myopia induces distortions of the ocular tissue and it is very common for segmentation algorithms to make many errors. The automated selection of a vascular layer as shown by OCT angiography software in these cases is not reliable.

When tissues are deformed, swollen, irregularly distorted and depart from normality, the risk of error in segmentation is important. In venous occlusions or in diabetic macular edema layers are very irregular and thickened, The software is unable to identify the layers as it is trying to follow layers with the normal thickness as found in normal eyes. The software cannot assess accurately the blood flow (Fig. 3).

JAYPEE BROTHERS



Fig. 3: Segmentation errors: With diseased tissue or alterations from normal, the algorithms used often fail. In normal eyes, the segmentation algorithms may show minor errors in one or more layers. Any deviation from normality increases the risk of segmentation error. Here, a superficial vessel is placed erroneously in the deep layers by the software (Optovue, AngioVue)

FALSE-POSITIVE FLOW

Segmentation errors can also induce false-positive flow (no-flow areas). These are false flows produced by the noise of eye movement. There are many sources of this error, and this error is not always corrected in current software. These artifacts may fool vessel density and flow measurements to give artificially large measurements of each. Possible sources of false-positive flow include hard exudates, pigment accumulation, thrombosed microaneurysms or retinal hemorrhages, and the borders of cystoid spaces. These artifacts need to be taken into account in order not to confuse nonvascular reflectivity with flow signals. Some false-positive flows are recorded when there is a crossing between two segmentation lines, usually when segmenting with internal limiting membrane profile in atrophic retina. In this case, the foveal shape may pass through the lower line picking some choroidal flows (Fig. 4).

FALSE-NEGATIVE FLOW

Absence of flow signal does not always mean there is a lack of vessels or that they are closed or thrombosed. It is necessary to confront with *en face* OCT where nonflowing vessels can clearly be seen.

JAYPEE BROTHERS

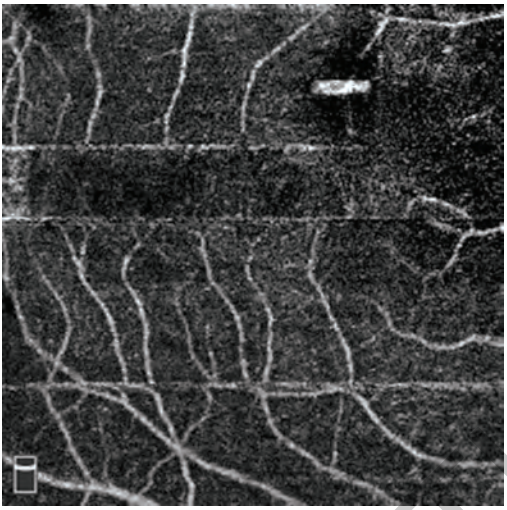

Fig. 4: False-positive flow (no-flow areas): These are flows produced by the noise of eye movement. In this case, a hard exudate has been detected as flow signal (Optovue, AngioVue)

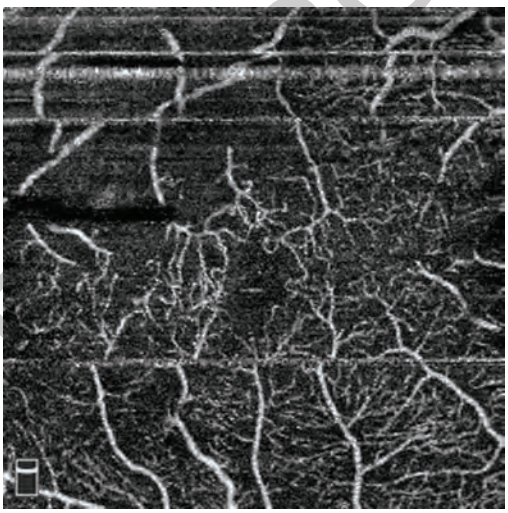

Fig. 5: False-negative flow: observed when flow is too slow or pulsating flow is too slow and is below the detection threshold of the system. In this image, we can also see white line artifacts (Optovue, AngioVue)

We do not see an existing flow when:

- Flow is too slow and is below the detection threshold of the system.
- Flow is pulsating or irregularly segmented and interrupted.
- Low intensity signal due to opacities in the lens or vitreous
- The signal may be decreased in the structures having a high scatter, like the retinal pigmented epithelium (Fig. 5).

JAYPEE BROTHERS

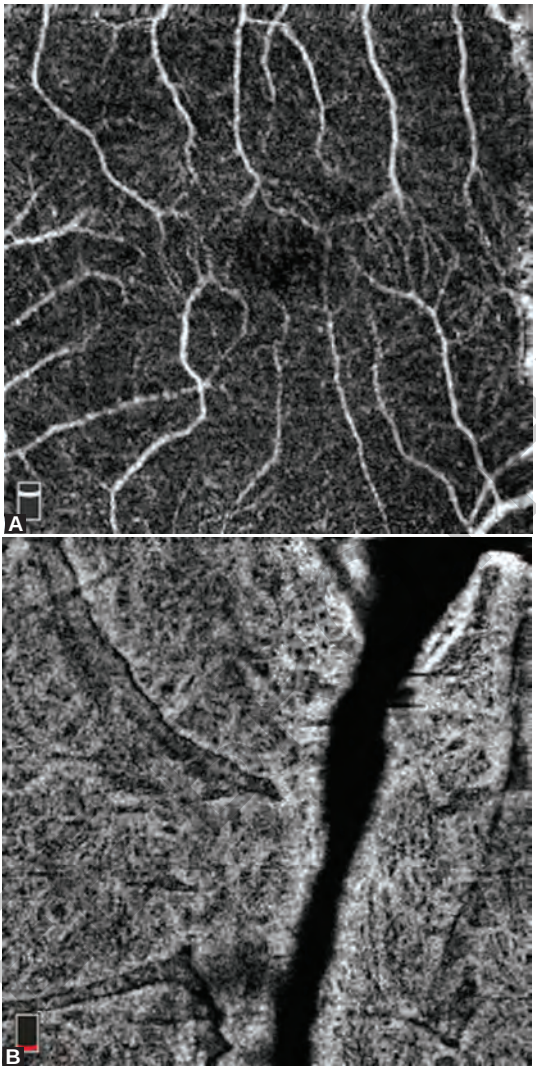

Figs 6A and B: Low signal: (A) Low intensity image due to lens opacities; (B) Dark image due to dense vitreous opacity

LOW-INTENSITY IMAGING

It is also the most frequent artifact. It is due to decrease of light penetration in deeper layers, in reason of tear film, vitreous hemorrhages or opacities, and lens opacities (Fig. 6).

NONVASCULAR FLOW SIGNAL

In OCTA, background bulk tissue motion can generally be subtracted because it is associated with a uniform decorrelation or variance

JAYPEE BROTHERS

BOX 3: False-positive flow artifacts (no-flow areas)

- Noise of eye movement
- Hard exudates
- Pigment accumulation
- Thrombosed microaneurysms
- Retinal hemorrhages
- Margins of cystoid spaces
- Crossing between two segmentation lines, picking some choroidal flows

BOX 4: False-negative flow artifacts

- Flow is too slow and is below the detection threshold of the system
- Flow is pulsating or irregularly segmented and interrupted
- Low intensity signal due to opacities in the lens or vitreous
- The signal may be decreased in the structures having a high scatter like the retinal pigmented epithelium

BOX 5: Nonvascular flow signal artifacts

Produced by:

- Retinal pigment epithelium
- Hard exudates
- Pigment accumulation
- Thrombosed aneurysms
- Retinal hemorrhages

BOX 6: Low-intensity artifacts

Decrease of light penetration in deeper layers in

- Tear film
- Corneal haze
- Vitreous hemorrhages or opacities
- Lens opacities

BOX 7: Movement artifacts[1]

- White line artifacts
- Quilting defect
- Stretch artifact
- Vessel doubling
- Gap defect

JAYPEE BROTHERS

value over most voxels with measurable OCT signal. However, the decorrelation signal in some very highly backscattering structures can still rise above the background in some instances. These include the RPE, hard exudates, regions of pigment accumulation, thrombosed aneurysms, and retinal hemorrhages. Possibly, the presence of a high concentration of backscattering particles can enhance decorrelation caused by tissue movement or scanner displacement between repeated scans (Boxes 3 to 7).

REFERENCE

1. Spaide RF, Fujimoto JG, Waheed NK. Image artefacts in optical coherence tomography angiography. Retina. 2015;35(11):2163-80.

JAYPEE BROTHERS

Angio OCT
in Everyday Ophthalmic Practice

Salient Features

- A brief and compact handbook
- Illustrates logical and simple method of analysis and interpretation of OCT angiography imaging
- States clearly the easy steps required to reach a diagnosis
- Deals the topics with the help of illustrations, drawings and structural and functional OCT figures
- Records most of the images with Optovue AngioVue OCT, an instrument both reliable and easy to use
- Intends to teach OCT angiography interpretation and supports ophthalmologists in their everyday routine works.

Bruno Lumbroso MD is Director, Centro Italiano Macula, Rome, Italy. He has been Director of the Department of Ophthalmology at Rome Eye Hospital and Professor LD of Clinical Ophthalmology in the University of Rome La Sapienza for more than 35 years. He has also been a pioneer in the development of clinical applications for *en face* OCT and OCT angiography. He is cofounder and General Secretary of the Societa Italiana di Angiografia OCT and of the Societa Italiana di Laser in Oftalmologia. He is involved in medical education in ocular imaging. His main interests are in logical methods of retinal imaging analysis and interpretation, and in clinical applications of OCT and OCT angiography technology for retinal disorders. He organized the first Congress on OCT angiography. He has written a number of handbooks on retinal imaging in fluorescein angiography, ICG, microperimetry, spectral domain OCT, *en face* OCT, and OCT angiography.

David Huang MD PhD is Professor of Ophthalmology and Biomedical Engineering, and Director, Center for Ophthalmic Optics and Lasers, Casey Eye Institute, Oregon Health and Science University, Portland, Oregon, USA. He is a coinventor of optical coherence tomography (OCT), the most common imaging procedure in ophthalmology, with an estimated 30 million patients imaged per year. His seminal article on OCT, published in *Science* in 1991, has been cited more than 10,000 times. He leads an active NIH-supported research program on the ophthalmic applications of OCT and OCT angiography. He holds patents in the areas of OCT, OCT angiography, laser therapeutic devices, and mobile diagnostic tests. He has received the Champalimaud Vision award, ARVO Friedenwald award, AAO Senior Achievement award, and NAE Russ award.

Marco Rispoli MD works in the Department of Ophthalmology, Rome Eye Hospital and Centro Italiano Macula, Rome, Italy. He is interested in developing ocular imaging. He has written handbooks on retinal imaging interpretation of time domain OCT and spectral domain OCT. He is cofounder of the Societa Italiana di Angiografia OCT.

Shelving Recommendation
OPHTHALMOLOGY

ISBN 978-93-5270-084-4

9 789352 700844

NOVARTIS