formation on PGMEE books, visit our website **www.jaypeebrothers.com,** for detailed information on PGMEE books, visit our website **www.jaypeebrothers.com**

JAYPEE

Bestselling book on the subject

Thoroughly revised & updated edition including Subjectwise Synopsis & Latest Exam Pattern Questions

New ACROSS

A Complete Review of Short Subjects

A Unique book for NEET, DNB, AIIMS, PGI, FMGE and State-level examinations

Skin
Ophthalmology

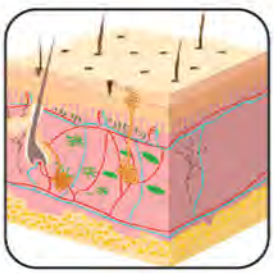



Volume 1

9th Edition

Saumya Shukla • Anurag Shukla

- **Thoroughly revised and updated edition with a new layout and two new sub specialities added (Radiotherapy & Nuclear Medicine).**
- **Concise, up-to-date and accurate.**
- **Written in simple language with precise explanation.**
- **Systematic presentation of the text.**
- **Book covers all questions from 2001 onwards**
- **All MCQs of All India (NBE Pattern), AIIMS, PGI, DNB, and State-based MCQs up to 2016 have been included**

A must-buy book for All India, AIIMS, PGI, JIPMER, DNB and State Entrance Exams

Contents

Dermatology (Skin & Venereal Diseases)

1.	General Anatomy & Appendageal Disorders	3
2.	Disorders of Pigmentation	11
3.	Allergic Disorders and Dermatitis (Eczema)	17
4.	Papulosquamous Disorders	24
5.	Papulovesicular / Vesicobullous Disorders & Immunologically Mediated Diseases	32
6.	Bacterial (Leprosy, TB) & Fungal Infections + Infestations (Scabies & Pediculosis)	44
7.	Venereal (Sexually Transmitted) Disease	59
8.	Genodermatoses & Deficiency Diseases	68
9.	Malignant Skin Disease	74
10.	Systemic Diseases With Prominent Cutaneous Features, Photosensitivity Disorders & Cutaneous Drug Erruptions	78
11.	Review Notes	87

Ophthalmology

1.	Anatomy & Development of The Eye	189
2.	Clinical Presentation & Methods in Ophthalmology	191
3.	Optics & Refraction	199
4.	Diseases of The Conjunctiva	209
5.	Diseases of The Cornea & Sclera	218
6.	Diseases of The Uveal Tract and Vitreous	234
7.	Diseases of The Retina	246
8.	Diseases of The Lens	267
9.	Glaucoma	281
10.	Diseases of The Optic Nerve	295
11.	Tumours of the Eye	300
12.	Ocular Injuries	313
13.	Neuro-Ophthalmogy	319
14.	Strabismus & Nystagmus	328
15.	Diseases of The Lid	336
16.	Diseases of The Lacrimal Apparatus	341
17.	Community Ophthalmology	344
18.	Review Notes	347

5

DISEASES OF THE CORNEA & SCLERA

Cornea: Anatomy & Physiology

- The junction of the cornea & sclera is called **limbus** and is marked by a shallow sulcus called **sulcus sclera**. Cornea is thickest at the limbus and thinnest at the center.

	Corneal diameter (mm)		Radium of curvature (mm)
	Horizontal	**Vertical**	
Anterior surface	11.7	**10.6**	**7.8**
Posterior surface	11.7	11.7	**6.5**
Corneal thickness	**Central** 0.5 – 0.6	**Peripheral** 1.2	

- Cornea has a curvature greater than the rest of the globe. ***Cornea is the most important refractive surface or eye. Its refractive index is 1.38 (1.376) and the anterior surface is the main refractive surface***Q. **It has 45D power and critical angle of cornea air interface is 46°.**
- The ***normal healthy cornea is avascular and devoid of lymphatic channels***Q***. It derives its nutrition by diffusion from aqueous, limbal capillaries and oxygen in the tear film***Q. **Oxygen is mostly derived from tear film** with a small contribution from limbal capillaries. **Glucose supply from cornea metabolism is mainly (90%) derived from aqueous** & supplemented (10%) by the limbal capillaries. The metabolism of cornea is *preferentially aerobic* & it can function only upto 6-7 hours anaerobically under normal conditions. The ***metabolically active cells are endothelium (most metabolically active), epithelium & stromal keratocytes***Q.
- Cornea is richly supplied by nerves (***without myelin sheaths & Schwann cell sheath***) which originate from ***small ophthalmic division of trigeminal nerve, mainly by long cilliary nerve.***Q There are no specialized nerve endings or sensory organelle. **Cornea is most densely inervated tissue in body.** D/t its dense nerve supply the cornea is extremely sensitive structure. With *corneal abrasion* or *bullous Keratopathy*, the direct stimulation of bare nerve ending causes ***pain, lacrimation & photophobia***Q.
- Corneal edema causes diffraction & symptoms of haloes around lights.

Cornea and Refraction of Light

- The shape of cornea is **prolate,** being flatter in periphery and steeper centrally, which creates an ***aspherical optical system***Q. The aspherical shape of cornea reduces spherical

Histology

- 3 layers of cornea are
  - **Stratified-nonkeratinized, nonsecretory squamous epithelium**
  - **Stroma/substatia propria (90% of thickness)**
  - **Endothelium (most metabolically active)**Q
- Between the epithelium and the stroma lies the **Bowman's membrane**. Between the stroma and the endothelium lies the **Descemet's membrane.**

Metabolic Role of Endothelium

- The main role of endothelium is to limit the fluid intake of the cornea from aqueous (i.e. *fluid regulation*) and maintain ***corneal deturgescence***Q**.** Increase in cell size (**polymegathism**) & variation in cell shape (**pleomorphism**) of endothelium reduce the ability to deturgesce cornea. The *hexagonal arrangement of cells decrease gaps and facilitate barrier function*. Endothelium provides a (Ca^{++} dependent) *leaky barrier* to aqueous humor by allowing molecules & electrolytes of small size (2-3nm) to penetrate through *focal tight junctions (maculae occludentes)*. Fluid moves from stroma (hyposmotic) to aqueous humor (hypertonic) requiring no energy. The generation of this osmotic gradient by membrane bound Na^+ - K^+ ATPase and intracellular carbonic anhydrase require energy. The delicate balance between fluid entering corneal stroma (barrier function) and fluid egressing the stroma (Na^+ K^+ ATPase pump function) maintain the corneal hydration at a fixed level of 78%. Any change would cause corneal oedema.
- ***Endothelial pumps maintain stroma in a relatively deturgesced state (~78% water), which allows an orderly lattice of collagen fibrils to enmesh in glycosaminoglycans & create a transparent tissue***Q. Endothelial pump is dependent on presence of Cl- & HCO_3^- and can be slowed down by *carbonic anhydrase inhibitor*. Corneal stroma contains *glycosaminoglycans (GAG)* which is the main cause of *corneal hydration and swelling pressure (50mmHg)*. GAG has anionic charges l/t separation of one molecule from other making it a sponge like structure that can swell & get hydrated. The GAG anionic repulsion expands the tissue and sucks in

JAYPEE BROTHERS

aberration minimizing refractive error fluctuations as the pupil size changes.

- **In the adult, the average** ***horizontal diameter is 11.5-12mm about 1 mm larger than vetical diameter***Q, and the anterior refractory power is ***43-43.50 diopters***Q (Yanoff). ***Anterior corneal curvature produces two-third of eyes refractive power (i.e. ~ + 48 D)***Q. However, the overall corneal power is less (~ **+ 43 D**) because of the negative power (- 5.80D) of posterior corneal surface.
- ***Cornea is the most important refractive surface of the eye and its anterior surface (i.e. air-cornea / air-tear interface) is the main refractory surface***Q.
- The **refractive index of cornea** is ***1.38 (1.376)***Q. The cornea has almost the same but slightly greater refractive index than aqueous & vitreous humor (1.336) and slightly lower than lens (1.386-1.406)
- **With the rule or according to the rule astigmatism** results when ***vertical meridian is more curved (i.e. ~ 0.05 D steeper) than the horizontal meridian***Q.

fluid with equal pressure called *imbibation pressure (-30 mmHg)*. Corneal oedema occurs if IOP exceeds SP as in glaucoma or if SP is low (with normal IOP) as in endothelial dystrophy.

Intraocular pressure (20) = Swelling pressure (50) + Imbibation pressure (-30)

- Descement's membrane, which is basement membrane of endothelial cell layer can be regenerated by endothelial cells to some extent when injured. However, endothelium layer does not regenerate and adjacent cells slide to fill in a damaged area. Adult cell density is *~2500 cells/mm² with annual decrease of 0.6% per year*. **At cell density of about 500 cells/mm² corneal oedema develops** and corneal transparency is reduced. Normal cornea has *~3-6 lac cells (area = 147 mm²)*

Peripheral Ulcerative Keratopathies (PUK)

PUK is characterized by peripheral corneal thinning, infiltrations and ulcerations. Examples include

- Phlyctenular keratoconjunctivitis **is** a delayed type hypersensitivity (type IV cell mediated immune response) **to endogenous microbial proteins.**
- Marginal keratitis (catarrhal ulcer) **is probably caused by** *hypersensitivity reaction against staphylococcal exotoxins* and cell *wall proteins*Q **with deposition of antigen-antibody complexes in peripheral cornea (antigen diffuse from tear film and antibody from blood vessels) with secondary lymphocytic infiltration. It can frequently be a/w staphylococcal blepharoconjunctivitis >>>> Moraxella & Haemophillus**
- Marginal Keratolysis is peripheral ulcerative keratitis **(PUK) associated with** ***connective tissue disease such as rheumatoid arthritis, SLE, polyarteritis nodosa, Wegener's granulomatosis*****, and relapsis polychondritis. It is** autoimmune disease **a/w systemic collagen vascular disorder.**
- **Mooren's ulcer** (chronic serpiginous or rodent ulcer) **is idiopathic, autoimmune disease which presents with** superficial peripheral ulcerative keratitis (ulcer), **circumferential & central** stromal thinning, undermining **& infiltration of leading edge epithelium,** vascularization **of ulcer bed upto its leading edge but not beyond and scarring.**
- Rosacea keratitis **is marginal corneal ulceration seen in 10% patients of rosacea. It is an idiopathic disorder.**
- Terrien marginal degeneration **is uncommon idiopathic thinning of peripheral lower cornea.**
- **Pellucid marginal degeneration**
- **Dellen**

Keratomycosis/ Fungal (Mycotic) Corneal Ulcer

Etiology

- **Filamentous septate hyphae** most notably, **Fusarium and Aspergillus (fumigatus)** are the most common causative organism in **tropics (or hot climate) and around the word**
- Unicellular budding **yeast** eg **Candida** is most common cause of fungal keratitis in **temprate (cold) regions.**

Clinical Features

- ***Symptoms are much milder than the clinical signs would suggest***Q
- There is **marked ciliary, & conjunctival congestion but symptoms of pain, watering and photophobia are disproportionately less (as compared to those with bacterial corneal ulcer)**Q
- *Presents with a gradual onset of pain, grittiness, photo phobia, blurred vision and watery or mucopurulent discharge.*
- The ulcer is ***dry-looking***Q, grayish white with **elevated rolled out margins** and ***feathery finger like extensions***Q into surrounding stroma under intact epithelium.
- A **sterile** ***immune ring (yellow line of Wesseley)***Q present where fungal antigen and host antibody meet.
- ***Multiple small satellite lesions*** Q may be present around ulcer **(feathery /fluffy margins with satellite lesions)**

JAYPEE BROTHERS

Predisposing Factors

- ***Injury by vegetative materials or animal tail are common modes of infection***ϙ.
- *Corneal disease, local immunosuppression*, long term use of topical steroid & antibiotics, prior corneal transplantation, contact lens wear, systemic immune suppression and diabetes (in **temperate zones**).

Diagnosis

Examination of wet KOH ϙ *& calcofluor white*, **for fungal hyphae** and culture on **Sabouraud's agent**.

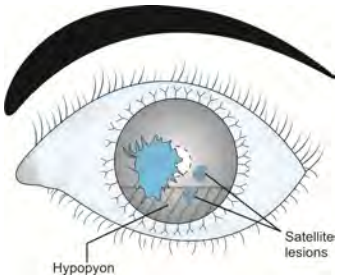

- A **big hypopyon** is present even if the ulcer is very small. Unlike bacterial ulcer the ***hypopym may not be sterile*** **(*pseudohypopyon*)** ϙ as fungi can penetrate into anterior chamber without perforation. **Hypopyon is thick and immobile (fixed non-shifting)** d/t direct invasion and enmeshing of fungal hyphae.
- ***Perforation is rare & corneal vascularization is conspicuously absent.*** ϙ

We	**W**esseley's sterile immune ring (yellow line) ϙ
Saw	**S**ymptoms are milder than signs would suggest ϙ
Vegetative	Seen after trauma by **vegetable** materialϙ
D	**D**ry looking ulcer ϙ
P	**P**seudohypopyon ϙ **(not sterile)**
S	**S**atellite lesions ϙ
Film	**F**eathery finger like extensions ϙ **(hyphated border)**, **F**ixed hypopyon

Treatment

Antifungal Agents

- **Polyenes (Amphotericin B, Natamycin & Nystatin)** bind to fungal cell wall ergosterol, but donot penetrate well through intact corneal epithelium.
- **Azoles** include imidazoles **(ie clotrimazole, e/keto/mi-conazole) and triazoles (ie flu/itra/vori/posa-conazole).**
- Pyrimidines **(flucytosine),** echinocandins **(capsofungin, micafungin)** and silver **sulfadiazine**ϙ**.**
- Systemic antifungal is required for severe keratitis & endopthalmitis only.

Adjuvant/Concurrent Therapy

- ***Cycloplegics as atropine or scopolamine*** ϙ are used to reduce ciliary spasm, uveal inflammation & prevent posterior synechiae formation
- Antiinflammatory & analgesics
- ***Carbonic anhydrase inhibitors for complications as secondary glucoma.***ϙ
- Tetracycline eg doxycycline can be used for anticollagenase effect.

★ Epithelial debridement, superficial keratectomy & keratoplasty may be required. **Steroids are contraindicated**ϙ

Herpes Simplex Virus : Ophthalmic Lesions

Herpes simplex virus (HSV) is **a *epitheliotropic, DNA virus***ϙ, which may become *neurotropic*. Its only natural host is man. It is of two types **(1) Herpes labialis/ HSV-I.** It is acquired by kissing or close contact. It typically causes infection ***above the waist*** ϙ **(2) Herpes genitalis/ HSV-II.** It is STD causes infection ***below the waist***ϙ. It is transmitted to eyes of neonates through infected genitals of mother. The lesions in the eye are mainly in the cornea, though in primary herpes skin and conjuctival lesions are known.

Primary Herpes

- Primary herpes (1st attack) involves a *non-immune* person & typic-ally occurs in *children*
- It clinically manifest as **severe *follicular keratoconjunctivitis*** with periorbital skin vesicles
- It is **usually self limiting and heals with out sequelae;** but the virus travels upto trigeminal ganglion and establishes the latent infection.

Recurrent Herpes

Recurrent infection is caused by re-activation of the virus which lies dormant in trigeminal ganglion. Predisposing stress stimuli which trigger an attack are – fever, infection, general ill health, steroids etc. Clinical features

Epithelial Keratitis	Stromal Keratitis	Metaherpetic Keratitis
• Fine and coarse superficial **punctate epithelial keratitis.** • **Dendritic ulcer** - It is **an irregular zig zag linear branching ulcer with knob at ends.** - ***Corneal sensation is markedly diminished*** ϙ - Floor of ulcer stains with	• **Disciform keratitis** ϙ - It is due to delayed type hypersensitivity reaction to HSV. - It is characterized by focal disc shaped stromal patch of stromal edema with out necrosis. - ***Presence of diminished***	• Also known as epithelial sterile trophic ulceration. • It is a mechanical healing

JAYPEE BROTHERS

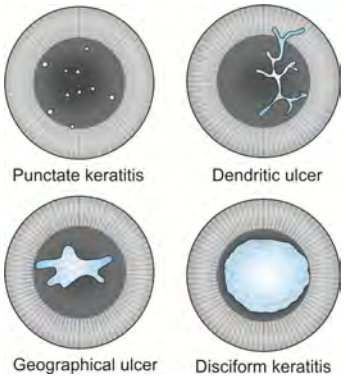

fluorescein and the ***virus laden cells at margin*** **take up** ***rose Bengal*** ♀ - It is characteristic lesion of recurrent herpetic keratitis. • **Geographical ulcer** ♀ - Branches of dendritic ulcer enlarge & coalesce to form a large epithelial ulcer with a **geographical or amoeboid configuration** - **Use of steroid in dendritic ulcer hasten the formation of geographical ulcer**♀. **Treatment** • ***Topical antiviral used*** ♀ • ***Topical steroid contraindicated*** ♀	***corneal sensations and keratic precipitates differentiates it form other causes of stromal edema*** ♀ - ***Wesley's ring*** ♀ or ring of infiltration may be seen • **Diffuse stromal necrotic keratitis** - It is caused by active viral invasion & tissue destruction **Treatment** ***Both topical antiviral and topical steroid used for treatment*** ♀	problem at the site of previous herpetic ulcer. • It is not an **active viral disease** **Treatment** ***Neither topical steroid nor antivirals used for treatment*** ♀

Causes of Corneal

Anaesthesia (Neurotrophic keratopathy)

- Congenital
  - Familial dysautonomia (Riley-Day syndrome)
  - Anhidrotic ectodermal dysplasia
  - Congenital insensitivity to pain
- Acquired
  - Alcohol block, electrocoagulation or section of gasserian ganglion or sensory root of trigeminal nerve for trigeminal neuralgia
  - ***Herpes simplex*** ♀
  - ***Herpes zoster*** ♀
  - Syphilitic (luetic) neuropathy
  - Leprosy
  - Diabetes
  - Acoustic neuroma
  - Abuse of topical anaesthetics

Hyposthesia

- Absolute glucoma
- Keratoconus anterior (axenfeld sign)

★**Neuroparalytic (exposure) keratopathy** is the result of improper wetting of the ocular surface by the tear film because of inability to close the eyes on blinking (lagopthalmos), despite normal tear production. It is seen in ***facial nerve palsy*** ♀ (as occurs in Bell's palsy, leprosy etc), severe proptosis and scarring of eye lids.

Enlarged nerves

- **F**uch's Corneal dystrophy
- **Old** age
- **Congenital** glucoma
- **L**eprosy ♀ (Hensen's disease)
- **I**cthyosis
- **N**eurofibromatosis ♀
- **K**eratoconus ♀
- **T**rauma
- **Refsum's** disease
- **MEN** type II B

Mnemonic – "**F**ind **Old** **Congenital LINK T**o **Refsum's MEN**"

Herpes Zooster Opthalmicus (HZO)

Etiology

It is caused by ***varicella-zoster virus*** ♀ (DNA virus). After an infection with *chicken pox* in childhood or youth the virus lies dormant in ***Gasserian ganglion of trigeminal nerve*** ♀ to appear later, particularly in elderly people ***with depressed cellular immunity e.g. cancer, leukaemia, AIDS, lymphoma and immunosuppressed organ transplant recipients*** ♀ etc.

Treatment

- **Oral acyclovir** (no later than 4 days after the onset of rash)
- Topical antiviral & antibiotic ointment are applied

Clinical Presentation

- **Lesions are** ***strictly limited to the one side of midline***. B/L lesions can occur in the immunocompromised.
- **Hutchinson sign –** In herpes zoster opthalmicus, **involvement of the tip of nose** supplied by external nasal nerve (a terminal branch of nasociliary nerve), **signifies increase risk of ocular involvement** (uveitis).
- **General features:** Onset of illness is sudden with fever, malaise, and severe *neuralgic pain* along the course of the affected nerve
- **Cutaneous lesions:** Appear in the area of involved nerve *after 3-4 days* of onset of disease. To begin with the affected areas becomes *red and oedematous* (mimicking erysipelas) followed by *vesicle* ***(weeping***

JAYPEE BROTHERS

on skin & lids.
- In scleritis, sclerosing keratitis or iritis, **dexamethasone** 0.1% along **with antiviral** is used **topically**
- **Systemic steroids** are used in progressive proptosis with total occulomotor nerve palsy & optic neuritis
- Oxyphenbutazone (NSAIDs) are sometimes useful in severe scleritis not responding to steroids.
- Neurotrophich ulcers are treated by tarsorrhaphy of lateral half of lid.

rashes) formation. The vesicles *suppurate, bleed*, and cause *small permanent pitted scars*. The active eruptive stage lasts for *3 weeks*. There occurs some anaesthesia of the affected skin which when associated with continued post herpetic neuralgia is called **anaesthesia dolorosa**. Inspect the hairline at the scalp for **post-herpetic scarring** & pigmentary changes.
- **Ocular lesions include**

- **Conjunctivitis** (m.c.) may be mucopurulent, follicular or rarely necrotizing.
- **Episcleritis & scleritis**
- **Iridocyclitis (anterior uveitis).** Transilluminate the iris for **sectoral stromal atrophy of iris.**
- **Secondary glucoma**Q
- **Anterior segment necrosis & pthisis bulb**
- ***Rare*** neurological complication eg. ***Motor nerve palsies***Q especially 3rd, 4th, 6th & 7th, Optic neuritis and Encephalitis.

HZO Keratitis

1. **Epithelial Keratitis**
   - **Punctate epithelial keratitis** or **pseudo dendrites. (Pseudodendritic keratitis**). Pseudodendrites are typically smaller than dendrites, and lack terminal end bulb formations. They are transient and usually resolve within 2 weeks after the cutaneous eruption, and steroids have little to no effect. *Microdendritic epithelial ulcers*: unlike of dendritic ulcers of HSV, these are usually peripheral and stellate rather than exactly dendritic in shape.
   - **Chronic epithelial keratitis**
2. **Nummular (Anterior Stromal) Keratitis**
3. **Dissiform (Deep stromal) Keratitis or Endothelitis**
4. **Limbal Vascular Keratitis (Sclero-Keratitis)**
5. **Neurotrophic Keratitis (Neuroparalytic ulceration) d/t destruction of sensory gasserian ganglion**
6. **Exposure keratitis (d/t facial nerve pasly).**

Acanthamoeba (Protozoal) Keratitis

Epidemiology

- ***It is a free living protozoa*** Q (not helminth) found in air, soil & fresh or brackish waters.
- ***It does not require a human host to complete their life cycle.*** Q They have two stages – active (trophozoite) and dormant (cystic). Trophozoite feed on E. Coli or other gram-negative bacilli and when exposed to unfavorable conditions, undergoes immediate encystment. Cystic are resistant, dormant stage. Excystment occurs when favourable condition occurs.
- Trophozoites are infective form and are believed to gain entry into the body through the lower respiratory tract, ulcerated skin and invade CNS by hematogenous dissemination.

- ***Infection is more common in chronically ill immuno-compromised or other debilitated patients*** Q
- ***Humans are largely resistant, though keratitis may occur following minor corneal abrasions*** Q (e.g. contact lens wearer)
- ***In immunosuppressed patients acanthamoeba infections may result in granulomatous amebic encephalitis (GAE) and disseminated infection.*** Q

Clinical Features

Symptoms	Signs
- Blurred vision with **severe pain which is far out of proportion to the clinical findings**Q.	- There is inflammation & cellular infiltration of corneal epithelium f/b stroma ultimately l/t necrosis (corneal melting).
- *Delay in diagnosis is common* as the clinical appearance mimics viral (HSV) keratitis, non healing corneal abrasion and fungal keratitis. So it is important to maintain a **high index of suspicion in any patient who responds incompletely to antibacterial therapy**.	- Early epithelial disease is a/w **irregular and grayish epithelium** (earliest feature), infiltration of epithelium, **pseudo dendrites or elevated epithelial ridges** (mistaken for *herpes simplex kratitis*), limbitis along with diffuse or focal anterior stromal infiltrates (around corneal nerves).
- It usually occurs in **contact lens wearers** or	- **Radial perineural infiltrates (radial keratoneuritis) is pathognomic** and appear during **first 1-4 weeks.** - Later disease show a **characteristic ring infiltrate** (that resemble

JAYPEE BROTHERS

Risk Features

- ***Extended wear soft contact lenses*** ♀. *Soft contact lens wearers* are at particular risk. It is ***most common cause of keratitis in soft contact lens users*** ♀ ***(after pseudomonas*** ♀***)***
- ***Use of homemade saline for contact lens*** ♀**.** Contact lens wearers who use (homemade) distilled water and saline (salt tablets) instead of commercially prepared solutions are at particular risk.
- Wearing of contact lens while swimming.
- ***Exposure to dirty water*** ♀
- ***Wind blown contamination*** ♀
- Corneal trauma
- Injury with veg matter may also cause corneal abrasions which is a predisposing factor for acanthameba infection

Treatment

- Since, a delay in treatment adversely affect visual outcome and the outcome is very much better if treatment is **started within 4 weeks** of onset of symptoms. Suggested **topical amoebicides** include

1. Cationic antiseptics inhibiting membrane function eg **PHMB** (***polyhexamethylene biguanide)***♀ *and* **chlorhexidine digluconate** (both 0.02%) are **first line agents.**
2. Aromatic diamidines inhibiting DNA synthesis eg **hexamide** di – isethionate, **pentamidine, and propamidine** (Brolene)
3. **Aminoglycosides** eg *neomycin & paromomycin*, which disrupt the plasmalemma & facilitate the entery of effective drug into cornea.
4. **Imidazoles**, which destabilize the cell wall eg *clotrimazole, fluconazole, ketoconazole, and meconazole*.
5. **DMSO** (dimethyl sulfoxide) used with propamidine to increase corneal penetration.

- **Topical steroids** : but it should be terminated before cessation of antiamoebal therapy. According to some ophthalmologist corticosteroid should not be used
- Debridement and keratoplasty.

rarely in non contact lens wearers **swimming or bathing in contaminated water.** - There may be no h/o antecedent trauma and is **often unilateral**. **Severe pain** is d/t deep linear stromal infiltrates localized along the corneal nerves. Variable degree of photophobia, redness & watering may be present.	stromal herpetic disase), along with uveitis. - Gradual enlargement and coalescence of the infiltrates form a **central or paracentral ring abscess** and **satellite lesions.** - Conjunctival chemosis and injection are often present. Scleritis (generally reactive; anterior & posterior with ± optic neuritis), slowly progressive stromal opacification, corneal neovascularization and **corneal melting** (often peripheral) is usual sequale. Hypopyon & cataract may also develop.

Diagnosis

- Diagnosis is established by staining of corneal scrapings & contact lenses with ***calcofluor white*** ♀, a chemifluorescent dye with an affinity for amoebic cyst. **Acridine orange**, **PAS, Gram's and Giemsa stains** may also demonstrate cysts.
- Acanthamoeba grows at 25-35°C. ***Corneal scrapings should be cultured on non-nutrient agar*** ♀ **(E. coli enriched)**. It shows trophozoites with in 48 hours which gradually turn into yeasts
- ***Plaque formation on culture over non-nutrient agar enriched with E. coli is characteristic feature of acanthameba infection*** ♀**.**
- **Invivo confocal microscope** establish the diagnosis based on visualization of pear shaped cysts (11-15µm) and irregular trophozoites. Trophozoite stage of acanthameba looks like macrophage.
- **Phase contrast microscopy, Biopsy**, recently PCR is a sensitive method of detecting Acanthamoeba.
- **Buffered charcoal yeast extract agar** is an alternative medium but offers lower recovery rates compared with **non nutrient agar with live bacteria overlay**.

Band Shaped Keratopathy

- It occurs due to ***deposition of calcareous salts*** ♀ **(calcium hydroxyapatite)** in Bowman's layer, epithelial basement membrane & anterior stroma.
- It is a *degenerative condition*. A whitish band appears in the inter palpebral area, commencing at the inner & outer sides, progressing until it forms a continuous band across the cornea. It occurs in
  - Chronic eye diseases like uveitis, glaucoma, keratitis or trauma. Chronic uveitis especially in blind shrunken eyes, & Still's disease. Aphakic eyes following vitrectomy with silicone oil.
  - Systemic diseases with raised serum calcium like Hyperparathyroidism, Vitamin D toxicity, ***Sarcoidosis*** ♀**.**
- **Sarcoid** presents with translucent, orange conjunctival nodules, ***band shaped keratopathy*** ♀ and uveitis and ***Uveoparotid fever (Heerfoldt disease)*** i.e. bilateral simultaneous involvement of entire uveal tract, parotid gland and cranial nerves.

JAYPEE BROTHERS

Keratoconus (Conical Cornea)

It is a noninflammatory, bilateral (85%) & asymmetrical ectatic condition of cornea which presents with ***protrusion of central part of the cornea with thinning of its central & inferior paracentral areas*** ♀. It usually *starts at puberty* and progresses slowly.

Associations

- **Systemic disorders** include, Down, Turner, Ehlers Danlos and Marfan Syndromes, atopy, Osteogenesis imperfecta & mitral valve prolapse
- **Ocular associations** include **vernal keratoconjunctivitis**♀, blue sclera, aniridia, ectopia lentis, Leber congenital amaurosis & retinitis pigmentosa. Rigid contact lens wear & constant eye rubbing area also predisposing factors

Management

- **Spectales** for regular or mild irregular astigmatism
- **Rigid contact lens** ♀ for higher astigmatism
- **Epikeratoplasty** in patient intolerant to lens & without significant central corneal scarring
- **Keratoplasty** penetrating or deep lamellar is indicated in significant corneal scarring
- **Intracorneal ring** segment implants (intacs)
- Corneal collagen cross linking using riboflavin drops to photosensitize eye **f/b UV-A light exposure, stabilizes or reverse ectasia**♀ **(at least in some).**

Clinical Presentation

Impairment of vision due to progressive myopia and astigmatism ♀, which subsequently becomes **irregular.** It can be graded by ***keratometry***♀ according to severity as mild (< 48D), moderate (48-54 D) and severe (> 54D).

Early signs	Late sign
- Corneal topography is the most sensitive method for detecting very early keratoconus - Prominent corneal nerves - **Oil droplet reflex** on direct opthalmoscopy from one foot - Slit lamp biomicroscopy shows very fine, vertical, deep stromal striae (**Vogt lines**) which disappear with external pressure on the globe - Keratometry show irregular astigmatism where the principle meridia are no longer 90⁰ apart and the *mires cannot be superimposed (i.e. are malaligned)* - Retinoscopy show an **irregular scissor or yawning reflex and astigmatism.** - Window reflex is distorted - Placido disc examination shows irregularity of circles	- ***Progressive corneal thinning*** ♀ with poor visual acuity resulting from marked irregular myopia, astigmatism with steep keratometry (K) readings - ***Bulging of lower lid in downward gaze (Munson sign)*** ♀ - ***Epithelial iron deposits (Fleischer ring)*** ♀ surround the base of cornea and are best visualized with cobalt blue filter. - Stromal scarring - **Acute hydrops** is an acute influx of aqueous into the cornea as a result of rupture in Desmet membrane leading to a sudden drop in visual acuity, discomfort & watering. Break heals in 6-10 weeks. Acute episode is treated by hypertonic saline, patching or a soft bandage contact lens.

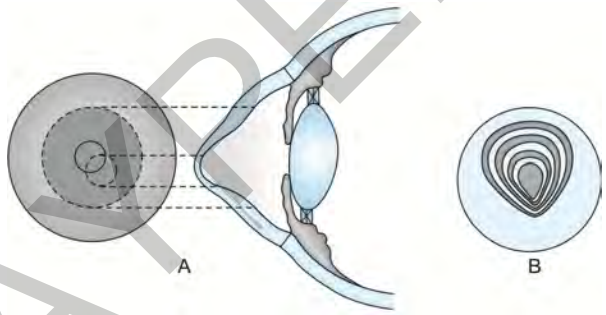

Keratoconus showing: A, configuration of cone-shaped cornea: B, irregular circles on Placido disc examination.

Keratoconus presents with – "**I H**ad **FAMOUS P**lan" i.e.

I	• **I**rregular circles on placido disc examination **I**rregular scissor or yawning reflex on retinoscopy **I**rregular astigmatism on retinoscopy
Had	• **H**ydrops
F	• **F**leischer ring ♀
A	• **A**stigmatism ♀
M	• **M**yopia ♀ **M**unson sign ♀ **M**alaligned mires on keratometry
O	• **O**il droplet reflex ♀ on direct opthalmoscopy
U	• **V**ogt lines on slit lamp biomicroscopy
S	• **S**tromal thinning in central & inferior paracentral areas
Plan	• **P**rotrusion (apical) of anterior cornea♀

JAYPEE BROTHERS

Corneal Transplantation (Grafting)/Keratoplasty

ContraIndications (CI)

Absolute CI	Relative CI
I. d/t Risk of transmission of communicable disease from donor to recipient	
Unknown: death due to unknown causeQ. Death d/t neurological disease of unknown (unestablished) diagnosis, encephalopathy of unknown origin or progressive encephalopathy	**Sub acute sclerosing panencephalitisQ**
Active: Active meningitis or encephalitis, Active septicemia (bacteremia, fungemia, viremia, parasitemia), **Viral hepatitis, Active miliary TB or tubercular meningitisQ**	Progressive multifocal-leukoencephalopathy
Rabies, HIV positive, HBsAg PositiveQ, Hepatitis C seropositive, HTLV I or II infection (many H)	Congenital rubella, Reye's syndrome
Creutzfeldt- Jackob disease	**Active ocular inflammation** e.g. conjunctivitis, scleritis, iritis, uveitis, vitreitis, choroiditis & retinitis (at the time of death
II. d/t Risk of transmission of non communicable disease from donor to recipient	
- **Active disseminated lymphoma** - **Leukemia's**	- Death d/t cyanide poisoning - Intrinsic eye disease, Retinoblastoma, malignant tumors of anterior segment or known adenocarcinoma of eye (1° or 2°)
III. Conditions affecting graft outcome	
No absolute CI	Patients on ventilator for > 72 hrs Congenital or acquired anterior segment abnormalities like corneal scar, keratoconus, keratoglobus, Fuch's dystrophy or prior refractory surgery

Types

- Full Thickness or Penetrating keratoplasty
- Partial Thickness or Lamellar Keratoplasty
  - **Superficial LK** (replacement of corneal epithelium & superficial stroma)
  - **Deep anterior LK (DALK).** all opaque tissue almost upto the level of Descemet membrane is removed
  - **Descemet stripping endothelial Keratoplasty (DSEK)/DS** automated EK (**DSAEK**; when a microkeratome is used to perform donor lamellar dissection)/ **Posterior LK (PLK)**
- Small Patch grafts which can again be full or partial thickness

Features of Corneal Graft Rejection

- Dimunition of vision, photophobia, redness & mild pain weeks to years after corneal transplant are indicative of acute graft rejection unless proven otherwise.
- ***Ciliary injection***Q & *anterior uveitis* is a prerejection sign.
- *Epithelial rejection* presents with irregular elevated line of abnormal epithelium ***(epithelial rejection line)***
- *Stromal rejection* presents with subepithelial infiltrates, & **Krachmer spots** i.e. reminiscent of adenoviral infection
- *Endothelial rejection* presents with **Khodadoust line** of *linear keratic precipitates* (d/t WBC deposition) & associated area of inflammation at graft margin and stromal oedema
- Increased flare, cells in anterior chamber & ***circumcorneal congestion***Q.

Donor's Eye

Age

- Cornea from donors b/w ***5 to 60/70 years age are preferred but the age limit at both ends are arbitrary (not fixed)***Q

Preservation

- Donor tissue **should be removed within 24 hrs (*ideally within 4-6 hrs*) of death**Q**.**
- The newer preservation methods involve preservation of cornea alongwith a 2-3 mm sclera rim (corneoscleral rim). This technique sequestrates the endothelium from the deleterious effects of post

HLA-matching is Not mandatory

- ***As the corneal tissue is avascular****, it is considered an immunologically privileged site.* ***Corneal transplants are unique in the sense that HLA typing and Systemic*** *immunosuppression is not mandatory*Q.
- Despite these advantages the cornea does express HLA antigens as well as minor histocompatibility

JAYPEE BROTHERS

- Below 5, cornea is floppy with high risk of astigmatism & above 70 endothelial count is low.
- Presence of arcus senilis is not a contraindication but may limit the size of graft for aesthetic reasons.

mortem aqueous'. Although **whole globe** may also be preserved.

1. **Whole globe enucleaten** is stored in ***moist chamber storage***Q. In situ corneo-sclerial rim excision with immediate transfer into storage media
2. Corneal clera rim is preserved in
   a. Media for hypothermia storage at 4°C
      1. Short term (eg M. K. medium)
      2. Intermediate term (eg Optisol 6S)
   b. Media for ***organ culture*** at 30°C to 37°C
   c. Cryopreservation

antigens and rejections do occur.

- *Although there is agreement that HLA matching does not improve the success of low risk corneal transplantation a number of studies now suggest benefit of matching in high risk patients.*
- **Slit lamp Slit lamp examination and specular microscopy is the most important quality control evaluation** for corneal donor tissue. A careful slit lamp examination and (or) specular microscopy is the 'sine quanon' quality control of a first class eye bank before release of tissue to accepting surgeon.
- Specular microscopy allows better and more precise assessment of corneal endothelium than an ordinary clinical slit lamp

Slit lamp examination	Specular microscopy
Used for evaluation of corneal epithelium, stroma and endothelium	*Allows detailed and precise determination of individual endothelial cell morphology and cell density (endothelial cell count)*

Cornea Verticillate (Vortex Keratopathy)

Etiology

- **P**henothiazines
- **I**ndomethacin
- **C**hloroquine & hydro**c**hloroquine (**A**ntimalarials)
- ***Amiodarone***Q
- **Fabry** disease (& its carrier state)

Mn- Fry PICA

Clinical Feature

- It is characterized by *whorl like corneal epithelial opacity (deposits)* seen in patients on long term treatment with (PICA) medications. The whorl pattern shows the *direction of migration of corneal epithelial cells*.
- ***Generally asymptomatic, harmless and reversible on stopping the drug***Q.
- Although deposits may involve the visual axis, ***vision is not impaired*** but sometimes patient may experience *glare, haloes around light and surface discomfort which responds to topical lubricants*.
- *Bilateral, fine greyish or* ***golden brown opacities***Q in the *inferior corneal* epithelium. *Arborizing horizontal lines* resembling cat's whiskers or whorl like pattern originating from a point below pupil, sparing the limbus.

Course & Treatment

- Higher the dose & longer the duration of amiodarone administration the more advanced the corneal deposits. Whereas, unlike retinopathy, chloroquine induced keratopathy bears no relationship to dosage or duration of treatment.
- The ***changes are usually reversible on cessation of therapy, although they may clear despite continued administration. Because it does not affect vision its presence is not an indication to discontinue treatment***Q.

JAYPEE BROTHERS

Xeropthalmia

Ocular manifestations of vitamin A deficiency ranging from night blindness to corneal melting are termed as xeropthalmia. It is largely limited to the first 6 years of life.

WHO Classification

Stage	Feature	
X N	*Night blindness* Q	*Earliest symptom* Q
X 1 A	**Conjunctival xerosis**	Patches of dry, lusterless, nonwettable conjunctiva described as emerging like sand banks at receding tide. Characterized by **loss of goblet cells, keratinization (hyper keratosis)** and **squamous metaplasia**Q**.**
X 1 B	***Bitots spot*** Q **(caused by Corynebacterium xerosis)**	Usually B/L **temporal raised,** silvery white foamy triangular **patch of keratinized epithelium**Q situated on bulbar conjunctiva
X 2	Corneal xerosis	Punctate keratopathy f/b dry, hazy & lustureless cornea
X 3 A	**Corneal ulceration / keratomalacia**Q affecting < 1/3 corneal surface	Sterile **corneal melting by liquefactive necrosis is Keratomalacia (late feature)** Q
X 3 B	Corneal ulceration / keratomalacia affecting > 1/3 corneal surface	
X S	Corneal scar	
X F	Xeropthalmic fundus	

Management of Xeropthalmia

Prophylaxis (Vitamin A)	
Infant 6-12 months old or any children < 8 kg	1 lac IU orally every 3-6 months
1-6 year children	2 lac IU orally every 6 months
Lactating mother	20,000 IU orally once at delivery or during the next two months to protect breastfed infant
Infants < 6 months not being breastfed	50,000 IU orally

Treatment	
• Local ocular therapy e.g. artificial tears etc. • Vitamin A therapy	
All patients of > 1 year age except women of reproductive age	20,000 IU orally or 10,000 IU IM on 1st day 2nd day & 4 weeks later
Children < 1 year age or < 8 kg weight	Half of the above dose
Women of reproductive age pregnant or not:	
- Upto X 1B stage	10,000 IU orally daily for 2 weeks
- Corneal xerospthalmia (2, 3A, 3B)	Dose of > 1 year age

Sclera

It is tough white coloured opaque outer covering of eyeball & is composed of collagen & elastin

3 (ill defined) layer

- **Episclera** (outermost)
- **Sclera proper**: scleral stroma is composed of collagen bundles (**mostly type I**, some type III & IV) of varying size & shape that are not as *uniformly orientated as in cornea (causing opaque appearance).*
- **Lamina fusca** (inner layer) blends with suprachoroidal & supraciliary lamellae of uveal tract.

Thickness	Area
1 mm	Posterior pole near optic nerve (**thickest**)
0.66 mm	**At** the insertion of rectus muscles
0.33 mm	**Beneath** the rectus muscles
0.30 mm	**Just behind the insertion of rectus muscle**Q (**thinnest**)

- **Pierced By**

Anteriorly
- Anterior ciliary arteries
- Episcleral veins

- **Posteriorly**
- Posterior ciliary nerve & vesslels
- Optic nerve (pass through lamina cribrosa of sclera)
- Vortex vein

- **Avascularity** & **lack of reaction** of its dense fibrous tissue to traumatic & infective insults, make disease of sclera very rare; & when they do occur, they tend to be chronic and slow to respond to treatment.

JAYPEE BROTHERS

for detailed information on PGMEE books, visit our website **www.jaypeebrothers.com,** for detailed information on PGMEE books, visit our website **www.jaypee**

New ACROSS

A Complete Review of Short Subjects

Why this book?

- The first and the most sought after subjectwise book for PGMEE and the bestselling MCQs book on short subjects.
- The book which has given a new approach and horizon to PGMEE preparation
- Thoroughly revised and updated edition with new layout
- Book covers all questions from 2001 onwards
- All MCQs of All India (NBE Pattern), AIIMS, PGI, DNB, and State-based MCQs up to 2016 have been included
- Detailed, yet concise, short notes are added for each chapter
- Subjects divided into theory and MCQs and further divided into chapters and subchapters, according to their topics such that the study material is easily retainable and understandable for students
- Each new edition is not only an addition of few hundred new questions; as each line of the book is completely revised and updated based on the latest editions of various standard textbooks everytime. Controversial questions are explained with complete references
- A completely revised, researched, concise and condensed (PGMEE-oriented) presentation of important topics and basic concepts with numerous self made tables, figures, flow charts and mnemonics throughout the book, to save student's ample time for preparation
- Provides a methodology to approach PGME examination; includes valuable pedagogical features and many topics of medicine, surgery and pharmacology, coinciding with short subjects
- Indispensable for course review and PGME examinations. Authors recommend to start reading and retaining this book after 2nd professional, during clinical postings.

Available at all medical bookstores
or buy online at www.jaypeebrothers.com

JAYPEE BROTHERS
Medical Publishers (P) Ltd.
www.jaypeebrothers.com

Join us on facebook.com/JaypeeMedicalPublishers

ISBN 978-93-86322-73-9