nation on medicine books, visit our website www.jaypeebrothers.com, for detailed information on medicine books, visit our website www.jaypeebrothers.com

GS Sainani
Rajesh G Sainani

Manual of Clinical & Practical Medicine



2nd Edition

JAYPEE

Contents

Preface to the Second Edition *vii*
Preface to the First Edition *ix*
Acknowledgments *xi*
1. Nutrition Including Obesity **1**
2. Infectious Diseases **24**
3. History Taking and General Examination **52**
4. Gastrointestinal System **85**
5. Cardiovascular System **126**
6. Respiratory System **209**
7. Nervous System **258**
8. Nephrology and Acid Base Disorders **341**
9. Endocrine and Metabolic Diseases Including Diabetes Mellitus **359**
10. Hematology and Oncology **410**
11. Musculoskeletal System **443**
12. Electrocardiography **483**
13. Imaging **531**
14. Procedures **605**
15. Diet **627**
16. Table Viva Voce **642**
17. Emergencies **707**
Appendix A Abbreviations **769**
Appendix B Laboratory Reference Values **773**
Appendix C Picture Credits **781**
Index *783*

CHAPTER

Gastrointestinal System

4

JAYPEE BROTHERS

CONTENTS

Introduction
Symptoms of GI Disorders
Symptoms of Hepatobiliary Disorders
General Examination of GI and Hepatobiliary Systems
Examination of Abdomen
Inspection of Abdomen
Palpation of Abdomen
Examination of Liver
Examination of Spleen
Examination of Kidneys
Urinary Bladder
Gallbladder
Cecum, Appendix, Descending Colon and Sigmoid Colon
Percussion of Abdomen
Auscultation of Abdomen
Inguinal Hernia and Inguinal Glands
Male Genitalia
Anus and Per Rectal Examination
Clinical Cases
Helicobacter pylori Infections
A Case of *Helicobacter Pylori* (*H. pylori*) Infection
A Case of Cirrhosis of Liver
A Case of Ascites
Spontaneous Bacterial Peritonitis (SBP)
Hepatorenal Syndrome
Hepatopulmonary Syndrome
Budd-Chiari Syndrome
Nonalcoholic Fatty Liver Disease (NAFLD)
A Case of Hepatosplenomegaly
A Case of Hepatomegaly
A Case of Splenomegaly
A Case of Jaundice
A Case of Diarrhea
Liver Abscess
A Case of Pyogenic Liver Abscess
A Case of Amebic Liver Abscess
A Case of Noncirrhotic Portal Fibrosis
A Case of Portal Hypertension
A Case of Hepatocellular Carcinoma
A Case of Tuberculosis of Abdomen
A Case of Irritable Bowel Syndrome (IBS)
Acute Pancreatitis

INTRODUCTION

The gastrointestinal (GI) system is a system of serially connected organs and measures 8 m in length, extending from the mouth to the anus. There are secretory glands all along the GI tract. The functions of GI system are propulsion, processing, absorption and elimination of ingested food. Other functions relate to hormonal secretion and immune response.

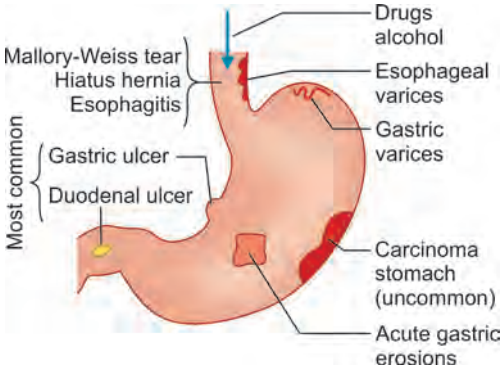

Fig. 4.1: Causes of upper GI bleeding

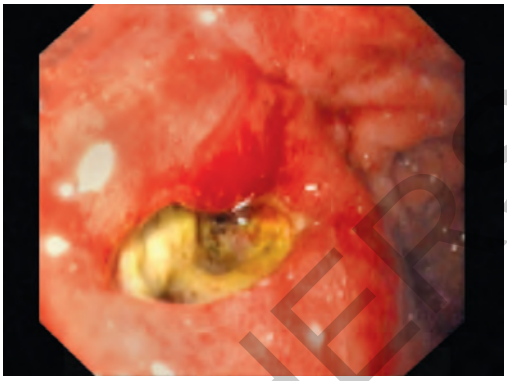

Fig. 4.3: Duodenal ulcer (on endoscopy)

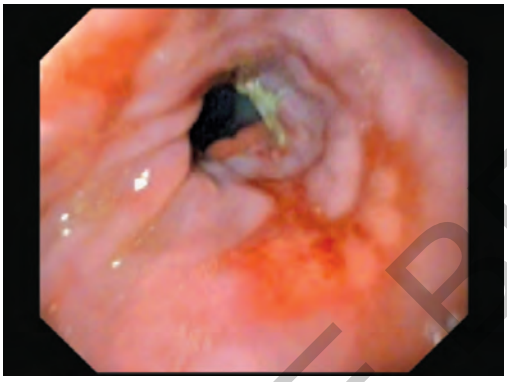

Fig. 4.2: Esophagitis (on endoscopy)

SYMPTOMS OF GI DISORDERS

1. **Oral**—Dry mouth, water brash, aphthous ulcers, altered taste sensation (dysgeusia) and halitosis.
2. **Esophagus**—Dysphagia, heartburn (retrosternal, epigastric), acid reflux, painful swallowing (odynophagia), feeling of lump in the throat (globus) and hematemesis (see Figure 4.1 for causes and Figures 4.2 and 4.3 for endoscopy pictures of esophagitis and duodenal ulcer). constipation and diarrhea (ileocecal tuberculosis, irritable bowel syndrome [IBS]), abdominal distension, lump in abdomen, melena (black stools), hematochezia (bleeding per rectum) (see Fig. 4.4 for causes) and mucus in stools.
3. **Stomach**—Nausea, vomiting, flatulence (gaseous distension, indigestion, belching), hiccups, epigastric pain and hematemesis.
4. **Intestines**—Constipation, diarrhea, altered bowel habits (carcinoma of colon), alternate.
5. **General symptoms**—Loss of weight and malnutrition (anemia, edema, vitamin deficiencies).

SYMPTOMS OF HEPATOBILIARY DISORDERS

- Jaundice
- Upper abdominal pain
- Abdominal distension (ascites)
- Edema legs
- Loss of appetite
- Loss of weight
- Bleeding—petechiae, ecchymosis
- Hematemesis, melena
- Fever
- Fatigue, weakness
- Itching (pruritus)
- Altered mental state
- Gynecomastia
- Loss of secondary sex characters
- Decreased libido

JAYPEE BROTHERS

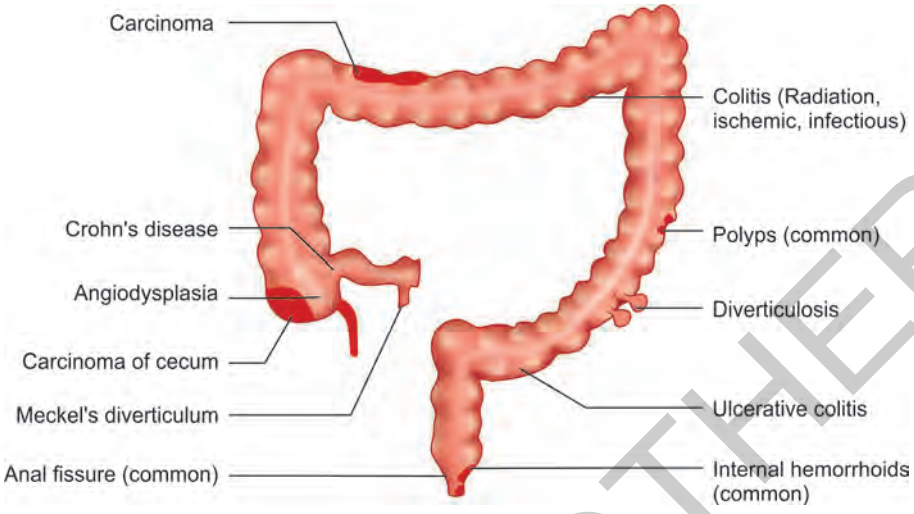

Fig. 4.4: Common causes of lower GI bleeding

We shall now discuss common symptoms:

1. **Causes of dry mouth (xerostomia)**—Dehydration (poor fluid intake, increased fluid loss), mouth breathing, diseases of salivary glands (mumps, Sjögren's syndrome, salivary calculi), drugs (anticholinergics, antidepressants), depression and anxiety (transient dryness of mouth).
2. **Causes of excessive salivation**—Irritating oral lesions, parkinsonism, esophageal obstruction, anxiety and drugs (iodine containing medicines).
3. **Disorders of taste**—Loss of primary taste sensation (sweet, bitter, salty, sour) due to lesions of VII and IX cranial nerves. Inability to appreciate flavors: disease of nasal mucosa and rarely lesions of olfactory nerves and abnormal taste: cerebral pathology and aura of epilepsy.
4. **Dyspepsia**—It is a symptom complex of nausea, vomiting, vague upper abdominal pain, flatulence, acidity and belching. Common cause is acid peptic disease (ulcerative). Some patients have nonulcer dyspepsia.
5. **Causes of nausea and vomiting**—
   - Acid peptic disease
   - Gastritis secondary to alcohol consumption, drugs and food poisoning
   - Early morning sickness (early pregnancy), infective disorders (viral hepatitis, appendicitis, pancreatitis, acute cholecystitis, malaria)
   - Increased intracranial pressure, migraine, psychogenic, achalasia cardia, pyloric stenosis, radiation therapy, chemotherapy, postoperative and a side-effect of many drugs.
6. **Hyperacidity**—Patient complains of retrosternal and epigastric burning pain, which is worse after meals, particularly after intake of spicy food and consumption of tea, coffee, soft and alcoholic drinks; smoking; and chewing pan masala and tobacco. It may be psychogenic (anxiety, stress, tension).
7. **Dysphagia** (esophageal obstruction, causes are listed in Box 4.1). **Hiatus hernia** is of two types**: sliding**, in which lower esophagus and upper portion of stomach herniate above the diaphragm,

JAYPEE BROTHERS

Box 4.1 Causes of dysphagia

- Upper one-third
  - Severe pharyngitis, esophagitis, esophageal ulcers
  - Carcinoma (pharynx and esophagus)
  - Compression (enlarged lymph nodes and goiter)
  - Neurogenic (bulbar palsy, myasthenia gravis and motor neuron disease)
  - Psychogenic (globus hystericus)
  - Iron deficiency (Plummer–Vinson or Kelly-Patterson syndrome), esophageal web, esophageal diverticulum
- Middle one-third
  - Carcinoma
  - Compression (enlarged lymph nodes, tumors and aneurysm of aorta)
- Lower one-third
  - Carcinoma (stomach, esophagus)
  - Hiatus hernia
  - Esophageal stricture
  - Achalasia cardia
  - Systemic sclerosis
  - Esophagitis
  - Candidiasis

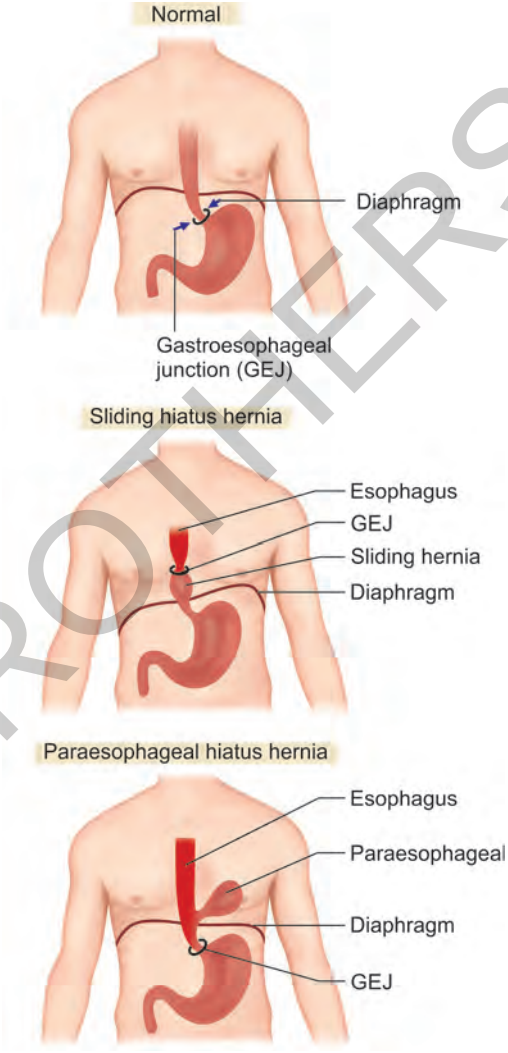

Fig. 4.5: Different types of hiatus hernia

and **paraesophageal**, in which lower most esophagus and esophagogastric junction remain below the diaphragm but upper portion of stomach herniates into thorax along the side of esophagus (Fig. 4.5). Sliding hernia is common and long-standing cases have typical symptoms of gastroesophageal reflux disease (GERD) (Fig. 4.6). Paraesophageal hiatus hernia is uncommon, and cases have no symptoms of GERD but long-standing hernia may get strangulated or may present with bleeding. Barium swallow is useful in identifying the type, size and the complications of hiatus hernias (Fig. 4.7).

8. **Pain in abdomen** (see Fig. 4.8 for causes).
   a. **Colicky**—Caused by spasm or obstruction to a hollow viscera. (a) Intestinal (periumbilical), (b) biliary (right hypochondriac region) and (c) ureteric (lumbar region). Patient is restless, tossing about with legs drawn towards abdomen and hands over the region of pain.
   b. **Inflammation**—Peritonitis (secondary to perforated viscus [intestine, appendix]), cholecystitis and pancreatitis. Pain is constant, the patient lies still. There is tenderness and guarding of abdominal wall, which hardly

JAYPEE BROTHERS

moves with breathing. Other causes of inflammatory pains are pyelonephritis, cystitis, diverticulitis, endometritis, salpingitis and inflamatory bowel disease.

c. **Referred pain**—(a) From abdominal viscera which corresponds to the segmental sensory nerve supply of overlying peritoneum (e.g. distension of hepatic and renal capsules causes pain) and (b) from extra-abdominal sources (e.g. acute myocardial infarction, pneumonia, pulmonary infarction, pleurisy, herpes zoster).

d. **Ischemic pain**—Mesenteric angina, splenic infarction, renal infarction and necrosis in hepatoma.



Fig. 4.6: Sliding hiatus hernia (on endoscopy)



Fig. 4.7: Irreducible sliding hiatus hernia with high gastroesophageal junction

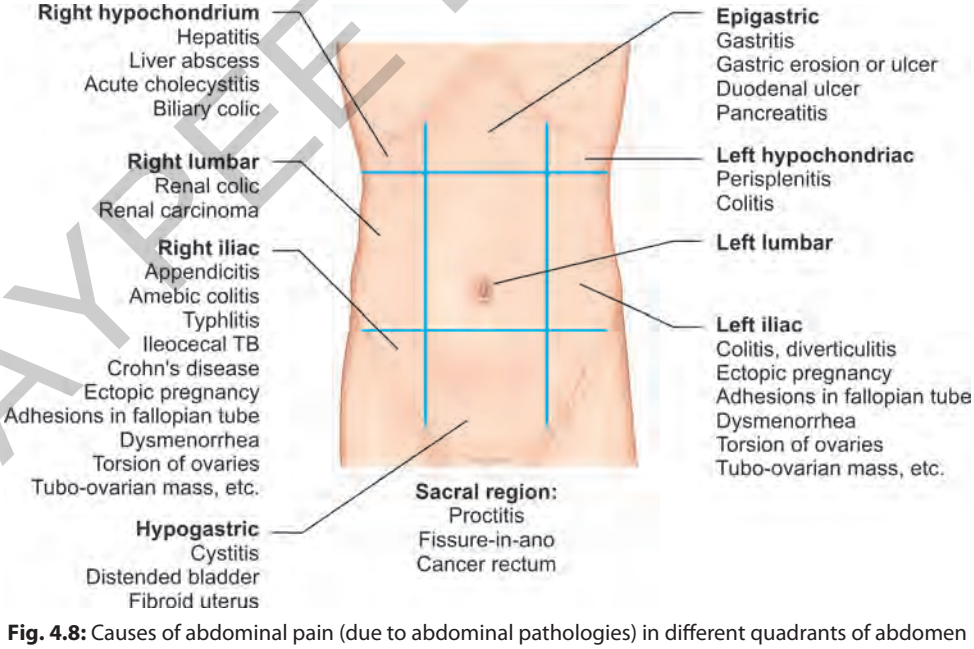

Fig. 4.8: Causes of abdominal pain (due to abdominal pathologies) in different quadrants of abdomen

JAYPEE BROTHERS

e. Metabolic—Diabetic ketoacidosis, hypercalcemic crisis, uremia and acute intermittent porphyria.

f. Hematological—Sickle cell crisis, paroxysmal nocturnal hemoglobinuria and hemorrhagic diathesis.

Pain of abdominal origin can radiate to distant areas (Box 4.2).

9. Diarrhea—Small bowel diarrhea (large watery stools without mucus or blood) or large bowel diarrhea (small sticky stools with blood, mucus and pus cells).

Causes

a. Infection
- Viral (rotavirus, adenovirus),
- Bacterial (*Escherichia coli*, *Salmonella*, *Shigella*, *Vibrio cholerae*),
- Parasitic (*Giardia lamblia*, *Entamoeba histolytica*) or
- Fungal infections; food poisoning, traveler's diarrhea,

b. Other causes

Drugs (ampicillin, amoxycillin, laxatives); IBS, ulcerative colitis, Crohn's disease, spurious diarrhea (fecal impaction), malabsorption, steatorrhea (tropical sprue).

10. Constipation—Common causes are dyschezia (bad habit of not going to toilet to ease bowels), low-fiber diet (eating more of nonvegetarian food and less of green vegetables).

Box 4.2 Radiation of visceral pain

Pancreas	–	Back
Gall bladder	–	Right shoulder
Spleen	–	Left shoulder
Kidney	–	Flanks
Genitourinary	–	Groin

Box 4.3 Causes of parotid gland enlargement (Fig. 4.9)

- Mumps
- Cirrhosis of liver
- Leprosy
- Diabetes mellitus
- Sjögren's syndrome
- Sarcoidosis
- Leukemia
- Lymphoma
- Parotid calculi
- Postoperative
- Parotid tumors
- Suppurative parotitis



Fig. 4.9: Bilateral parotid gland enlargement

GENERAL EXAMINATION OF GI AND HEPATOBILIARY SYSTEMS

- Built, nutrition, body mass index, skinfold thickness
- Pallor, koilonychia, pedal edema
- Jaundice, scratch marks, xanthelasma
- Aphthous ulcers (lips, tongue, oral cavity)
- Glossitis, angular stomatitis, cheilosis
- Bruising, clubbing
- Erythema nodosum, pyoderma gangrenosum
- Dermatitis (pellagra, crazy pavement dermatosis), edema feet, petechiae, ecchymosis, bone tenderness
- Dupuytren's contracture, pigmentation, parotid gland enlargement (Box 4.3, Fig. 4.9)

For examination of mouth, lips, tongue, oral mucosa, teeth, gums, palate and tonsils. See Chapter 3 page 69.

JAYPEE BROTHERS

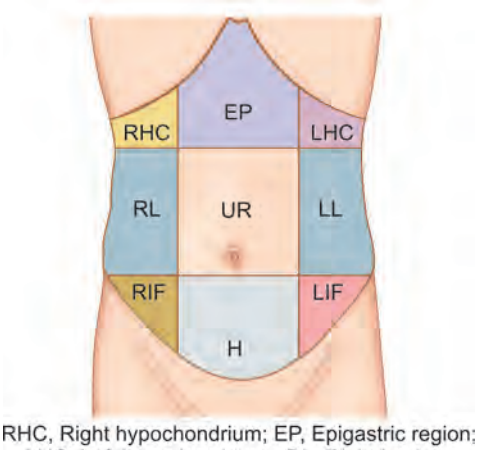

RHC, Right hypochondrium; EP, Epigastric region; LHC, Left hypochondrium ; RL, Right lumbar; LL, Left lumbar ; UR, Umblical region; RIF, Right iliac fossa; H, hypogastric; LIF, Left iliac fossa

Fig. 4.10: Regions of abdomen

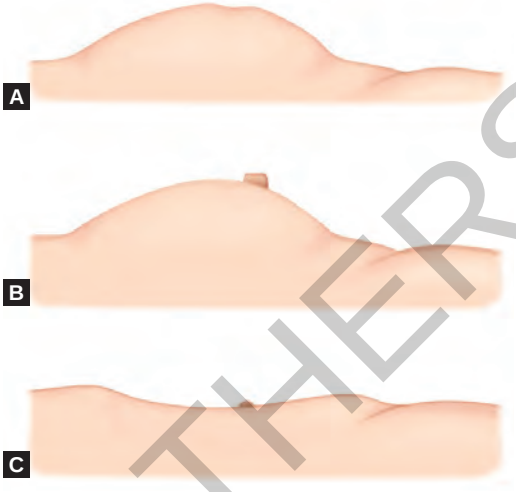

Fig. 4.11: Shapes of abdomen. (A) Obese abdomen, umbilicus sunken; (B) Distended abdomen, umbilicus everted (ascites); (C) Scaphoid abdomen

Examination of Abdomen

For descriptive and localization of abnormal findings, abdomen is divided into nine quadrants (Fig. 4.10).

Inspection of Abdomen

Ideally patient should undress and lie supine; cover the patient with a sheet; inspect from nipples to knee joints (for females, bra and under garments are permissible).

1. **Shape of abdomen** (Fig. 4.11)
   - Normal;
   - Obese (umbilicus sunken) ;
   - Distended: generalized (umbilicus everted), localized;
   - Scaphoid (thin, lean, emaciated)

   a. Generalized distension of abdomen—It occurs due to the following five Fs (fat, fluid, fetus, flatus and feces).
   - Fatty abdomen is protuberant anteriorly with sunken umbilicus (Fig. 4.11).
   - Fluid (ascites) collects more in flanks with horizontally slit umbilicus (smiling). Dull percussion note in flanks. The distance between xiphoid process and umbilicus is more than the distance between umbilicus and pubic symphysis (Fig. 4.12).
   - Fetus (pregnancy) and central swellings arising from pelvis (ovarian cyst) result in vertically

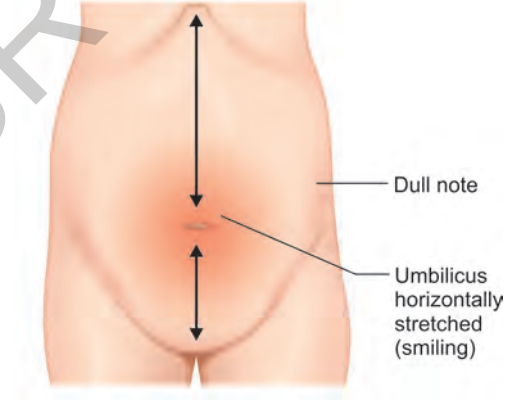

Fig. 4.12: Distance between xiphisternum and umbilicus is more than the distance between umbilicus and pubic symphysis

JAYPEE BROTHERS

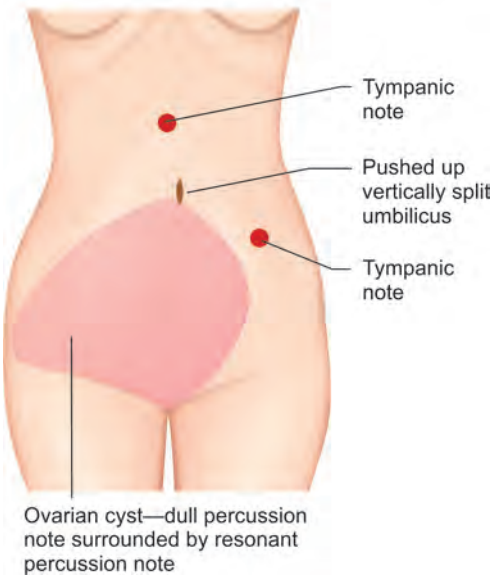

Fig. 4.13: Ovarian cyst

slit umbilicus with a tympanic note in the flanks. The distance between umbilicus and pubic symphysis is more than the distance between umbilicus and xiphoid process (Fig. 4.13).

- Flatus may produce distension that is central, localized in flanks or generalized, depending upon the site of intestinal obstruction. Percussion note is tympanic due to distended intestinal loops.
- Feces (impacted) in sigmoid colon cause distension with tympanic percussion note (distended colon).

b. Localized distension—Localized distension or swelling could be due to underlying visceral enlargement.

- Liver (right hypochondrium and epigastric regions)
- Spleen (left hypochondrium and umbilical regions)
- Kidneys, lumbar regions
- Ovaries (right or left iliac fossae)



Fig. 4.14: Edema of abdominal wall with white striae

- Distended urinary bladder (hypogastric region)
- Small bowel obstruction (umbilical region)
- Abdominal tumors (depends upon the organ from which tumor is arising).

Also note if the swelling moves freely with respiration (e.g. liver and spleen and tumors arising from stomach move freely with respiration, while tumors arising from posterior structures such as kidneys and lymph nodes move poorly).

2. Abdominal wall—Look for edema of the abdominal wall, divarication of recti (post-surgery and lax abdomen), metastatic nodules, white or pink striae (Fig. 4.14) (due to recent change in the size of abdomen, e.g. after delivery or removal of intra-abdominal tumor or ascitic fluid); linea nigra (seen in pregnancy as midline pigmentation of abdomen below umbilicus). Cushing's syndrome or patients on cortisone therapy may show bluish (purple) striae over the abdomen. Note scars of previous surgeries (large scars) and minimal access surgery (sites of port and a small scar).

3. Movements of abdomen

a. In healthy persons, abdomen bulges during inspiration and retracts during expiration.

JAYPEE BROTHERS

b. In paralysis of diaphragm, movements become paradoxical (bulges in expiration and sinks in inspiration).
c. In peritonitis, abdominal movements are limited or absent.

4. **Umbilicus**—Examine umbilicus whether it is inverted (normal) or everted (hernia). While coughing, if there is further evertion and bulge with expansile impulse on palpation, diagnosis of umbilical hernia is confirmed. Also note if umbilicus is transversely or vertically slit (Figs 4.12 and 4.13).
5. **Pulsations**—Notice if there are any visible pulsations in the epigastric region; the causes of epigastric pulsations are as follows:
   a. Abdominal aortic pulsations in thin and lean persons (normal finding)
   b. Expansile pulsations due to aneurysm of abdominal aorta
   c. A swelling (enlarged lymph nodes or carcinoma of stomach) situated anterior to aorta is felt as nonexpansile epigastric pulsations
   d. Right ventricular pulsations in epigastric region in tricuspid regurgitation
   e. Pulsatile liver in tricuspid regurgitation.
6. **Visible peristalsis** (see Fig. 4.15 for causes)
   a. Normal in thin persons
   b. Pyloric obstruction (slow wave moving across the abdomen from left hypochondrium to the right side)

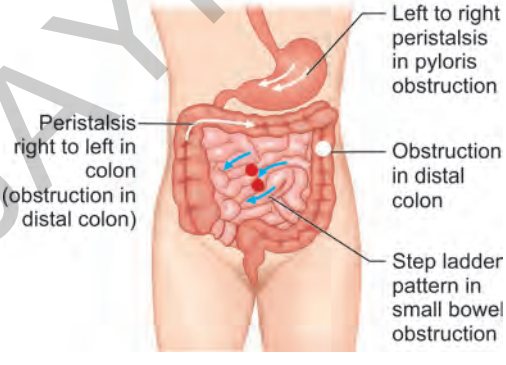

Fig. 4.15: Types and causes of visible peristalsis

   c. Small bowel obstruction (stepladder pattern)
   d. Large intestine obstruction (peristalsis from right to left in the upper abdomen) Peristalsis can be stimulated by gentle stroking, applying cold stimulus or in case of pyloric obstruction asking patient to drink water
7. **Distended veins**—(not just visible) are abnormal. They can be above or below umbilicus and in flanks. The flow of blood in distended veins is tested by emptying a section of vein (by milking it with fingers) and sealing each end of the vein with finger pressure. One finger is lifted and the filling noted. The maneuver is repeated by lifting the other finger while maintaining pressure with first finger.
   The rapidity of venous filling gives the direction of flow of blood (distended abdominal veins are shown in Figure 4.16).
   a. Inferior vena cava obstruction—Flow of blood is from below upwards both below and above the umbilicus. Prominent veins may be present in the back also. Abnormal veins become more prominent with patient standing.
   b. Superior vena cava obstruction—Flow of blood is from above downwards in veins both above and below umbilicus.
   c. Portal hypertension (intrahepatic obstruction, e.g. cirrhosis of liver)—Veins are distended around umbilicus (caput medusae) and the flow of blood is away from the umbilicus.
   d. Portal hypertension (extrahepatic portal vein obstruction)—Flow of blood is towards the umbilicus (rarely seen).
8. **Spider nevi**—These are centrally dilated arterioles with radiating capillaries; on pressure by pinhead, spiders blanch and fill up with release of pressure.
9. **Umbilical hernia**—Ask patient to cough or raise his head and shoulders without support to make it prominent.

JAYPEE BROTHERS

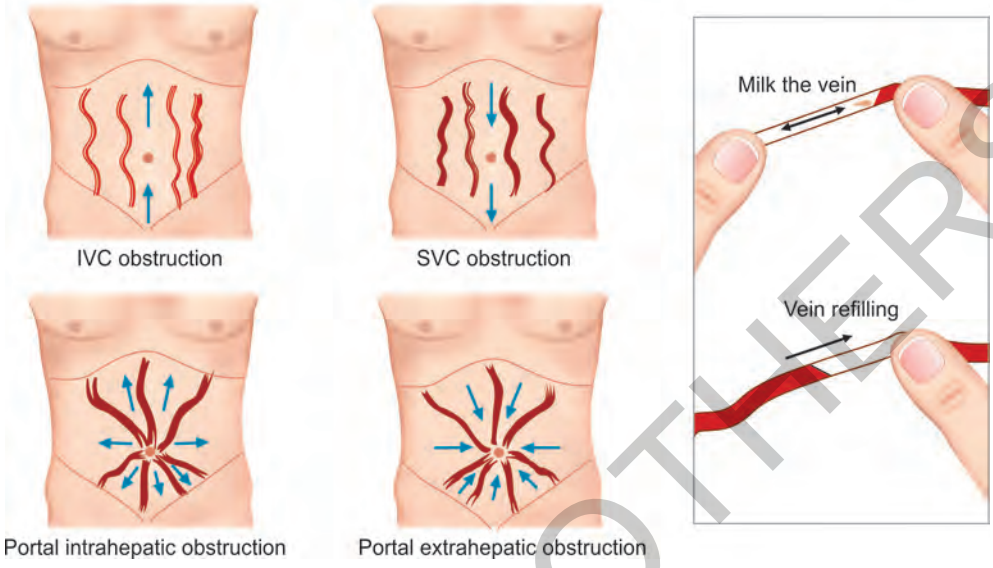

Fig. 4.16: Distended abdominal veins

10. **Divarication**—Divarication of the recti occurs in persons who have had raised intra-abdominal pressure as a result of gross ascites, gross obesity or repeated pregnancies.
    Abdominal contents protrude when patient raises his head and shoulders.
11. Inspect penis, scrotum for hydrocele, varicocele and undescended testes and look for cough impulse for inguinal and femoral hernias.

Palpation of Abdomen

Ask the patient to lie supine with knees bent or resting over pillow (to relax abdomen), and breathe quietly but a little more deeply than normal with open mouth.

1. **Superficial palpation**—Using the flat of hands (warm your hands in cold weather), start from a quadrant away from the site of perceived pathology. Each quadrant is palpated. Note localized tenderness, rigidity or guarding.
2. **Deep palpation**
   - **a.** Palpate more deeply and firmly with the flat of hands.
   - **b.** Use both hands putting the left hand over the right to exert increased pressure, especially in obese or muscular patients.
   - **c.** Divert patient's attention by talking to the patient.
   - **d.** Palpate each quadrant, starting away from the area of pain/tenderness.
   - **e.** Note tenderness, rebound tenderness and rigidity. Palpate for liver, spleen and kidneys (described below). If swelling is felt, ascertain its size, shape, location, consistency, tenderness and movements with breathing, mobility or adherence to adjoining structures.
3. **Dipping method (used in patients with ascites)**—Tap or dip with fingers to displace fluid and feel the organs (liver, spleen, kidneys).
   - **a. Guarding**
     - **i.** It is felt as muscle contraction.
     - **ii.** It is a reaction to underlying visceral inflammation (e.g. cholecystitis—right hypochondrium [RHC], appendicitis—right iliac fossa [RIF]).
     - **iii.** In peritonitis, there is diffuse board like rigidity.

JAYPEE BROTHERS

Box 4.4 Sites of tenderness, guarding in common abdominal diseases

- Gastric ulcer—Epigastrium in midline
- Duodenal ulcer—Epigastrium to right of midline
- Appendicitis—RIF, McBurney's point (junction of the middle and outer thirds of the line joining the umbilicus to the anterior superior iliac spine)
- Cholecystitis—Right hypochondric region
- Sigmoid diverticulitis—Left iliac fossa
- Pyelonephritis—Renal angle
- Perisplenitis—Left hypochondriac region

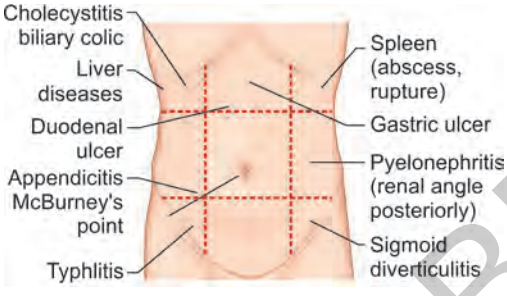

Fig. 4.17: Sites and causes of abdominal tenderness

iv. The diffuse/generalized guarding may be voluntary (nervous patient).
v. Localized guarding is more specific of underlying pathology.

b. **Tenderness**—Pain felt by the patient on palpation. Deep tenderness is generally due to inflammation or ulceration of underling viscera and the surrounding peritoneum (Box 4.4; Fig. 4.17).

c. **Rebound tenderness**—A sign of peritonitis. Rebound tenderness is elicited by exerting firm pressure over viscera, say when you press in left iliac fossa, and then suddenly release the pressure, and if it causes pain over RIF, the test is positive and is suggestive of appendicitis. Sudden release of pressure stimulates inflamed parietal peritoneum, causing pain in the region of inflammation.

4. **Rigidity**—An advanced stage of guarding felt over severely inflamed viscera. It occurs in peritonitis due to perforation of hollow viscus, pancreatitis, cholecystitis, appendicitis and ruptured ectopic gestation. In diffuse peritonitis, rigidity is present all over the abdomen.

Examination of Liver

Methods for Palpation of Liver

1. Place right hand well below and parallel to right costal margin and ask the patient to breathe deeply, and feel for the lower border of liver with radial border of index finger of right hand. Move the hand upwards until liver is felt or till right costal margin is reached.
2. Sit on the bed, insert tips of both hands gently below the right costal margin by keeping hands vertically over the abdomen to palpate the liver edge with the patient taking slow deep breaths.
3. Keeping both hands side by side with fingers fanned out and pointing towards right costal margin and epigastrium, use eight fingers as feelers to palpate the lower border of right and left lobes. Move fingers from lateral to medial side to outline the entire lower border. Start from lower abdomen and move upwards so as not to miss edge of grossly enlarged liver.
4. Hooking method is used particularly in obese persons. Hook fingers of both hands below right costal margin directing pressure upwards while patient is taking deep breaths, and palpate liver edge with finger pads.

Examine the surface of liver for nodularity. Measure liver enlargement from costal margin in right midclavicular plane for right lobe and below xiphoid process in the midline for left lobe. Normally, liver edge may be just palpable below the costal margin in deep inspiration.

JAYPEE BROTHERS

Practical Hints

- In infants, liver is normally palpable
- Liver is displaced down in emphysema and kyphoscoliosis (on percussion, upper border of liver dullness is displaced down)
- Riedel's lobe may simulate kidney or gallbladder (GB) swelling. It is more common in females
- Normal liver edge is soft. Firm or hard edge is abnormal
- Small nodules over liver surface (e.g. cirrhosis of liver) are not easy to appreciate, but large nodules (e.g. metastasis, cysts, hepatoma) can be felt.

Tenderness

Normal liver is painless. Causes of liver tenderness are shown in Box 4.5 .

Causes of Enlarged Liver (Hepatomegaly)

1. **Infections**
   - Bacterial (typhoid, tuberculosis, brucellosis)
   - Viral hepatitis (A, B, C, D, E viruses), infectious mononucleosis
   - Protozoal (amebic abscess, schistosomiasis, malaria, kala-azar)
   - Parasitic (hydatid cyst)
   - Spirochetal (Weil's disease, syphilis)
   - Fungal (actinomycosis).
2. **Congestive hepatomegaly**
   - CCF
   - Constrictive pericarditis
   - Pericarditis with effusion
   - Budd-Chiari syndrome.
3. **Cirrhosis (portal, biliary)** (see Table 4.1 for differential features of portal and biliary cirrhosis).
4. **Hematological**—Chronic myeloid leukemia, chronic hemolytic anemia, lymphoma (Hodgkin's, non-Hodgkin's), polycythemia vera, myelofibrosis and hemochromatosis.

Box 4.5 Causes of enlarged tender liver

- Congestive cardiac failure (CCF)
- Hepatitis (viral, alcoholic, amebic)
- Carcinoma of liver (primary, secondary)
- Amebic liver abscess
- Pyemic liver abscess
- Weil's disease

Table 4.1: Differential features of portal and biliary cirrhosis

Feature	*Portal cirrhosis*	*Biliary cirrhosis*
1. Prevalence	Common	Uncommon
2. Sex	Predominant in men	Predominant in women
3. Jaundice	Mild	Deep
4. Itching	Rare	Common
5. Ascites	Common	Rare
6. Hepatomegaly	Mild	Marked
7. Splenomegaly	Moderate to severe	Mild
8. Clubbing	Rare	Common
9. Serum cholesterol	Normal	High
10. Xanthomas	Absent	May be present
11. Alkaline phosphatase	Normal	High

5. **Infiltrative disorders**
   - Fatty liver
   - Amyloidosis
   - Gaucher's disease
   - Niemann–Pick's disease
   - Glycogen storage disease.
6. **Toxic**—Alcohol, arsenic.
7. **Tumors**—Primary (carcinoma, sarcoma), secondaries (carcinoma)
8. **Granulomatous disorders**—Tuberculosis, sarcoidosis.

Examination of Spleen

Normal spleen is not palpable. It has to be at least twice its normal size to be just palpable.

JAYPEE BROTHERS

for detailed information on medicine books, visit our website **www.jaypeebrothers.com,** for detailed information on medicine books, visit our website **www.jay**

Manual of
Clinical & Practical Medicine

About the book

This book is targeted for clinical and practical examination in medicine not only towards final MBBS but also for postgraduate examinations (MD, DNB, MRCP). Its key chapters are history taking and general examination, gastrointestinal system, cardiovascular system, respiratory system, nervous system, nephrology plus acid base disorders, endocrine and metabolic diseases including diabetes mellitus, hematology and oncology and musculoskeletal system. The basics of **Electrocardiography (PQRST)** are discussed in details followed by Quiz ECGs (25) and complexes ECGs with interpretation (20). These will help students to answer ECG spots. **Imaging** —It contains X-rays (chest, bones, joints, barium studies), important ultrasonography images, important CT scan and MRI **images, PET CT and modern medicine images (total 121).** These will enable students to answer spots on images. **Procedures and instruments**—The important procedures with instruments are discussed which are usually asked in practical examination as spots. **Diet**–in different diseases and caloric values of different preparations served are described. For **Table Viva Voce—300** questions with answers are discussed which will be of help to students to face any question during the table viva voce. The **chapter on Emergencies is of immense importance as usually emergencies are asked** and will also be of help for the students, again in table viva voce. Two new chapters on nutrition and infectious diseases have been added.

- This manual describes initially bedside clinical methods in each chapter followed by clinical cases in each chapter; total 285 cases (long, short and spot) which are invariably kept in the practical examination. These cases are described with illustrations followed by viva voce in each case.
- **In short, this book should be a key and core companion to the students (undergraduates, postgraduates) during practical examination and it should also be useful as a ready reckoner to the family physicians, even junior consultants.**
- **For practical examination, students need not read any other book as this book gives more than enough clinical and practical material for undergraduates and postgraduates to go successfully through the practical examination.**
- This manual is supplemented with **714 illustrations, 112 boxes and 73 tables.**

About the Authors



(Hon. Brigadier) GS Sainani, brilliant academic career, appointed as Professor and Head, Department of Medicine at a young age of 32 years. Undergraduate and postgraduate teaching experience of 60 years. He is a National Professor and he has delivered lectures in several Indian universities.

He has taught at 10 foreign universities mostly in USA, Australia and UK. He has taught MRCP students at Hammersmith Hospital and St Mary's Hospital, London.

He has been examiner for MBBS and MD at 18 Indian universities. He has also been an examiner for DNB medicine on several occasions.

He is recipient of 36 awards including 5 gifted teacher and master teacher awards, 2 Dr BC Roy and 7 lifetime achievement awards including 2 by the President of India. He has delivered 26 orations.

GS Sainani yearly oration is instituted by 3 national and 1 international association (WCCPCI).

He is recipient of 21 fellowships and has been conferred Hon. FRACP, Hon. FISC and Hon. D Lit. He has been invited as a guest speaker/chairman on 520 occasions. He has 559 publications, author of 3 medical books, editor-in-chief of 5 medical books including API Text Book of Medicine, editor of 8 National Journals including Journal of Applied Medicine (19 years) and JAPI (7 years).

He is now Emeritus Director, Department of Medicine in Jaslok Hospital, Emeritus Professor, Grant Medical College (GMC), Mumbai and National Academy of Medical Sciences (NAMS), New Delhi and Emeritus International Advisor, Royal College of Physicians (RCP), London.



Rajesh G Sainani, currently a practicing gastroenterologist with special interest in gastrointestinal physiology and motility disorders.

He has had a training in gastrointestinal physiology and motility disorders at University of Melbourne, Australia and after return from Melbourne, he has trained other gastroenterologists in motility disorders.

He has been invited to deliver talks on his expertise in motility disorders at several conferences, CMEs organized by different institutions in the country. He has 25 publications which have appeared in indexed journals, API Medicine Update books and Book on Medical Therapeutics published by Elsevier.

In addition,he has 20 abstracts of the papers presented at national conferences. He has been teaching DNB students. He is recipient of 3 awards.

Available at all medical bookstores or buy online at www.jaypeebrothers.com

JAYPEE BROTHERS
Medical Publishers (P) Ltd.
www.jaypeebrothers.com

Join us on facebook.com/JaypeeMedicalPublishers

Shelving Recommendation
MEDICINE

ISBN 978-93-5270-127-8