thers.com, for detailed information on orthopedics books, visit our website www.jaypeebrothers.com, for detailed information on orthopedics bo

ASIA PACIFIC ARTHROPLASTY SOCIETY

Celebrating 50 YEARS
Passion, Quality and Innovation in Healthcare Publishing

Comprehensive Guide in Knee & Hip Arthroplasty

Asia-Pacific Arthroplasty Society Delta Compendium

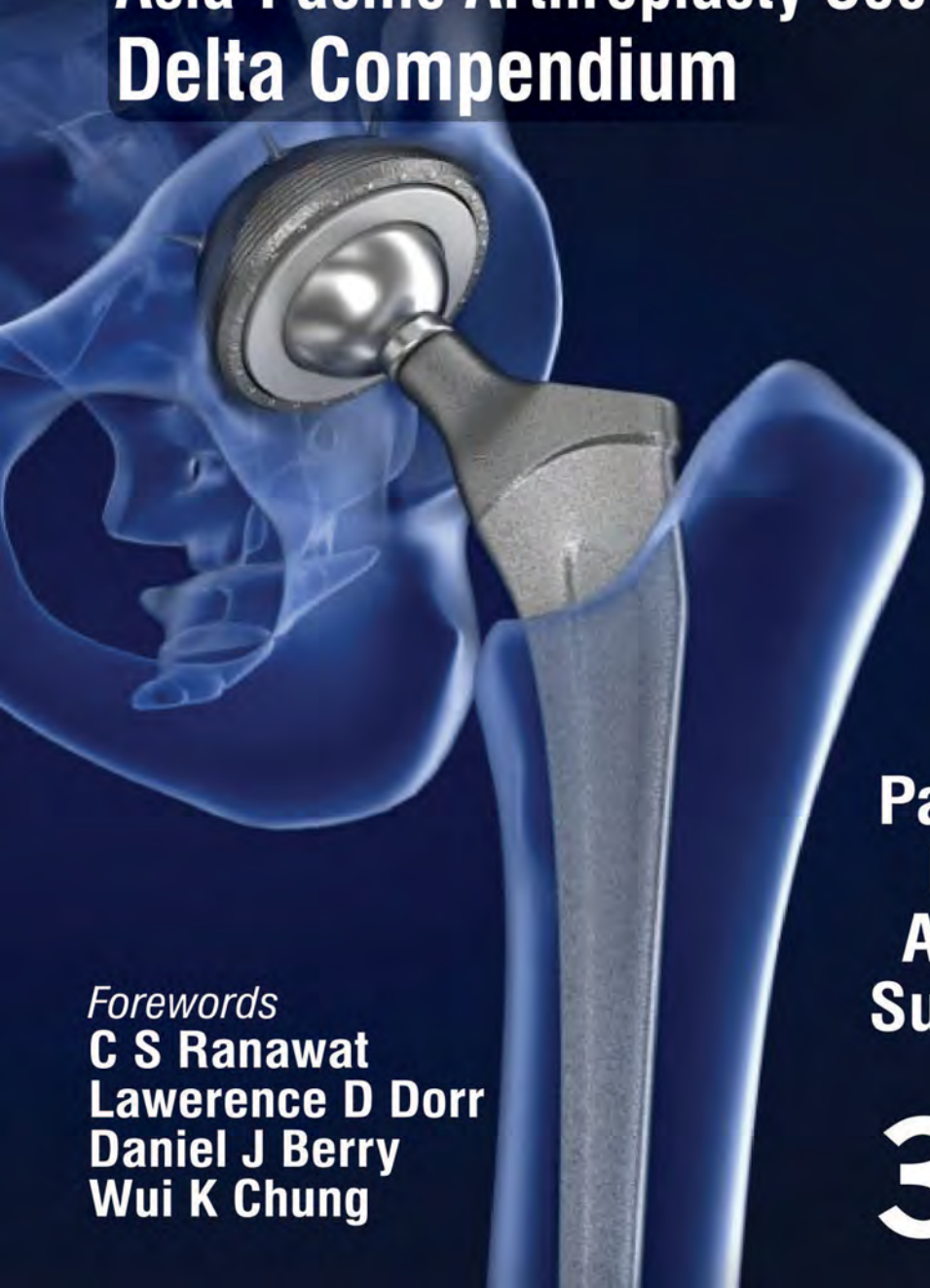



Parag Sancheti
Rami Sorial
Ashok Shyam
Sunny S Gugale

Forewords
C S Ranawat
Lawerence D Dorr
Daniel J Berry
Wui K Chung

3rd Edition

JAYPEE

Contents

Section 1: Science of Arthroplasty

1. **How to Establish a Successful Arthroplasty Practice** 3
   AV Gurava Reddy
2. **Critical Surgical Anatomy for Safe Total Knee Arthroplasty** 5
   Jonathan J Negus, Joshua Xu
3. **Surgical Anatomy for Total Hip Arthroplasty** 12
   Terence Moopanar, Rami Sorial
4. **Kinematics of Knee Arthroplasty** 19
   Kiran Kharat, Col Narinder Kumar
5. **Biomechanics of the Hip Joint** 26
   Mahesh Kulkarni, Snehal Hedgire
6. **Modern Cement Technology in Arthroplasty** 30
   Anoop Jhurani, Piyush Agarwal, Mukesh Aswal
7. **Bearing Surfaces for Total Hip Arthroplasty: Material and Design** 38
   Dhanasekara Raja P, Sumit Chawla, N Rajkumar, Rajasekaran Shanmuganthan
8. **Mechanical Failure of Hard-on-Hard Bearings in Arthroplasty and Preventive Measures** 46
   Sachin Tapasvi, Anshu Shekhar, Shantanu Patil
9. **Alternative Bearings in Total Hip Arthroplasty** 53
   Dhanasekara Raja P, Melvin George, N Rajkumar, Rajasekaran Shanmuganthan
10. **Essential Knowledge about Polyethylene** 63
    Parag Sancheti, Sunny S Gugale
11. **The Science of Ligament Balancing** 66
    Arun Mullaji, Gautam Shetty
12. **Scientific Basis for Unicompartmental Knee Replacement: Technical Implications** 69
    Wui K Chung
13. **Thromboprophylaxis in Total Joint Arthroplasty** 73
    Abhijit S Agashe
14. **Patellofemoral Kinematics in Total Knee Arthroplasty Design** 78
    Rajshekhar KT
15. **Understanding Mid-Flexion Instability in Total Knee Arthroplasty** 81
    Dhanasekara Raja P, Raja Bhaskara Rajasekaran, Rajasekaran Shanmuganthan

Section 2: Primary Knee Arthroplasty

16. **Surgical Approaches to the Knee** 87
    Ashok Rajgopal, Vivek Dahiya

17. **Concepts Underlining Balancing in Total Knee Arthroplasty** 91
SV Vaidya, Jitesh Manghwani

18. **Components Rotational Alignment in Total Knee Arthroplasty** 99
Neeraj Adkar, Vinil Shinde

19. **Posterior Cruciate Ligament in Total Knee Arthroplasty: Balancing the Controversy** 106
AV Gurava Reddy, Adarsh Annapareddy, Sukesh Rao Sankineani

20. **Algorithm for Dealing with Varus Deformity** 110
Arun Mullaji, Gautam Shetty

21. **Algorithm for Dealing with Fixed Flexion Deformity** 113
SKS Marya, Chandeep Singh

22. **Classification and Treatment Algorithm of a Valgus Knee** 117
Kailash Patil

23. **Total Knee Replacement in Valgus Knees: An Algorithmic Approach** 122
Mojieb Manzary, Rasha Al-Ansari

24. **Dealing with Severe Valgus Knee** 131
SKS Marya, Shitij Kacker

25. **Total Knee Arthroplasty after High Tibial Osteotomy** 137
Myung Chul Lee

26. **Total Knee Replacement in Complex Multiplanar and Segmental Knee Deformities** 144
Manuj Wadhwa, Ritesh Khokhar

27. **Rotating Mobile-bearing Total Knee Arthroplasty** 151
N Rajkumar, D Soundar Rajan

28. **High-flexion TKA: View through the Mist** 158
Agrawal Anuj

29. **Navigation in Total Knee Replacement** 166
Anoop Jhurani, Piyush Agarwal, Mukesh Aswal

30. **Extensor Mechanism Deficiency in Total Knee Arthroplasty** 179
Simon Coffey

31. **Patellofemoral Arthroplasty** 186
Simon Coffey

32. **Noncemented Primary Total Knee Arthroplasty** 191
Stavrakis AI, Ranawat AS

33. **Current Role of Patient-specific Instrumentation in Total Knee Arthroplasty** 196
Terence Moopanar, Rami Sorial

34. **UKA: The Mobile-bearing Option** 200
Rami Sorial, Sheraz Anjum

35. **Fixed-bearing Unicondylar Knee Arthroplasty** 212
Srihatach Ngarmukos, Aree Tanavalee

36. **Minimal Invasive Unicondylar Knee Arthroplasty** 220
Michael Neil, Amir Kalanie

37. **Multicompartment UKR and ACL Reconstruction** 226
Francesco Mancuso, Hemant Pandit

Section 3: Revision Total Knee Arthroplasty

38. Surgical Approaches for Revision Total Knee Arthroplasty **235**
Shekhar Agarwal, Anuj Jain

39. Evaluation of Painful Total Knee Arthroplasty **239**
Hemant Wakankar, Chaitanya Vyawahare

40. Management of Major Bone Defects in Revision TKR: Unility of Cones and Sleeves **246**
Wui K Chung

41. Dealing with Bone Loss in Total Knee Arthroplasty **255**
Manuj Wadhwa

42. Knee Balancing in Revision Total Knee Arthroplasty **260**
Rajesh Malhotra, Deepak Gautam

43. Rationale for Stem Extension Selection in Revision TKA **267**
Budhiparama NC, Hidayat H, Ifran NN

44. Management of the Disrupted Quadriceps Mechanism in Revision Total Knee Arthroplasty **276**
Raju Vaishya, Amit Kumar Agarwal, Abhishek Vaish, Vipul Vijay

Section 4: Primary Total Hip Arthroplasty

45. Surgical Approaches for the Hip Replacement **283**
KH Sancheti, Rajeev Joshi

46. Modern Cementing Techniques **290**
KH Sancheti, Rajeev Joshi, Mahavir Dugad

47. Restoration of Center of Rotation and Balance of THR **293**
Zachary C Lum, Lawrence D Dorr

48. Altered Hip Center in Total Hip Arthroplasty **300**
KH Sancheti, Rajeev Joshi, Mahavir Dugad

49. Cemented Total Hip Arthroplasty **312**
Suryanarayan P, Ashok Raju G, Kalaivanan Kanniyan

50. Cementless Stem: The Scientific Basis of Choice **323**
Hrushikesh Saraf

51. Tapered Cementless Stem in THR **331**
Petros J Boscainos, William A Hadden

52. S-ROM in Primary and Revision THA: Technical Details and Surgical Tips **336**
Michael Neil, Abhijit Kawalkar

53. Cups and Diametric Considerations in Primary Total Hip Arthroplasty **342**
Ashok Gavaskar, David Rojas Vintimilla

54. Total Hip Arthroplasty for Developmental Dysplasia of the Hip **349**
Yunqing Ma, Hong Zhang

55. Total Hip Arthroplasty in High Grade Developmental Dysplasia of Hip **355**
Li Cao, Wenbo Mu

56. Role of Dual Mobility Cup in Total Hip Arthroplasty **365**
Craig Waller

57. Surgical Management of Hip Dislocations following Total Hip Arthroplasty **371**
Vaibhav Bagaria, Kalyan Tadepalli

58. Minimally Invasive Surgery: Posterior Approach Variants **377**
Sol Qurashi

59. Bipolar Hip Arthroplasty **386**
Baldev Dudhani, Ashok Shyam

60. Total Hip Arthroplasty in Acetabular Fractures **397**
Kanniraj Marimuthu, PS Ashok Kumar, Vijay C Bose

Section 5: Revision Total Hip Arthroplasty

61. Principles of Revision Total Hip Arthroplasty **405**
Smit Shah, Rami Sorial

62. Pathomechanics and Radiology of Aseptic Loosening in Total Hip Arthroplasty **417**
Sanjeev Madan, Balakumar Balasubramanian

63. Acetabular Defects in Revision Arthroplasty and its Management **425**
Mahesh Kulkarni, M Mallesh

64. A Brief Overview: Current Trends in the Management of Major Acetabular Bone Loss **435**
Wui K Chung

65. Evaluation and Management of Femoral Bone Defects in Revision Total Hip Arthroplasty **441**
Michael Neil, Amir Kalanie

66. Femoral Side Revision Total Hip Replacement **447**
Wui K Chung

67. Management of the Infected Hip and Knee Arthroplasty: Evidence-Based **452**
Mohit Bhandari, Vickas Khanna, Anthony Adili, KO Oduwole

68. Management of Periprosthetic Fractures of the Hip **461**
Rami Sorial, Yasser Khatib

69. Extended Trochanteric Femoral Osteotomy: Technical Tips **469**
Simon Coffey

Section 6: Periprosthetic Infection

70. Strategies for Management of the Infected Joint **475**
Karan Goswami, Joshua Newman, Javad Parvizi

71. Diagnostic Tools for Developing Countries **484**
Alexander J Rondon, Javad Parvizi

72. Antibiosis: Pharmacokinetics, Antibiotic Selection for Prophylaxis and Therapy **492**
Kier Blevins, Javad Parvizi

73. Scientific Basis for Management of Periprosthetic Joint Infection: Role of Lavage and Debridement, Antiseptics, and Antibiotics **497**
Noam Shohat, Javad Parvizi

74. One- or Two-stage Septic Revision of Periprosthetic Joint Infection **501**
Christian Lausmann, Mustafa Citak, Thorsten Gehrke

75. My Approach to Periprosthetic Joint Infection **508**
Li Cao, Baochao Ji

76. Future Technologies for the Diagnosis of PJI **515**
Alexander J Shope, Karan Goswami, Javad Parvizi

Index *519*

3 Surgical Anatomy for Total Hip Arthroplasty

Terence Moopanar, Rami Sorial

HIP JOINT

- The hip joint is a ball and socket diarthrodial joint and stability is largely conferred by its bony architecture.
- *Primary ossification centers*: Ilium, ischium, and pubis (fuse 14–16).
- *Secondary ossification centers*: Iliac crest, the anterior inferior spine, the ischial tuberosity, the pubic symphysis, and the triradiate cartilage (fuse 20–22).
- Labrum and capsule give the joint further stability.

Acetabulum

- The acetabular surface is orientated approximately 45° in abduction (caudally) and 15° anteversion.
- Mostly circular contour in its superior margin, but it has only enough hemispherical depth to allow for 170° coverage of the femoral head.
- Surgically divided into four quadrants by a line drawn from anterior superior iliac spine (ASIS) through center of acetabulum (forming anterior and posterior quadrants) and a line perpendicularly (superior and inferior quadrants) (Fig. 1).
  - Posterior-superior is safest
    - Contains superior gluteal nerve and vessels and sciatic nerve
  - Posterior-inferior is second safest
    - Contains inferior gluteal nerve and internal pudendal vessels
  - Anterior-inferior is unsafe
    - Contain the obturator vessels
  - Anterior-superior is unsafe
    - Contains external iliac artery and vein unsafe for screws
- The anatomic and high hip center (HHC) quadrant systems can be used to locate the safe and dangerous zones for the transacetabular placement of screws, but they also can be used as a guide for retractor placement, for drilling acetabular anchoring holes for graft fixation, or to estimate bone depth in a specific acetabular zone.

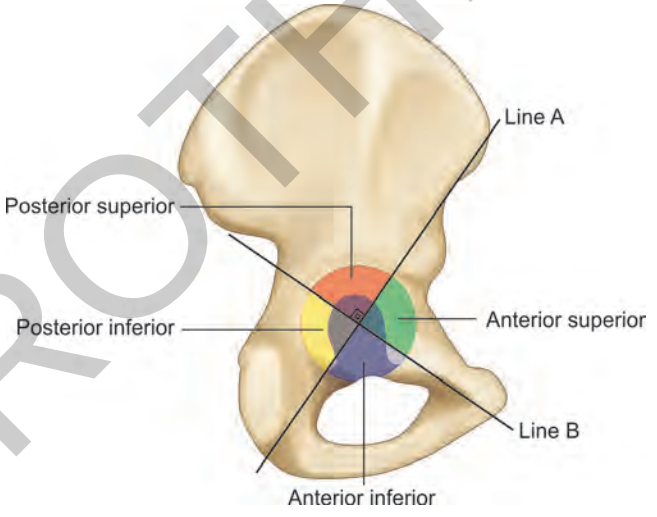

Fig. 1: Surgical quadrants system for safe placement of acetabular screws.
Source: Orthobullets Chris Battista.

Transverse Acetabular Ligament

Excessive retroversion is associated instability, anterior impingement, and groin pain.

- The transverse acetabular ligament which straddles the inferior limit of the cup defines the normal version for cup placement.
- This is particularly useful in difficult cases such as congenital hip dysplasia, where a dysmorphic acetabulum presents a challenge to correct cup placement.

Femoral Head

- The femoral head, which is covered within the acetabulum and augmented by labrum (and is

JAYPEE BROTHERS

continuous with the transverse acetabular ligament inferiorly), contains an important surgical point of pivot.
- This point is the center of the femoral head, which often coincides with the level of the tip of the greater trochanter.

Femoral Neck

- The femoral neck is anteverted at approximately 15° from the posterior condyles of the distal femur (from 30° at birth).
- The neck is approximately 135° to the shaft of the femur in childhood and becomes less valgus as an adult (125°).

Femur

Anteriorly bowed (1.2 m) in its midportion. The extent of bowing is clinically relevant because if excessive it may not be possible to utilize long straight implants without considerable undersizing.

IMPORTANT SURGICAL LANDMARKS

- The transverse acetabular ligament helps guide acetabular component version and signifies the inferior border of the cup.
- The base of the fovea signifies the cotyloid fossa, which is a guide to the extent of medially reaming.

Medialization of Acetabulum

- The U-shaped acetabular portion usually protrudes above the true floor by a few millimeters and this corresponds to the lateral portion of the teardrop on an anteroposterior (AP) pelvis X-ray.
- Reaming away the U-shaped portion of the acetabulum converts the acetabulum into the desired hemisphere.
- Usually in osteoarthritic patients, the acetabulum is encumbered with osteophytes that push the femoral head laterally, posteriorly, and superiorly. The hip center therefore needs to be re-established in the opposite direction (inferiorly, medially, and anteriorly).
- Inflammatory disease may lead to protrusio (medial and superior migration) and care therefore needs to be taken when establishing the hip center.

SURGICAL APPROACHES (FIG. 2)

- *Anterior (Smith-Peterson) approach*: Between sartorius and tensor fasciae latae superficially and rectus femoris and gluteus medius deep.

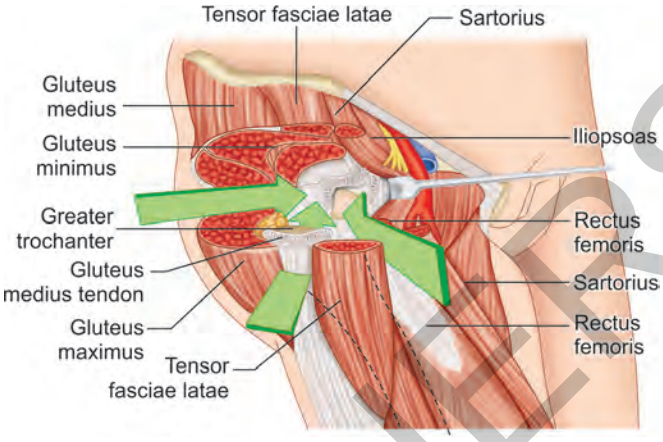

Fig. 2: Surgical approaches to hip joint.
Source: Hoppenfeld S, DeBoer P, Buckley R. Philadelphia: Lippincott Williams and Wilkins 2009. Surgical Exposures in Orthopaedics: The Anatomic Approach.

- *Anterolateral (Watson-Jones) approach*: Plane of dissection is between tensor fasciae latae and gluteus medius.
- *Lateral (Hardinge) approach*: No internervous plane as it splits gluteus medius and vastus lateralis.
- *Posterior (Moore of Southern) approach*: Split gluteus maximus and takes down external rotators to access hip joint.

FEMUR HEAD NECK TROCHANTER DISTANCE (OFFSET)

- Offset is defined as the perpendicular distance between the center of the femoral and the long axis of the femur.
- It varies independently of the neck-shaft angle (although patients with increased valgus tend to have less offset, whereas patients with increased varus have more offset).
- If the variant is pathologic it is necessary to re-establish normal hip joint kinematics and abductor function.

Femoral Geometry

- Proximal femoral geometry varies with age due to overall bone loss.
- Endosteal expansion of the isthmus results in the proximal femur losing its "501" configuration and becoming "stovepipe" in shape.
- This may result in intraoperative fracture when broaching the canal if care is not taken (Fig. 3).

Dorr Classification

- Dorr et al. have developed an index that characterizes the calcar-to-canal ratio.

JAYPEE BROTHERS

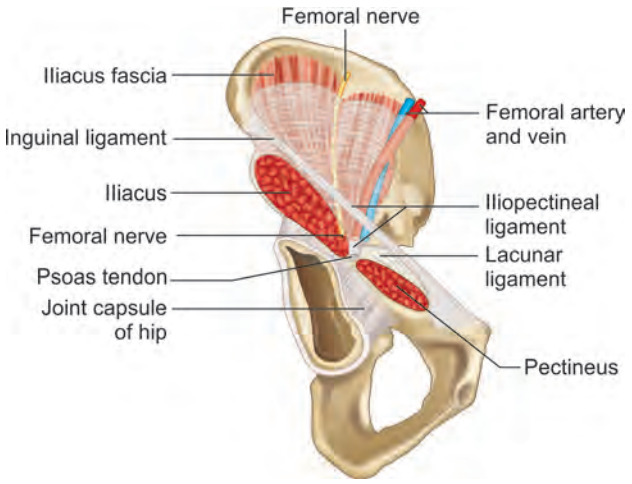

Fig. 3: Capsular acetabular attachment and associated anatomy.
Source: Delta Course Compendium (3rd edition).

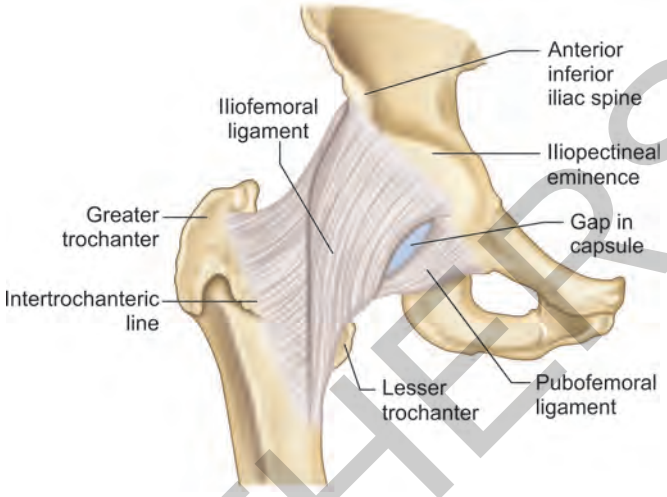

Fig. 4: Anterior ligaments of the hip.
Source: Delta Course Compendium (3rd edition).

- The index is a ratio of the canal diameter at the level of the lesser trochanter to the canal diameter at a point 10 cm distal.
- As the canal calcar isthmus ratio (the Dorr index) approaches 1, the prosthesis fills proximally but is distally compromised. A cemented prosthesis is therefore suggested in such cases.

Articular Capsule

- The capsule is attached along the anterior and posterior periphery of the acetabulum just outside the acetabular labrum.
- Making anterior and posterior incisions between the capsule and labrum allow retractors to be placed safely over the anterior and posterior columns.
- Inferiorly the capsule is attached to the transverse acetabular ligament.
- Anteriorly it attaches to the femur along the intertrochanteric line.
- Posteriorly it has an arched free border that results in only partial covering of the femoral neck.

Iliofemoral Ligament (Y-ligament and Ligament of Bigelow)

- This is the strongest ligament in the human body (350 kg tensile strength). The fibers become taut in extension thereby providing stability allowing muscular relaxation.
- The superior portion may resist excessive external rotation.
- When this ligament is contracted a flexion/internal rotation contracture may result, requiring release at total hip arthroplasty (THA).
- It is particularly important to correct this internal rotation contracture if a posterior approach to the hip is done (otherwise a tendency toward hip internal rotation will result) (Fig. 4).

Pubofemoral Ligament

- This is applied to the inferior and medial parts of the anterior capsule.
- The fibers of the pubofemoral ligament become taut in hip extension and abduction.
- In trying to correct a hip adduction contracture at arthroplasty, these fibers may need to be released to provide for adequate hip abduction.

Ischiofemoral

- The ligament reinforces the posterior surface of the capsule.
- Its fibers spiral laterally and upwards so it tightens during extension, but loosens or unwinds during hip flexion.
- Other fibers traverse horizontally and attach to the inner surface of the greater trochanter, providing a check to internal hip rotation (Fig. 5).

HIP LIGAMENTS

- The zona orbicularis lies like a collar around the narrowest part of the femoral neck and is covered by the other ligaments which partly radiate into it.
- The twisted orientation of the capsular ligaments surrounding the hip joint provides stability in full extension when these ligaments are in a tight closed packed position.

JAYPEE BROTHERS

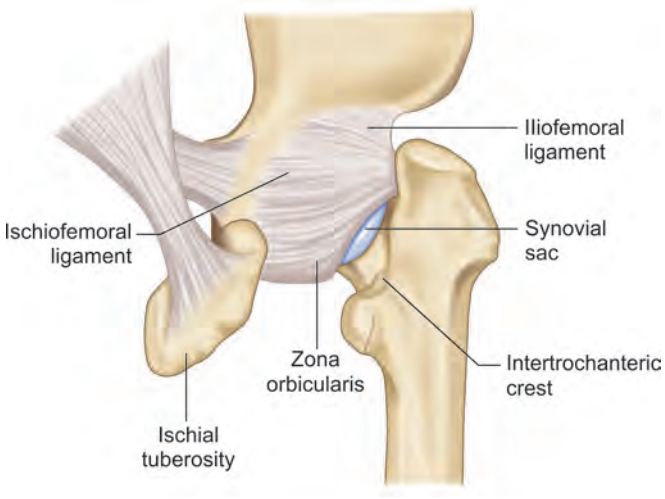

Fig. 5: Posterior ligaments of the hip.
Source: Delta Course Compendium (3rd edition).

Hip Joint Optimal Contact

- The position of optimal articular contact (flexion, abduction, and external rotation) is the "loose-packed position", because flexion and lateral rotation tend to uncoil the hip ligaments.
- This forms the basis of reducing intracapsular femoral neck fractures using the Leadbetter maneuver—whereby the loose packed position is used to acquire anatomical reduction prior to final extension which maintains reduction.

Muscles of the Hip

- 17 muscles of the hip are divided into four groups that operate as part of a closed kinematic chain-link system. These are the gluteal group, the adductor group, the iliopsoas group, and the lateral rotator group. Other muscles can move the hip joint, but primarily move the knee (rectus femoris and sartorius).
- The range of motion accommodated at the hip is:
  - Flexion (120°) (Rectus femoris, sartorius, and iliopsoas)
  - Extension (30°) (Gluteus maximus and hamstrings)
  - Abduction (45°–50°) (Gluteus medius and gluteus minimus)
  - Adduction (20°–30°) (Adductors longus, brevis, magnus, pectineus, and gracilis)
  - Internal rotation (35°) (Anterior fibers of the gluteus medius and minimus and the tensor fascia latae muscles)
  - External rotation (45°) (Obturator internus and externus, the superior and inferior gemellus, and quadratus femoris and piriformis)
- Normal gait on level ground requires at least the following hip joint ranges of motion:
  - 30° flexion
  - 10° hyperextension
  - 5° of both abduction and adduction
  - 5° of both internal and external rotation.

VESSELS

- The common femoral artery (second largest compared to the aorta) courses directly anterior and medial to the hip capsule, from which it is separated by the iliopsoas tendon.
- The common femoral vein accompanies the artery in the femoral sheath and becomes the external iliac vein as it passes under the inguinal ligament. It receives contributions from the profundus femoris and greater saphenous vessels.
- The artery is lateral to the vein at the level of the inferomedial capsule and is more susceptible to injury.
- The common femoral vessels have been the most commonly reported extrapelvic vascular structures injured in association with THA.
- This can occur during the anterior lateral approach when a retractor is placed too far medially over the anterior inferior acetabular margin.
- Bulk allograft placement for acetabular reconstruction, osteophyte resection, and resection of scar tissue from the anterior inferior acetabulum has also resulted in femoral artery injury.
- During cemented acetabular component fixation, extrusion of excess cement anteromedially has resulted in pseudoaneurysm formation, thrombus formation, and peripheral femoral arterial embolization, which is life-threatening.
- Intimal damage from the heat of polymerization is thought to be the likely cause.
- Prolonged cement spicule pressure has resulted in postoperative vessel erosion and pseudoaneurysm formation and the formation of an arteriovenous fistula.
- These injuries can be avoided by placing an abdominal/lap pad in this region during cementing or by removing the anterior extra-acetabular cement before polymerization.
- The profundus (deep) femoris artery has been injured, although rarely, during THA.

JAYPEE BROTHERS

- Retractor placement too far medially over the anterior inferior quadrant can result in a false aneurysm of the medial circumflex artery.
- Extruded cement in this region may also cause injury to the medial circumflex vessel.
- When this vessel is encountered at the superior border of the quadratus femoris muscle it seldom causes significant hemorrhage unless injured closer to its origin.
- Hohmann retractor placement over the anterior hip capsule and gluteus medius has resulted in severe arterial hemorrhage from profunda femoral and lateral circumflex artery laceration.
- Osteotome use during the removal of scar and capsule during revision surgery has also resulted in injury to the lateral circumflex artery.
- The superior gluteal vessels branch off the posterior division of the internal iliac artery usually passing between the lumbosacral trunk and the first sacral nerve.
- The gluteal nerve travels with the artery and vein.
- These structures are closest to the posterior column as they exit through the superior aspect of the sciatic notch.
- They are relatively fixed as they pass out of the pelvis above the piriformis muscle.
- Laceration of the superior gluteal artery has occurred with a fixation screw in the area of the sciatic notch.
- Injury has also occurred when a pin retractor was inserted in the direction of the notch.
- The superior gluteal vessels are as close as 2 mm from bone at this point.
- To minimize the risk to the superior gluteal vessels during transacetabular screw placement, the notch should be gently palpated to avoid instrument protrusion into this region.
- The inferior gluteal and internal pudendal vessels are the terminal branches of the anterior division of the internal iliac artery.
- They are closest to the posterior column at the level of the ischial spine.
- The internal pudendal vessel is closer to the posterior column as it curves around the ischial spine to re-enter the pelvis through the lesser sciatic notch.
- The gluteal vessels pass under the piriformis in the lower part of the greater sciatic foramen.
- Injury to these vessels can occur if excessively long transacetabular screws are used for acetabular component fixation.
- These screws would need to exit the posterior column by at least 5 mm because these structures are located at least this distance from bone.

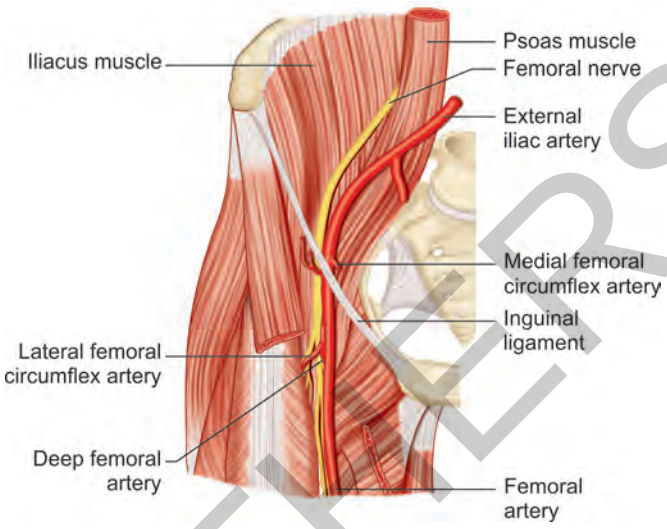

Fig. 6: Course of the femoral artery and associated branches.
Source: Delta Course Compendium (3rd edition).

- Reported injury to the external iliac vein is uncommon compared to external iliac artery injury.
- During the surgical approach the vessels lie within the pelvis, but they can be injured during acetabular exposure by retractors placed too far medially over the anterior column.
- Injury can also occur during preparation for placement of a cemented acetabular component from excessive medial reaming, excess extra-articular cement, or cement extrusion into the pelvis through an aberrant anchoring hole (Fig. 6).

SCIATIC NERVE (L4 TO S3)

- The sciatic nerve is formed from segments of the sacral plexus that unite anteriorly and medially to the piriformis muscle just proximal to its exit from the pelvis through the greater sciatic notch. The nerve exits below the piriformis muscle passing over the posterior lateral surface of the posterior acetabular column.
- It then descends between the greater trochanter of the femur and the ischial tuberosity, crossing over the obturator internus, gemelli, and quadratus femoris muscles (Fig. 7).
- The course of the common peroneal nerve descends more obliquely than that of the tibial nerve, leaving the fibers of the common peroneal nerve more superficial and more susceptible to injury.
- Sciatic and peroneal nerve palsies are the most common forms of peripheral nerve injuries following THA with reported incidences ranging from 0.5% to 2.0%.

JAYPEE BROTHERS

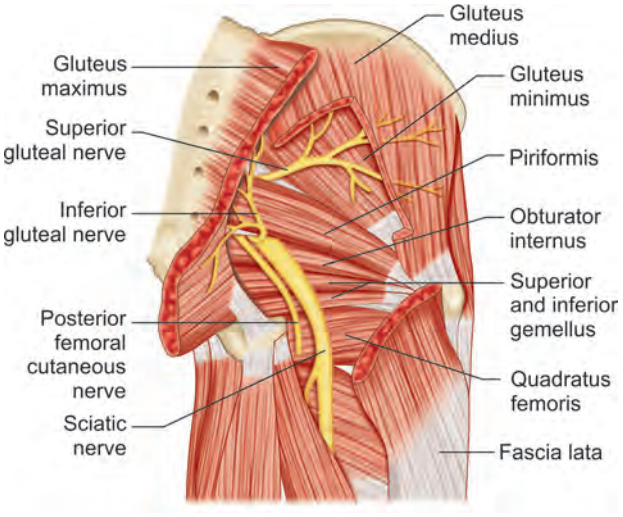

Fig. 7: The course of the sciatic nerve at the hip.
Source: Delta Course Compendium (3rd edition).

- The anatomic course of the sciatic nerve creates a vulnerability to injury by posterior acetabular retractors and power reamers during reconstructive surgery of the hip.
- Localization and extent of the nerve lesion i.e. determining nerve continuity, lesion severity, or fascicular lesion distribution are essential for assessing the potential of spontaneous recovery and thereby avoiding inappropriate therapy/treatment. Adequate therapy is in most cases is conservative management, but in certain cases early surgical exploration and release of the nerve is indicated. Nerve conduction studies and electromyography are essential in the diagnosis of nerve injuries.
- More recently, magnetic resonance imaging (MRI) neurography using pulse sequences that are insensitive to susceptibility artefacts were able to accurately localize fascicular lesions in the presence of total hip replacements.

FEMORAL NERVE (L2–L4)

- Femoral nerve palsy is uncommon, but an acknowledged complication of total hip replacement surgery (approximately 1% of nerve injuries).
- Risk factors include hip dysplasia, revision surgery, and female patients. In most cases, the cause of nerve injuries is unknown but is thought to be due to aberrant retractor placement.
- The femoral triangle lies directly anterior and medial to the hip joint, and within this space the femoral nerve is vulnerable to injury.
- Other postulated causes include cement extravasation, lengthening or stretch, hematoma, and pseudoaneurysm formation.
- Direct neural injury caused by retractors appears to have the best prognosis for recovery. Prognosis is related to the degree of nerve damage and femoral nerve recovery generally runs a more predictable course than the sciatic nerve.

OBTURATOR NERVE

- Obturator nerve injury is a rare complication of total hip replacement surgery that usually presents with medial groin pain.
- Persistent groin pain after THA, evidence of cement extrusion on pelvic radiographs, clinical exam of obturator muscle strength, and positive electromyogram (EMG) findings are needed to confirm this diagnosis.
- Most reports of obturator neuropathy have been secondary to intrapelvic violation by drills and/or cement.
- Wire mesh used to protect the intrapelvic structures from cement penetration has been noted to be inadequate. Bone grafting of all suspected defects is indicated.
- Extruded cement (which is reportedly the most common cause of nerve pathology) should be surgically removed and preservation of the nerve should be attempted.
- In cases where the nerve is nonfunctional or grossly abnormal, an obturator neurectomy should be considered.

BIBLIOGRAPHY

1. Alecci V, Valente M, Crucil M, et al. Comparison of primary total hip replacements performed with a direct anterior versus the standard lateral approach: perioperative findings. J Orthop Traumatol. 2011;12:123-9.
2. Barber TC, Roger D, Goodman S, et al. Early outcome of total hip arthroplasty using the direct lateral vs the posterior surgical approach. Orthopedics. 1996;19: 873-5.
3. Bhargava T, Goytia R, Jones L, et al. Lateral femoral cutaneous nerve impairment after direct anterior approach for total hip arthroplasty. Orthopedics. 2010;33(7):472.
4. Burnett R. Total hip arthroplasty: techniques and results. BCMJ. 2010;52:455-64.
5. Charnley J. Arthroplasty of the hip. A new operation. Lancet. 1961;1:1129-32.

JAYPEE BROTHERS

6. Chechik O, Khashan M, Lador R, et al. Surgical approach and prosthesis fixation in hip arthroplasty worldwide. Arch Orthop Trauma Surg. 2013;133:1595-600.
7. Farrell CM, Springer B, Haidukewych G, et al. Motor nerve palsy following primary total hip arthroplasty. J Bone Joint Surg Am. 2005;87:2619-25.
8. Hardinge K. The direct lateral approach to the hip. J Bone Joint Surg Br. 1982;64:17-9.
9. Hoppenfeld S, DeBoer P, Buckley R. Surgical exposures in orthopaedics: the anatomic approach. Philadelphia, PA: Lippincott Williams and Wilkins; 2009.
10. Kennon RE, Keggi J, Wetmore R, et al. Total hip arthroplasty through a minimally invasive anterior surgical approach. J Bone Joint Surg Am. 2003;85-A:39-48.
11. Lachiewicz PF. Abductor tendon tears of the hip: evaluation and management. J Am Acad Orthop Surg. 2011;19: 385-91.
12. Learmonth ID, Young C, Rorabeck C. The operation of the century: total hip replacement. Lancet. 2007;370: 1508-19.
13. Light TR, Keggi K. Anterior approach to hip arthroplasty. Clin Orthop Relat Res. 1980;152:255-60.
14. Masonis JL, Bourne R. Surgical approach, abductor function, and total hip arthroplasty dislocation. Clin Orthop Relat Res. 2002;405:46-53.
15. Masterson EL, Masri B, Duncan C. Surgical approaches in revision hip replacement. J Am Acad Orthop Surg. 1998;6:84-92.
16. Nakata K, Nishikawa M, Yamamoto K, et al. A clinical comparative study of the direct anterior with mini-posterior approach: two consecutive series. J Arthroplasty. 2009;24:698-704.
17. Pellicci PM, Potter H, Foo L, et al. MRI shows biologic restoration of posterior soft tissue repairs after THA. Clin Orthop Relat Res. 2009;467:940-5.
18. Schmalzried TP, Amstutz H, Dorey F. Nerve palsy associated with total hip replacement: risk factors and prognosis. J Bone Joint Surg Am. 1991;73:1074-80.
19. Schmalzried TP, Noordin S, Amstutz H. Update on nerve palsy associated with total hip replacement. Clin Orthop Relat Res. 1997;344:188-206.
20. Sierra RJ, Raposo J, Trousdale R, et al. Dislocation of primary THA done through a posterolateral approach in the elderly. Clin Orthop Relat Res. 2005;441:262-7.

JAYPEE BROTHERS

for detailed information on orthopedics books, visit our website www.jaypeebrothers.com, for detailed information on orthopedics books, visit ou

Comprehensive Guide in Knee & Hip Arthroplasty

Asia-Pacific Arthroplasty Society—Delta Compendium

Salient Features

- Aims to combine the rational approach to patient care and the sharing of expert knowledge and surgical techniques
- It is the amalgamation of authors from various regions of the globe and this provides a combination of varied views to create a document that can provide excellent advice to novice as well as senior surgeons
- Divides into six sections—the first section on Science of Arthroplasty introduces the essential basics and core concepts of arthroplasty along with concepts needed for pre- and perioperative management of all arthroplasty patients. Second section covers the surgical procedures as well as management algorithms for simple including complex primaries including severe deformities. Third section covers all the recent advances as well as technical guide to complex situations in revision total knee arthroplasty (TKA). The next two sections focus on primary total hip replacement (THR) and revision THR and provide an excellent overview of every aspect of these surgeries. Sixth section is focused on prosthetic joint replacement and is contributed by the group who are world renowned for their work in the area
- It is written in a fluid format with abundant use of images and pictures
- Covers the basics and the complex areas of arthroplasty along with recent advances.

Parag Sancheti FRCS (Ed) MS (Ortho) DNB (Ortho) MCh (UK) completed his MS (Ortho) (1992) from BJ Medical College, Pune, Maharashtra, India. He is the Professor and Chairman, Sancheti Institute for Orthopaedics and Rehabilitation, Pune. A holder of many esteemed fellowships including AO fellowship (Switzerland) and the Ranawat fellowship for joint replacement surgery. He is awarded the MCh (Ortho) degree in United Kingdom (UK). He is a visiting faculty for the Dundee University, UK and is an examiner for MS (Ortho) and DNB examinations. An Avid Orator, he has presented copious papers in national and international conferences. With many publications on his name, he is authored various chapters related to the specialist fields in orthopedic surgery. A winner of many prestigious awards including the Award of Excellence by the Governor of Maharashtra, he is an inspiration for many.

Rami Sorial FRACS FAOrthA is a Consultant Orthopedic Surgeon and Head, Department of Orthopedics, Nepean Hospital, Sydney, Australia since 1997. He has been awarded the prestigious FRACS, FAOrthA (1993) by the Royal Australasian College of Surgeons. He is also an adjunct Associate Professor, Nepean Clinical School, University of Sydney and Orthopedic Examiner, Court of Examiners, the Royal Australasian College of Surgeons. He has been an awardee of many fellowships in Phoenix, Boston and London. He has lectured extensively both nationally and internationally and has participated in demonstration of surgeries to advance and share surgical skills particularly within the Asia Pacific region. He is awarded as the Visiting Professor, Sichuan University, West China Hospital, Chengdu, China.

Ashok Shyam MS (Ortho) is an Orthopedic Surgeon and working as a Consultant, Sancheti Institute for Orthopaedics and Rehabilitation, Pune, Maharashtra, India. He is also the Chief Researcher and Head of the Indian Orthopaedics Research Group and Co-founder of the Indian Orthopaedic Research Society. He has 74 scientific articles published in National and International Journals along with 12 book chapters and is the Editor-in-Chief of the Journal of Orthopaedic Complications and Journal of Orthopaedic Case Reports.

Sunny S Gugale DNB (Ortho) is a Consultant Arthroplasty and Arthroscopy Surgeon, Department of Arthroplasty and Sports Medicine, Sancheti Institute for Orthopaedics and Rehabilitation, Pune, Maharashtra, India for 10 years. He has been trained in the field of Arthroplasty, nationally and internationally. He has contributed to two book chapters and has many scientific articles published in his name.

Available at all medical bookstores or buy online at www.jaypeebrothers.com



JAYPEE BROTHERS Medical Publishers (P) Ltd.

www.jaypeebrothers.com

Join us on facebook.com/JaypeeMedicalPublishers

Shelving Recommendation

ORHTOPEDICS

