nformation on PGMEE books, visit our website www.jaypeebrothers.com, for detailed information on PGMEE books, visit our website www.jaypeebrothers.com

JAYPEE

Bestselling book on the subject

Thoroughly revised & updated edition including Subjectwise Synopsis & Latest Exam Pattern Questions

New ACROSS

A Complete Review of Short Subjects

A Unique book for NEET, DNB, AIIMS, PGI, FMGE and State-level examinations

Psychiatry
Radiology

Radiodiagnosis/Radiotherapy/ Nuclear Medicine

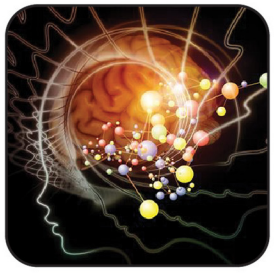



Volume 3

9th Edition

Saumya Shukla • Anurag Shukla

- **Thoroughly revised and updated edition with a new layout and two new sub specialities added (Radiotherapy & Nuclear Medicine).**
- **Concise, up-to-date and accurate.**
- **Written in simple language with precise explanation.**
- **Systematic presentation of the text.**
- **Book covers all questions from 2001 onwards**
- **All MCQs of All India (NBE Pattern), AIIMS, PGI, DNB, and State-based MCQs up to 2016 have been included**

A must-buy book for All India, AIIMS, PGI, JIPMER, DNB and State Entrance Exams

Contents

Psychiatry

1. Signs and Symptoms in Psychiatry 3
2. Psychoanalysis, Ego and Defense Mechanism. 13
3. Cognitive Disorders (Delirium, Dementia and Amnestic Syndromes) 22
4. Substance Related Disorders 33
5. Schizophrenia 41
6. Other Psychotic Disorders/Delusional Disorder 51
7. Mood Disorders 55
8. Anxiety, Grief, Adjustment, Sexual, General Identity and Impulse Control Disorders 66
   - 8.1 Anxiety Disorders 66
   - 8.2 Grief 74
   - 8.3 Adjustment Disorder 75
   - 8.4 Sexual Disorders 76
   - 8.5 General Identity Disorder 77
   - 8.6 Impulse Control Disorders (Oniomania/Pyromania) 78
9. Somatoform Disorder 79
10. Eating Disorders 86
11. Normal Sleep and Sleep Disorders 87
12. Personality Disorder 90
13. Paediatric Psychiatry 93
14. Drugs and Side Effects 99
15. Electroconvulsive Therapy 107
16. Review Notes 109

Radiology

Radiodiagnosis

1. Physics and Techniques 213
2. Diagnostic Features and Specific Signs 226
3. Investigation of Choice 244
4. Systemic Radiodiagnosis I: Neurology and Nephrology 258
5. Systemic Radiodiagnosis II: Others 281
6. Review Notes 331

Radiotherapy 389

Review Notes 415

Nuclear Medicine 435

Review Notes 445

1

PHYSICS AND TECHNIQUES

Contrast Agents

Intravascular Radiological Iodinated Contrast Media

- All are tri-iodo benzene ring derivatives with *3 atoms of iodine* at 2, 4, 6 position (*in monomers) & 6 atoms of I_2 per molecule of ring anion (in dimers). They have low lipid solubility, low toxicity, low binding affinitie for protein, receptors or membranes, low molecular wt (<2000) and are very hydrophilic*. On iv injection, b/o high capillary permeability, all are distributed rapidly into **extravascular**, ***extracellular space (except in CNS)***Q. They *do not enter the interior of blood cells or tissue cells* and are rapidly excreted (>90% by GFR within 12 hrs). They are *used purely as imaging and not therapeutic agents (no pharmacological actions*)
- All *ionic agents* are salts of *sodium or meglumine (N-methyl glucomine)* and dissociate in water in *2 ions (osmotic particles)* per molecule whereas, *non-ionic agents* do not ionize or dissociate. All *monomers* contain *1* and *dimers contain 2* tri-iodinated radio opaque anion benzene ring (*i.e. 3 & 6 I_2 atoms* per molecule) respectively. *Ionic monomers are high osmolar contrast media (HOCM)* with a 3:2 iodine per particle ration; whereas nonionic monomer, ionic dimer (both 3:1 ratio) and nonionic dimer (6:1 I_2 per particle ratio; physiologically isotonic) are **low osmolar contrast media (LOCM)**.
- **High osmolar contrast agents (HOCM)** are all ***ionic monomers***Q; whereas **low osmolar contrast agents (LOCM)** ***may be ionic dimers, and nonionic monomers or dimers (i.e. both ionic & nonionic)***Q. HOCM have osmolality in range of **1500** mosmols/kg water at concentrations of 300 mg I_2/ml. Whereas LOCM have osmolality which is *less than half of the osmolality of HOCM* (i.e. 600-700 for nonionic monomer, 560 for ionic dimer and 300 for nonionic dimer). So compred *to physiological osmolality of 300 mosmols/kg water*, ***nonionic dimers are physiologically isotonic*** in solution at 300 mg iodine/ml. Normal plasma osmollity is 300 mosmols/kg water at iodine concentration of 300mg/ml.
- So LOCM means that osmolality is lower than the HOCM (not physiological). *Lowest osmolality/osmolarity is seen in* ***non ionic dimer*** *agents* which becomes almost ***physiologically isotonic or iso-osmolar***Q (visipaque 320 is 290 mosmol/kg and isovist 300 is 320 mosmol/kgH_2O;320 & 300 are iodine concentrations).
- **Contrast agent ratio (CAR)** which indicates the osmolality of an agent, is derived by dividing the number of particles in solution.

$$CAR = \frac{\text{Number of } \textbf{iodine atoms}}{\text{Number of } \textbf{particles} \text{ in solution}}$$

Extracellular MRI Contrast Agent

Iodinated contrast agents have low lipid solubility, low toxicity, low binding affinities for protein, receptor or membranes, low moleculer wt & are very hydrophilic. On iv injection b/o high capillary permeability they all are ***distributed rapidly into extravascular, extracellular interstitial space (except in CNS)***Q but do not enter blood or tissue cells. **Pharmacokinetics of all extracellular MRI contrast agents (all gadolinium except Gd-BOPTA) are similar to iodinated water soluble contrast media**. They ***donot cross the blood brain barrier unless the barrier is disrupted***Q. These agents accumulate in tissues with abnormal vascularity (inflammation & malignancy) and in regions where BBB is disrupted.

Owing to their rapid equilibration in interstial space of both normal & inflammatory/tumor tissues, the use of dynamic MR imaging after bolus injection makes the best use of narrow imaging window with a transiently increased tumor /inflammatory to normal tissue contrast.

These agents are well tolerated with no differences in the safety of various agents except when it comes to extravasation in soft tissues; then the osmolality is important and ***high osmolar agents are likely to induce more local dmage***. In blood, the osmotic load of all Gd-based contrast media is very low, compared to iodinated contrast media, because only a small amount of contrast agent is required to produce a diagnostic MRI.

The pharmacokinetics of all agents except **Gd-BOPTA** (gadobenate dimeglumine) are similar to iodinated water soluble contrast media. Unlike all other Gd- chelates, Gd-BOPTA has a capacity for weak & transient protein binding & is eleminated through both the renal & hepatobiliary pathways. So it behaves *as a conventional extrcellular contrast agent in first few minutes* following iv administration and as a *liver specific agent in a later delayed phase* (40-120 min after administration) when it i taken up specifically by normal functioning hepatocytes.

These are *more nephrotoxic than iodinated contrast medium in equimolar dose*. However, nephrotoxicity after contrast enhanced (CE) MRI is not common even in patients with renal disease as the *dose required is small in comparison to the doses of iodinated contrast media* that are used for CT or other radiographic examinations.

Nephrogenic systemic fibrosis (NSF) is characterized by indurated scleroderma like skin changes mainly affecting limbs & trunks. It can progress to cause flexion contractures of joints & fibrotic changes affecting other organs such as muscles, heart, liver and lungs. NSF is most commonly a/w *administration of less stable, nonionic-linear chelates (gadodimide >> gadovesetamide*; l/t release of highly toxic Gd^{+++} ion) in

JAYPEE BROTHERS

Osmolality is proportional to **the ratio of iodine atoms to the number of particles in solution**. The contrast agent with **lower ratio (3:2)** are **HOCM** and they have more particles in solution per iodine atom (or in other words less iodine atoms per particle). And agents with ***higher ratio (3:1 or 6:2 and 6:1)*** are **LOCM**.

HOCM	LOCM	
Ionic monomers (**HOCM**; $3I_2$ &2 osmotic particles per molecule= **3:2**)	**Nonionic monomers** (**LOCM**; $3I_2$ & 1osmotic particle per molecule = **3:1**)	**Ionic dimers** (**LOCM**; $6I_2$ & 2 osmotic particles per molecule = 3:1)
- ***Diatrizoate (Urografin, hypaque)***Q - Iothalmate (Conray) - Ioxithalmate - Metrizoate `	- ***Iohexol (Omnipaque)***Q - ***Iopamidol (neopam)***Q - Iomeron - Iopromide (ultravist) - Ioversol (optiray) - Ioxilan - Iobitridol (Xenetix)	- Ioxaglate (hexabrix) **Nonionic dimmers** (**Isotonic LOCM**; $6I_2$ & 1 osmotic particles per molecule = 6:1) - ***Iodixanol (visipaque)***Q = Isotonic - Iotrolan (isovist)=LOCM

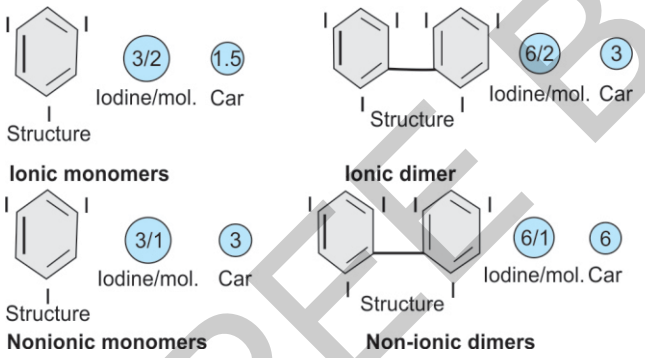

patients with *advanced renal failure (GFR < 30ml/min) including those on dialysis*. A more stable Gd-CA such as macrocyclic Gd chelates might prove less hazardous if CEMRI is thought to be necessary in such a group of patients, including *pregnant & lactating women with end stage renal failure.*

Extracellular MRI-CA (with osmolality in mosmol kg H_2O)	MR Contrasts for liver imaging
• **Linear ionic** - Gadopentate dimeglumine (Gd-DPTA)=1960 - Gadobenate dimeglumine (Gd-BOPTA)=1970 • **Linear –nonionic** - Gadodiamide (Gd – DPTA - BMA)= 650 - Gadovesetamide (Gd-DTPA-BMEA)=1110 • **Cyclic–ionic** - Gadoterate meglumine (Gd-DOTA)= 1350 • **Cyclic–nonionic** - Gadoteridol (Gd-HP-DO3A)= 630 - Gadobutrol (Gd-BT-DO3A)= 1600	• Non specific Gd-chelates eg omniscan, gadovist distribute in extracellular space • **Hepatocyte selective Gd-chelates** eg **Gd-BOPTA** & **Gd – EOB-DTPA** (multihance, primovist) initially distribute in EC space but undergo hepatic excretion • **Non Gd – based contrasts** - **Magafodipir trisodium (Mn DPDP) eg manganese based** teslascan is selectively taken by **hepatocytes** & excreted into bile ducts - **Superparamagnetic iron oxide particles (ferrumoxide** 80-150nm)eg endorem is selectively taken up by **Kuffer cells** - **Ferucarbotran** (60 nm iron oxide particles) eg resovist (by Kuffer cells)

Adverse Reactions to Radiological Contrast Media (RCM)

Factors Significantly Predisposing to adverse drug (contrast) reactions

All adverse reactions are significantly more frequent with **HOCM** and in patients with

- *Previous adverse reaction* (excluding mild reactions like flushing, nausea) to contrast and h/o *asthma or bronchospasm* are two most dangerous predisposing factors.
- H/o allergy or atopy
- Cardiac patients in failure, with decompensation (CCF), unstable arrhythmia, recent MI
- ***Renal patients in failure (creatinine > 2mg%), diabetic nephropathy, on metformin***Q

Renal Adverse Reactions (Contrast Nephropathy)

- It is reduction in renal function induced by contrast agent. It classically presents with rise in BUN & creatinine (>25% or 44 µmol/L within 3 days of IV constrast).
- Patients at **highest risk** for developing contrast induced ARF are those with

1. ***Pre-existing renal impairment/failure (>132µmol/L) and oliguria***Q.
2. ***Diabetic nephropathy***Q (DM without renal impairment is not a risk factor)
3. ***Dehydrated (hypovolemic) patient***Q.

JAYPEE BROTHERS

- Feeble infants, aged patients, patient with severe general debility, ***dehydration***Q
- Anxiety, apprehension, very nervous.
- ***Hematological eg sickle cell anemia***Q & metabolic conditions.
- Menifest hyperthyroidism, thyrotoxic-goitrous patients (**absolute contraindication** to RCM administration).
- Delayed adverse reactions (more common in LOCM & dimmers than HOCM &/or monomers)

Guidelines to Prevent generalized RCM reactions

- ***Use nonionic agents***Q
- Premedication (with *corticosteroid / prednisolone* orally 12 hr & 2hr before RCM *along with anti histamines) in high risk patients* especially when ionic agents are used.

Types of Adverse Reaction

- **Idiosyncratic (anaphylactoid) reactions** are most serious & fatal complications that occur without warning are *not dose dependent*.
- **Non-idiosyncratic reactions** are *dose dependent* & therefore relate to the chemical composition, osmolality & concentration of contrast agent and the volume, speed & multiplicity of the injection. Examples include
  - **Hyperosmolar reactions** such as *erythrocyte damage* (d/t loss of intra RBC water), ***endothelial damage and blood brain barrier damage*** occur in HOCM, that have very high osmolality (5-8 times the physiological osmollity). Other hyperosmolar reactions are **vasodilatation** (l/t local heat, warmth, discomfort or severe pain during peripheral arteriography; and severe systemic hypotension, peripheral venous pooling, decreased venous return & cardiac failure), **hypervolemia** (l/t decreased hemoglobin concentration and increasing stress on left ventricle) and **cardiac depression** (esp after coronary angiography). All these are reduced by use of LOCM.
  - **Chemotoxic reactions** are d/t anion rather than to its iodine content as it is very firmly bound to benzene ring. Chemotoxicity increases as the number of carboxyl group increases & number of hydroxyl group decreases. Chemotoxicity may l/t allergic like symptoms, cardiac, neurological & renal toxicity as well as vascular manifestations.
  - **Cationic toxicity** may result from changes (either greater or lesser) in *sodium or calcium ion concentration*
- **Vasomotor reactions** like severe hypotension, tachy or bradycardia, marked apprehension, anxiety, sweating, and depression of myocardiac contraction, and reduced cardiac output l/t unconsciousness, collapse & death are *combined idosyncratic & non-idosyncratic reactions*.

4. Large doses and multiple injections within 72 hours (usually upto 25 g and maximally upto 70 gm of iodine i.e. 1 gm iodine per Kg body weight is advisible even in well hydrated patients with good renal function).
5. Intra arterial injection (in renal arteries or aorta) is more nephrotoxic than intravenous injection.
6. Nephrotoxic drugs (diuretics, antibiotics, NSAIDs, cytotoxic therapy) may enhance nephrotoxicity.
7. ***Myelomatosis, multiple myeloma***Q (b/o tubular obstruction d/t proteinaceous casts).
8. **Metformin (phen formin)**, an *oval biguanide hyperglycemic therapy* for diabetes mellitus type 2, in patients with severe renal impaiment.
9. **HOCM** are more nephrotoxic and large doses may damage renal medulla & reduce intramedullary blood flow in patients with acute calculus renal colic.

- *Metformin is primarily excreted by kidney as an active compound*. In patients with severe renal impairment, intravascular accumulation of biguanide may occur ofter RCM precipitating a **potentially fatal – biguanide lactic acidosis** (*vomiting, diarrhoea, somnolence*). RCM related lactic acidosis is extremely rare in diabetics receiving metformin, if the patient has normal renal function before RCM. It is therefore recommended that metformin is *only discontinued if there is pre-existing renal impaiment* and it may be *recommenced 48 hr later* (after reassurance of good renal function after RCM).
- It is an established concept, that HOCMs are more nephrotoxic and ***LOCMs are preferred for all patients considered to be at increased risk of contrast nephropathy***Q, (especially with diabetic nephropathy). However, it is not yet established whether nonionic **monomer** LOCM or nonionic **dimer** LOCM (i.e. iso-osmolar agents) have the *lower renal toxicity*.
- **Delayed reactions like** arm pain, delayed rash, flu like symptoms, *salivary gland swelling (iodide mumps), delayed vasculitisw, disseminated LE and Steven Johnson syndrome* are more common in women and with **LOCM** and **dimers**. Presumbly the reaction is *idiosyncratic and non dose dependent*. Because of this nonionic dimer – iotrolan has been with drawn from clinical use.
- Patients with **thrombotic tendency (like severe polycethmia)** may have an increased risk *esp after arterial injection of nonionic LOCM*. HOCM inhibits thrombosis more than LOCM.
- Patients with **pheochromocytoma** may develop hypertensive crisis, therefore, *preliminary alpha - & beta – adrenergic blockade* is advisible.
- It is clear that all RCM can cause nephropathy in patients with risk factor. Although **hemodialysis** can safely remove iodinated contrast media from the body, it does not prevent nephrotoxicity & nephropathy of poorly functioning kidneys. In contrast **hemofiltration** is effective in reducing this complication.

JAYPEE BROTHERS

CAT Scan: Concept, Evolution and Hounsfield Unit/CT number (CTn)

CAT Scan: Concept and Evolution

- In conventional projection radiography (e.g. X-ray), structures further from film are superimposed on those closer to the film. This causes an overall reduction in contrast b/w objectects of smilar composition and l/t an inability to determine the depth and shap of an object.
- **Tomography** literally means a **sectional imaging** or **slice (transverse section) view**Q of a patient. In tomography only structures in a selected slice, parallel to the film are imaged sharply. Those above and below are deliberately blurred (so as to be unrecognizable) by simultaneous movement, of two of the three following: tube, film, patient during the exposure. In **conventional linear tomography** the contrast is poor because of influence of overlying tissue.
- **Computed tomography** (**CT scan** or originally k/a **computed axial tomography = CAT Scan)** generates image in ***transaxial section***Q, i.e. perpendicular to the axis of rotation of x-ray tube about the body and generally **perpendicular to crano-caudal axis of patients body**. Unlike linear tomography, CAT images are not influenced by the properties of neighbouring regions of body and therefore, display true contracts within the imaged section. The only limitation being imposed is by width/thickness of section.
- Most CT had are performed in supine position with the plane of section at **10-25° to Reid's baseline (canthomeatal line)** to avoid radiation through eyes (esp. senstive lens).
- Three factors significantly improve the spatial resolution of CT such that it can be described as high resolution CT **(HRCT).**

Narrow *beam colimation*Q
↓
i.e. it cuts thin slices of ≈1.5 mm as compared to ≈10 mm of CT scan

High *Spatial reconstruction algorythm (Edge enhancing or sharp algorithm) Ex Bone algorythim*Q
↓
Makes structure visible, sharper & reduces smoothing (opposite to sharp) but it makes image noise more obvious

Small *field of view*Q
↓
Increase resolution

Hounsfield unit / CT number

- **CT** is ***a special type of X-ray procedure***Q, that involves the measurement of the weakening, or attenuation of X-ray beams by body structure at numerous positions located within the patient.
  These attenuation values are named **Hounsfield unit (CTn)** in honour of **Godfrey Hounsfied**, the inventor of CT Scanning.
- CT mages are mostly calculated on 512×512 (rarely 256 × 256 or 1024 × 1024) pixel matter. Each **pixel** or more correctly described as **voxel** is a volume element having 3 dimensions with *a depth that is equal to thickness of the section*. The value stored in each pixel/voxel, the CT number represents the average liner attenuation coefficient of tissue (μ_t) in the voxel.
- CTn is an *arbitrary unit of X-ray attenuation* used for CT scan, and it *depends on average linear attenuation coeficient of the matter* and is given by

$$HU = \frac{\mu_t - \mu_{H_2O}}{\mu_{H_2O}} \times 1000$$

μ_t = Attenuation coefficient of tissue of interest
μ_{H2O} = Attenuation coefficient of water

- By definition, **water has CTn equal to 0**, and **air** (b/o its *very low density* giving it and *attenuation coefficient of zero*) has a ***CTn equal to -1000***Q. Air and water are used as fixed points for calibration of CTn scale, which approximately ranges from *–1000 to +3000 (i.e. 400 levels of grey)* or more accurately from -1024 to +3071 (4096 levels of grey).
  A CT number **-1000** is represented as **black** and **+3000** as **white**, with **all shades of grey displayed between**.
  However, the human eye cannot differentiate >50 grey shades. So **windowing** is done to bring out hidden details in image. For example -900 to -400 window range (which coincides with CTn of lung – 300 to - 800) display detailed lung structure but same section with -240 to + 300 window range provides no information of lung but show good structural detail outside.
- **CTn (or HU)** for various tissues is.

CTn above 0 i.e. Positive	
Bone	500-1000
Contrast	130
Calcification	100
Muscle	40-60
Blood (congealed)	55-75
Grey matter (brain)	35-45
White matter (brain)	20-30

CTn ≤ 0 (i.e. Negative)	
Water	0
Fat	-50 to -150
Lung	-300 to 800

JAYPEE BROTHERS

Colour Doppler USG

- **Colour doppler** permits accurate **detection of vessels (arteries and veins), confirming their patency and direction of flow** (where relevant eg in portal vein) and **obtain useful velocity information**, such as *peak systolic velocity, mean velocity & turbulence*. It permits the detection of very small vessels (that even could not be studied in 2D images) and the **assessment of number and distribution of vessels with in a tissue volume.**
- Color doppler can **identify segments of stenosis or occlusion** (by directly measuring *diameter reduction or cross sectional area reduction* in large vessels or indirectly quantifying stenosis by the *increase in velocity* that occurs as blood passes through stenosis), **detect false aneurysm** (by to and fro patterns as blood flows in and out of flase aneurysm during the cardiac cycle) **and define plaques/thrombus** (smooth, echogenic plaques are likely to be fibrotic and stable, whereas irregular, hypoechoic plaques are more likely to be unstable and act as a source of **emboli**).
- Color doppler can be used for **evaluation of neck vessels (carotid & vertebral arteries)**, pulsatile neck masses, **peripheral arteries/veins of extremities (lower & upper limb), large abdominal vessels** (such as **portal vein, hepatic artery, hepatic vein, renal artery, renal vein, aorta & IVC**), **blood flow to ovaries, uterus, testis and prostate** (in pelvis; through trans abdominal, trans vaginal or transrectal approaches). Color doppler can also be used to evaluate **vascular complications** of **renal transplant** and to identify **ureteric jets** as urine enters the bladder at vesico-ureteric junctions. In patients with obstructed ureter the jets on affected side will be less frequent or absent.
- **In Colour doppler colours** are used to represent ***direction of flow***Q towards & away from the transducer; usually **red is towards & blue is away from transducer**. Mn "**BART** or **jV AB**= **B**lue – **A**way; **R**ed - **T**owards". **Shades (intensity of colour)** represent ***velocity of flow***Q; the paler shades representing higher velocity.
- **Power doppler** is good for *showing areas of flowing blood*, particularly when it is *moving slowly or in small vessels*; but *at the expense of losing directional & velocity information.*

Neck Vessel Examination

- Color doppler can be used for **evaluation of neck vessels (carotid & vertebral arteries)** *in patients with transient ischemic attacks (TIA) or reversible ischemic neurological deficits (RINDs),* who may benefit from carotid endaterectomy surgery. It is usually not indicated in patients with established and completed strokes, unless there are milder-resolving strokes in younger patients.
- Stenosis or absent segment in one **vertebral vessel** in neck is not usually of clinical significance as the basilar circulation can be maintained from the other artery. However, a **reversed flow** (sometimes exercise of ipsilateral arm muscles may be required to produce it) **is a sign of occluded or severely stenotic subclavian artery (subclavian steal syndrome).**

Abdominal & Pelvic Vessel Examination

- Color doppler USG examination of abdominal vessels is little more challenging than peripheral & neck vessel examination because of their *deeper location, presence of respiratory motion and bowel gas interferences.*
- **Blood to uterus and ovaries** varies with ovulation with increased flow and decreased pulsality near ovulation; it is used to monitor **infertility treatment**. Increased vascularity with low RI (<0.6) is seen in **ectopic pregnancy** (d/t trophoblastic tissue) and **trophoblastic disease**; return of wave form and RI to normal correlates well with successful treatment. Increased uterine artery RI during established pregnancy (a sign of increased resistance in placenta) reflects **intra uterine growth retardation.**
- Color doppler USG is also useful in differentiating **ovarian/testicular torsion** (decreased blood flow) from **inflammation (epididymo-orchitis)** and tumors (increased blood flow), **varicoceles** (multiple serpiginous cystic areas in epididymis).

Transcranial Doppler Examination

- **Transcranial color doppler USG examination of neonatal and fetal brain** through the fontanelles and thin calvarial bones to detect fetal abnormalities. **In adults, transcranial approach** is more difficult esp. in females, back skinned and elderly and **can examine main cerebral arteries (not veins) only** through thin squamous temporal bone in front of ear. The main indication for transcranial color doppler in adults include **monitoring of spasm and flow after** stroke and subarachnoid hemorrhage, assessment of intracranial collateral pathways and detection of stenosis (>65%) and aneurysm (>5mm) of main cerebral arteries.

Peripheral Vessel Examination

- Peripheral vessels (arteries & veins) can be evaluated for stenosis or occlusion in **patients with claudication**, and **peripheral vascular disease**; for abnormal flow in **varicose veins** and to reveal thrombosis/plaque in ***deep vein thrombosis***Q.

JAYPEE BROTHERS

Direct Catheter Arteriography (Angiography)

- **Direct catheter arteriography (angiography)** is *percutaneous arterial* catheterization based on original work of *Seldinger* (in Stockholm, 1953). The most useful and commonly used sites for insertion of catheter into the arterial tree are 1) **femoral artery (most preferred & most common route)** and 2) **axillary artery** (although *most proximal portion of brachial artery* is punctured rather than axillary artery, so **high brachial** is preferred term).
- The **most common vessel** punctured for diagnostic and therapeutic angiography is **common femoral artery. Retrograde** femoral artery puncture is the most common technique used to approch arteries above inguinal ligament (such as coronary, carotid etc). **Antegrade** femoral artery puncture is used when performing ipsilateral superficial femoral, popliteal or infragenicular artery angioplasty.
- In practice, femoral & axillary arteries permit investigation of most areas so other sites like popliteal, lower brachial, radial artery, common carotid, etc are used in special circumstances (eg if femoral approach is not possible d/t iliac-occlusive disease). In recent years, there has been a *trend toward a greater use of upper extremity access* even in those individuals with patent femoral vessels because of lower morbidity caused by small caliber catheters (and DSA technique enables adequate studies to be obtained by injection through small caliber catheters).
- **Digital substraction angiography (DSA)**, digitally substract (manipuletes via computer) the shadow that are present on plain films from the films taken after contrast injection resulting in an image containing detalis of opacified structures only.
- **Selective catheterization** of renal artery, coeliac axis etc is done by fluoroscopic manipulation of special shape catheters like straight flush/pigtail/cobra/sidewinder. **Superselective (or subselective) catheterization** is *catheterization of small subsidiary arteries that themselves arise from named branch arteries* mostly during *embolization procedure*. A **co-axial catheter** (one that passes through the lumen of a diagnostic or guiding catheter) is often used for catheterization of these small vessels.
- *Damage to arterial wall (like subintimal stripping) leading to dissection* occurs during puncture, manipulation and injection of saline/large volumes of contrast. The decreasing order of artery damaged during femoral route celiac angiography is **external iliac artery > internal iliac artery > inferior mesenteric > gastroduodenal > celiac trunk > superior mesenteric artery**.

JAYPEE BROTHERS

2

SYSTEMIC RADIODIAGNOSIS I: NEUROLOGY & NEPHROLOGY

These chapters also include complete description of pathology, medicinal & surgical aspects of relevant topics

CENTRAL NERVOUS SYSTEM

Multiple Sclerosis (MS)

Demyelinating disorder characterized by inflammation & ***selective destruction of CNS myelin predominantly of white matter long tracts***Q. Characteristic pathological triad include – inflammation, demyelination & gliosis (scarring).

Pathogenesis

- Perivenular cuffing with inflammatory T cells and macrophages, which also infiltrate the surrounding **white matter**
- At site of Inflammation, **BBB** is **disrupted**
- Myelin specific auto antibodies promote **demyelination** & stimulate macrophages & microglial cells.
- As lesion evolves, Astrocytes proliferates (**gliosis**)

Clinical Presentation

- Age of onset is between **20 & 40 years** (slightly later in men) with a **F:M ratio of 3:1**. Course is *relapsing/remitting/progressive*.
- **Sensory symptoms** include *paresthesia* (eg tingling, prickling, formications, pins & needles, or painful burning), *unplesant sensations* (feelings that body parts are swollen, raw, wet or tightly wrapped), *pain and hypesthesia* (reduced sensation, numbness or dead feelings).
- **Weakness of muscles** may mainfest as *loss of strength, speed, or dexterity, as fatigue or gait disturbance*, Exercise induced weakness is characteristic symptoms of MS. Weakness is of UMN type and is usually a/w the signs of pyramidal signs. **Spasticity** is commonly seen with *painful muscle spasms*.
- **Optic neuritis** presents as *decreased visual acuity and color perception* (desaturation) in central field of vision and rearely complete loss of light perception. The symptoms are generally monocular, preeded/accompanied by *periorbital pain (aggerevated by eye movements)* and accompanying afferent pupillary defect, papilliti and ultimately optic atrophy.
- **Diplopia** (double vision) may result from *internuclear opthalmoplegia (INO)* of cranial nerve (6 >3, 4) palsy. INO consists of *impaired adduction* of one eye (d/t *ipsilateral medial longitudinal fasciculus lesion*) often a/w prominent nystagmus & small skew deviation of abducting eye. Gaze disturbances common in MS include *bilateral INO horizontal gaze palsy, one & a half syndrome* (horizontal gaze palsy and INO), and acquired pendular nystagmus.
- *Visual blurring*, ataxia, *bladder dysfunction* (eg detrusor hyper reflexia, detrusor sphincter dyssynergia occurs

MRI Findings

- **MRI has revolutionized the diagnosis & management of MS**Q**.** Characteristic abnormalities are found in **>95%** of patients, although **>90%** of lesions visualized by MRI are asymptomatic.
- Early MS lesions show **gadolinium (Gd) enhancement** d/t increased vascular permeability caused by inflammatory breakdown of BBB. Such *leakage of IV-Gd into parenchyma* occurs early, severs as a marker of inflammation and persists for 1 month; and residual MS plaque remains visible indefinitely as a focal area of **hyper intensity** (a lesion) **on spin echo (T_2WI) and proton density images**.
- Lesions are frequently oriented ***perpendicular to the ventricular surface,*** corresponding to the pathological pattern of previous **demyelination (Dawson's fingers)**. Lesions are **multifocal** within the brain, brainstem & spinal cord. **Lesions >6mm** located in **corpus callosum, periventricular white matter, brain stem, cerebellum, or spinal cord (i.e. juxtacortical, periventricular, infratentorial or spinal cord) are MS- typical lesion- locations** (regions) and perticularly helpful diagnostically.
- Total volume of T2W signal abnormality **(burden of disease)**

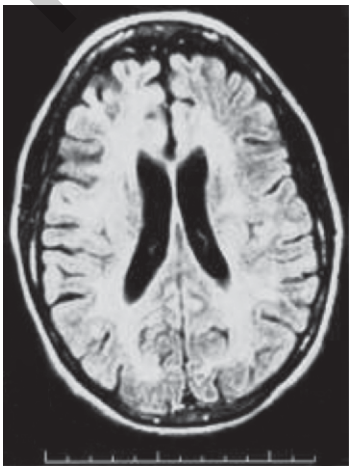

Multiple Sclerosis as shown of a FLAIR MR image

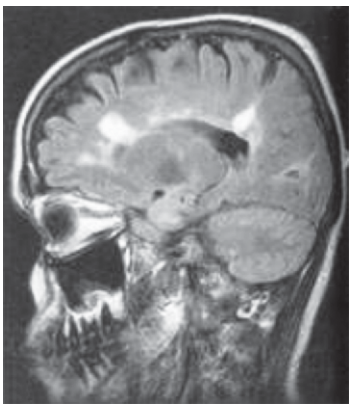

Parasagittal FLAIR MR image

JAYPEE PROOFERS

in >90%), *constipation, cognitive dysfunction*, depression, fatigue, facial weakness, vertigo, *sexual dysfunction* (like decreased libido/sensation, impotence in men and decreased lubrication or adductor spasm in women).
- Heat sensitivity (eg visual blurring d/t hot shower/ exercise = **Unthoff's symptom**), Lhermitte's symptom, **paroxysmal symptoms** (high frequency i.e. 5-40/day, brief duration i.e. 10 s-2 min), trigeminal neuralgia, hemifacial spasm, glossopharyngeal neuralgia & facial myokymia (rapid flickering).

Diagnosis of MS

- It requires ≥**2 episodes** of **symptoms** and ≥**2signs** that reflect pathlogy in **anatomically non contiguous white matter tracts** of the CNS.
- Symptoms must **last for >24hr** and occurs as distinct episode that are **seperated by ≥1month**.
- **At least 1 sign** must be present on **neurological** examination and the **other may be** documented by abnormal paraclinical tests such as **MRI or EPs**
- A/t most recent diagnostic scheme, **the 2nd clinical episode** (event in time) may be supported by *paraclinical test usually* development of new *focal white matter lesions on MRI.*
- *In insidious / gradual neurological progression of disabiity for ≥6 months* without superimposed relapse, documentation of ***intrathecal IgG synthesis may be used to support the diagnosis*** Q ***(assessed by presence of oligoclonal banding or CSF-IgG index)*** Q.

shows a significant correlation with clinical disability, as do brain atrophy.
- Few (1/3rd) T2W lesios appear as **black holes** (*hypointense lesions*) on T1WI, which may be a marker of irreversible demyelination & axonal loss.
- Magnetization transfer ratio (**MTR**) imaging & proton magnetic response spectroscipic imaging (**MRSI**) may ultimately serve as *surrogate marker of clinical disability*. MRSI *may differentiate demyelination from edema* and can quantitate molecules such as *N-acetyl aspartate, which is a marker of axonal integrity*.

Evoked Potentials (EP)

- EP testing of *visual, auditory, somatosensory or efferent/motor-CNS pathways* provide most information. When the pathways studied are clinically uninvolved
- It *is not specific* to MS, although *a marked delay in latency* of a specific EP component (as opposed to reduced amplitude or distorted wave shape) is suggestive of demyelination.

CSF

- Mononuclear cell pleocytosis and **an increased level of intrathecally synthesized IgG** (assessed by **oligoclonal banding/OCB** &/or **CSF-IgG index**). CSF IgG index expresses the ratio of IgG to albumin in CSF divided by the same ratio in serum. 2 or more OCB on agarose gel electrophoresis are found in >75-90% MS patients.
- Pleocytosis of >75 cells /µL, presence of polymorphonuclear leukocytes or protein concentration >1gm/L should raise concern that diagnosis is not MS.

Vein of Galen Malformation (VOGM)

Etio-Pathology

- Vein of Galen (great cerebral vein) is large deep vein at the base of brain that curves posteriorly under the splenium of corpus callosum. It is located under cerebral hemisphere & drains anterior & central regions of brain into sinuses of posterior cerebral fossa. ***It unites with inferior sagital sinus to form the straight sinus*** Q.
- VOGM is hetrogenous group of anomalies a/w *enlarged deep venous* structures of *galenic system* that are *fed by abnormal midline arterio-venous communications*.
- *Aneurysmal dilatation of VOG is most common pathological finding*. The hugely dilated central venous structure is a persistent embryonic vein k/a *median vein of prosencephalon*.
- VOGM are located in *subarachoid space* and may be:
  Type 1= AV malformation fed by enlarged arterial branches l/t dilatation of VOG + straight sinus + trocular herophili
  Type 2= angiomatous malformation involving basal ganglia + thalmi ± mid brain

Clinical Presentation

- *Can be detected in utero >30 weeks* gestation age
- Male: Female = 2: 1 and ***loud intracranial bruit*** Q may be heard b/o blood turbulence
- **Neonatal pattern of presentation** (0-1 month) is ***high output cardiac failure*** Q d/t massive shunting.
- **Infantile** (1-12 months) pattern includes ***macrocrania from obstructive hydrocephalus and seizures*** Q.
- Adult (>1year) pattern of presentation is *headache, focal neurological defecits* (5%) d/t steal of blood from surrounding structures (steal phenomenon) ± *hydrocephalus* ± *intracranial haemorrhage*
- It may be a/w –
- ***Smoothy marginated midline mass, posterior to indented 3rd ventricle*** Q
- ***Dilatation of lateral & third ventricle*** Q (37%), straight + transverse sinus & trocular herophili.
- Prominent serpiginous network in basal ganglia, thalami and mid brain.
- Porencephaly & nonimmune hydrops.

- **Obs/ Trans fontanellar USG** shows ***median tubular hypoechoic cystic space with high velocity turbulent bidirectional flow*** Q (on pulsed / color doppler). B mode USG shows sonolucent posterior

JAYPEE BROTHERS

draining into VOG
Type 3= transitional AVM with both features

- Feeding vessels of VOGM are
- *Posterior cerebral artery, posterior choroidal artery (90%)*
- Anterior cerebral artery & anterior choroidal artery
- Middle cerebral artery + lenticulostriatal + thalamic perforating arteries (least common; nidus type).

3rd ventricular mass & obstructive hydrocephalus.

- **Angiography** shows *enlarged choroidal / thalamoperforating arteries*, VOG
- On **NECT,** round well circumscribed homogenous hyperdense/isodense mass in region of 3rd ventricle outlet, hyperdense intracerebral hematoma (ruptured AVM), hyperdense focal zones (ischemic) & rim calcification. *Strong enhancement on contrast enhanced CT.*
- **MRI** shows *areas of high velocity signal loss (signal void).*

Signs of Raised Intracranial Tension (ICT)

In children

- ***Suture diastasis (1st & Most prominent)*** Q
- ***Increased convolutional markings or copper beating of skull vault***Q. However, **it is not necessarily pathological** & n*ormal children particularly b/w 4-10 years* as well as children with craniostenosis may show this sign.
- *Sellar erosion* is a late sign of long standing raised ICT usually in children above 10 years of age.

★ Manifestations of **localizing evidence** of presence of cerebral tumor are *localized skull (vault) erosion, intracranial calcification, hyperostosis, abnormal vascular markings and pineal displacement.*

In adults

- ***Thinning or erosion of dorsal sellae***Q (**cardinal sign**).
- Erosion starts as *slight porosis* of anterior cortex of dorsum & sellar floor (best seen in lateral view). It progresses to ***loss of lamina dura (definition of cortex***Q***)*** & eventually frank erosion.
- **Pineal displacement** (>3mm from midline in PA and Towne's view) is a strong evidence of mass lesion displacing pineal away from affected hemisphere.
- Suture diastasis is not seen in adults.

Types of Injuries

	Diffuse Axonal Injuries (DAI)	Cortical/Cerebral/ Brain Contusion	Epidural Hematoma (EDH)	Subdural Hematoma (SDH)	Multiple Infarcts
Etiology	*High velocity severe closed head injury* with *sudden acceleration deceleration or rotational force* produce *axonal shear strain deformation* often at grey-white junction (d/t differing tissue density or fixation) Characteristic microscopic findings are *axonal bulbs or retraction balls (hallmark)* & perivascular hemorrhage Gross pathological markers are *disruptions of penetrating blood vessels at corticomedullary junctions, corpus callosum, internal*	Focal brain lesions primarily involving *superficial grey matter*, with relative sparing of white matter d/t *linear acceleration deceleration forces or penetrating trauma* Punctate or linear hemorrhages occur along gyral crests *d/t brain striking on stationary osseous ridge or less often a dural fold.* **Coup** (*same side as impact*) is *small* area of *direct* impact on stationary brain a/w skull fracture **Countre coup** (*180⁰ opposite to side of impact*) is *broad* area of impact as	Blood collects *b/w inner table of skull and dura* (calvarial periosteal layer) which is bound to cranium at sutural margins Source of bleeding are ***middle meningeal artery tear (most common)***Q or less commonly venous d/t *rupture of dural venous sinuses or diploic veins* Mostly a/w *skull fractures* (in squamous part of temporal bone) but in children EDH can occur without fracture or invisible (ping pong). #	Blood Collects b/w inner dural layer & leptomeninges (arachnoid-pia mater) i.e. *epiarachnoid space* Generally venous in origin, ***from laceration of bridging cortical veins***Q. Less common causes are injury to pial vessels & pacchionian granulations and rapid decompression of obstructive hydrocephalus *History of trauma* may be *lacking* particularly in *elderly*	A gradual & global reduction in cortical blood flow of *normal aging subjects* (vascular dementia)

JAYPEE BROTHERS

	capsule, deep grey matter & upper brain stem producing numerous small haemorrhagic foci	a result of moving brain against stationary calvarium a/w fall.			
Location/Presentation	It is characterized by ***loss / severe impairment of consciousness beginning, at the moment of direct impact***Q. Tend to be *diffuse, bilateral & in very predictable locations* depending on severity of trauma - **Grade I**- at peripheral *grey-white junctions of lobar white matter* (parasaggital frontal & periventricular temporal lobes) - **Grade II**- also involves *corpus callosum* (particularly posterior body & splenium) - **Grade III**- DAI also involves *dorsolateral upper brain stem (mid brain)*	Compared to DAI, CC are *less frequently a/w initial loss of consciousness & poor prognosis* unless they are extensive or occur with shearing or brainstem injury Multiple, bilateral lesions characteristically on **temporal lobes** (just above petrous bone or posterior to greater sphenoid wing) and **frontal lobes** (in orbito frontal, inferior frontal & rectal gyri above cribriform plate, planum spenoidale and lesser sphenoid wing) and less so the **parasaggital convexity (gliding contusion** as sub cortical tissue glides more than cortex).	95% are *unilateral & occur above tentorium in temporoparietal* area As it force fully strips the dura away from inner table, an EDH assumes a characteristic focal ***biconvex or lentiform shape***Q. EDH may cross dural *attachments but not sutures* More common in *younger (20-40 yrs)* as dura is easily stripped away and presents with *transient loss of consciousness* (from brain stem concussion), ***lucid interval***Q, delayed somnolence 24-96 hrs after accident (d/t accumulation of EDH) and *progressive deterioration of consciousness to coma.*	Usually more extensive than EDH & may *cross suture line but not dural attachments* *95% are supratentorial* (frontoparietal, convexity, middle fossa most common) Bilateral, inter hemispheric parafalcial SDH is common in child abuse *More common in elderly* d/t prominent extra axial space (b/o cerebral atrophy) which allows increase motion.	Often asymmetrical - Frontal - Temporal - Parietal lobe with multiple areas of diminished flow
CT	Initial CT are often *normal* in 50-80% DAI Unfortunately only 20% DAI lesions contain sufficient hemorrhage to be detectable on CT as ***multiple small petechial hemorrhage at grey-white junction & corpus callosum***Q	CT 24-48 hrs after injury often show more lesions than initial normal/subtle scan Hemorrhagic contusions are more easily identified & appear as small *foci of high attenuation (hyerdense)* within superficial gray matter of frontal or temporal lobes. They may be surrounded by larger irregular areas of low attenuation from associated edema. Characteristic **salt & pepper lesion** or **mottled /speckled densities** d/t mixed areas of hyperdensity (petechial hemorrhage) & hypodensity (edema) *Edema & mass effect increase* in first few days & delayed hemorrhage may develop	***Well defined, homogenous, hyperdense, biconvex (lenticular or elliptical) extra axial fluid collection***Q. It is *usually a/w overlying skull fracture, does not cross suture lines*. However at vertex, where the periosteum that forms the outer wall of sagittal sinus is not tightly attached to the *saggital suture*, the EDH can cross midline *Only EDH displace falx & venous sinuses away from inner table.* *Mass effect with sulcal effacement & midline shift* is frequent **Swirl sign** predicting	**Acute** SDH is seen as ***homogenously hyperdense, crescent shaped exteraaxial collection***Q that spreads diffusely over the affected hemisphere **Sub acute SDH** is nearly *isodense* with cortex. In such cases *displaced gray white matter interface, midline shift, effacement of adjacent sulci, sulci not traceable to brain surface, ipsilateral ventricle compression or distortion, thickening of ipsilateral portion of skull, contrast enhancement and window setting* usually permit detection of SDH	- Cortical & subcortical infarct - Large ventricles and cortical sulci - White matter leucencies

JAYPEE BROTHERS

for detailed information on PGMEE books, visit our website www.jaypeebrothers.com, for detailed information on PGMEE books, visit our website www.jaypeeb

New ACROSS

A Complete Review of Short Subjects

Why this book?

- The first and the most sought after subjectwise book for PGMEE and the bestselling MCQs book on short subjects.
- The book which has given a new approach and horizon to PGMEE preparation
- Thoroughly revised and updated edition with new layout
- Book covers all questions from 2001 onwards
- All MCQs of All India (NBE Pattern), AIIMS, PGI, DNB, and State-based MCQs up to 2016 have been included
- Detailed, yet concise, short notes are added for each chapter
- Subjects divided into theory and MCQs and further divided into chapters and subchapters, according to their topics such that the study material is easily retainable and understandable for students
- Each new edition is not only an addition of few hundred new questions; as each line of the book is completely revised and updated based on the latest editions of various standard textbooks everytime. Controversial questions are explained with complete references
- A completely revised, researched, concise and condensed (PGMEE-oriented) presentation of important topics and basic concepts with numerous self made tables, figures, flow charts and mnemonics throughout the book, to save student's ample time for preparation
- Provides a methodology to approach PGME examination; includes valuable pedagogical features and many topics of medicine, surgery and pharmacology, coinciding with short subjects
- Indispensable for course review and PGME examinations. Authors recommend to start reading and retaining this book after 2nd professional, during clinical postings.

Available at all medical bookstores
or buy online at www.jaypeebrothers.com

JAYPEE BROTHERS
Medical Publishers (P) Ltd.
www.jaypeebrothers.com

Join us on facebook.com/JaypeeMedicalPublishers

ISBN 978-93-86322-73-9
9 789386 322739