l information on ophthalmology books, visit our website **www.jaypeebrothers.com,** for detailed information on ophthalmology books, visit our website **www.jaypeebrothers.com**

Gonioscopy

A Text and Atlas

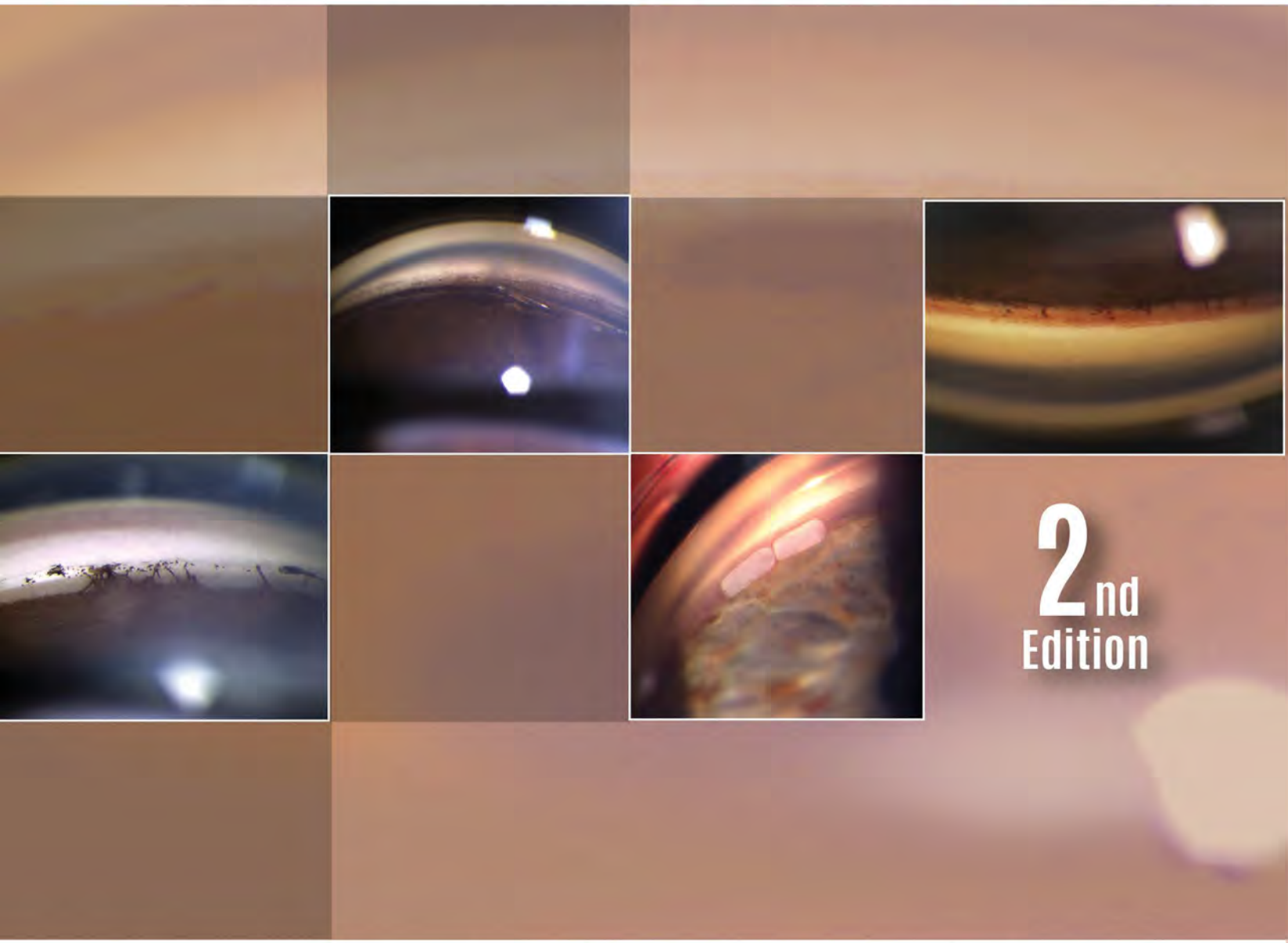

2nd Edition

Tanuj Dada
Talvir Sidhu

Foreword
Robert N Weinreb

JAYPEE

Contents

1. **History of Gonioscopy** 1

2. **Principle of Gonioscopy** 4

3. **Indications of Gonioscopy** 7

4. **Types of Gonioscopes: Direct and Indirect** 11
   - Direct Gonioscopy *12* • Indirect Gonioscopy *14*

5. **Gonioscopy Techniques** 20
   - Indirect Gonioscopy with Scleral Lenses (Goldmann) *20* • Indirect Gonioscopy with Corneal Lenses (Posner/Zeiss) *22* • Direct Gonioscopy Technique *23*
   - Intraoperative Gonioscopy Technique *24* • Retcam Gonioscopy Technique *26*
   - Documentation of Gonioscopy/Recording-Goniogram *26*

6. **Dynamic Gonioscopy Techniques** 29
   - Manipulative Gonioscopy *29* • Indentation Gonioscopy *31* • Biometric Gonioscopy *34*

7. **Gonioscopy Grading Systems** 36
   - Shaffer's System *36* • Spaeth System *37* • Scheie System *37* • RPC Classification *37*
   - Becker System *38* • Shaffer-Kanski System *38*

8. **Sterilization of Gonioscopes** 40
   - Ideal Sterlization Method *40* • Common Errors While Performing Gonioscopy *41*

9. **Normal Gonioscopic Anatomy** 42
   - Corneal Wedge-localizing the Schwalbe's Line *43* • Iris *43* • Iris Processes *46*
   - Ciliary Body Band *47* • Scleral Spur *47* • Trabecular Meshwork *47* • Schlemm's Canal *48*
   - Schwalbe's Line *49* • Normal Blood Vessels *49* • Other Regions *50*

10. **Assessment of Angle Pathology: An Overview** 52
    - Protocol for Evaluation of Angle Structures *52* • Angle Pathology *53*

11. **Primary Angle Closure Disease** 55
    - Clinical Features *56* • Gonioscopy in Angle Closure *56* • Gonioscopic Features *56*

12. **Primary Open Angle Glaucoma** 65
    - Clinical Features *65* • Gonioscopic Features *66*

13. **Juvenile Open Angle Glaucoma** 69
    - Clinical Features *69* • Gonioscopic Features *69*

14. **Congenital Glaucoma** 76
    - Primary Congenital Glaucoma *76* • Clinical Features *77* • Gonioscopic Features *79*

15. Axenfeld-Rieger Syndrome **82**
• Clinical Features *83* • Gonioscopic Features *85*

16. Iridocorneal Endothelial Syndrome **91**
• Clinical Features *91* • Gonioscopic Features *96*

17. Aniridia **98**
• Clinical Features *98* • Gonioscopic Features *99*

18. Glaucomas Associated with an Increased Angle Pigmentation **102**
• Pigment Dispersion Syndrome *102* • Clinical Features and Gonioscopy *102*
• Pseudoexfoliation Syndrome *103* • Clinical Features *104* • Gonioscopic Features *106*
• Oculodermal Melanocytosis/Nevus of Ota *106* • Clinical Features and Gonioscopy *107*

19. Uveitic Glaucoma **112**
• Open Angle Glaucoma *112* • Angle-Closure Glaucoma *112* • Clinical Features *113*
• Gonioscopy Findings *113*

20. Post-traumatic Glaucoma **120**
• Clinical Features *120* • Gonioscopic Features *121*

21. Lens-induced Glaucoma **133**
• Open Angle Mechanisms *133* • Angle Closure Mechanisms *133*

22. Neovascular Glaucoma **137**
• Preglaucoma Stage *137* • Open Angle Glaucoma Stage *137*
• Angle-Closure Glaucoma stage *138*

23. Postsurgical Glaucoma **141**
• Anterior Segment Surgery *141*

24. Miscellaneous Conditions **157**
• Congenital Ectropion Uvea *157* • Sturge-Weber Syndrome *158* • Neoplastic Activity *159*
• Elevated Episcleral Venous Pressure-induced Glaucoma *160* • Iridofundal Coloboma *163*
• Foreign Body in Angle *163* • Wilson's Disease *163* • Retinal and Optic Disc Examination with Gonioscopy *170*

25. Intraoperative Gonioscopy and Gonioscopic-guided Surgery **171**
Shamira Perera, Chelvin Sng
• Intraoperative Gonioscopy *171* • Gonioscopic-guided Surgery *175*
• Pearls for Practicing Gonioscopic-guided Surgery *175*

26. Gonioscopy after Glaucoma Surgery **179**
• Postsurgical Evaluation of Anterior Chamber Angle *179* • Glaucoma Implants *184*
• Medical Implants in Eye *190*

27. RetCam Gonioscopy **191**

28. Self-Assessment Questionnaire **197**

Index *209*

CHAPTER 27

RetCam Gonioscopy

JAYPEE BROTHERS

Gonioscopy is the current gold standard for assessing the anterior chamber angle. The advantages of gonioscopy performed on the slit lamp include the ability to visualize the anterior chamber angle under high magnification, the use of corneal wedge to help identify the landmarks in the angles such as Schwalbe's line, and the ability to dynamically indent the angle and distinguish peripheral anterior synechiae from appositional closure. Various grading schemes have been developed to categorize eyes on the basis of gonioscopic assessment of the anterior chamber angle, but such schemes are based on subjective and at best semiquantitative assessment. A number of factors such as the type of lens used, the technique used, illumination and the skill of the observer affects the reporting of gonioscopy findings.

The **RetCam**, popularly known as the Eyecam (Clarity Medical Systems, Pleasanton, CA, USA), is a new technology originally designed to yield wide field photographs of pediatric fundus for the diagnosis and management of posterior segment diseases. The current version available is RetCam 3 which has the option of using 5 lenses for capturing external views, disc, macula, peripheral fundus and anterior chamber. With modifications in the optical technique and the inclusion of two lenses with 120° and 130° field of view respectively, the device can be used to visualize angle structure in a manner similar to direct gonioscopy. The hardware consists of a handheld digital video camera connected by an optical fiber to a light-emitting control unit and computer assembly. The operator focus, illumination and the acquisition of images is controlled with a foot pedal. Still images of the anterior chamber angle can be automatically saved to a computer hard drive and videos also captured with real-time imaging. **Fluorescein angiography** of the anterior segment to detect angle neovascularization is also possible with this technology. The machine can be placed in the operation theater and documentation of both anterior and posterior segment can be done, especially in examination of infants with congenital glaucoma under general anesthesia.

For an imaging session, the patient is positioned supine and the lens probe is placed on a coupling gel without direct corneal contact, minimizing alteration of the angle configuration due to compression artefacts and causing less discomfort than gonioscopy. To image a particular angle quadrant, the patient is instructed to look in the direction of that angle. The probe is positioned at the opposite limbus to the angle being photographed and light from the fiber-optic probe is directed towards the angle of interest, and then tilted downward, to bring the angle structures in view while minimizing pupillary constriction **(Figs 27.1 to 27.18)**.

The RetCam is thus a new and objective way of documenting angle configuration, using a photographic method similar to goniophotography. The images produced are easy for clinicians to interpret and angle appears similar to what is seen in gonioscopy. Images recorded by RetCam can be saved on a computer, thus allowing comparisons to be made over time. Such goniophotographic documentation by RetCam allows for monitoring of angle changes over time and tracking of angle changes with disease progression, as well as treatment effects and also can be used as a patient education tool. The RetCam can identify several etiologies such as pigment dispersion syndrome, pseudoexfoliation syndrome, and neovascular glaucoma as it produces high magnification, true color view of the structures within the iridocorneal angle. Perhaps the simplest yet most noticeable advantage of RetCam technology over traditional gonioscopy relates to patient comfort. Unlike gonioscopy, RetCam is applied lightly to the limbus with the



Fig. 27.1: RetCam



Fig. 27.2: RetCam hand piece with 130° lens with patient in supine position

patient in a semi-recumbent position, which limits natural reflex to move during examination. The lens probe is placed on a coupling gel without direct contact onto the cornea, eliminating the concern of compression artefact. Light from the fiberoptic probe is directed into the angle as opposed to the pupil to reduce the light artefact. Lastly, a trained ophthalmic



Fig. 27.3: RetCam gonioscopy being performed in a case of congenital glaucoma under general anesthesia

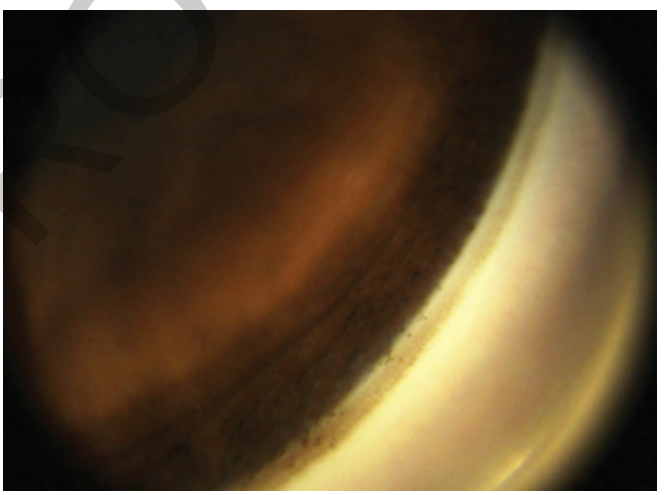

Fig. 27.4: Wide open angle seen on RetCam gonioscopy

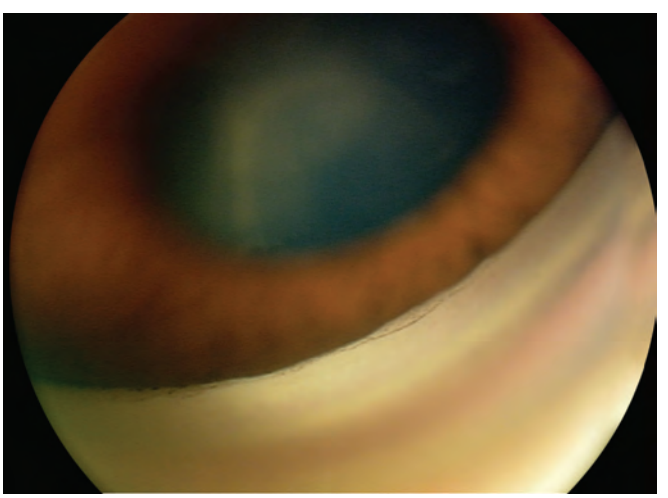

Fig. 27.5: A closed angle with only Schwalbe's line visible (*Photo Courtesy: Dr Shamira Perera*)

JAYPEE BROTHERS

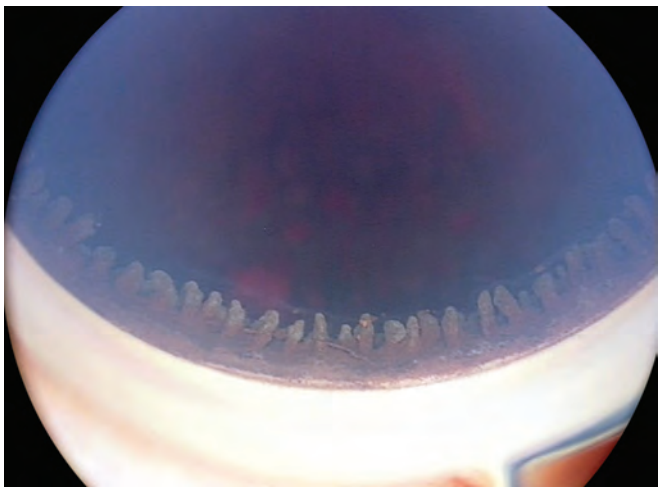

Fig. 27.6: Total aniridia enabling the ciliary processes to be seen (*Photo Courtesy: Dr Shamira Perera*)

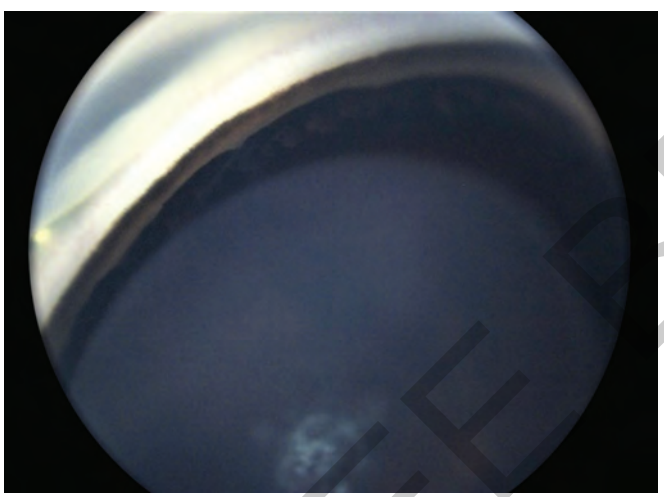

Fig. 27.7: Aniridia with small stump of iris and anterior insertion of iris seen in congenital glaucoma



Fig. 27.8: Aniridia with a stump of iris along with superiorly displaced cataractous lens



Fig. 27.9: Anterior insertion of iris in primary congenital glaucoma

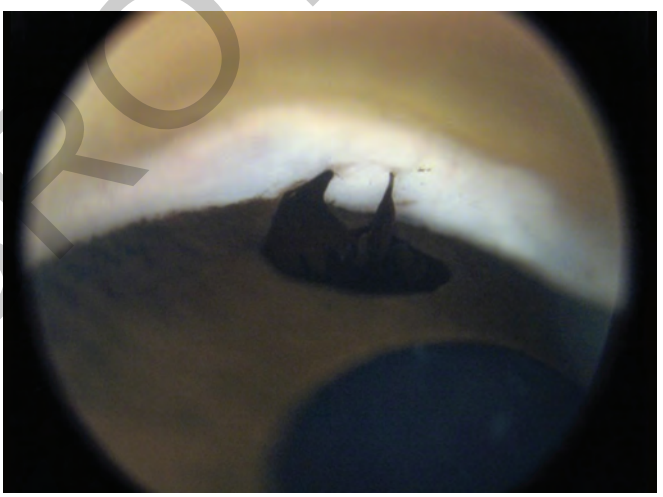

Fig. 27.10: Small sclerostomy with iris adhesions and peripheral iridectomy in a primary congenital glaucoma

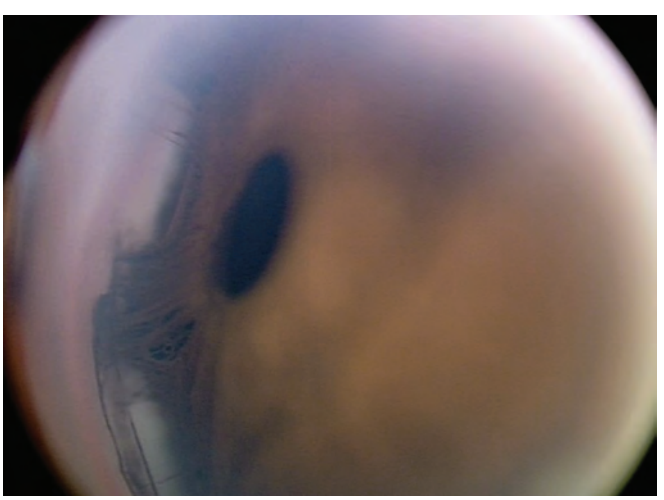

Fig. 27.11: Iris strands extending to a posterior embryotoxon in anterior segment dysgenesis (*Photo Courtesy: Dr Shamira Perera*)

JAYPEE BROTHERS

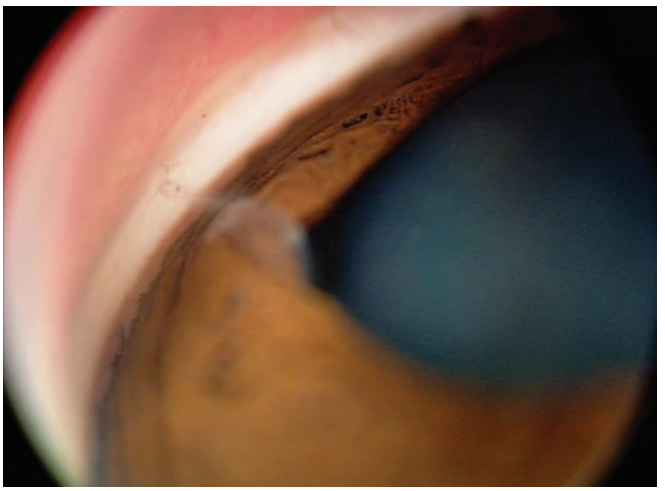

Fig. 27.12: Vitreous strand attached to side port incision causing peaking of the pupil (*Photo Courtesy: Dr Shamira Perera*)

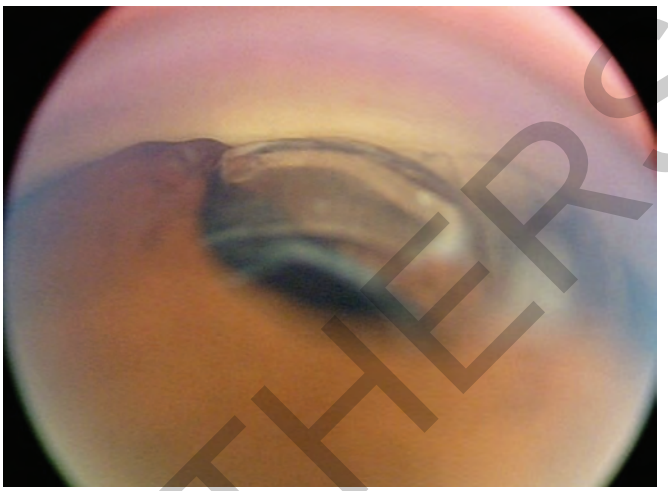

Fig. 27.15: Traumatic partial dislocation of intraocular lens and capsular bag through the pupil with significant zonular loss. Soemmering's ring can be seen to the right of the haptic (*Photo Courtesy: Dr Shamira Perera*)

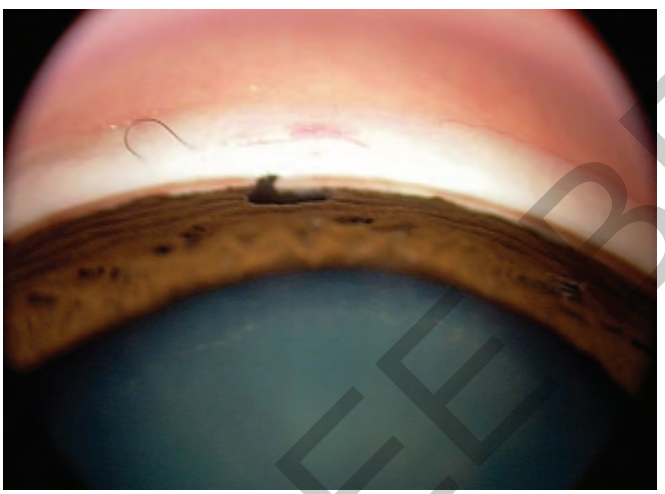

Fig. 27.13: Normal appearance of the releasable suture, sclerostomy and surgical iridectomy after trabeculectomy (*Photo Courtesy: Dr Shamira Perera*)



Fig. 27.16: Iridodialysis and angle recession after a blunt injury to the globe (*Photo Courtesy: Dr Shamira Perera*)

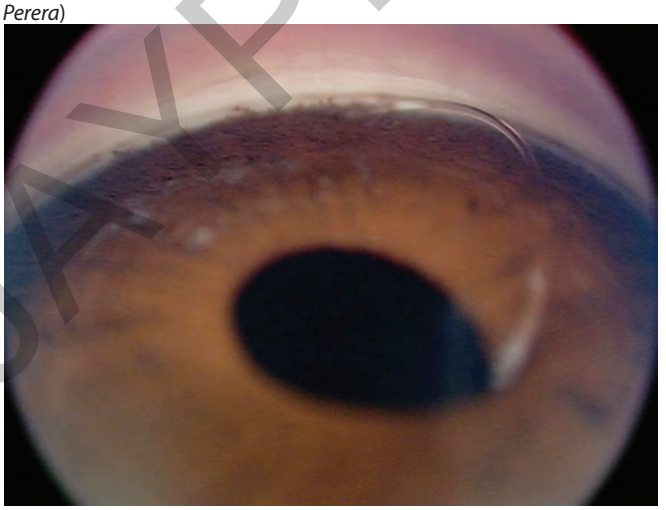

Fig. 27.14: Haptic of intraocular lens displaced into the anterior chamber (*Photo Courtesy: Dr Shamira Perera*)

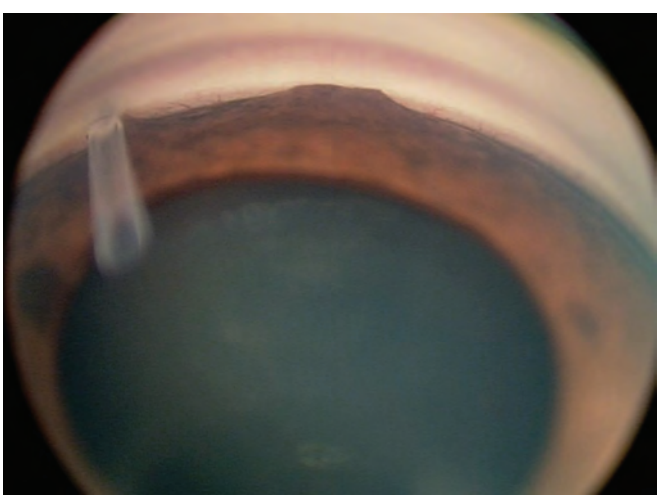

Fig. 27.17: Tube in the anterior chamber with an adjacent area of peripheral anterior synechiae (PAS) (*Photo Courtesy: Dr Shamira Perera*)

JAYPEE BROTHERS



Fig. 27.18: Angle recession and an area of PAS (*Photo Courtesy: Dr Shamira Perera*)

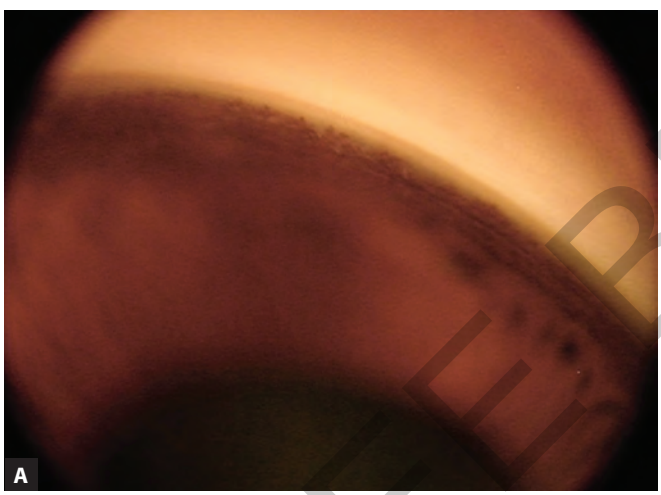

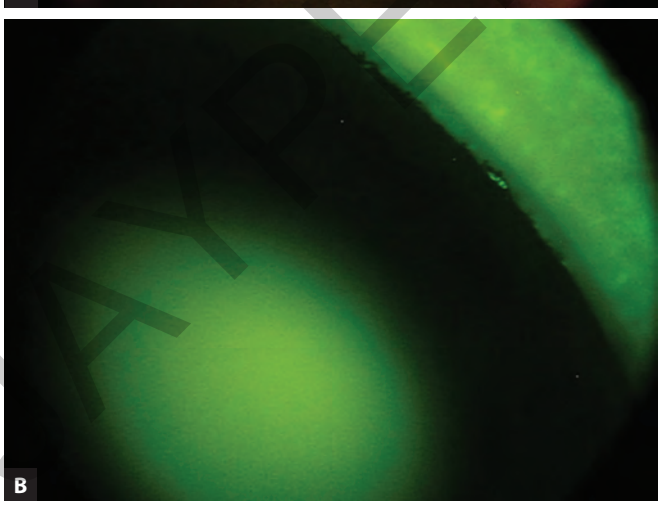

Figs 27.19A and B: RetCam goniophotograph does not show neovascularization at angle (A) while RetCam gonio-angiography shows leaks at iris root suggesting early neovascularization (B) (*Photo Courtesy: Dr Tarun Arora*)

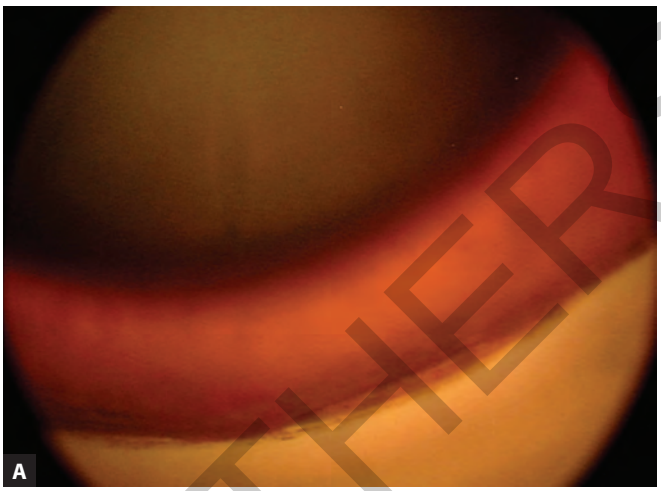



Figs 27.20A and B: RetCam goniophotograph shows neovascularization at angle with partial angle closure (A) and RetCam gonio-angiography shows leaks at iris root (B) (*Photo Courtesy: Dr Tarun Arora*)

technician can acquire images for each RetCam application. Then, the images can be either evaluated locally or send remotely for evaluation by a clinician. The imaging system is designed to enable tele-ophthalmology applications via the internet.

In a study comparing these two modalities Perera et al.[1] found that the agreement between RetCam and gonioscopy in detecting closed quadrants in superior, inferior, nasal and temporal quadrants based on ACI statistics was 0.73, 0.75, 0.76 and 0.72 respectively. RetCam had 76% sensitivity and 81% specificity for detecting the eyes with angle closure, using the current two quadrant definition of angle closure. Another study done by Sihota R et al.[2] compared gonioscopy in congenital glaucoma with RetCam anterior chamber visualization and found that the clarity and focus of angle view was better in RetCam versus indirect gonioscopy, 77.5% versus 47.5%, respectively. They also found that the clarity with RetCam was maintained at high magnification while it was difficult with

JAYPEE BROTHERS

indirect gonioscopy. Arora T et al.[3] also performed gonioscopy, RetCam gonio-photography and RetCam gonio-angiography to look for early angle neovascularization in severe/very severe NPDR and PDR and found that the yield of neovascularization in angle was much higher using RetCam gonio-angiography **(Figs 27.19 and 27.20)**. Although, the RetCam is as yet unable to provide quantitative measurements of anterior chamber depth like the ASOCT or the UBM, it provides a 360° visualization of the entire anterior chamber angle compared with the ASOCT and UBM which provide only cross-sectional views.

The device has some limitations. The imaging of anterior chamber angle using RetCam takes longer than gonioscopy, about 5 to 10 minutes per eye. The device is very expensive and additional space is required for supine examination. Imaging in the supine position may widen the angle due to effect of gravity with posterior shifting of the lens-iris diaphragm. The light source from the RetCam delivered by a fiberoptic cable may cause pupillary constriction, artificially altering the anterior chamber angle configuration. Unlike with dynamic gonioscopy, it is difficult to discern the presence of peripheral anterior synechiae, due to the inability to indent the angle while performing RetCam imaging. Similarly, determination of iris configuration is difficult in two-dimensional view of RetCam. Reproducibility may also be compromised as with repeat imaging each photograph may be slightly rotated and images may not be obtained over the exact same location.

REFERENCES

1. Quek DT, Nongpiur ME, Perera SA, Aung T. Angle imaging: advances and challenges. Indian J Ophthalmol. 2011;59 (Suppl):S69-75. doi: 10.4103/0301-4738.73699. Review. PubMed PMID: 21150037; PubMed Central PMCID: PMC3038508.
2. Azad RV, Chandra P, Chandra A, Gupta A, Gupta V, Sihota R. Comparative evaluation of RetCam versus gonioscopy images in congenital glaucoma. Indian J Ophthalmol. 2014;62(2):163-6. doi: 10.4103/0301-4738.116487. PubMed PMID:24008788; PubMed Central PMCID: PMC4005231.
3. Azad R, Arora T, Sihota R, Chandra P, Mahajan D, Sain S, Sharma Y. RetCam fluorescein gonioangiography: a new modality for early detection of angle neovascularization in diabetic retinopathy. Retina. 2013;33(9):1902-7. doi: 10.1097/IAE.0b013e318285cdd6. PubMed PMID: 23584699.

JAYPEE BROTHERS

for detailed information on ophthalmology books, visit our website **www.jaypeebrothers.com,** for detailed information on ophthalmology books, visit our website **www.jaypeebr**

Gonioscopy
A Text and Atlas

Salient Features

A Comprehensive Text and Atlas on Gonioscopy including:

- Over 600 goniophotographs
- Principle, indications, techniques, classification and types of gonioscopes
- Dynamic gonioscopy
- Normal gonioanatomy and developmental anomalies
- Angle closure and open angle forms of glaucoma
- Intraoperative gonioscopy
- RetCam gonioscopy
- Gonioscopy after glaucoma surgery
- Tumors, foreign bodies, surgical complications and systemic diseases
- Self-assessment questionnaire.

Tanuj Dada MD MAMS is Professor of Ophthalmology, Dr Rajendra Prasad Centre for Ophthalmic Sciences, All India Institute of Medical Sciences, New Delhi, India. He has authored 5 textbooks on glaucoma and has over 250 research publications in peer-reviewed indexed journals. He is also Secretary General of the International Society of Glaucoma Surgery, Co-Chair of the Associate Advisory Board and Education Committee of the World Glaucoma Association, and serves on the Board of Directors of the Asia-Pacific Glaucoma Society. He is the Editor-in-Chief of *Journal of Current Glaucoma Practice* and an Associate Editor of *Journal of Glaucoma*.



Talvir Sidhu MD is currently working as a Senior Resident and PhD Scholar in Dr Rajendra Prasad Centre for Ophthalmic Sciences, All India Institute of Medical Sciences, New Delhi, India. She completed her graduation and postgraduation from All India Institute of Medical Sciences, New Delhi. She has 10 indexed publications, 7 chapters in ophthalmology books and has published an educational video course on gonioscopy.



International Contributors



Keith Barton
London



Mermoud André
Switzerland



Michael Coote
Australia



Shamira Perera
Singapore



Chelvin Sng
Singapore

Available at all medical bookstores
or buy online at www.jaypeebrothers.com

JAYPEE BROTHERS
Medical Publishers (P) Ltd.
www.jaypeebrothers.com

Join us on facebook.com/JaypeeMedicalPublishers

Shelving Recommendation
OPHTHALMOLOGY

ISBN 978-93-5270-152-0