rmation on paediatric books, visit our website www.jaypeebrothers.com, for detailed information on paediatric books, visit our website www.jaypeebrothers.com






Hutchison's Atlas of Paediatric PHYSICAL DIAGNOSIS

SECOND EDITION

Editors
Krishna M Goel
Robert Carachi

Foreword
Neena Modi

JAYPEE

Contents

1. **Paediatric History and Examination** 1
Krishna M. Goel, Robert Carachi

2. **Growth and Development** 26
Louis C.K. Low

3. **Neonatal Medicine** 36
Elaine M. Balmer, Suzie Wills, Helen Mactier

4. **Paediatric Genetics** 75
Margo L. Whiteford

5. **Disturbances of Nutrition** 90
Krishna M. Goel

6. **Respiratory Disorders** 102
Anne Margaret Devenny

7. **Gastroenterology and Hepatology** 124
Krishna M. Goel, Robert Carachi

8. **Paediatric Cardiology** 151
Trevor Richens

9. **Paediatric Surgery** 177
Mairi Steven, Robert Carachi

10. **Dermatology** 208
Ram Gulati, Catherine Jury, Mary Mealyea

11. **Haematological Disorders** 247
Krishna M. Goel

12. **Paediatric Rheumatology** 270
Paul Galea, Krishna M. Goel

13. **Urinary System** 289
R. Cameron Shepherd, Salvatore Cascio

14A. **Diseases of the Nervous System** 315
P.D. Moses, M. Thomas, B. Koshy, S. Muthusamy, S. Yoganathan

14B. **Neurosurgical Diseases of the Nervous System** 370
Roddy O'Kane, Maya Kommer

15. **Accidental Poisoning in Childhood** 386
Krishna M. Goel

16. **Metabolic Diseases** 397
Peter Galloway, Rajeev Srivastava

17. **Endocrine Disorders** 422
Louis C.K. Low

18. **Paediatric Orthopaedics** 444
Benjamin Joseph

19. **Paediatric Dentistry** 466
Richard Welbury, Alison M. Cairns

20. **Immunity and Allergy** 488
Rosemary Anne Hague

21. **Infectious Diseases** 507
Jugesh Chhatwal, Daniel Reid, Ian W. Pinkerton

22. **Paediatric Ophthalmology** 547
Sarada David, Kirsteen J. Thompson, Gordon N. Dutton, Richard Bowman

23. **Haematological Investigations in Children** 579
Christina Halsey, Elizabeth A. Chalmers

24. **Biochemical and Microbiological Investigations in Paediatrics** 592
Peter Galloway, Alison E Balfour

25. **Paediatric Emergencies** 599
Sarah Coles, Andrew Carachi

26. **Paediatric Otolaryngology** 627
W. Andrew Clement, Ameet Kishore

27. **Paediatric and Adolescent Gynaecology** 650
Kevin P. Hanretty, Paul L. Wood

28. **Disorders of Emotion and Behaviour** 658
Michael Morton, David James

29. **Paediatric Radiology** 677
Sanjay V. Maroo, Sandra J. Butler

30. **Prescribing for Children** 742
James Wallace

31. **Child Abuse and Neglect—How do we Protect these Children?** 749
Jean Herbison

32. **Paediatric Rehabilitation** 786
Judy Ann John, Lydia Edward Raj, Debbie Skeil

33. Paediatric Maxillofacial Surgery **816**
Khursheed F. Moos

34. Paediatric Reconstruction Surgery **839**
Martyn H.C. Webster

35. Practical Paediatric Procedures **851**
Alastair Turner, Robert Carachi, Krishna M. Goel

36. A Prescription for Play **883**
Phyllis Kilbourn, Rosemary Sabatino

37. Nutrition Assessment **896**
Mona Basker, N.V. Mahendri

38. Surgical Oncology **903**
Philip Hammond

39. Paediatric Podiatry **907**
Gordon F. Watt, Stewart C. Morrison, Krishna M. Goel

Appendices **927**

Index *939*

CHAPTER 3

Neonatal Medicine

Elaine M. Balmer, Suzie Wills, Helen Mactier

JAYPEE BROTHERS

INTRODUCTION

The neonatal period covers birth through the first 28 days of life. Conditions presenting in the neonatal period may conveniently be divided into those conditions affecting all infants regardless of gestation and complications specific to preterm birth. The relative importance of each category for the workload of a neonatal unit will depend on geographical location and local (or national) arrangements for provision of neonatal care.

Preterm birth is defined as birth before 37 completed weeks of gestation, with gestation defined traditionally from the first date of the last menstrual period and thus more strictly described as menstrual age.[1] With advent of near-universal ultrasound dating of early and/or mid-pregnancy, gestation is fairly certain for the vast majority of women, at least in developed countries; when gestation is in doubt, reasonably accurate clinical assessment of gestation may be made by a combination of external appearance and muscular tone and positioning, according to predefined criteria **(Fig. 3.1)**.[2]

Neonatal mortality and morbidity follow a U-shaped curve and are increased for both preterm and post-mature (delivered after 42 completed weeks' gestation) babies.[3] Induction of labour after 40 weeks' gestation reduces the risk of perinatal death, although the absolute risk is very low [number needed to treat, 410].[4] Both preterm and post-term birth are associated with behavioural and emotional problems in early childhood, especially attention deficit/hyperactivity problem behaviour but the mechanism of this, particularly for post-mature infants, remains to be elucidated.[5]



Figure 3.1 Clinical assessment of gestation.

Several terms are used to describe pregnancy outcome, national health and the outcome of neonatal care:

Infant mortality = number of deaths before 1 year of age per 1,000 liveborn children

Perinatal mortality = number of still births and deaths within the first 7 days per 1,000 total births

Neonatal mortality = number of deaths in the first 28 days of life per 1,000 live births. Neonatal mortality can be divided into early (≤7 days) and late (8–28 days) mortality, but these differences have become blurred which promotes longer survival of the sickest and most pre-term infants.

In utero growth is determined by many factors, including maternal health and nutritional status as well as hypertension, cigarette smoking and/or substance misuse. Foetal growth can be compromised by intrauterine infection, e.g. rubella or toxoplasmosis, chromosomal abnormality and multiple pregnancy. Low birth weight is defined by the World Health Organization as less than 2,500 g at birth regardless of gestation, and needs to be distinguished from intrauterine growth restriction (IUGR) (failure to achieve genetic growth potential) and small for gestational age (birth weight below the 10th percentile for gestational age). Since birth weight is influenced by maternal stature and ethnicity, foetal growth is best assessed by use of customised birth weight charts.[6] Postnatal growth should be assessed by use of the WHO growth charts, which were updated in 2006 following the WHO Multicentre Growth Reference



Figure 3.2 Symmetrical intrauterine growth restriction.



Figure 3.3 Asymmetrical intrauterine growth restriction.

Study implemented between 1997 and 2003.[7] For infants born before completing 37 weeks' gestation, birth weight and subsequent growth should be plotted on a preterm growth chart, such as the UK-WHO Neonatal and Infant Close Monitoring Chart, appropriate to the infant's sex **(Figs. 3.2 to 3.4)**.[8]

GENERAL ASSESSMENT OF THE NEWBORN

Examination of a newborn infant can conveniently be divided into immediate post-birth assessment and the routine examination of the newborn.

Post-birth Examination

Examination of the infant immediately after delivery should assess if resuscitation is required and ascertain if there are any factors likely to have immediate consequences for the infant such as significant prematurity or major congenital abnormality. The eponym Apgar score was first described in 1953 as an objective means of assessing the condition of the newborn[9]; although now commonly replaced by a simplified assessment of heart rate, breathing, tone and colour,[10] the Apgar score remains useful in indicating the severity of distress at birth and in predicting longer-term outcome.[11] On an individual basis, however, the infant's condition at birth is of limited prognostic value and outcome is more related to response to resuscitation and the subsequent neonatal course.

Heart rate at birth can be assessed either with a stethoscope or by palpating for a pulse at the base of the umbilical cord; absence of a palpable pulse should be confirmed by auscultation. Infants who are pink with a heart rate above 100 beats per minute and who are breathing regularly do not need active intervention, nor suctioning of the airway. They should be dried and, whenever possible, given to their mother for skin-to-skin contact and initiation of breastfeeding. If the infant has not established spontaneous respiration, or if the infant remains blue and/or bradycardia persists, then basic resuscitation should be commenced (vide infra).

Routine Examination of the Newborn

This clinical assessment should include top-to-toe physical examination, with particular emphasis on auscultation of the heart, palpation of the abdomen and examination of the eyes, genitalia and hips. Routine examination of the newborn may be undertaken by any suitably trained person, including midwife or doctor, and affords an opportunity to enquire about familial conditions likely to have implications for the newborn and to offer support to new parents. It is ideally conducted before 72 hours of life.[12]

TABLE 3.1 The Apgar scoring system.[6]

Score	*0*	*1*	*2*
Heart rate (beats per minute)	0	<100	>100
Respiratory rate	Absent	Slow, irregular, weak cry	Good, vigorous cry
Muscle tone	Flaccid, limp	Some flexion of extremities	Good flexion, active motion
Reflex irritability	No response	Weak cry and grimace	Vigorous cry, cough, sneeze
Skin colour	Blue	Acrocyanosis	Pink

JAYPEE BROTHERS

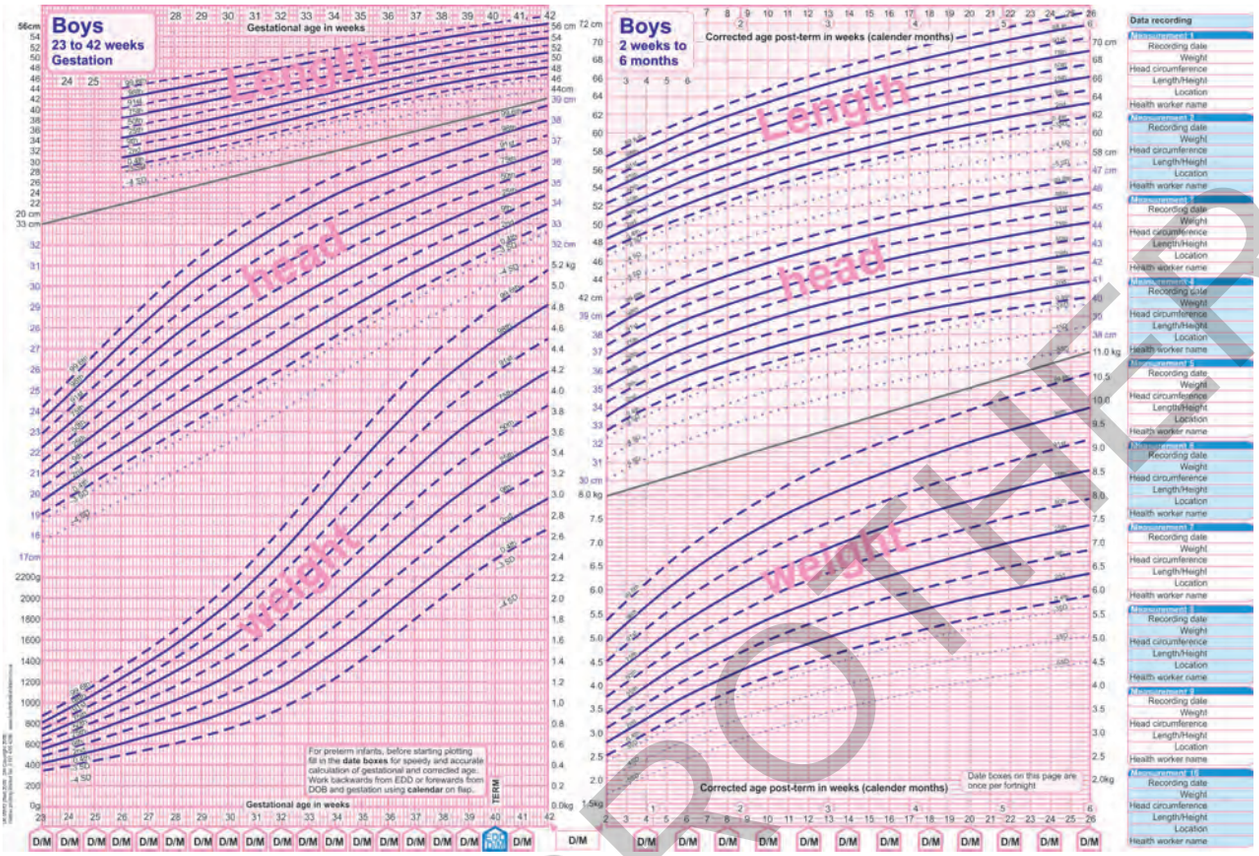



Figure 3.4 Growth chart—UK-WHO Neonatal and Infant Close Monitoring Chart.

JAYPEE BROTHERS



Figure 3.5 Caput succedaneum.



Figure 3.6 Bilateral cephalhaematoma.



Figure 3.7 Foetal alcohol syndrome.

Although full clinical examination will require that the infant is naked, it is important that the infant is as quiet as possible, and so it is often useful to auscultate the heart sounds and check the red reflexes before the infant is disturbed by being fully undressed.

Scalp

Head shape should be noted, and the head circumference measured and plotted on a standardised, sex-specific growth chart. The anterior fontanelle should be patent; the posterior fontanelle is also commonly palpable in the newborn. Some skull moulding is usual after a vaginal delivery; caput succedaneum is a serosanguinous, subcutaneous, extraperiosteal fluid collection with poorly defined margins caused by pressure of the presenting part of the scalp against the dilating cervix. Caput succedaneum extends across the midline, crossing over suture lines, and usually resolves within a few days **(Fig. 3.5)**.

Cephalhaematoma results from bleeding between the skull and the periosteum, generally in the parietal region and usually associated with prolonged or instrumental delivery. Cephalhaematoma may be bilateral; the swelling does not cross the suture lines **(Fig. 3.6)**. An underlying associated skull fracture is rare. Resolution of a cephalhaematoma may take several weeks as the blood clot is absorbed from the periphery towards the centre, and parents should be counselled that the swelling will harden, leaving a slightly softer area in the centre. Early and exaggerated neonatal jaundice is a common consequence.

A chignon may be evident in infants delivered by vacuum extraction. This should resolve within a few hours to several days. Rarely, vacuum extraction may be complicated by subaponeurotic haemorrhage.

Face and Mouth

The overall appearance of the face may be indicative of congenital abnormality, and this should be described in terms of the specific features, e.g. hypertelorism, low set ears, long thin philtrum. Sometimes, a constellation of features will point to a specific diagnosis, such as Down or Alpert syndrome, or may suggest exposure to a single teratogen such as alcohol or sodium valproate **(Fig. 3.7)**. When the appearance of the infant is unusual and no immediate diagnosis comes to mind, comparison should be made with both parents.

Cleft lip (cheiloschisis) will be immediately evident; cleft palate (palatoschisis) can only be excluded after direct visual inspection of the palate **(Fig. 3.8)**.

Epstein pearls, or palatal cysts of the newborn, are small (1–3 mm) white or yellow cystic vesicles commonly seen in the median palatal raphe of the mouth. They will resolve spontaneously over the first few weeks of life.

Natal teeth may be present and will require to be removed; if not securely fixed within the gum, this should be undertaken as soon as possible **(Fig. 3.9)**.

JAYPEE BROTHERS



Figure 3.8 Bilateral cleft lip.



Figure 3.9 Natal teeth.



Figure 3.10 Ranula. (*See* Fig. 19.52.)



Figure 3.11 Cloudy corneas.

(*Source:* Baiyeroju A, Bowman R, Gilbert C, et al. Managing eye health in young children. Community Eye Health. 2010;23(72):4-11.)



Figure 3.12 Dilated pupil with cataract visible as a black shadow obstructing the red reflex.

(*Source:* Baiyeroju A, Bowman R, Gilbert C, et al. Managing eye health in young children. Community Eye Health. 2010;23(72):4-11.)

A ranula is a mucocele which is usually confined to the floor of the mouth. This swelling is benign, but will require surgical excision **(Fig. 3.10)**.

Eyes

Subconjunctival haemorrhage is common and self-resolving; blue discolouration is associated with osteogenesis imperfecta. Yellow sclerae are indicative of significant neonatal jaundice (which may be difficult to assess in a dark-skinned infant) and should prompt measurement of serum bilirubin. Cloudy corneas suggest congenital glaucoma or inherited metabolic disorder **(Fig. 3.11)**.

It is essential that a red reflex is demonstrated in each eye to exclude cataract or retinoblastoma. Both of these conditions require prompt ophthalmology referral **(Fig. 3.12)**.

JAYPEE BROTHERS

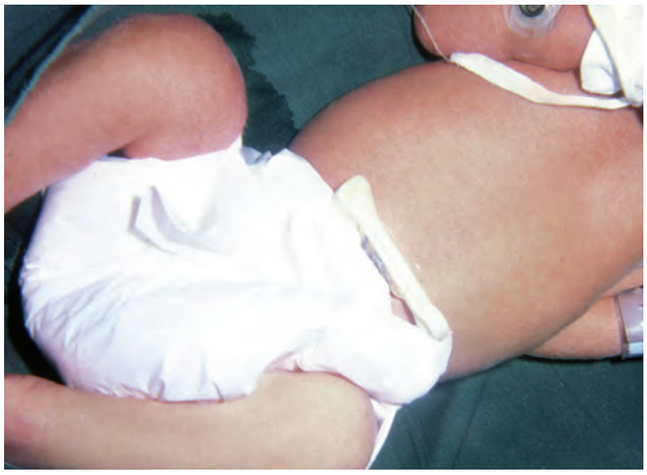

Figure 3.13 Harlequin colour change.



Figure 3.14 Erythema toxicum.



Figure 3.15 Salmon patch.

Skin

Physiological skin changes are commonly seen in the newborn, and may cause unnecessary alarm. Cutis marmorata describes a normal physiological response to cold with a characteristic bluish mottling seen on the extremities and trunk. Harlequin colour change is seen as a transient erythema involving one half of the infant's body with simultaneous blanching of the other side, strictly demarcated in the midline. This unusual vascular phenomenon is thought to be due to immaturity of the hypothalamic centre controlling dilation of peripheral blood vessels; it resolves with crying or movement and does not require treatment **(Fig. 3.13)**.

Milia are tiny white spots that occur on the faces of around 50% of newborn babies, most often on the nose and cheeks. They represent collections of secretions from immature sweat glands and will resolve spontaneously, usually by 1–2 months of age. Erythema toxicum is an extremely common rash that appears within the first few days of life, presenting as erythematous macules with white/yellow coloured vesicles. The vesicles contain eosinophils. Parents should be reassured that the rash will disappear and that no treatment is required **(Fig. 3.14)**.

Neonatal pustular melanosis presents at birth with small, flaccid, superficial fragile pustules. Commonly, some of the pustules will already have ruptured in utero, leaving pigmented macules. The macules tend to fade over 3–4 weeks. All areas of the body may be affected. This benign condition is more common in black-skinned infants; recognition is important to avoid unnecessary investigation and treatment.

Vascular naevi are due to abnormal blood vessels in the skin. They vary in severity and permanence; hence, accurate diagnosis is important. The most common of the vascular birthmarks, occurring in around 50% of newborns, are salmon patches or stork bites. These fine capillary haemangiomas are visible as flat, deep red areas on the eyelids, bridge of nose, upper lip and nape of neck, and tend to darken in colour when the baby cries. Most fade during the first 6–12 months, although areas on the nape of the neck may persist. No treatment is required **(Fig. 3.15)**.

Port-wine stains are large, flat, deep purple/red lesions, which may occur on any part of the body. The incidence is about 3 per 1,000 births; males and females and all racial groups are equally affected. The lesions are due to lack of small nerves that normally control constriction of blood vessels. Lesions appear dark pink, smooth and flat in the neonatal period, but become darker with thickening of the overlying skin as the child ages. Port-wine stains tend to affect only one side of the body, most commonly on the face and upper trunk **(Fig. 3.16)**. Lesions in the distribution of the trigeminal nerve may be associated with retinal and intracranial haemorrhages, and ophthalmological assessment is required. Associated vascular malformations of the ipsilateral meninges and cerebral cortex occur in Sturge-Weber syndrome, which may be complicated

JAYPEE BROTHERS



Figure 3.16 Port-wine stain.



Figure 3.17 Congenital melanocytic naevus.



Figure 3.18 Mongolian blue spot. (*See* Fig. 1.38.)

by seizures and neurological disability. Port-wine stains may be improved with laser treatment as an alternative to camouflage make-up.

Pigmented birthmarks include congenital melanocytic naevi, which occur in 1–6% of newborns.[13] These naevi can be present on any part of the body as circumscribed, light brown to black patches, heterogeneous in size and consistency. They may be hairy and tend to grow in proportion to the infant's growth. Larger melanocytic naevi have the potential to become malignant, and require regular dermatological review **(Fig. 3.17)**.

Mongolian blue spots are flat, bluish-coloured lesions representing a collection of melanocytes in the dermis. They are most commonly seen in the lumbosacral area in oriental and black infants and can be single or multiple. Mongolian blue spots tend to fade as the infant gets older; accurate documentation at birth can be useful if concerns are raised later regarding bruising injury. No treatment is necessary **(Fig. 3.18)**.

Cardiovascular System

Examination of the cardiovascular system begins with inspection, looking for respiratory distress and/or cyanosis. The apical impulse is normally felt in the fifth intercostal space in the mid-clavicular line, and both brachial and femoral pulses should be palpable. Difficulty feeling the femoral pulses should prompt urgent exclusion of coarctation of the aorta. The normal predominance of the right ventricle in the neonatal period may be evident as mild parasternal heave during the early hours of life, particularly if there is clinical evidence of persisting pulmonary hypertension. Thrills are unusual, and will be accompanied by a loud murmur. Murmurs are common in the first day or two of life, often reflecting delayed closure of the ductus arteriosus, and significant cardiac pathology may be present without a murmur. Oxygen saturation in a healthy term infant breathing room air should be greater than 90% by 10 minutes of age and above 94% by 24 hours of age; since lower saturations may not be clinically evident, routine post-ductal oxygen saturation monitoring as a means of early detection of congenital heart disease is becoming a recommended standard of care.[14] It should be noted that this test is considerably more costly than clinical examination alone, and that the cost effectiveness for an individual facility will depend, among other factors, on the rate of antenatal detection.

Respiratory System

The healthy newborn is an obligate nasal breather, and relies on diaphragmatic excursion for effective respiration. Normal respiration should be quiet, at a rate of 40to 60 breaths per minute. Tachypnoea may reflect respiratory disease, sepsis or systemic illness, and should never be ignored.

Abdomen

The abdomen should be soft, with no palpable masses. The liver is normally palpable 1 cm below the liver edge;

JAYPEE BROTHERS

hepatomegaly may be isolated or associated with splenomegaly (e.g. severe haemolysis, congenital infection, metabolic disease). Autosomal recessive polycystic kidney disease may present as bilateral masses. Divarication of the rectus abdominal muscles is a benign condition, which should improve with age; similarly, umbilical herniae will generally resolve spontaneously within the first year **(Fig. 3.19)**. Careful inspection of the anus is important, as rarely meconium may be passed through a rectovaginal fistula in female children with imperforate anus **(Figs. 3.20A and B)**.

Genitalia

In males, the scrotum may be enlarged due to a hydrocoele or inguinal hernia. The former will transilluminate (more easily visible in a darkened room) and is expected to resolve within the first few weeks **(Fig. 3.21)**.

An inguinal hernia should be reducible with gentle pressure; a tender and non-reducible groin swelling requires urgent surgical attention **(Fig. 3.22)**.



Figure 3.19 Umbilical hernia.

If neither testis can be felt in the scrotum or groin (and particularly if the penis is small or there is apparent hypospadias), urgent sex chromosomal analysis is indicated. Parents should be counselled not to name the child until the results are known **(Figs. 3.23A and B)**.

Unilateral undescended testis is not uncommon, particularly in preterm infants; the family should be advised to seek medical advice if both testes have not descended to the scrotum by 1 year of age. Pigmentation of the scrotum or labia is normal in babies whose parents are not white, but may be an early sign of congenital adrenal hyperplasia.

Hips

An important part of the newborn examination is screening for developmental dysplasia of the hip. Hips should abduct equally **(Fig. 3.24A)**, buttock and thigh creases **(Fig. 3.24B)** and leg length should be symmetrical. Leg length is best assessed by flexing the knees and placing the feet on a flat surface; the knees should be at an equal height. Ortolani manoeuvre will detect a congenitally dislocated hip; with the knees flexed at right angles, the hips should be slowly abducted from the midline position through 90° **(Fig. 3.24C)**. A dislocated hip will clunk back into place. If Ortolani test is negative, Barlow test should be performed to check for stability of the hip; with the hips and knees held flexed, gentle pressure is applied to front of the knee in an attempt to slide the femur backwards **(Fig. 3.24D)**. An unstable hip will dislocate out of the acetabulum. Babies with unstable hips should be referred for prompt orthopaedic assessment; the investigation of choice is ultrasound of the hips **(Figs. 3.25A and B)**.

Spine

The spine should be carefully examined to exclude any obvious deformity; hairy tufts or pits may be indicative of underlying spinal deficits. Spina bifida may present as either a closed or an open lesion; the clinical effects will depend on the site and extent of the lesion. Spina bifida

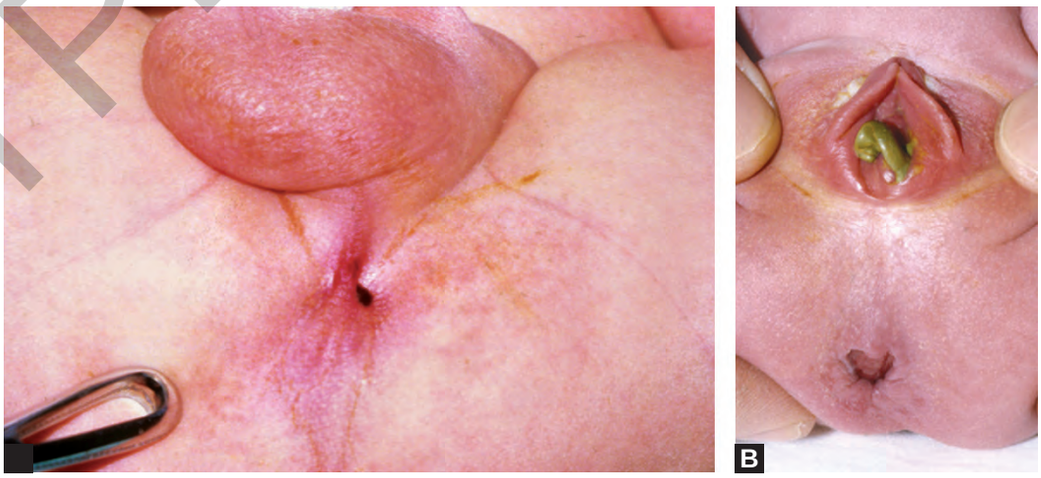

Figures 3.20A and B (A) Imperforate anus; (B) Imperforate anus with rectovaginal fistula.

JAYPEE BROTHERS

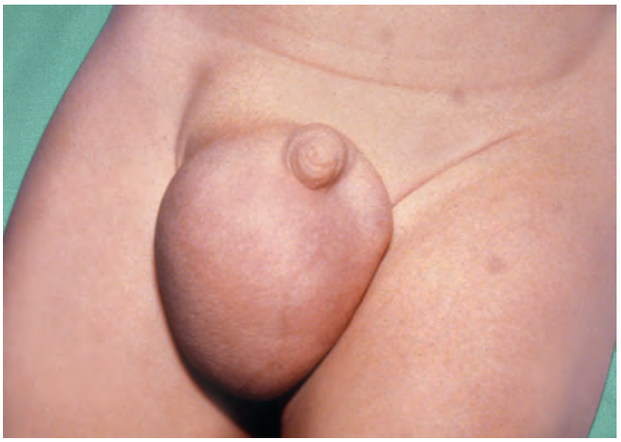

Figure 3.21 Hydrocoele.



Figure 3.22 Inguinal hernia.

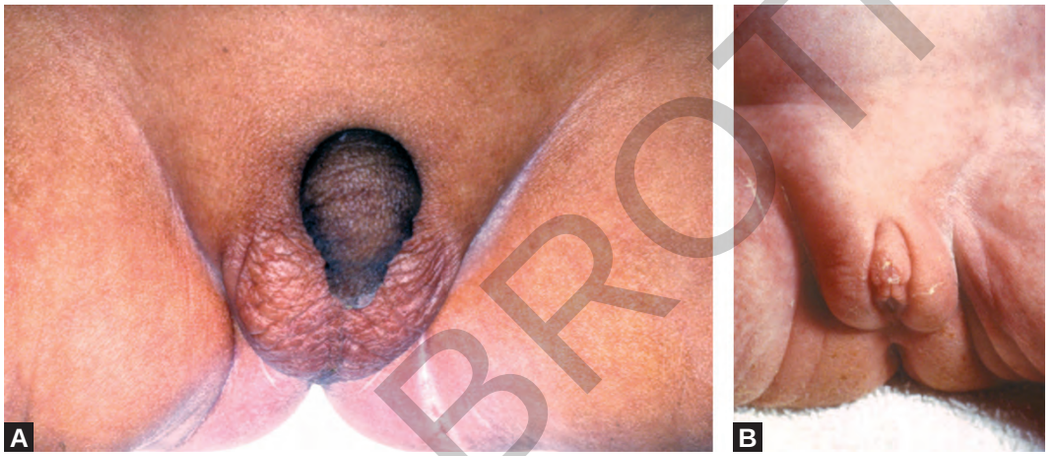

Figures 3.23A and B Ambiguous genitalia.

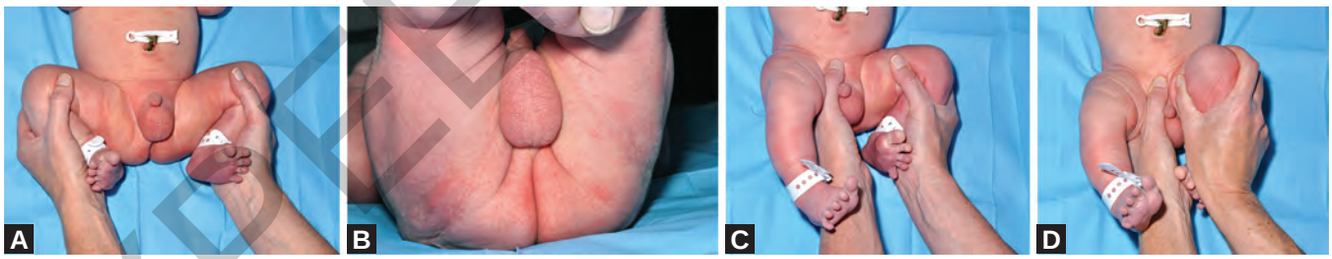

Figures 3.24A to D Clinical examination of hips.

occulta indicates a defect in the vertebral arch with an intact spinal cord and meninges. More extensive lesions may be indicated by an overlying patch of hair or other skin abnormality, and can be complicated by tethering of the spinal cord during childhood. In meningocele, there is herniation of the meninges through the bony defect in the spine and the lesion is covered with skin. Surgery is required but, since the spinal cord is spared, prognosis is usually good **(Fig. 3.26)**.

The situation is worse in myelomeningocele—spinal cord involvement leads to complications including lower limb paralysis, hydrocephalus, neuropathic bladder and bowel and kyphoscoliosis. The lesion is usually closed as soon as possible after birth to minimise the risk of infection, and long-term multidisciplinary management will be required **(Fig. 3.27)**.

Primitive Reflexes

The healthy term newborn will exhibit a flexed posture, and have periods of quiet wakefulness. Several primitive reflexes will be present from birth, gradually disappearing with the progress of normal development.

JAYPEE BROTHERS

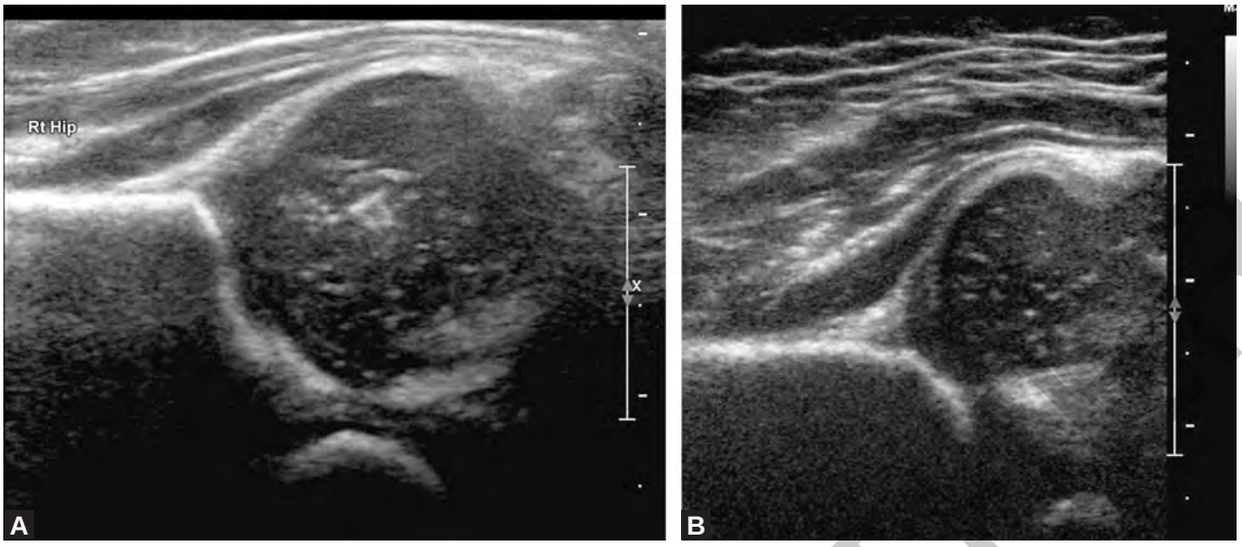

Figures 25A and B Hip ultrasound. (A) Normal right hip; (B) Decentred right hip.



Figure 3.26 Meningocele.

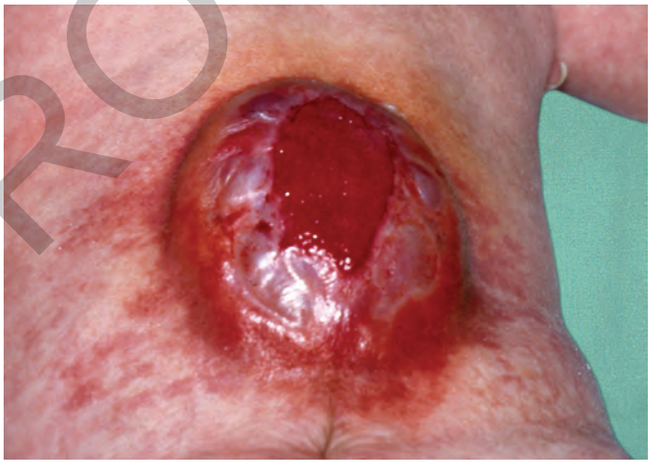

Figure 3.27 Myelomeningocele.



Figure 3.28 Moro response.

The Moro response, or embracing reflex, was described by Ernst Moro in 1918.[15] This reflex is present at birth, peaks in the first month of life, and generally disappears around 3 months of age. It is elicited by a sudden shift in position of the infant's head, generally by allowing the head to fall backwards while supporting the body. The legs and head extend and the arms jerk up and out with palms up and thumbs flexed before being brought together. The infant will then generally clench his hands and cry. Bilateral absence of the Moro response indicates damage to the central nervous system, while a unilateral absence suggests either a fractured clavicle or injury to the brachial plexus. It is postulated that in human evolution, the Moro reflex helped the infant cling to his mother while she carried him around all day by providing a reflex grasping onto his mother if the infant slipped **(Fig. 3.28)**.

JAYPEE BROTHERS



Figure 3.29 Rooting reflex.



Figure 3.30 Stepping reflex.



Figure 3.31 Palmar grasp.



Figure 3.32 Positive Babinski sign.

The sucking and rooting reflexes also help the infant to survive by facilitating breastfeeding. The rooting reflex causes the newborn infant to turn his head towards anything that strokes his cheek or mouth; it disappears by 4 months of age, long after the breastfed infant has learned how to find his mother's nipple **(Fig. 3.29)**.

When a newborn baby's feet are placed on a flat surface, he/she will instinctively put one foot in front of the other, thus appearing to walk, even though he cannot support his/her own weight. This primitive stepping reflex is short-lived, disappearing by around 6 weeks of age. It subsequently reappears as a voluntary action towards 1 year of age, prior to independent walking **(Fig. 3.30)**.

The palmar grasp reflex is also present at birth and persists until 5 or 6 months of age. Grasping is elicited by either stroking the palm or placing an object into the infant's palm. The grasp is strong, but unpredictable in that it may be suddenly released. Stroking the back of the infant's clenched fist will induce opening of the hand **(Fig. 3.31)**.

Reflecting immaturity of the corticospinal tracts, stroking the plantar surface of the foot in a newborn will elicit an extensor response or positive Babinski sign. This will be replaced by a flexor response by the age of 2 years **(Fig. 3.32)**.

The other primitive reflex present at birth is the Galant reflex. This is elicited by stroking the skin along the side of the infant's back, following which he/she will swing towards the side that was stroked. This reflex disappears by 6 months of age. The tonic (or asymmetric) neck reflex is usually present between 1 and 4 months of age. When the child's head is turned to the side, the arm on that side will straighten and the opposite arm will bend, in the position of a fencer. Persistence of the reflex beyond 6 months suggests upper motor neuron dysfunction. The tonic neck reflex is thought to have an evolutionary function in preparing the infant for voluntary reaching **(Fig. 3.33)**.

CONGENITAL ABNORMALITIES

Congenital abnormalities may result from a multitude of causes. Chromosomal non-disjunction during meiosis may result in either too many or too few chromosomes; common examples include trisomy 21 (Down syndrome)

JAYPEE BROTHERS



Figure 3.33 Tonic neck reflex.



Figure 3.34 Down syndrome.
(*Courtesy:* Image courtesy of Down Syndrome, Scotland.)



Figure 3.35 Edward syndrome facies.

and 45,XO (Turner syndrome). Partial deletion of a chromosome may occur (e.g. 1q21.1 deletion syndrome or 7q11 deletion William syndrome) or additional chromosomal material may be inherited (e.g. 22q11 duplication). Damage may occur to the developing embryo, either unexplained or as a result of vascular accident (e.g. transposition of the great arteries, holoprosencephaly, isolated limb abnormalities), or the developing embryo or foetus may be affected by an infectious organism [e.g. *Cytomegalovirus* (CMV)] or by toxins such as alcohol or prescription drugs (e.g. retinoic acid, sodium valproate). Single gene defects will manifest in one in four children born to apparently healthy parents who are asymptomatic carriers; the homozygous state occurs more commonly with consanguineous parents. Generally speaking, the earlier in pregnancy the insult occurs, the more devastating the consequences in terms of structural abnormality.

Whole Chromosomal Addition or Deletion

The most common three trisomies presenting at birth are 21 (Down syndrome), 18 (Edward syndrome), and 13 (Patau syndrome). These conditions are more common in older mothers, and are increasingly diagnosed by antenatal screening, with termination of pregnancy an option for affected pregnancies. The prognosis varies, being worse for trisomy 13 and 18, the majority of whom die within the first year.

Down Syndrome

Described by John Langdon Down in 1866, trisomy 21 is the most common genetic condition in human. Affected individuals have a typical facies, with epicanthic folds, flat nasal bridge, protruding tongue and low set ears with brachycephaly. Other common features include hypotonia, clinodactyly, sandal gap, and Brushfield spots. The incidence of congenital heart disease is up to 50%, with atrioventricular or ventricular septal defects most common. Learning disability is universal, ranging from mild to moderate and is reflected in delayed gross motor and speech development. Weight gain may be problematic in the neonatal period because of poor feeding, but obesity is common in later life. All children with Down syndrome will manifest stunted longitudinal growth, with final adult height averaging 154 cm for males and 144 cm for females. Specialised growth charts are available for children with Down syndrome and for some other genetic conditions **(Fig. 3.34)**.[16]

Edward Syndrome

The association of IUGR, congenital heart disease (most commonly septal defects with or without patent ductus arteriosus), micrognathia, cleft lip and/or cleft palate, hypertelorism, webbed toes, rocker bottom feet and cryptorchidism is suggestive of trisomy 18 **(Fig. 3.35)**. Affected children show a typical clenching of the hand

JAYPEE BROTHERS

for detailed information on paediatric books, visit our website www.jaypeebrothers.com, for detailed information on paediatric books, visit our website www.jaype

Hutchison's Atlas of Paediatric PHYSICAL DIAGNOSIS

This atlas has been designed to be used by paediatricians at whatever stage of training and experience they are but in particular, it should assist those taking postgraduate examinations in the specialty. For many paediatric conditions, a pictorial representation is a significant factor in making the correct diagnosis. In this comprehensive work of thirty nine chapters every paediatric subspecialty is included.

This well-illustrated comprehensive volume with coloured high quality clinical photographs provides an extensive practical view of paediatric diseases, both medical and surgical. In this edition every chapter has been revised, reviewed and updated. One new chapter on Paediatric Podiatry has been included and sections on surgical urology and neurosurgery have been incorporated. Also the new images have been added. Additional contributors have added greater depth and knowledge to the Atlas. Key learning points with bullet pointed lists provide guidance to vital issues, giving it an advantage over many of the more discursive texts previously available. Case studies enhance the text and root it into the context of clinical practice.

The diverse authorship of the 39 chapters in the atlas reflects the specialist interests now required to provide a comprehensive view of paediatric disease, to do this 64 authors from 7 countries who have contributed to the text.

Available at all medical bookstores
or buy online at www.jaypeebrothers.com

JAYPEE BROTHERS
Medical Publishers (P) Ltd.
www.jaypeebrothers.com

Join us on facebook.com/JaypeeMedicalPublishers

Shelving Recommendation
PAEDIATRICS

ISBN 978-93-5270-159-9