ebrothers.com, for detailed information on anesthesia books, visit our website www.jaypeebrothers.com, for detailed information on anesthesia books

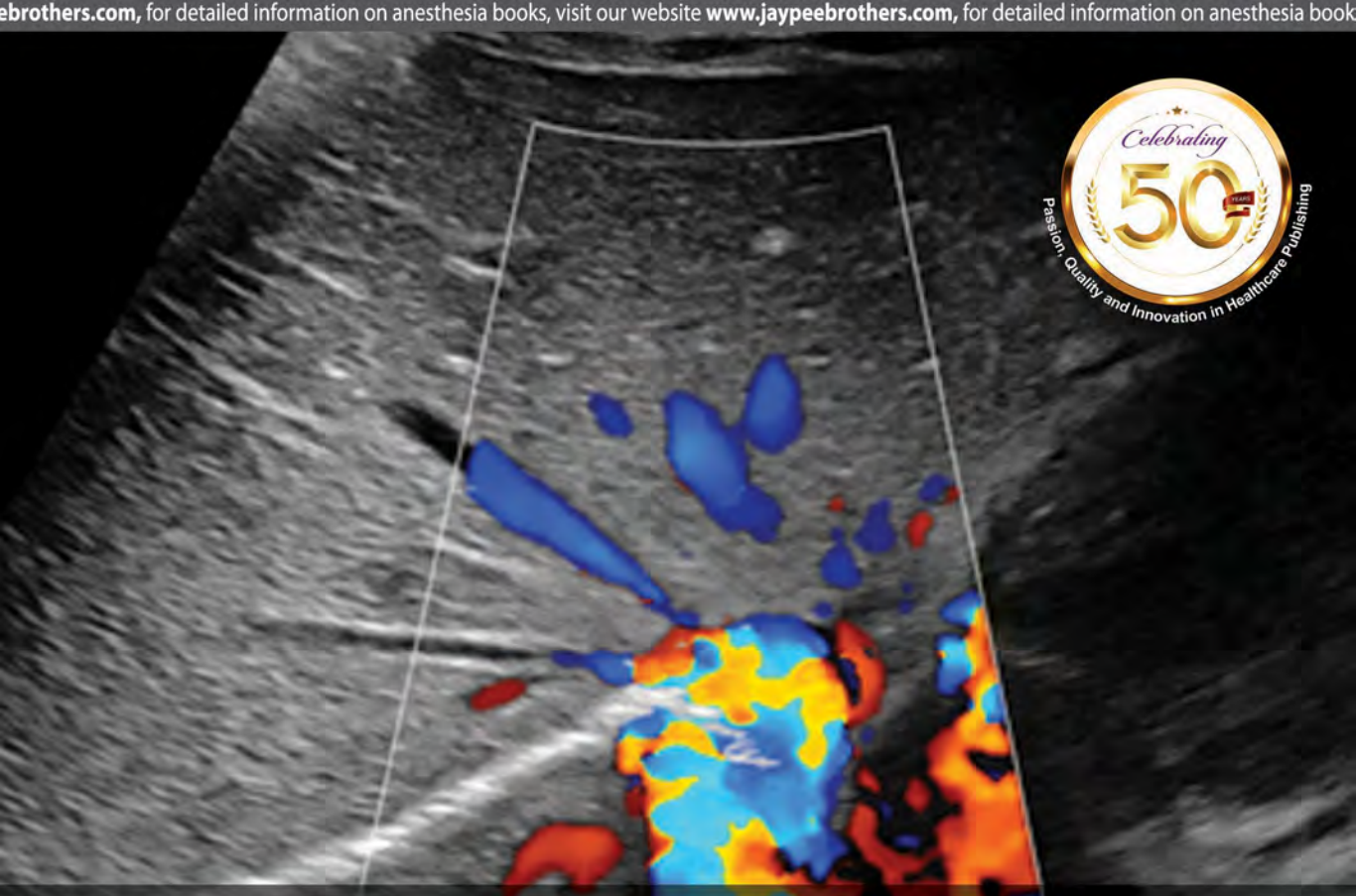

Ultrasound in Critical Care

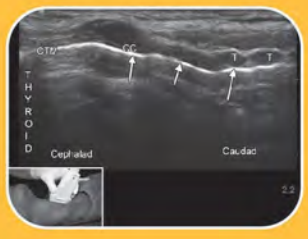





Puneet Khanna

Foreword
Colin Royse

JAYPEE

Contents

1A. Point of Care Ultrasound 1
Puneet Khanna, Shakshi Gera, Rashmi Bhatt
- Characteristics of POCUS *1*
- History of POCUS *1*
- Who uses POCUS? *1*
- How to Use POCUS *2*
- POCUS in Medical Education *6*
- Limitations *6*

1B. Applications in Critical Care Medicine 10
Arvind Kumar, Manish Soneja
- Head and Neck including Subclavian Vein *10*
- Ultrasonography of the Airway *13*
- Utility of Chest Sonography in Critical Care *13*
- Echocardiography in the Critical Care Ward *19*
- Basic Views in Critical Care *19*
- Assessment of Ventricular Function *20*
- Measurement of Cardiac Output *21*
- Measurement of Chamber Pressures *22*
- Assessment of Hypovolemia *22*
- The Hypotensive Patient *22*
- Deep Vein Thrombosis *23*
- Abdominal Ultrasound *25*

1C. Should Intensivist do the Ultrasonography: Guidelines, Qualification, Experience and Training? 31
Shailaja Behera, Puneet Khanna
- Training and Accreditation *31*

2A. Basic Physics of Ultrasound and the Doppler Phenomenon 34
Devasenathipathy Kandasamy, Ananya Panda
- Overview *34*
- Properties of Ultrasound *34*
- Basic Ultrasound Instrumentation *37*
- Safety Considerations *38*

2B. Modes of Ultrasonography 39
Devasenathipathy Kandasamy, Ananya Panda
- Overview *39*
- A-Mode (Amplitude-Mode) Imaging *39*
- M-Mode (Motion-Mode) Imaging *40*
- B-Mode (Brightness-Mode) Imaging *40*
- Image Resolution *43*
- Image Optimization *44*
- Ultrasound Artifacts *47*

2C. Doppler Imaging 51
Devasenathipathy Kandasamy, Ananya Panda
- Overview *51*
- The Doppler Principle *51*
- Modes of Doppler Imaging *51*
- Setting up and Optimizing Doppler Images *54*

3. Ultrasound for Vascular Access 57
Akhil Kant Singh, Karthic Iyer
- History of Central Venous Access *57*
- The Evidence *58*
- General Considerations *58*
- The Procedure *60*
- After the Procedure 65

4A. Airway Ultrasound 68
Bikash Ranjan Ray
- Advantage of Ultrasound Imaging of Upper Airway *68*
- Challenges of Airway Imaging *68*
- Airway Anatomy: What Does Ultrasound Reveal? *68*
- Ultrasound Imaging of Airway *70*
- Clinical Application of Upper Airway Ultrasound *74*
- Future Aspects *79*

4B. Ultrasound-guided Percutaneous Dilatational Tracheostomy and Cricothyrotomy 82
Sulagna Bhattacharjee, Souvik Maitra
- Ultrasonographic Anatomy of Neck *83*
- Techniques *83*
- Confirmation of Placement *86*
- Complications *87*
- Ultrasound-guided Cricothyrotomy *87*

- Cricothyrotomy Technique *87*
- Role of Ultrasound in Cricothyrotomy *88*
- The Transverse TACA Technique (Thyroid Cartilage-Airline-Cricoid Cartilage-Airline) *88*
- The Longitudinal "String of Pearl" Technique *89*
- Which Technique to Follow? *89*
- Complications *89*

5. Lung Ultrasound 93
Soumya Ray
- Overview *93*
- History *93*
- Equipment for Lung Ultrasound *93*
- How to Perform Lung Ultrasound? *94*
- Lung Ultrasound in Intensive Care Unit 105
- Limitations of Lung Ultrasound *108*

6. Chest Ultrasound in Acute Respiratory Distress Syndrome 110
Shyam Madabhushi, Puneet Khanna
- Lung Morphology in Acute Respiratory Distress Syndrome *110*
- Differentiating Acute Respiratory Distress Syndrome from other Causes of Respiratory Failure *111*
- Lung Ultrasound and Extravascular Lung Water *111*
- Prognosis of Acute Respiratory Distress Syndrome Determined by Ultrasound *111*

7. Ultrasonography in Cardiac Evaluation 115
Sarvesh Pal Singh, Sonali Bansal
- Indications for Performing Echocardiography in the Critically Ill Patient *115*
- Advantages and Disadvantages of Echocardiography in the Intensive Care Unit *116*
- General Points *116*
- Common Transthoracic Echocardiography Views for Intensive Care Unit *117*
- Assessment of Ventricular Function *122*
- Assessment of Systolic Function of Left Ventricle *123*
- Assessment of Diastolic Function of Left Ventricle *127*
- Assessment of Right Ventricular Function 129

8. Volume Status Assessment and Predicting Volume Responsiveness 138
Tanvir Samra
- Static versus Dynamic Parameters *138*

- Static Indices of Ventricular Preload *138*
- Dynamic Parameters: Predicting Volume Responsiveness *140*
- Passive Leg Raising: Prediction of Fluid Responsiveness in Spontaneously Breathing Adults *143*
- Current Role of Ultrasound for Volume Status Assessment and Prediction of Fluid Responsiveness *144*
- Ultrasound Protocols *144*

9. Ultrasound in Cardiopulmonary Resuscitation.....150
Rakesh Garg
- Need of Ultrasound in Resuscitation *150*
- Ultrasound-guided Management *151*
- Limitations *162*

10. Ultrasound-guided Therapeutic Procedures in Intensive Care Unit.....167
Nitish Parmar, Puneet Khanna, Devasenathipathy Kandasamy
- General Principles *167*
- Thoracocentesis *173*
- Pericardiocentesis *178*
- Paracentesis *183*
- Percutaneous Drainage of Intra-abdominal Collections *187*

11. Ultrasonography in Neurocritical Care 196
Gyaninder Pal Singh, Niraj Kumar
- Measurement of Optic Nerve Sheath Diameter *196*
- Measurement of Midline Shift of Brain *199*
- Assessing Adequacy of Cerebral Blood Flow with Transcranial Doppler *199*
- Assessing Pupils in Patients *203*

12. Focused Assessment Sonography of Trauma 208
Kapil Dev Soni
- Technique *209*
- Clinical Application *213*
- Limitations *215*

13. Abdominal Ultrasonography intThe Intensive Care Unit 216
Riddhi Kundu, Puneet Khanna, Manisha Jana
- Detection of Free-Fluid Accumulation (Focused Assessment with Sonography for Trauma and Extended Focused Assessment with Sonography for Trauma) *217*
- Ultrasound of the Kidneys and Urinary Bladder *221*

- Imaging the Major Vessels *223*
- Imaging the Gallbladder *225*
- Detection of Pneumoperitoneum *226*
- Guiding Therapeutic Procedures *226*

14. Blue, Falls, and Sesame Protocol 229
Dalim Kumar Baidya, Anil Malik
- The Blue Protocol (Bedside Lung Ultrasound in Emergency) *229*
- The Falls Protocol (Fluid Administration Limited by Lung Sonography) *234*
- The Sesame Protocol *235*

15A. Ultrasound of Diaphragm 238
Sandeep Sahu, Alka Verma, Rashmi Soori
- Applied Anatomy of Diaphragm *238*
- Variant Anatomy *239*
- Function *240*
- Dysfunction *240*
- Clinical Presentation of Diaphragm Dysfunction *240*
- Different Techniques for Evaluating the Diaphragm *241*
- Ultrasonography *241*
- Thickness of Diaphragm *243*
- Diaphragmatic Velocity *248*
- The Echogenicity of Diaphragm in Intensive Care Unit *248*
- Clinical Applications *248*
- Limitations of Ultrasonography *249*

15B. Ultrasonography for Assessment of Muscles Dysfunction in ICU 252
Vijay Hadda, Rohit Kumar
- Assessment of Muscle Function *252*
- Reliability of Ultrasonography for Assessment of Muscle Functions *257*
- Literature Supporting the Use of Ultrasonography for Assessment of Muscle Function in Intensive Care Unit *258*

15C. Ultrasonography in Deep Vein Thrombosis 260
Akhil Kant Singh
- Ultrasound *261*
- How I Scan the Leg? *264*

15D. Clinical Case Scenarios 268
Rahul K Anand, Kapil Dev Soni, Ajay Singh, Rashmi Bhatt
- Case 1 *268*

- Case 2 *269*
- Case 3 *270*
- Case 4 *271*
- Case 5 *273*
- Case 6 *274*

15E. Infection Control and Legal Issues in ICU Sonography 276
Puneet Khanna, Rajkumar Subramanian

- Organisms of Concern *276*
- Legal Issues in ICU Sonography *278*

Index.....*281*

JAYPEE BROTHERS

Chapter

3 Ultrasound for Vascular Access

Akhil Kant Singh, Karthic Iyer

HISTORY OF CENTRAL VENOUS ACCESS

In 1929, a 25-year-old, German surgical resident named Werner Forssmann; inserted a 4 Fr ureteric catheter into his left cubital vein, and got an X-ray of the chest to demonstrate the tip of the catheter in the right side of the heart. Later, he injected contrast and visualized the right side of the heart. He published his findings but was met with derision. He was also forced to leave his job and joined the German army as a surgeon.[1]

Although, Forssmann was not particularly encouraged by the response in his own country, Dickinson Richards and Andre Cournand from the US refined Forssmann's technique for testing cardiovascular physiology. For their innovation and research into central venous access, Forssmann, Cournand, and Richards were jointly awarded the Nobel Prize for medicine in 1956.

Catheterization of the central veins has improved by leaps and bounds since the time of the early pioneers. Central venous cannulation is a procedure commonly performed by anesthesiologists and intensivists. The scenario in which one might perform the procedure ranges from controlled conditions like those encountered in the operating rooms; to emergent, life-threatening situations like ongoing cardiopulmonary resuscitation.

Even though a lot of water has flown under the bridge in the form of various developments, since the first attempt at central venous cannulation, the "landmark" technique remains the most commonly attempted method, especially by trainees in developing countries. Studies reporting landmark based approaches to central venous cannulation differ in their results depending on the vessel being accessed, but the consensus is in favor of the usage of ultrasound. Ultrasound-guided approaches have largely supplanted the "landmark" technique as the ideal technique, and for good reason.

- Higher rates of first-pass cannulation, especially in anatomically difficult patients like those who are obese or short necked, and in patients with narrow venous lumen due to hypovolemia.
- Lesser rates of complications like hematoma (especially in patients with coagulation disorders), arterial puncture or pleural injury.
- Identification of vessel thrombosis.

Given its advantages, various organizations including the National Institute for Clinical Excellence, UK, European Federation of Societies for Ultrasound in Medicine and Biology (EFSUMB), Association of Anaesthetists of Great Britain and Ireland (AAGBI)[2] and the American Society of Anesthesiologists[3] have prescribed the regular use of ultrasound guidance while

JAYPEE BROTHERS

gaining central venous access in their guidelines. In fact, the AAGBI questions the need for attaining competency for all staff in the landmark-based approach in its draft policy on vascular access.[2]

THE EVIDENCE

The medical literature is replete with studies and case reports about ultrasound-guided vascular access. There have been numerous studies about the effect of ultrasound on ease of insertion, number of attempts and complications while performing vascular access procedures.

The evidence is clear regarding the utility of ultrasound in internal jugular vein cannulation in adults. Ultrasound guidance results in improved first attempt success, and overall success rates.[4,5] Whether results are equally applicable to experienced operators as well is unclear, but we think that the use of ultrasound would be beneficial even in this subset. In children again, although the data is limited; the literature supports the use of ultrasound for vascular access in the internal jugular vein.[6]

A Cochrane review of the evidence for ultrasound guidance in subclavian vein cannulation found that it reduces the risk of accidental arterial puncture and hematoma formation. No difference was found in total complications, number of attempts or time taken to insert the guidewire.[7] The catch is that studies reviewed were not of good quality and there was no discrimination between experienced and inexperienced operators. Notwithstanding the poor evidence, we would still recommend that ultrasound be used, particularly by beginners.

For femoral vein cannulations, ultrasound increases first attempt success and decreases total time taken. Ultrasound also has a greater benefit in children[8] and in patients undergoing cardiopulmonary resuscitation.[9,10] Intuitively, beginners derive greater benefit than experienced physicians.[11]

Thus, ultrasound-guided central venous cannulation is an important skill which should be taught to all residents and routinely used in clinical practice.

This chapter will introduce the reader to the basic approaches to central venous cannulation using an ultrasound, and touch briefly upon ultrasound being used for peripheral venous and arterial cannulation.

GENERAL CONSIDERATIONS

In Plane or Out of Plane

Whether one uses the in-plane or out-of-plane technique, is a personal choice. The out-of-plane approach is the more commonly used technique and the ultrasound probe is placed perpendicular to the direction being traversed by the vessel. The needle is visualized as a hyperechoic point in the anechoic circle which is the vein (Fig. 1). In the in-plane technique, the probe is positioned longitudinally, over it. In this view, the vessel is envisioned in the long axis, along with the shaft and tip of the needle as it is advanced (Fig. 2). Herein, lies the advantage of this technique over the out-of-plane approach. It is easy to lose sight of the tip and puncture the posterior wall, if the operator does not fan the probe while using the out-of plane technique. Of course, the main drawback of the in-plane approach is the difficulty encountered while keeping the vessel in the viewing window.

JAYPEE BROTHERS

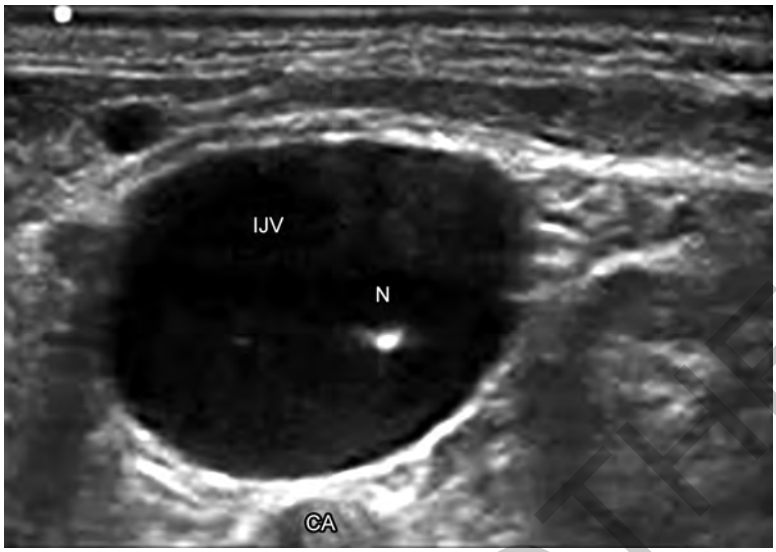

Fig. 1: Needle visualized within the IJV.
Abbreviations: IJV: Internal jugular vein; N: Needle tip; CA: Carotid artery.

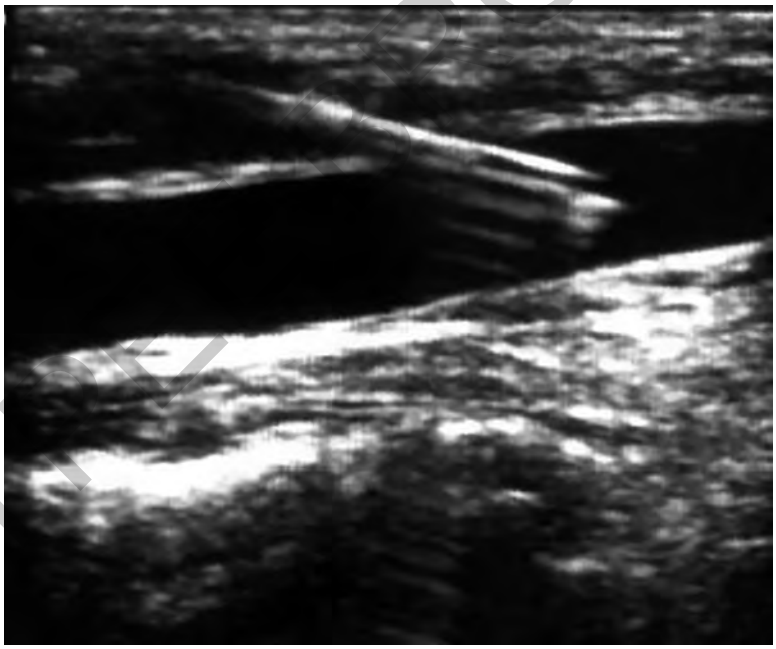

Fig. 2: Needle shaft entering IJV (Longitudinal view).

Static or Dynamic Ultrasound Guidance

Dynamic ultrasound guidance utilizes imaging in real time to visualize the target vessel and the needle pathway. On the other hand, in the static approach the ultrasound is used

JAYPEE BROTHERS

to assess vessel patency and size, the adjacent structures and to ascertain the site of puncture. The actual vessel puncture is done without ultrasound guidance. The static approach is infrequently used and has been shown to be inferior to the dynamic ultrasound guidance.

Vein or Artery

Correctly differentiating the vein from the artery is, of course the basic step before taking a puncture; but it is not always as straightforward as it sounds. Arterial walls are more hyperechoic, and thus brighter and large arteries are less compressible as compared to veins, it is sometimes difficult to differentiate between the two. In hypovolemic patients, arteries can also be compressed with minimal pressure. If the vein in the area of interest has a thrombus, the operator might find difficulty in compressing the vein, thus confounding the identification. In such cases, color Doppler and/or pulse wave Doppler can be used to aid identification.

One-person or Two-person Technique

Intuitively, a two-person technique is easier for beginners. One person holds the ultrasound probe, while the other inserts the line. This technique allows the person inserting the line to use both her/his hands for performing the procedure but might make image optimization difficult, because the probe control is in the hand of the other person. The other disadvantage is that this technique requires two people which might not always be possible. Experienced operators prefer the one-person technique as it affords better image control. Needless to say, it requires better hand-eye coordination.

THE PROCEDURE

We always find it prudent to "sound" the vessel of interest before actually starting the cleaning and draping process. It gives us an estimate about the depth and caliber of the vessel, its general direction and the relation of the surrounding structures. For example, while obtaining venous access in the neck, turning the head too much toward one side may make the internal jugular vein ride on top of the carotid artery instead of being side-by-side. This increases the risk of arterial puncture, even when the procedure is done under ultrasound guidance. Also, we look for evidence of thrombus in the vessel we are interested in (Fig. 3). This should be done in all patients who have had catheters placed previously (e.g. dialysis-dependent patients). Visualizing the vessel also helps in detecting the presence of valves which might be a cause of difficulty in passing the guidewire.

For placing catheters in the neck veins, it is helpful to place the patient in Trendelenburg position, if feasible. This helps in distending the veins of the necks and avoiding air embolism. In conscious patients, asking the patient to perform a Valsalva maneuver may also help to increase the intrathoracic pressure and consequently, increase the caliber of the veins.

While placing catheters in the neck under ultrasound guidance, we do not place a roll between the scapulae, as is the practice at some places. We do not find it aids the imaging of the vessels or the placement of the catheter.

JAYPEE BROTHERS

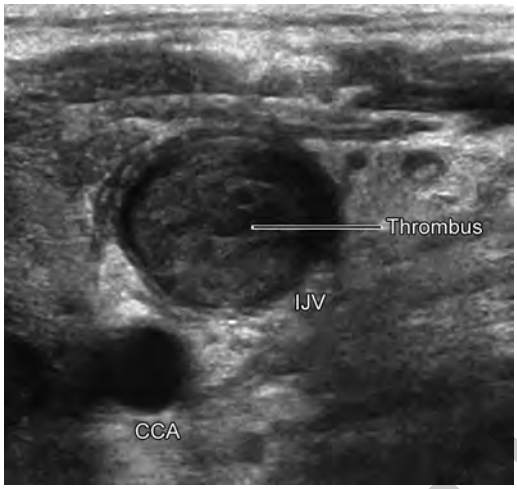

Fig. 3: Transverse view of thrombus within IJV.
Abbreviations: IJV: Internal jugular vein; CCA: Common carotid artery.

For femoral vein cannulation, the patient's leg is externally rotated and slightly abducted.

Maintaining sterility during the procedure is of utmost importance. Using a sterile laparoscopic camera cover is the protocol at our institution. That of course adds to the cost of the procedure in the form of yet another consumable but we find that it ensures asepsis and reduces overall costs by avoiding catheter-associated bloodstream infections. Some operators prefer to use a sterile drape to wrap around the probe and the cord and cover the exposed end of the probe with a transparent dressing like Tegaderm®. Whatever method is used, it is important to place ultrasound gel directly over the transducing surface of the probe and to eliminate air bubbles by smoothing out the camera cover or the transparent dressing. Presence of air bubbles over the probe will result in a suboptimal ultrasound image and will make visualization difficult.

We prefer to use the single operator, out of plane approach. The needle can be positioned close to the probe in an almost vertical orientation or it can be placed a little further away, proximally. If the needle is placed away from the probe, the depth of the vein should be kept in mind and the angle of approach of the needle will have to be adjusted accordingly, so as to "triangulate" the path of the needle toward the center of the vein.

While making the skin puncture, the needle indentation can be visualized on the ultrasound. It is easy to occlude the vessel while pressing down with the probe to maintain image acquisition, especially in small adults and children. Knowing the right amount of pressure to apply comes with experience and is, fortunately, not very difficult. The tip of the needle should be visualized continuously, so as to avoid piercing the posterior wall of the vessel. The needle trajectory should be assessed constantly. If the needle is seen to be going medially or laterally, it should be withdrawn slightly and realigned, so as to puncture the vein.

When the needle enters the vein, blood can be aspirated freely. One may have to insert the needle in a little further because sometimes the endothelium may tent into the lumen. The needle tip should be visualized within the vein at all times. Our practice is to place the probe down and then thread the guidewire in, because we have two hands. For operators

JAYPEE BROTHERS

blessed with more appendages or those using the two-person technique, it is possible to thread the guidewire under ultrasound guidance with the in-plane technique. Once the guidewire is in place, we confirm its location with the ultrasound. We suggest not just looking for the guidewire in the vein, at the insertion point, but rather as far as possible in to the chest. To achieve this, we slide the probe distally till the clavicle, and then drop the tail to visualize the vein going under. This is done to ensure that the guidewire has not exited the vein.

Subclavian Vein Cannulation

Obtaining vascular access in the subclavian vein is complicated by its anatomy.

The subclavian vein is described as starting from the lateral border of the first rib where the axillary vein continues as the subclavian vein. From here on, it travels over the first rib and under the medial one-third of the clavicle, proceeds to enter the mediastinum and joins with the internal jugular vein behind the sternoclavicular joint; forming the brachiocephalic vein. Most of the subclavian vein runs under the clavicle, and this bony structure makes sono-visualization of the vein difficult, if not impossible. There are three different approaches described in the literature; (1) infraclavicular, (2) through the axillary vein, and (3) supraclavicular. There is some confusion in the literature with regards to the infraclavicular approach and through the axillary vein approach, insofar as the description is concerned. Most studies have used the term "infraclavicular" when they have actually described the axillary vein approach, which is performed in the infraclavicular fossa.

In the infraclavicular approach, it is recommended that a probe with a smaller footprint is used. Lichtenstein[12] and Lanspa et al.[13] have described a technique using a pediatric microconvex probe with cannulation of the proximal axillary vein or subclavian vein. The idea is to get under the clavicle without compressing the vein and visualize the vein in the short axis. We prefer the short axis view as it is difficult to keep the vein centered in the long axis view. The combination of lubrication and a relatively smooth surface makes as the probe is prone to sliding which may result in accidental arterial puncture. The short axis view helps in real time differentiation of the vein and artery while taking the puncture (Fig. 4).

The axillary vein approach to subclavian vein cannulation involves placing the ultrasound probe in the infraclavicular fossa in either the short axis or long axis view. As has been mentioned before, the long axis view allows for the guidewire to be threaded into the vein under vision (Fig. 5).

The supraclavicular approach as described by Mallin et al.[14] comprises using an endocavitary probe (Fig. 6) to picture the confluence of the subclavian vein with internal jugular vein in the supraclavicular fossa. The probe is placed lateral to the clavicular head of the sternocleidomastoid. The small footprint of the probe allows for catheterization to take place in the long axis view. Because the endocavitary probe is usually not available in emergency rooms and operating rooms, a high-frequency linear probe may be used for the purpose, but its larger footprint might make visualization more cumbersome. Another alternative is using a "Hockey Stick" probe (Fig. 7).

With progressive adoption of ultrasound guidance for subclavian vein cannulation, this previously underutilized location is coming back into favor. As long as the operator,

JAYPEE BROTHERS

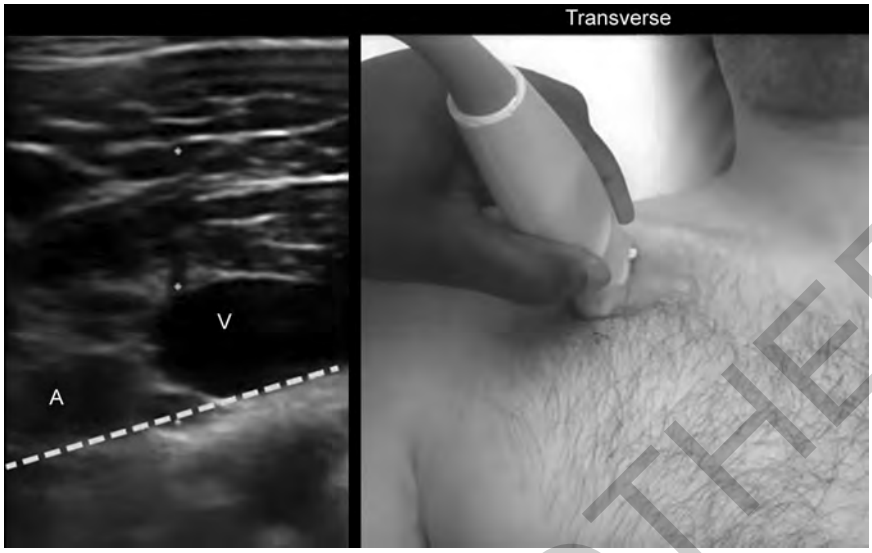

Fig. 4: Transverse view of subclavian vein (V) and subclavian artery (A).

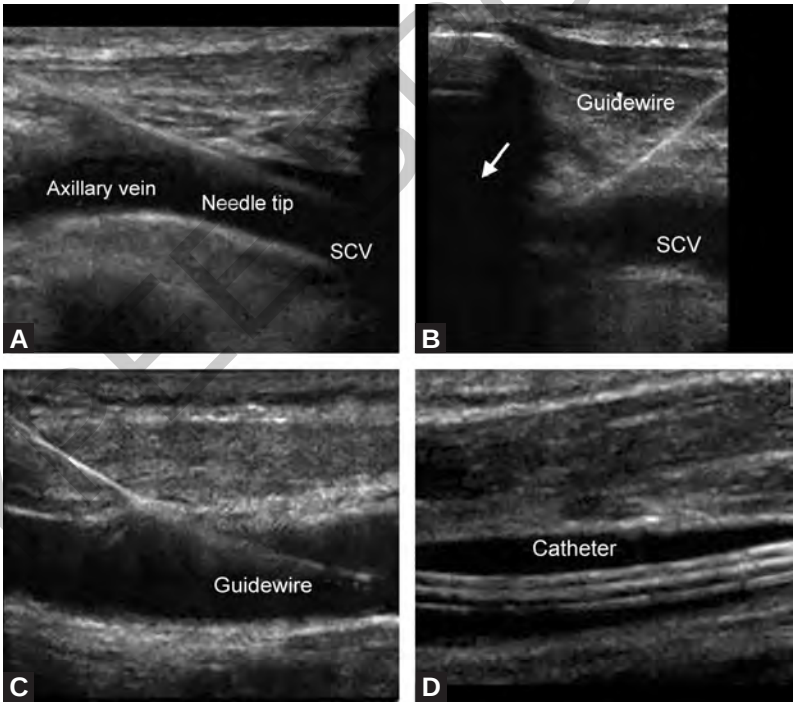

Figs. 5A to D: Longitudinal view of axillary vein puncture (A), guidewire insertion (B and C), catheter in situ (D).
Abbreviation: SCV: Subclavian vein.

especially the novice remains mindful of the surrounding structures; particularly the pleura, the risk of complications is quite low.

JAYPEE BROTHERS



Fig. 6: Endocavitary probe.



Fig. 7: Hockey stick probe.

Femoral Vein Cannulation

Ultrasound is not commonly used for femoral vein cannulation. Sufficient data is not available to definitely conclude, if reduced complications occur with use of ultrasound, but higher rates of successful first pass cannulations occur with ultrasound. In obese individuals and critically ill-patients with significant edema, where palpation of the femoral artery is difficult or pediatric population where there are higher rates of vessel overlap in the femoral triangle, ultrasound is helpful.

Position of the patient is supine. Mild reverse Trendelenburg position makes the femoral vein more prominent. The ultrasound transducer is placed on the femoral triangle with the pointer facing medially. The vessels are imaged in the short axis view while the needle is inserted out of plane.

External Jugular Vein

External jugular vein cannulation is associated with lesser complications like carotid puncture and pneumothorax. The external jugular vein is usually easily identified as it crosses over the sternocleidomastoid in the posteroinferior direction. Given its narrow caliber, double puncture is common. The vein may be tortuous or contain a valve. These can cause difficulty in the passage of the guidewire. Ultrasound can help delineate the anatomy and detect valves or thrombus in the vein although it does not improve the success rate or the speed of cannulation. Position of the patient is similar to that for internal jugular vein cannulation. The transducer is initially placed transversely over the external jugular vein and then the probe is turned clockwise to trace the longitudinal course of the vein. The needle is inserted in an in-plane technique almost parallel to the skin, as the vein is very superficial. Instead of using the needle present in the central line set, one may cannulate the external jugular vein using a 16G intravenous (IV) cannula and then thread the guidewire through the IV cannula.

JAYPEE BROTHERS

Once the guidewire has been placed correctly, the technique is the same as the landmark technique. It is good clinical practice to visualize the catheter in the vein. The catheter can be seen like a "target sign" in the vein lumen in the short axis view. Some institutions also take a print of the captured image of the guidewire in the long axis view and attach it to the patient's file.

AFTER THE PROCEDURE

After placing neck lines or performing subclavian vein cannulation, we always look for pleural sliding to rule out pneumothorax. This is especially important in difficult cannulations or in patients with short necks.

It is also advisable to confirm placement of the catheter by injecting an agitated saline flush through the distal port of the catheter and observing the presence of hyperechoic contrast either in the lumen of the vessel, or the right atrium. The heart can be visualized using a phased array or curvilinear probe, either in the apical four chamber view or the subxiphoid four chamber view.

Peripheral Venous Cannulation

Peripheral venous cannulation can be a challenge in patients who are obese, who have had long hospital stays or in children. Ultrasound aided peripheral venous cannulation does not have as robust a body of evidence as central venous cannulation, but various authors have attempted to describe ease of insertion and first attempt success rate and have come up with differing results. Costantino[15] demonstrated first pass success rate of 46% in an emergency department setting while Ueda et al.[16] reported that they were able to cannulate 96% of their patients in the first attempt. Schoenfeld et al.[17] reported better patient satisfaction scores with ultrasound-guided peripheral venous cannulation. We recommend using ultrasound when no veins are palpated (as might be the case in obese patients) or when previous attempts have failed.

While cannulating peripheral veins, it is important to keep the tip of the needle in the ultrasound view. The target is quite small and one can quite easily lose sight of the tip of the needle with even small movements of the probe. As has been described by Ueda et al.[16] this can be easily learnt through a short teaching module.

Arterial Cannulation

Although arterial cannulation by palpation is the preferred method, ultrasound does have a role as well. Specifically, ultrasound guidance comes into play in the obese, the very young and patients who have low systemic pressures; where difficulty might be encountered in palpating a pulse. Also, when cannulation is to be attempted at a site other than the usual locations (radial, brachial, femoral, axillary or dorsalis pedis) or blind cannulation attempts have been unsuccessful, ultrasound can be of great help. Numerous studies also support this practice and report that the use of ultrasound results in higher first attempt cannulation success rates.[18-20]

JAYPEE BROTHERS

Arterial cannulation can be performed using both the long axis and short axis approaches. As has been mentioned before, the short axis view is easier to obtain but it is easy to lose track of the tip of the needle. The long axis allows for continuous visualization of the shaft and tip of the needle but this approach has a steeper learning curve. Another method described is cannulation after surface marking of the artery, better known as static guidance. We do not use this technique as we find the other methods better.

The area of interest for the arterial cannulation should be scanned with the ultrasound and artery and vein differentiated before the site is cleaned and draped. While placing the arterial cannula, asepsis has to be maintained. The linear probe should be covered with a sterile plastic cover after applying ultrasound gel liberally to the transducer surface. If a catheter over needle type of cannula is being used, care has to be taken to progress the needle a few millimeters after the flash of blood is observed to ensure the catheter is inside the lumen as well. If there is resistance in pushing the catheter in, it means it is not in the vessel.

REFERENCES

1. Meyer JA. Werner Forssmann and catheterization of the heart, 1929. Ann Thorac Surg. 1990;49 (3):497-9.
2. Bodenham Chair A, Babu S, Bennett J, et al. Association of Anaesthetists of Great Britain and Ireland: Safe vascular access 2016. Anaesthesia. 2016;71(5):573-85.
3. American Society of Anesthesiologists Task Force on Central Venous Access, Rupp SM, Apfelbaum JL, et al. Practice guidelines for central venous access: a report by the American Society of Anesthesiologists Task Force on Central Venous Access. Anesthesiology. 2012;116(3):539-73.
4. Karakitsos D, Labropoulos N, De Groot E, et al. Real-time ultrasound-guided catheterisation of the internal jugular vein: a prospective comparison with the landmark technique in critical care patients. Crit Care. 2006;10(6):R162.
5. Brass P, Hellmich M, Kolodziej L, et al. Ultrasound guidance versus anatomical landmarks for internal jugular vein catheterization. Cochrane Database Syst Rev. 2015;1:CD006962.
6. Lausten-Thomsen U, Merchaoui Z, Dubois C, et al. Ultrasound-Guided Subclavian Vein Cannulation in Low Birth Weight Neonates. Pediatr Crit Care Med. 2017;18(2):172-5.
7. Brass P, Hellmich M, Kolodziej L, et al. Ultrasound guidance versus anatomical landmarks for subclavian or femoral vein catheterization. Cochrane Database Syst Rev. 2015;1:CD011447.
8. Aouad MT, Kanazi GE, Abdallah FW, et al. Femoral vein cannulation performed by residents: a comparison between ultrasound-guided and landmark technique in infants and children undergoing cardiac surgery. Anesth Analg. 2010;111(3):724-8.
9. Hilty WM, Hudson PA, Levitt MA, et al. Real-time ultrasound-guided femoral vein catheterization during cardiopulmonary resuscitation. Ann Emerg Med. 1997;29(3):331-6; discussion 337.
10. Siddik-Sayyid SM, Aouad MT, Ibrahim MH, et al. Femoral arterial cannulation performed by residents: a comparison between ultrasound-guided and palpation technique in infants and children undergoing cardiac surgery. Paediatr Anaesth. 2016;26(8):823-30.
11. Wadman MC, Lomneth CS, Hoffman LH, et al. Assessment of a new model for femoral ultrasound-guided central venous access procedural training: a pilot study. Acad Emerg Med. 2010;17(1): 88-92.
12. Lichtenstein D. Cathe´te´risme e´cho-guide´de la veine sous-clavie`re en re´animation. Ann Fr Anesth Reanim. 2000;19:266s.
13. Lanspa MJ, Fair J, Hirshberg EL, et al. Ultrasound-guided subclavian vein cannulation using a micro-convex ultrasound probe. Ann Am Thorac Soc. 2014;11(4):583-6.

JAYPEE BROTHERS

14. Mallin M, Louis H, Madsen T. A novel technique for ultrasound-guided supraclavicular subclavian cannulation. Am J Emerg Med. 2010;28(8):966-9.
15. Costantino TG, Parikh AK, Satz WA, et al. Ultrasonography-guided peripheral intravenous access versus traditional approaches in patients with difficult intravenous access. Ann Emerg Med. 2005;46(5):456-61.
16. Ueda K, Hussey P. Dynamic Ultrasound-Guided Short-Axis Needle Tip Navigation Technique for Facilitating Cannulation of Peripheral Veins in Obese Patients. Anesth Analg. 2017;124(3):831-3.
17. Schoenfeld E, Shokoohi H, Boniface K. Ultrasound-guided peripheral intravenous access in the emergency department: patient-centered survey. West J Emerg Med. 2011;12(4):475-7.
18. Gu WJ, Tie HT, Liu JC, et al. Efficacy of ultrasound-guided radial artery catheterization: a systematic review and meta-analysis of randomized controlled trials. Crit Care. 2014;18(3):R93.
19. Gao YB, Yan JH, Gao FQ, et al. Effects of ultrasound-guided radial artery catheterization: an updated meta-analysis. Am J Emerg Med. 2015;33(1):50-5.
20. Shiloh AL, Savel RH, Paulin LM, et al. Ultrasound-guided catheterization of the radial artery: a systematic review and meta-analysis of randomized controlled trials. Chest. 2011;139(3):524-9.

JAYPEE BROTHERS

for detailed information on anesthesia books, visit our website **www.jaypeebrothers.com,** for detailed information on anesthesia books, visit our

Ultrasound in Critical Care

Key Features

- Comprehensive coverage of the fundamentals of ultrasound use in critical care
- Guidance on ultrasound procedures enables practitioners to use ultrasound for vascular and therapeutic procedures
- Cardiac ultrasound chapters help you assess and monitor the patient's cardiopulmonary status noninvasively
- Chapter on Neck and Upper Respiratory Ultrasound offers an overview of techniques that have not been comprehensively described in any other source
- Color presentation, within illustrations that emphasize the basic skills required to visualize anatomic structures and interpret findings.



Puneet Khanna MBBS MD FAGE is currently working in the Department of Anesthesiology, Pain medicine and Critical Care at the All India Institute of Medical Sciences (AIIMS), New Delhi. He did both his MD and Senior Residency from AIIMS and after a brief stint as Assistant Professor at the Postgraduate Institute of Medical Education and Research (PGIMER), Chandigarh, he came back to his alma mater as an Assistant Professor. Dr Khanna is extremely passionate about his work and has a keen interest in academics and research. He has close to a hundred publications in both national and international journals to his credit. He lives in Delhi with his wife and daughter and when not working, he loves travelling and exploring new places with his family.

Available at all medical bookstores or buy online at www.jaypeebrothers.com

JAYPEE BROTHERS
Medical Publishers (P) Ltd.
www.jaypeebrothers.com

Join us on facebook.com/JaypeeMedicalPublishers

Shelving Recommendations
ANESTHESIA, RADIOLOGY

ISBN 978-93-5270-168-1

9 789352 701681