thers.com, for detailed information on cardiology books, visit our website www.jaypeebrothers.com, for detailed information on cardiology books



Includes Interactive DVD-ROM
Containing 87 Videos
Duration 1 hour 21 minutes

PERCUTANEOUS MITRAL VALVOTOMY

Second Edition



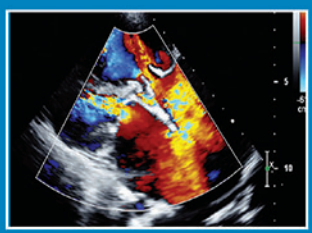

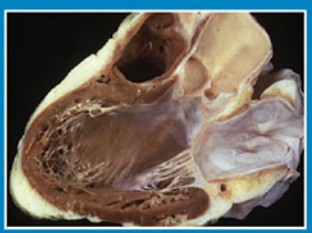

Harikrishnan S

Forewords
Jaganmohan A Tharakan
CN Manjunath

JAYPEE

CONTENTS

SECTION 1: INTRODUCTION

1. **Prelude** **3-6**
Harikrishnan S

2. **Rheumatic Heart Disease—An Epidemiological Mystery** **7–14**
Biju Soman

3. **Anatomy of the Mitral Valve** **15–24**
Yoav Turgeman, Hosam Hasan-Ali, Syamkumar Menon, Raghuram A Krishnan
- Mitral Subvalvular Apparatus 18
- Mitral Valve Orifice 22

4. **Pathological Aspects of Rheumatic Mitral Stenosis** **25–37**
Ruma Ray, Prasenjit Das
- Normal Mitral Valve 25
- Rheumatic Mitral Stenosis 26

5. **Pathophysiology, Natural History and Hemodynamics of Mitral Stenosis** **38-50**
Krishnakumar M, Mahesh Kumar S, Arun SR
- Natural History of Mitral Stenosis 38
- Pathophysiology of Mitral Stenosis 39
- Obstructive Physiology of Mitral Stenosis 41
- Chamber Dynamics in Mitral Stenosis: Left Atrium and Left Ventricle 42
- Pulmonary Circulation 44
- Hemodynamics of Mitral Valve Stenosis 44
- Hemodynamics of Percutaneous Balloon Mitral Valvotomy 47

SECTION 2: EVALUATION PRIOR TO PERCUTANEOUS MITRAL VALVOTOMY

6. **Mitral Stenosis— Evaluation and Medical Management** **53-59**
Harikrishnan S, Stigimon Joseph
- Clinical History 53
- Medical Management 55
- Mixed Valve Lesions 58

7. **Percutaneous Mitral Valvotomy—Indications, Contraindications and Mechanism** **60–66**
Harikrishnan S
- Mechanism of Percutaneous Balloon Mitral Valvotomy 60
- Indications and Contraindications for PMV 61
- PMV—Special Considerations 62
- Practical Approach in the Developing World 64

8. Stress Testing Prior to Percutaneous Mitral Valvotomy **67–70**
P Shanmuga Sundaram, Harikrishnan S

- Treadmill Exercise Testing in Patients with Mitral Stenosis 68
- Dobutamine Stress Echocardiography 68

9. Electrocardiogram in Mitral Stenosis **71–78**
Krishnakumar Nair, Diego Chemello, Raja Selvaraj

- Terminology 71
- Left Atrial Abnormality 72
- Right Atrial Abnormality 73
- Combined Atrial Abnormality 74
- Right Ventricular Hypertrophy 74
- Atrial Arrhythmias 75
- Mitral Stenosis Severity and the ECG 76
- Effects of Mitral Valvotomy on Electrocardiographic Changes of Mitral Stenosis 76
- Clinical Significance 76

10. Radiological Evaluation in Mitral Stenosis **79–85**
Bhavesh Harivadan, Harikrishnan S

- Chest Roentgenography 79
- Left Ventricular Angiography in Mitral Stenosis 82

11. Balloon Mitral Valvotomy—Role of Echocardiography **86–124**
Hosam Hasan-Ali, Harikrishnan S

- Anatomical Background 86
- Pathophysiology of Mitral Stenosis 86
- Echocardiographic Assessment in MS Prior to Percutaneous Mitral Valvotomy 87
- Subvalvar Pathology 96
- Left Atrium 97
- Assessment of Lesions in Other Valves 100
- Transesophageal Echocardiography in PMV 101
- Doppler Assessment of Mitral Valve 105
- Pressure Half-Time 106
- Pulmonary Hypertension 108
- Periprocedural Monitoring 108
- Post-PMV Assessment 109
- Left Atrial Function 110
- Exercise Echocardiography 110
- Predictive Value of Echocardiographic Assessment of MV Morphology Before PMV 111

12. Three-dimensional Echocardiography in PMV: The Latest Tool **125–133**
Gadage Siddharth, Sivasubramonian Sivasankaran

13. Subvalvular Apparatus in Rheumatic Mitral Stenosis—Methods of Assessment and Therapeutic Implications **134-142**
Yoav Turgeman

- Anatomy and Function of Subvalvular Apparatus 135
- Methods of Assessment of the SVA 136

- Impact of SVA Deformity on the Results of PBMV 140
- Clinical Implications and Conclusion 140

14. Atrial Function in Mitral Stenosis—Effect of Percutaneous Mitral Valvuloplasty **143-150**
Tomás F Cianciulli, María C Saccheri

SECTION 3: PMV—PROCEDURE, TECHNICAL CONSIDERATIONS AND PERIPROCEDURAL MONITORING

15. Transseptal Puncture **153–168**
Harikrishnan S, Krishnakumar Nair

- Anatomy of the Atrial Septum 153
- How to Perform Transseptal Puncture 155
- Landmarks for Septal Puncture 161
- Septal Puncture Without Arterial Stick 167
- Probing the Septum 168

16. Use of Safe-Sept Guidewire in Transseptal Access **169–173**
Carlo de Asmundis, Darragh Moran, Jayakeerthi Yoganarasimha Rao Gian-Battista Chierchia, Pedro Brugada

- Indications 169
- Technical Aspects 169

17. Percutaneous Mitral Valvotomy—Procedure **174–183**
Harikrishnan S, Sanjay G, Rajesh Muralidharan

- Preparation of the Patient (SCTIMST Protocol) 174
- Obtaining the Vascular Access 174
- Preparation of the Septal Puncture System and the Balloon 175
- Steps of Percutaneous Mitral Valvotomy 176

18. Periprocedural Monitoring during PMV **184–190**
S Venkiteshwaran, Suchith Majumdar

- Other Formulas to Calculate Mitral Valve Area (MVA) 188

19. Anesthetic Management during Percutaneous Mitral Valvuloplasty **191–195**
Thomas Koshy

- Patient Evaluation Prior to PMV 191
- Precatheterization Preparation 192
- Premedication and Fasting Guidelines 192
- Patient Monitoring During PMV 193
- Patient Sedation 193
- General Anesthesia 194
- Management of Complications 194
- PMV and the Anesthesiologist 195

20. Intracardiac Echocardiography Imaging in Percutaneous Balloon Mitral Valvuloplasty **196–206**
Santhosh KG Koshy, Antwon Robinson

SECTION 4: PMV—TECHNIQUES AND GADGETS

21. Different Techniques and Devices for Percutaneous Mitral Valvuloplasty—Introduction **209–211**
Mohammad A Sherif

- Historical Background 209
- Techniques Available for Percutaneous Mitral Valvotomy 210

22. The Single Balloon Mitral Valvotomy Catheters **212–224**
Harikrishnan S, Krishnakumar M, Suji K

- Comparison Between Inoue and Accura Balloons with Respect to Safety and Efficacy 222
- Blue Arrow PBMV Balloon 223

23. Double Balloon Technique **225–231**
Mohammad A Sherif, Arun Gopalakrishnan

- Double Balloon-Technique (DBT) 225
- Balloon Sizing 226
- Double Balloon Technique—Advantages and Disadvantages 228

24. Mitral Valvotomy by Metallic Commissurotome **232–238**
Mohammad A Sherif, Harikrishnan S

- Description of the Device 232
- Mechanism of Valvotomy with Metallic Commissurotome 234
- Technique 234
- Technical Considerations 235
- Complications 236
- Initial and Long-Term Results 237

25. JOMIVA Balloon **239–241**
Sajy Kuruttukulam

- Technique 239

26. Other Gadgets for Percutaneous Mitral Valvotomy **242–245**
Mohammad A Sherif, Harikrishnan S

- Multi-Track System 242
- Nucleus™ Balloon 244

27. Percutaneous Mitral Valvuloplasty—Comparative Analysis of Different Gadgets **246–252**
Mohammad A Sherif

- Inoue Versus Double Balloon 247
- Inoue Balloon Technique Versus Percutaneous Metallic Commissurotomy 249

28. Reuse and Resterilization of PMV Hardware **253–258**
Suji K, Sethu Parvathy VK

- Methods of Sterilization 254
- Resterilization Process of the PMV Hardware 255

- Sterilization Using Hydrogen Peroxide 255
- Resterilization of Inoue Balloon 256

SECTION 5: COMPLICATIONS FOLLOWING PMV

29. Device-related Complications during Percutaneous Mitral Valvotomy **261–267**
Harikrishnan S

- Breakage of Coiled Left Atrial (LA) Wire 261
- Entrapment of the Pigtail Guidewire 262
- Balloon Rupture During PMV 264
- Balloon Impasse 266

30. Complications of Transseptal Puncture and Management **268–274**
Harikrishnan S, Meera R

- Suspected Pericardial Tamponade 268
- Management 269
- Reversal of Heparin—Protamine 270
- Autotransfusion 271
- Thrombus Formation in the Septal Puncture Site 271

31. Neurological Complications Related to Percutaneous Mitral Valvotomy **275–281**
Sajith Sukumaran

- Systemic Embolism in Patients with Mitral Stenosis 275
- Factors Associated with Systemic Embolization 276
- Percutaneous Balloon Mitral Commissurotomy and Systemic Embolism 277
- Prevention of Cardioembolic Stroke in Rheumatic Mitral Stenosis During Percutaneous Mitral Interventions 277
- Periprocedural Stroke and Treatment Options 278

32. Thromboembolic Complications during Balloon Mitral Valvotomy **282–288**
Dash PK

33. Arrhythmias and Its Management during Percutaneous Mitral Valvotomy **289–296**
Shomu R Bohora

- Arrhythmias During PMV 289
- Preprocedure Management of Atrial Fibrillation 291
- Postprocedure Management of Atrial Fibrillation 293
- Atrial Flutter 294

34. Deflation Failure of Mitral Valvuloplasty Balloon **297–304**
Pranav Bansal, Mamtesh Gupta, Jagdish Dureja

35. Emergency Surgery after Percutaneous Mitral Valvotomy **305–310**
Praveen Reddy Bayya, Praveen Kumar Neema, Praveen Kerala Varma

- Acute Mitral Regurgitation 307

36. Troubleshooting of Single Balloon Catheters—Inoue and Accura Balloons **311–316**
Harikrishnan S

SECTION 6: PMV IN SPECIAL SITUATIONS

37. Percutaneous Mitral Valvotomy in Pregnancy **319–329**
Shyam Sundar Reddy

- Mitral Stenosis and Pregnancy 319
- Medical Therapy 320
- Interventions in Mitral Stenosis in Pregnancy 321
- Percutaneous Mitral Valvotomy (PMV) in Pregnancy 321
- PMV in Pregnancy—Procedural Details 322
- Short- and Long-term Outcomes Following PMV in Pregnancy 324

38. Percutaneous Mitral Valvotomy in Juvenile Mitral Stenosis **330–334**
Randeep Singla

- Indication for PMV in Juvenile Mitral Stenosis 330
- Valve Morphology 330
- PMV Procedure in Juvenile Mitral Stenosis 330
- Vascular Access 331
- Balloon Selection and Dilatation 331
- Complications 331

39. Transjugular Percutaneous Mitral Valvotomy **335–340**
Boonjong Saejueng, Sudaratana Tansuphaswadikul

- Transjugular Interatrial Septal Puncture 336
- Procedure of Septal Puncture 336
- Mitral Valve Dilatation Procedure 337
- Complications 340

40. Percutaneous Prosthetic Mitral Balloon Valvotomy **341–346**
Col. Subroto Kumar Datta

- Case Selection/Indication 341
- Evaluation 342
- Echo 342
- Selection and Sizing of Balloon 343
- Procedure 343
- Follow-Up 344
- Discussion 344

41. Tackling Subvalvular Disease during Balloon Mitral Valvotomy **347–353**
CN Manjunath, Prabhavathi, BC Srinivas

42. Over-the-Wire Techniques during PMV **354–359**
KS Ravindranath, Ravi S Math, CN Manjunath

43. PMV Performed with other Percutaneous Interventions **360–370**
Dinesh Choudhary, Harikrishnan S

- PMV and Percutaneous Valvotomy of Other Valves 360
- Which Valve to Tackle First? 360
- PMV and Percutaneous Aortic Valvotomy 361
- BAV Along with PMV—Techniques 362
- PMV and Balloon Tricuspid Valvotomy 367
- Triple Valve Intervention 368
- Percutaneous Coronary Intervention and PMV 368

44. Balloon Tricuspid Valvotomy along with PMV **371–375**
Harikrishnan S, Amit Kumar Chaurasia

45. PMV in Patients with Atrial Fibrillation **376–384**
Krishnakumar M

- Mechanism of Atrial Fibrillation in Mitral Stenosis 376
- Restoration and Maintenance of Sinus Rhythm in Mitral Stenosis 380

46. Percutaneous Mitral Valvotomy in Dextrocardia **385–388**
Harikrishnan S, Krishnakumar Nair

47. Balloon Mitral Valvotomy—Left Femoral Vein Approach and in Venous Anomalies **389–393**
Rajesh Muralidharan

- BMV in Other Venous Anomalies 392

48. Retrograde Nontransseptal Balloon Mitral Valvuloplasty **394–398**
Harikrishnan S, Arun Gopalakrishnan

49. Percutaneous Mitral Valvotomy in Technically Challenging Situations **399–415**
Harikrishnan S, Rohan Vijay Ainchwar

- Calcification of the Valve 399
- Left Atrial Thrombi 400
- Difficulty at the Groin Puncture Site 400
- Difficulty in Septal Puncture, Dilatation and Balloon Entry 401
- Difficulty in Negotiating the Atrial Septum 403
- Balloon Catheter Stuck at Septum—Septal Catch 403
- Techniques Facilitating Entry of Balloon Across Mitral Valve 406
- Entry of Balloon Through the Secondary Orifices 410
- Failure to Dilate the Valve 411
- Popping of the Balloon Back to Left Atrium 411
- Small Left Atrium 412
- Percutaneous Mitral Valvotomy in Small Children 413

50. Left Atrial Appendage Occlusion and Percutaneous Mitral Valvotomy **416–426**
Dale Murdoch, Darren Walters

- Background and Rationale 416

51. Percutaneous Treatment of Lutembacher's Syndrome: Balloon Mitral Valvotomy and Device Closure of Atrial Septal Defect **427–439**
Shiv Bagga, Saujatya Chakraborty, Ramalingam Vadivelu

- Pathophysiology 427
- Treatment of Lutembacher's Syndrome 427
- Percutaneous Treatment of Lutembacher's Syndrome 428
- Step-by-Step Technique for Percutaneous Therapy of Lutembacher's Syndrome 435

52. Percutaneous Mitral Valvotomy in Mitral Restenosis **440–450**
Krishnakumar Nair, Harikrishnan S

- Definition 440

- Prevalence 441
- Predictors of Restenosis 441
- Pathology 442
- Management 443

SECTION 7: LONG-TERM OUTCOME FOLLOWING PMV

53. Left Atrial Thrombosis in Rheumatic Mitral Stenosis **453–461**
Sonny P Jacob

54. Comparison of Percutaneous Mitral Valvotomy and Surgical Mitral Commissurotomy **462–467**
Sanjay G

- PMV Vs Surgical Commissurotomy in Special Situations 464

55. Mitral Regurgitation Following Percutaneous Mitral Valvotomy **468–475**
Rachel Daniel, Anees Thajudeen

- Mechanism of Mitral Regurgitation Following PMV 468
- Incidence 471
- Clinical Course of MR 472
- Surgical Management of MR Following PMV 474

56. Atrial Septal Defects Following Percutaneous Mitral Valvotomy **476–479**
Harikrishnan S, Kiron Sukulal

57. Pulmonary Hypertension in Rheumatic Mitral Stenosis— Influence of Percutaneous Mitral Valvotomy **480–491**
Harikrishnan S, Chandrasekharan C Kartha

- PH in Rheumatic Mitral Valve Disease 484
- Effect of Balloon Mitral Valvotomy on PH 486

58. Long-term Follow-up of Patients Undergoing Percutaneous Mitral Valvotomy **492–499**
Rachel Daniel

- Mitral Restenosis and Long-Term Outcome 494
- Follow-up and Management of Patients After PMV 494
- Infective Endocarditis Prophylaxis 495

59. Setting A New PMV Program **500–503**
Ajeet Arulkumar, Harikrishnan S

Index *505*

DVD CONTENTS

LIST OF VIDEOS IN CINE AND ECHO

Chapter 10
Video 1—Fig. 10.4: Mitral stenosis LV angio RAO view

Chapter 11
Video 1—Fig. 11.18: Small thrombus in the LA appendage TTE
Video 2—Fig. 11.22A: Lutembacher 4 chamber view 2D
Video 3—Fig. 11.22B1: Lutembacher color flow
Video 4—Fig. 11.22B2: Lutembacher in 4 chamber view color flow
Video 5—Fig. 11.28: Stationary PML, well moving AML - TEE image
Video 6—Fig. 11.39: Post PMV MR, Iatrogenic ASD is also seen

Chapter 15
Video 1—Fig. 15.18A and B: Aortic stain video
Video 2—Fig. 15.19A and B: LA angio levophase showing left atrium
Video 3—Step 2: Tracking the Brockenbrough needle
Video 4—Step 3: Descent to the fossa ovalis from the left innominate vein
Video 5—Step 4: Lateral view aortic root check
Video 6—Step 5A: Septal puncture
Video 7—Step 5B: Septal puncture lateral view
Video 8—Step 6: Mullins dilator being advanced to LA
Video 9—Step 7: Pigtail wire being introduced into LA
Video 10—Step 8: Pigtail wire in LA

Chapter 17
Video 1—Fig. 17.4: Septal dilatation
Video 2—Fig. 17.5: BMV balloon introduction
Video 3—Fig. 17.8.1: Balloon into LV
Video 4—Fig. 17.8.2: BMV balloon dilatation
Video 5—Fig. 17.8.3: PMV balloon dilatation medial commissure split

Chapter 23
Video 1—Fig. 23.3: Double balloon

Chapter 25
Video 1—Fig. 25.3: JOMIVA balloon septal dilatation
Video 2—Fig. 25.4: JOMIVA balloon inflation

Chapter 29
Video 1—Fig. 29.9: Balloon rupture

Chapter 32
Video 1—Fig. 32.2: Left main coronary occlusion following PMV
Video 2—Fig. 32.3: PCI for LM occlusion cine runs

Chapter 35
Video 1—Fig. 35.2: Post PMV severe MR TEE images
Video 2—Fig. 35.2: Post PMV MR medial commissure LA wire seen
Video 3—Fig. 35.2: Cineangiogram Post PMV MR medial commissure LA wire seen

Chapter 39
Video 1—Fig. 39.2.1: Venogram IVC1
Video 2—Fig. 39.2.2: Venogram IVC2
Video 3—Fig. 39.2.3: Venogram IVC3
Video 4—Fig. 39.3: Transjugular PA angio levophase
Video 5—Fig. 39.5: Transjugular balloon dilatation
Video 6—Fig. 39.5: Transjugular
Video 7—Video-1: Transjugular LA angio post-puncture
Video 8—Video-2: Transjugular septal puncture
Video 9—Video-3: Transjugular RA angio (5)
Video 10—Video-4: Transjugular septal dilatation

Chapter 41
Video 1—Video-1: Transthoracic echocardiography showing severe subvalvular thickening
Video 2—Video-2: Severe subvalvar disease producing multiple inflow jets
Video 3—Video-3A: Impact of measuring MVA at proper plane
Video 4—Video-3B: Impact of measuring MVA at proper plane
Video 5—Video-4A: Balloon impasse sign
Video 6—Video-4B: Balloon impasse sign
Video 7—Video-5A: Abnormal shape of balloon due to subvalvar disease
Video 8—Video-5B: Normal shape of balloon
Video 9—Video-6A: Severe submitral stenosis
Video 10—Video-6C: Severe submitral stenosis
Video 11—Video-7A: Submitral release from antegrade approach
Video 12—Video-7B: Submitral release from antegrade approach
Video 13—Video-7C: Submitral release from antegrade approach
Video 14—Video-7D: Submitral release from antegrade approach
Video 15—Video-8A: Submitral release from retrograde approach
Video 16—Video-8B: Submitral release from retrograde approach
Video 17—Video-8C: Submitral release from retrograde approach
Video 18—Video-8D: Submitral release from retrograde approach
Video 19—Video-9: Balloon dilatation of subvalvar stenosis

Chapter 42
Video 1—Additional videos
Video 2—Additional videos
Video 3—Additional videos
Video 4—Additional videos
Video 5—Additional videos

Chapter 43
Video 1—Fig. 43.7: BPV with accura balloon pigtail wire in LPA

Chapter 44
Video 1—Fig. 44.3: BTV dilatation RAO
Video 2—Fig. 44.3: BTV entry RAO 30° view

Video 3—Fig. 44.3: BTV waist RAO 30° view
Video 4—Fig. 44.5: BTV - Over the wire entry

Chapter 46
Video 1—Fig. 46.3: Dx PA pseudo AP
Video 2—Fig. 46.6: Dx reverse loop entry to LV

Chapter 47
Video 1—Fig. 47.2: LFV approach to PMV

Chapter 49
Video 1—Fig. 49.1: PMV in a calcific mitral valve
Video 2—Fig. 49.5: Balloon stuck at septum
Video 3—Fig. 49.6A: Hairpin loop entry
Video 4—Fig. 49.6B: Hairpin loop entry
Video 5—Fig. 49.7: Classic reverse loop
Video 6—Fig. 49.7: Formation of reverse loop with LA wire
Video 7—Fig. 49.7: Reverse loop balloon subvalve entry 2
Video 8—Fig. 49.7: Reverse loop entry and balloon dilatation
Video 9—Video 49.1: Needle jerk entry to LA while puncturing
Video 10—Video 49.3: Probing entry in a pregnant patient
Video 11—Video 49.3: Probing entry in a bulging septum
Video 12—Video 49.3: Probing entry

LIST OF PROCEDURAL VIDEOS

Video 1—Demonstration of the hardware, preparation of the balloon and resterilisation

Video 2—Video recording of a PMV procedure actually done in the cathlab

Chapter 11

Balloon Mitral Valvotomy—Role of Echocardiography

Hosam Hasan-Ali, Harikrishnan S

JAYPEE BROTHERS

ANATOMICAL BACKGROUND

The mitral valve (MV) is a complex structure consisting of 6 components; annulus fibrosus, leaflets, chordae tendineae, papillary muscles, posterior left atrial wall and left ventricular wall. These 6 components should be considered functionally a unit, since derangement of any one can cause MV dysfunction.[1] The detailed description of mitral valve anatomy is given in Chapter 3.

Pathological Anatomy in Mitral Stenosis

Rheumatic pathology results in 4 forms of MV pathology—commissural (30%), cuspal (15%), chordal (10%) and combined (45%). The detailed description of the pathological anatomy in mitral stenosis (MS) is given in Chapter 3.

By rheumatic process, the primary orifice of the mitral valve—at the level of the mitral valve annulus gets narrowed due to commissural fusion and valve thickening. The valve orifice which is tubular normally, changes to "funnel-shaped". With the pathology of the leaflets, the orifice becomes fish—mouthed or buttonhole like. The secondary orifices, between the chordal structures also get narrowed due to chordal fusion and chordal shortening. The subvalvar pathology causes the mitral valve opening to become a funnel-shaped structure.

The primary orifice located at the level of the annulus is narrowed mainly due to commissural fusion. When only one commissure is fused or one is fused more than the other the stenotic orifice is eccentrically located. A centrally located orifice indicates symmetrical commissural fusion.[2,3] Though calcification may occur in any part of the MV or its associated structures, it is most frequently found in the leaflets and in the commissural regions.[4,5]

PATHOPHYSIOLOGY OF MITRAL STENOSIS

The detailed description of the pathophysiology of MS can be found in Chapter 5. Mitral stenosis leads to obstruction of the left ventricular inflow, leading to raised left atrial (LA) pressure which is passively transmitted to the pulmonary capillary bed. In response to this, there will be pulmonary artery

vasoconstriction and the chronically elevated pulmonary venous hypertension will lead to structural changes in the pulmonary arteries. The resultant pulmonary arterial hypertension will lead to right ventricular hypertrophy followed by right ventricular (RV) dilatation and failure.

All the above anatomical and pathophysiological alterations can be evaluated by echocardiography. Henceforth echocardiography is considered as the investigation of choice in the evaluation of patients with mitral stenosis.

ECHOCARDIOGRAPHIC ASSESSMENT IN MS PRIOR TO PERCUTANEOUS MITRAL VALVOTOMY

Echocardiography is the primary modality of evaluation in a patient who is planned for percutaneous mitral valvotomy (PMV). It is essential for the intraprocedural monitoring, the postprocedural assessment and follow-up.

What are the Parameters we Assess for PMV?

To discuss this we should know the indications and contraindications for PMV. The indications are described elsewhere in this book. The absolute contraindications are commissural calcium, left atrial thrombus and ≥ 3+ mitral regurgitation. We get good results following PMV in uniformly thickened valves with no calcium and no significant subvalvar pathology. So, the primary aim of echocardiographic assessment is to find the suitable valve for PMV and identify those valves which will give inadequate results or lead to complications.

EAE-ASE recommendations 2009[6] says that the assessment of severity rheumatic MS should rely mostly on valve area because of the multiple factors influencing other measurements, particularly mean gradient and systolic pulmonary artery pressure.

Parameters Assessed by Echocardiography

A. Preprocedure

1. Severity of MS (Fig. 11.1 and Table 11.1)
2. Pliability (Suitability of the valve for PMV)
   a. Calcification
   b. Valve thickening (uniform/non-uniform)
   c. Subvalvar pathology
   d. Commissural morphology.
3. Mitral regurgitation
4. Left atrial thrombus [Usually performed with transesophageal echocardiography (TEE)]
5. Assessment of the interatrial septum
6. Diseases of the other valves
7. Assessment of pulmonary hypertension.

B. Intraprocedure monitoring

1. Adequacy of commissural splitting (stepwise dilatation)
2. Mitral regurgitation
3. Complications—cardiac tamponade.

JAYPEE BROTHERS

C. Postprocedure evaluation

1. Adequacy of commissural splitting
2. Residual stenosis, MR
3. Atrial septal defect (ASD).

Table 11.1: Severity of mitral stenosis modified from ASE/EAE[6]

Severity	*Mild*	*Moderate*	*Severe*
Mitral valve area (cm^2)	>1.5	1–1.5	<1
Pressure half-time (msec)	100–150	150–220	>220
Mean pressure gradient (mm hg)*	<5	5–10	>10

*At heart rates 60–80 bpm in sinus rhythm

M-mode Echocardiography (Figs 11.1 to 11.7)

M-mode echocardiography, the first echocardiographic modality used for the assessment of MS is still widely utilized. The M-mode parameters used to assess the severity of MS are DE amplitude and EF slope.

M-mode Parameters in the Assessment of Severity of MS and Pliability

DE amplitude of more than 18 mm is indicative of a pliable valve. The normal EF slope is 50 to 180 mm/sec. When there is severe MS the EF slope comes down to 10 to 20 mm/sec or can even reach zero (Fig. 11.5). Even though there is correlation between the EF slope and severity of MS, EF slope is found to be altered in left ventricular (LV) diastolic dysfunction. So, it is not found as useful a parameter when we have better techniques like 2D echocardiography.

Two-dimensional Echocardiography

The most important and useful echocardiographic modality in the assessment for PMV is 2D echocardiography. Since the valve morphology is the most

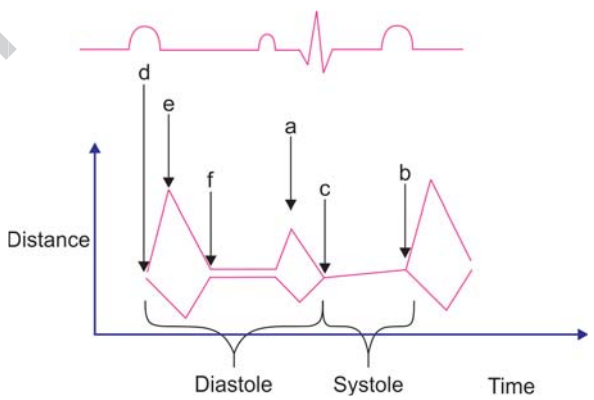

Fig. 11.1: Normal M-mode echocardiography of mitral valve
Courtesy: Edwards F Crooks

JAYPEE BROTHERS

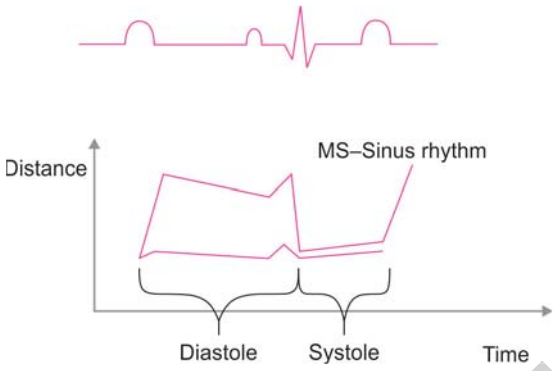

Fig. 11.2: M-mode echocardiography in mitral stenosis in sinus rhythm
Courtesy: Edwards F Crooks

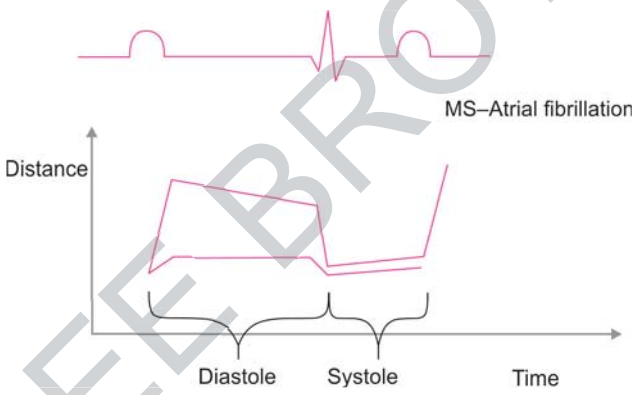

Fig. 11.3: M-mode echocardiography in MS in atrial fibrillation
Courtesy: Edwards F Crooks

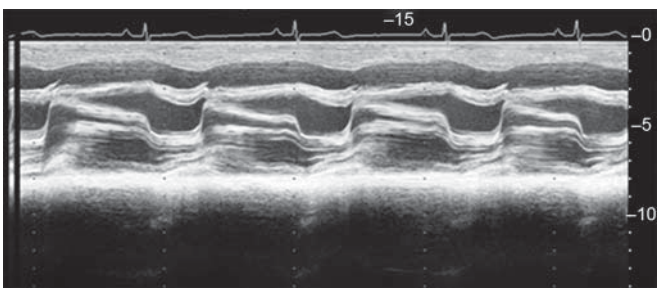

Fig. 11.4: M-mode echo of mitral valve in mitral stenosis.
Note the anterior movement of the PML and thickening of the leaflets

JAYPEE BROTHERS

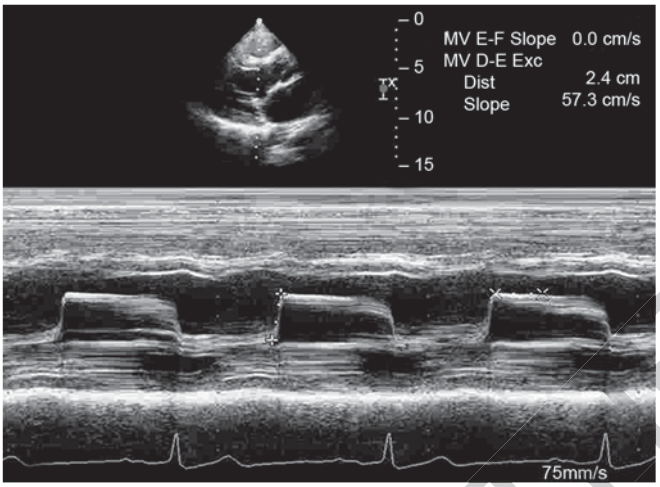

Fig. 11.5: M-mode echo of mitral valve in mitral stenosis. *Note* the DE amplitude of 24 mm and EF slope of 0 cm/sec. This indicates severe and pliable MS

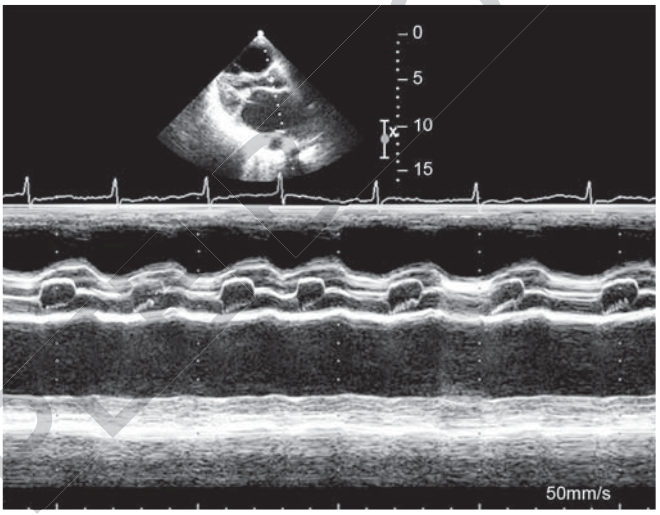

Fig. 11.6: M-mode echocardiography showing dilated left atrium, dilated RV, normal sized aorta and normally opening aortic valve in a patient with tight MS in atrial fibrillation

important predictor of the success of PMV, 2D echocardiographic assessment is very crucial (Figs 11.8 and 11.9).

Due to rheumatic processes, the mitral valve becomes thickened and the mobility of the valve leaflets gets restricted. This will be evident in the parasternal long axis (PLAX) view where the anterior mitral leaflet (AML) shows a "hockey-stick" appearance and the valve appears doming (Fig. 11.8).

The other structures which can be assessed by 2D echo are the aortic and tricuspid valves. The aortic valve is assessed in the PLAX and the parasternal short axis (PSAX) views and also the 5 chamber views. The tricuspid valve is assessed in the apical four chamber (A4C) view.

JAYPEE BROTHERS

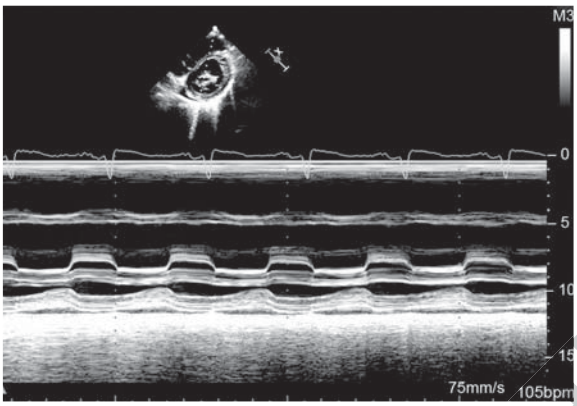

Fig. 11.7: M-mode echocardiography in a patient with severe MS and severe LV dysfunction

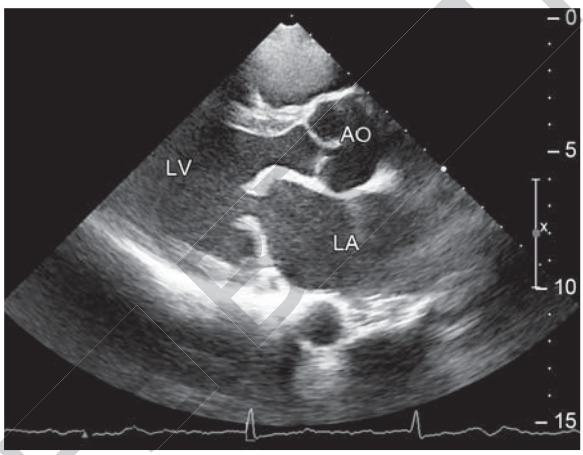

Fig. 11.8: PLAX view showing the grossly thickened mitral valve and anterior mitral leaflet (AML) giving the characteristic "hockey-stick" appearance. Doming of the mitral valve is also seen
Abbreviations: LV, left ventricle; AO, aorta; LA, left atrium

The parameters which are evaluated in the 2D echocardiographic assessment of MS are:

1. Left atrial enlargement.
2. MS severity by planimetry assessment of mitral valve area (MVA).
3. Morphology of the mitral valve
   a. Calcification (especially at the commissure)
   b. Valve thickening (uniform/non-uniform)
   c. Subvalvar pathology
   d. Commissural morphology—fibrosis, fusion
4. LA thrombus (usually performed with TEE, but sometimes detected by TTE itself)
5. Assessment of the interatrial septum
6. Disease of the other valves.

JAYPEE BROTHERS

Mitral Valve Area Assessment by Planimetry

Mitral valve area (MVA) measured by planimetry method (Fig. 11.9) has the best correlation with valve area measured on explanted valves.[6] So, this is considered the reference measurement for MVA. Planimetry is the direct measurement of MVA and, unlike other methods, does not involve (1) any hypothesis regarding flow conditions, (2) cardiac chamber compliance, or (3) presence of associated valvular lesions.

The MV in rheumatic MS becomes a funnel-shaped structure that tapers to the primary orifice at its tips. So depending on the area of scanning, the MVA can get altered (Fig. 11.10). The settings of the echo machine also affect the measurement of MVA.

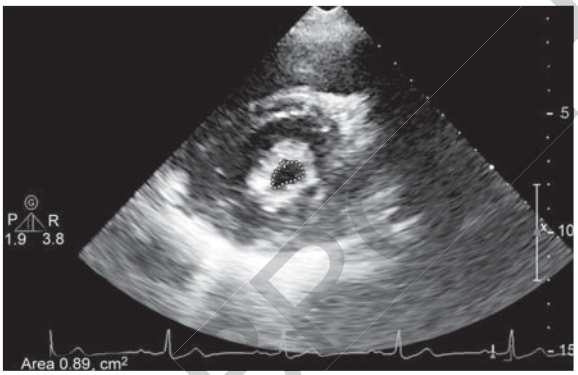

Fig. 11.9: Assessment of MVA by planimetry. The 2D MVA here is 0.894 cm² indicating severe MS. Both the commissures are fused

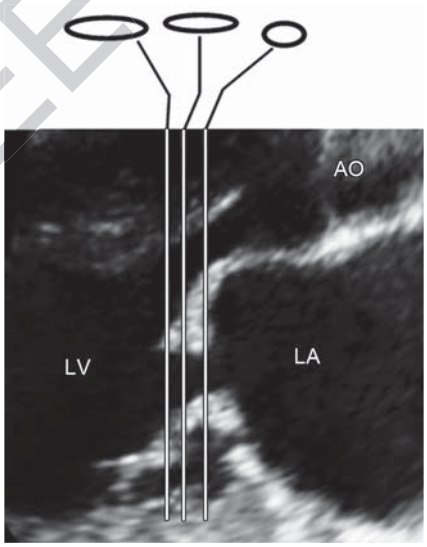

Fig. 11.10: Measurement of 2D MVA by planimetry may be fraught with fallacies if not measured properly. This picture shows significant variation in MVA when measured in three different imaging planes
Abbreviations: LA, left atrium; LV, left ventricle; AO, aorta

JAYPEE BROTHERS

How to Ideally Measure MVA by Planimetry

1. The PSAX view—smallest orifice to be identified by scanning from the LA to LV apex.
2. Identification of the orifice at its maximal opening in mid diastole.
3. The measurement plane should be perpendicular to the mitral orifice.
4. Lowest gain settings (increased gain settings lead to "blooming" of echoes, underestimates the MVA).
5. Trace the contour of the inner mitral orifice.
6. Commissures to be included if open.
7. Average of three measurements in SR, 5-10 in AF. (*Ref. EAE ASE guidelines 2009*)[6].

Limitations of Planimetry Measurement

1. Orthogonality of the imaging plane with the mitral orifice is assumed, but not granted.
2. The level at which the 2D plane intersects the funnel formed by the stenotic mitral orifice cannot be controlled by the echocardiographer.
3. Calcium will make the tracing of the contour difficult.
4. Commissures especially the opened commissures will be difficult to be traced accurately.

Mitral Leaflet Separation Index

Another parameter which is useful in assessing the severity of MS is the mitral valve leaflet separation index (Fig. 11.11). It is measured in diastole in PLAX view and apical 4 chamber view, then the average of the two measurements are taken. An index of 0.8 cm or less predicted severe MS. A value of 1.1 to 1.2 cm or more indicates mild MS. This parameter is found to be an independent predictor of success during PMV (with 90% sensitivity and 100% specificity).[7,8]

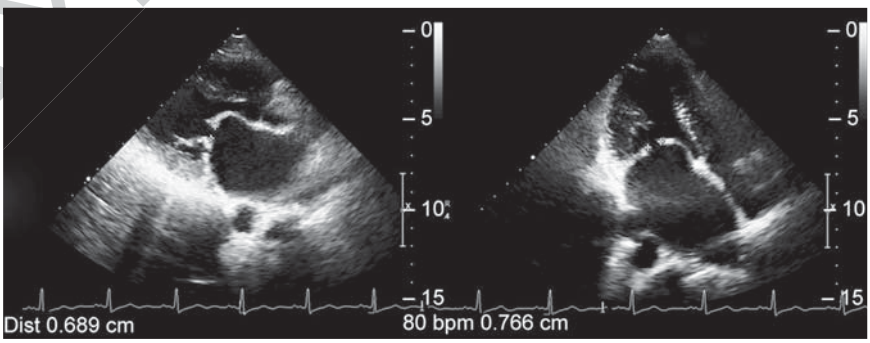

Fig. 11.11: Leaflet separation index. The value obtained is 0.689 (PLAX) and 0.766 (A4C) is averaged to get the value of 0.727 cm which indicates severe MS

JAYPEE BROTHERS

Mitral Valve Morphology

As the primary mechanism by which PMV increases MVA is splitting of the fused commissures, commissural morphology is one of the most important factors which influence the outcome of PMV. So, assessment of valve morphology by echocardiography becomes critical.

While assessing the morphology of the valve, mobility, thickening, subvalvar pathology and calcification are the four important parameters which are evaluated. Of these parameters, commissural morphology is the most important.

Various scoring systems are used to grade the morphology of the valve. The details of those are given later in this Chapter.

Mobility of the Valve

Leaflet motion: To assess leaflet motion the MV leaflets are usually imaged in the parasternal long axis view during maximum doming of the anterior leaflet in early diastole. Wilkins scoring system[9] assesses the mobility and grades it into 4. More objective grading of the morphology of the mitral valve is done by the system by Reid et al.[10]

They assess the extent of doming of the anterior mitral leaflet (AML) by drawing a line from the junction of the posterior wall of the aortic root and anterior MV to the tip of the mitral leaflet (xy- H) (Fig. 11.12). From this line, a perpendicular line is drawn to the leading edge of the maximum dome (ab- L). Leaflet mobility is then expressed as a slope by dividing the height of the dome by the length of the dome—H/L[10] (Table 11.2).

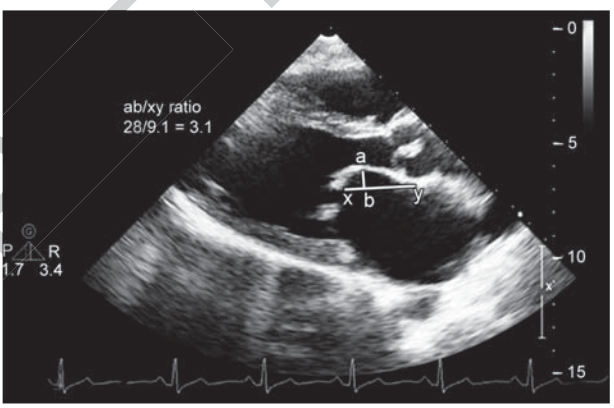

Fig. 11.12: PLAX view demonstrating the measurement of H/L ratio

Table 11.2: Height and length ratio[10]

Height and length ratio (ab/xy)	*Grade*	*Score*
< 0.25	Mild	0
0.25–0.44	Moderate	1
> 0.45	Severe	2

JAYPEE BROTHERS

Valve Thickening

The normal thickness of the mitral valve is less than 4 mm. Thickness of 5 to 8 mm is considered mildly thickened and >8 mm is considered markedly thickened. Thickening can extend to the whole of the leaflet or it can be localized to the margins.[9] As the thickness increases, the outcome of the procedure becomes worse.

Valve thickening is usually assessed from the 2D image in the PLAX view. A more objective assessment of valve thickening can be obtained by measuring the ratio of the thickness of the valve leaflet to the thickness of the posterior aortic wall (valve thickness/posterior aortic wall thickness— the normal value is <1.4). Ratio up to 2.0 is considered mild thickening, 2 to 5 is moderate and > 5 is considered severe thickening.[10]

Valve Calcification

Even though valve calcification (Figs 11.13 to 11.15) influences the outcome of PMV, it is the calcium in the commissures which mostly influences the outcome. Commissural calcium is analyzed in parasternal short axis view by careful scanning of the MV orifice from the level of the aortic root to the MV leaflets. The echogenicity of the aortic root is used as a point of reference.[11] The severity of commissural calcium is assessed in each commissure as follows (when absent = 0 and when present =1); then the score of both commissures is summed to give a total score – maximum of 2.[12]

Calcification is the most important factor in deciding whether the patient should go for a closed procedure or not. If there is commissural calcium it is a contraindication to a closed procedure (Fig. 11.16). Calcium restricted to the belly of the AML or PML (Fig. 11.14) is not an absolute contraindication to the procedure. Even-though there are reports on PMV in unicommissural calcium, bicommissural calcium (Fig. 11.13) is a contraindication to the procedure.

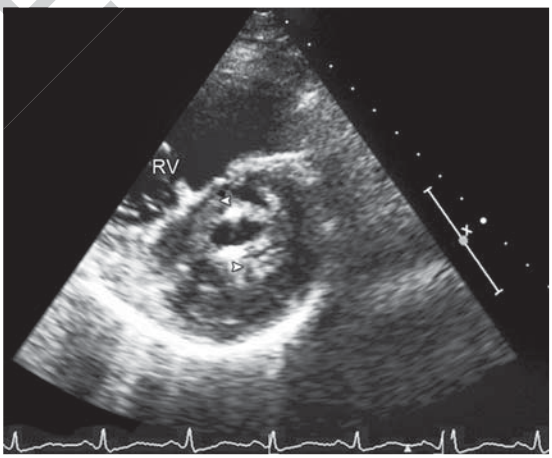

Fig. 11.13: Short axis view of the mitral valve showing calcium in the belly of both AML and PML. This is not a contraindication for PMV

Abbreviations: AML, Anterior mitral leaflet; PML, Posterior mitral leaflet; RV, right ventricle

JAYPEE BROTHERS

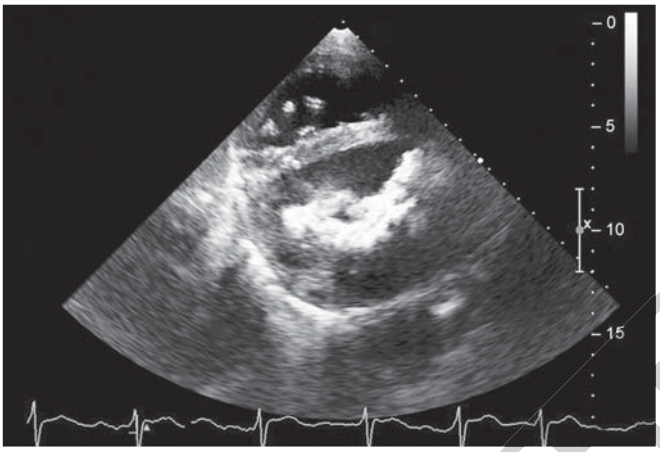

Fig. 11.14: Heavily calcific mitral valve in a patient with severe mitral stenosis (PSAX view)

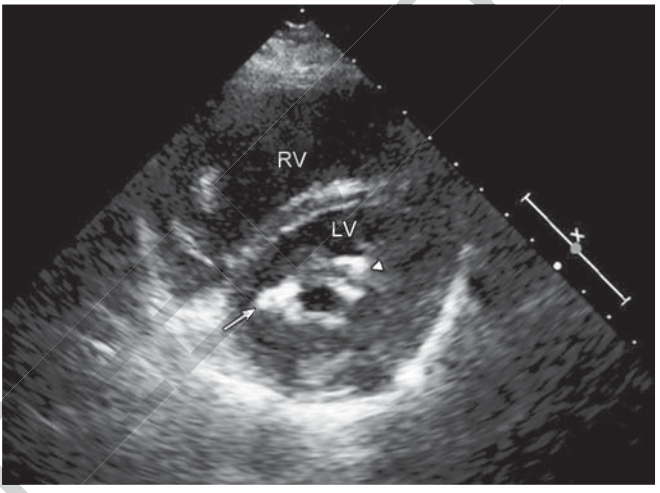

Fig. 11.15: Bilateral commissural calcium in 60-year-old female with severe MS. This is a contraindication of PMV
Abbreviations: LV, left ventricle; RV, right ventricle

Fibrotic valves as evidenced by bright echogenic valve tissue gives inferior results compared to nonfibrotic valves. Fibrotic valves usually yield less to balloon dilatation.

SUBVALVAR PATHOLOGY

Subvalvar pathology (SVP) is found to be an important predictor of the outcome of PMV. Higher grades of SVP is associated with poor outcomes after PMV. The subvalvar region is the secondary orifice of the mitral valve, which gets narrowed by rheumatic process.

JAYPEE BROTHERS

According to the original description by Wilkins et al[9] subvalvar thickening usually requires a series of modified views to assess it properly. In the parasternal long axis view, the standard alignment should be tilted medially and laterally so that the long axis of each papillary muscle and its attached chordal apparatus can be examined in turn. From the apical window, the extent of subvalvar shortening and scar will be best viewed in a four chamber view with the transducer angled more posteriorly into the left ventricle, or from a foreshortened two chamber view angled medially and laterally.[9]

Detailed description about the assessment of the subvalvar apparatus is given in Chapter 13.

Chambers, Septum and Thrombi

Structures other than mitral valve also need to be assessed while evaluating the patient for PMV. The structures are left atrium including the left atrial appendage and the interatrial septum.

LEFT ATRIUM

The left atrium will be dilated in MS (Figs 11.16 and 11.17). The size of the left atrium depends on the severity of the stenosis, duration of obstruction and the presence of mitral regurgitation. The size of the left atrium will increase as the severity of stenosis increases. In some patients with long standing MS as seen in developing countries like India, we may come across very large left atria, called the "aneurysmal LA".

The other structure which needs to be evaluated very closely is the left atrial appendage. It is usually seen in the PSAX view, but it is sometimes difficult to obtain a good image. If we can identify a thrombus in the LAA in transthoracic echocardiography, we can avoid a TEE (Figs 11.17 to 11.19).

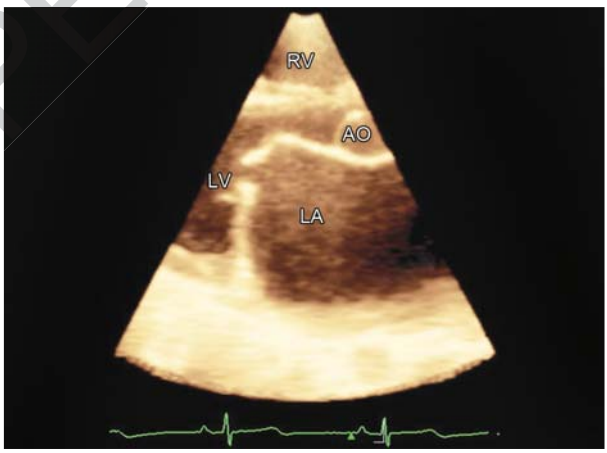

Fig. 11.16: 3D echocardiographic image recorded online using the matrix array probe in PLAX view showing the dilated LA, thickened and doming mitral valve
Abbreviations: RV, right ventricle; AO, aorta; LV, left ventricle; LA, left atrium

JAYPEE BROTHERS

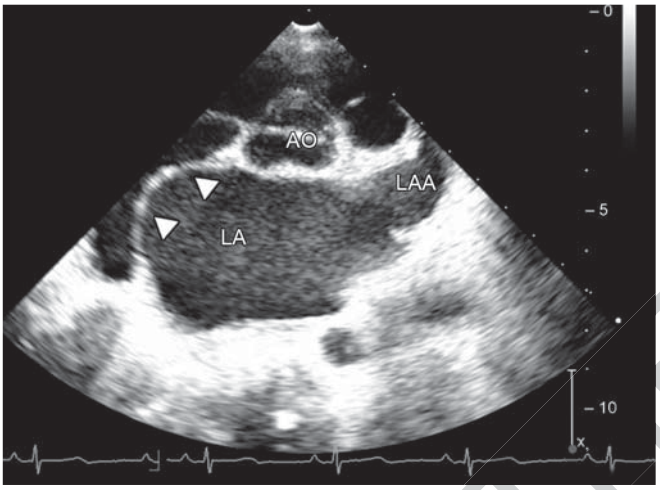

Fig. 11.17: PSAX view showing the dilated left atrium, left atrial appendage which is free of thrombus and bulging IAS towards the right atrium (arrow heads)
Abbreviations: LA, left atrium; AO, aorta; LAA, left atrial appendage

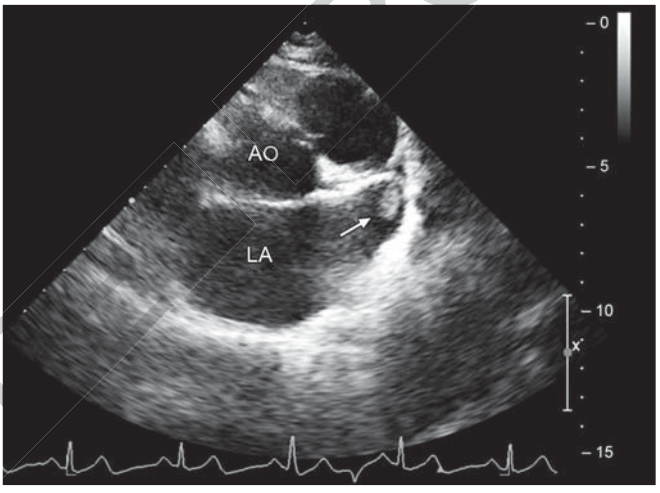

Fig. 11.18: A small thrombus in the apex of the left atrial appendage (PSAX view)
Abbreviations: LA, left atrium; AO, aorta

Left Ventricle

The left ventricle is usually normal in size or slightly smaller in mitral stenosis due to chronic under filling. If the LV is dilated, it may be due to the presence of LV dysfunction (which can be seen in few cases of MS due to extension of the rheumatic pathology into the LV) or most commonly due to the presence of aortic regurgitation or mitral regurgitation. Other uncommon causes are the presence of other diseases like coronary artery disease.

JAYPEE BROTHERS

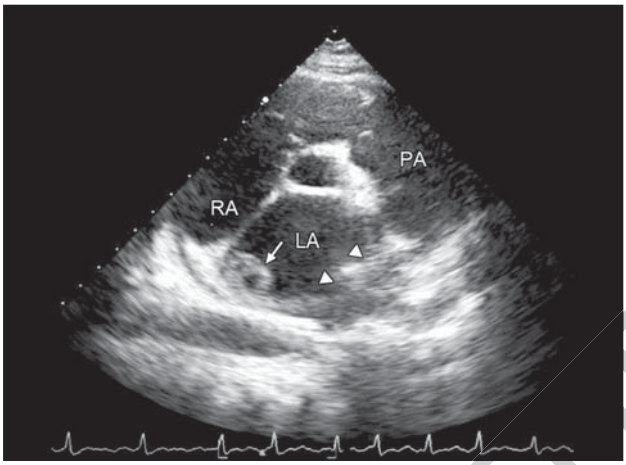

Fig. 11.19: TTE picture showing two thrombi (arrow and arrowheads) in the left atrium. The thrombi shown by the arrow shows partial lysis after initiation of anticoagulation
Abbreviations: RA, right atrium; LA, left atrium; PA, pulmonary artery

Interatrial Septum

The interatrial septum is to be evaluated in detail prior to PMV in order to plan the the transseptal puncture. In severe MS, the IAS may be bulging to the right atrium (Figs 11.17, 11.20 and 11.21) making the transseptal puncture difficult (Figs 11.19 and 11.21). The orientation of the IAS is altered since the LA is dilated and this should be borne in mind while attempting the transseptal puncture. Occasionally, we may come across Lutembacher syndrome which is a combination of rheumatic MS and congenital ASD (Figs 11.22A and B).

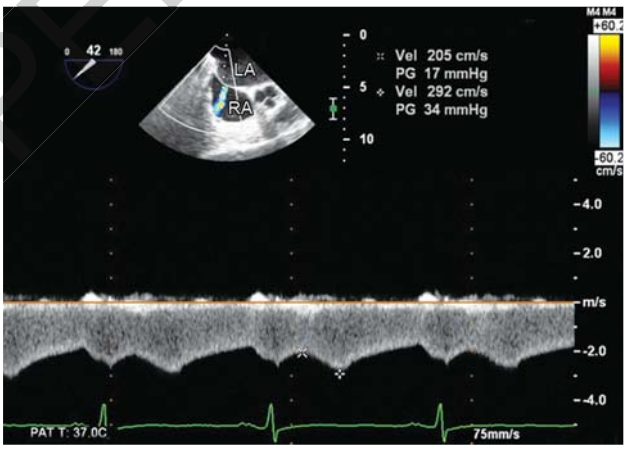

Fig. 11.20: Residual iatrogenic ASD in a patient planned for re-PMV for mitral re-stenosis. *Note* the high gradient of 17 to 32 mm Hg between the left and right atrium, indicative of the high left atrial pressure
Abbreviations: RA, right atrium; LA, left atrium

JAYPEE BROTHERS

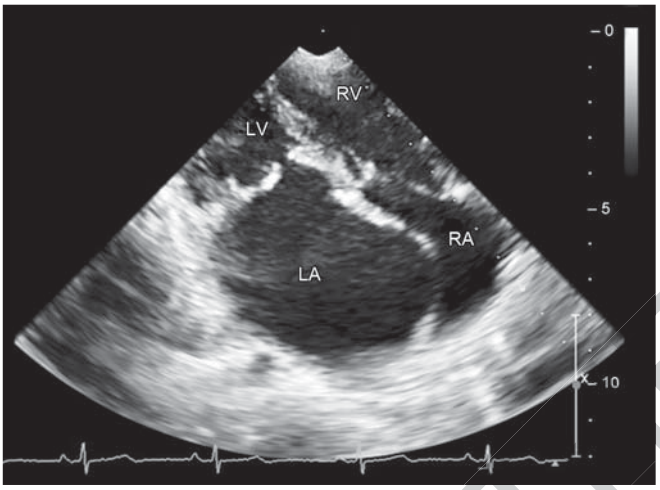

Fig. 11.21: A4C view showing dilated left atrium, thickened and doming mitral valve and the bulging of the IAS towards the right atrium
Abbreviations: RA, right atrium; LV, left ventricle; LA, left atrium; RV, right ventricle

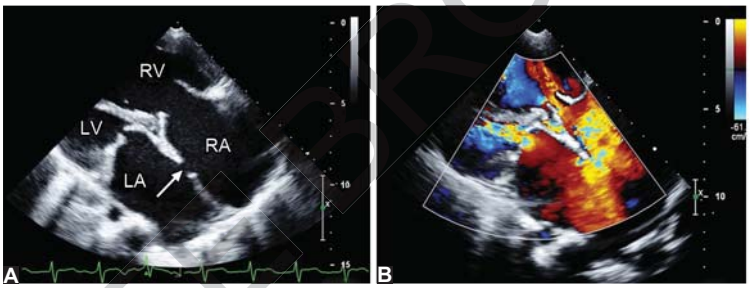

Figs 11.22A and B: Lutembacher syndrome: (A) Showing doming mitral valve and a defect in the IAS, (B) Color flow mapping showing flow through the ASD and the turbulence across the MV
Abbreviations: RA, right atrium; LV, left ventricle; LA, left atrium; RV, right ventricle

Sometimes we may come across patients planned for a re-PMV for mitral restenosis. Some may have residual ASD which is a remnant of the last procedure. The flow across the ASD will be of high gradient because of the very high left atrial pressure (Fig. 11.20).

ASSESSMENT OF LESIONS IN OTHER VALVES

Another important use of echocardiography is the assessment of the lesions in other valves, which even alters the management of the patients (Figs 11.23 to 11.26). For example, a patient with severe MS and significant aortic valve disease will preferably have double valve replacement than PMV alone.

A patient having associated aortic stenosis or tricuspid valve stenosis (Figs 11.23 and 11.24), may be planned for percutaneous aortic valvotomy or percutaneous tricuspid valvotomy along with PMV.

JAYPEE BROTHERS

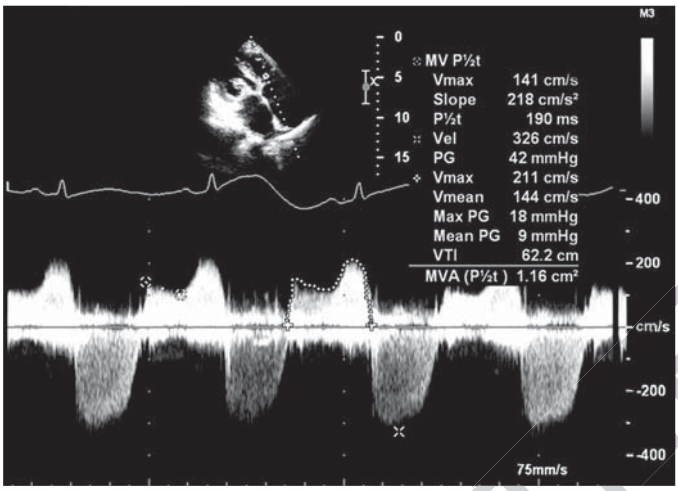

Fig. 11.23: Doppler flow across the tricuspid valve. Shows significant TS with a mean gradient of 9 mm Hg. TR jet peak velocity measured is 36 mm Hg indicating mild PAH

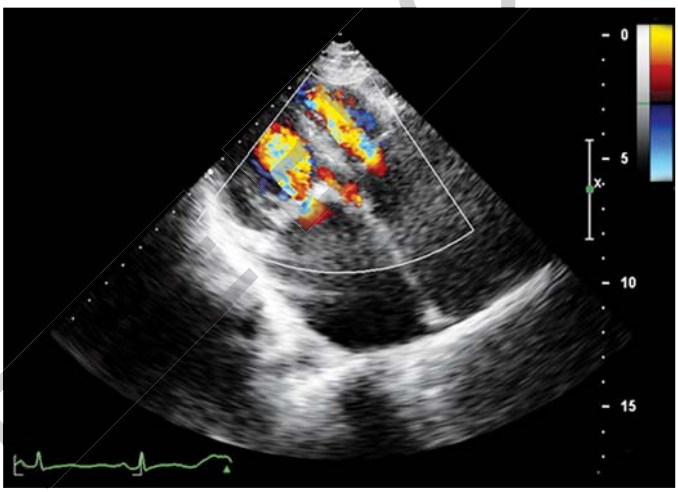

Fig. 11.24: A patient with both mitral and tricuspid stenosis. Color flow imaging shows turbulent flows across mitral and tricuspid valves in diastole

TRANSESOPHAGEAL ECHOCARDIOGRAPHY IN PMV

Transesophageal echocardiography is an essential part of evaluation of the patient prior to PMV. It is useful in the following situations:

1. To rule out left atrial or LA appendage thrombus.
2. Assessment of mitral regurgitation
3. Assess associated lesions like AR
4. Assess the septum, to aid in septal puncture.

Since, the resolution of TTE is poor to image the left atrium and LA appendage, TEE is essential in ruling out thrombi in the left atrium. It is

JAYPEE BROTHERS

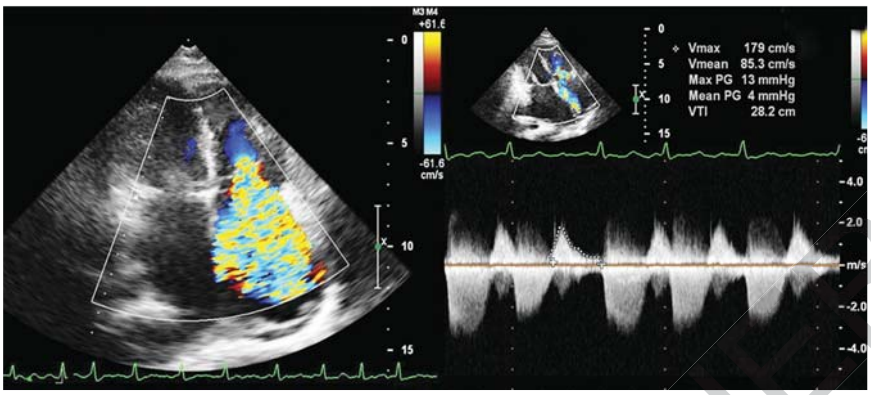

Fig. 11.25: Severe TR in a patient with severe MS and organic tricuspid valve disease. Doppler tracing is seen by the side showing tricuspid valve flow gradient of 4 mm Hg and a RVSP of 50 mm Hg indicating moderate PAH

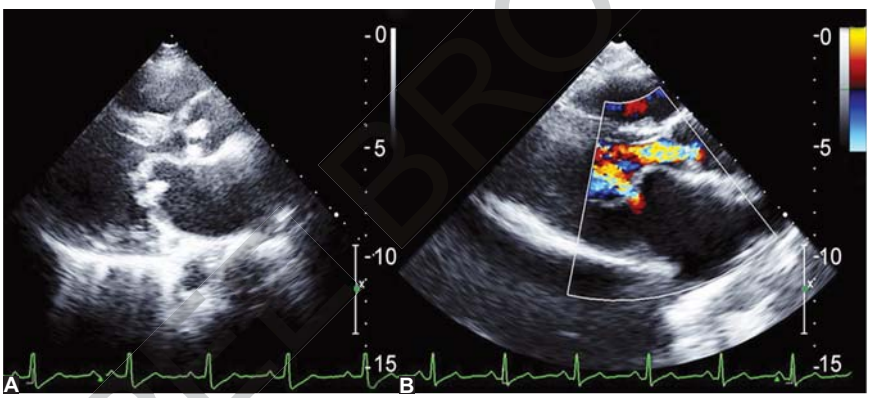

Figs 11.26A and B: PLAX view showing severely thickened aortic and mitral valves in a patient with severe MS and aortic valve disease (A). Color Doppler flow imaging showing aortic regurgitation and mitral stenosis (B)

mandatory to do a TEE and rule out left atrial thrombi before PMV. Images of LA thrombi in TEE are available in Chapter 53. Sometimes pectinate muscles in the left atrial appendage can mimic thrombi. Pectinate muscles are finger like projections which project into the LAA cavity (Fig. 11.27). Usually, they will have the same echotexture as the LAA wall which helps to differentiate them from LA thrombus.

Sometimes in patients with poor TTE windows, TEE can be used to assess the morphology of the valve, the interatrial septum and aortic valve (Figs 11.28 to 11.32).

Mitral regurgitation can be very well-assessed with TEE in multiple views (Fig. 11.33). So when the patient is taken up for TEE prior to PMV, it is always better to assess MR in two views.

JAYPEE BROTHERS

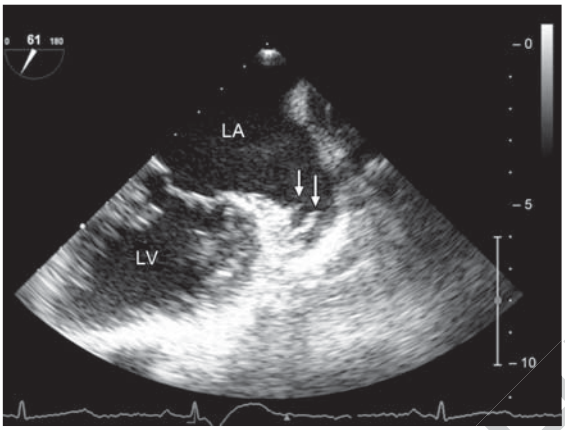

Fig. 11.27: TEE showing LAA, with finger like projections of pectinate muscles
Abbreviations: LV, left ventricle; LA, left atrium

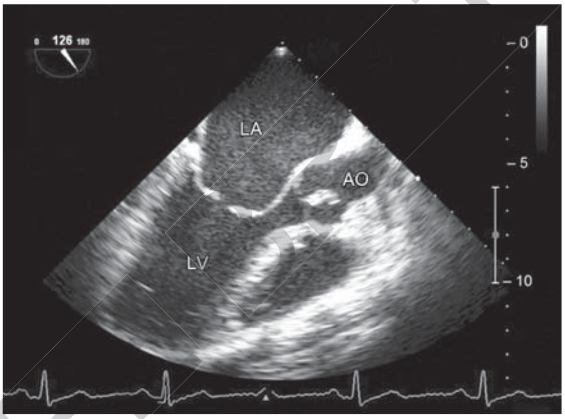

Fig. 11.28: Doming mitral valve—TEE image
Abbreviations: LV, left ventricle; LA, left atrium; AO, aorta

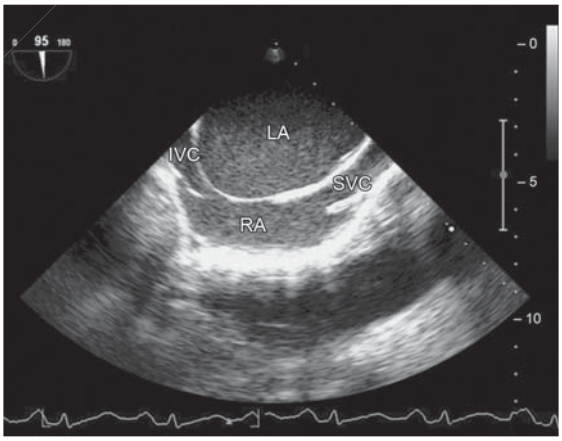

Fig. 11.29: TEE bicaval view showing bulging septum towards the RA; *Abbreviations:* RA, right atrium; IVC, Inferior vena cava; LA, left atrium; SVC, superior vena cava

JAYPEE BROTHERS

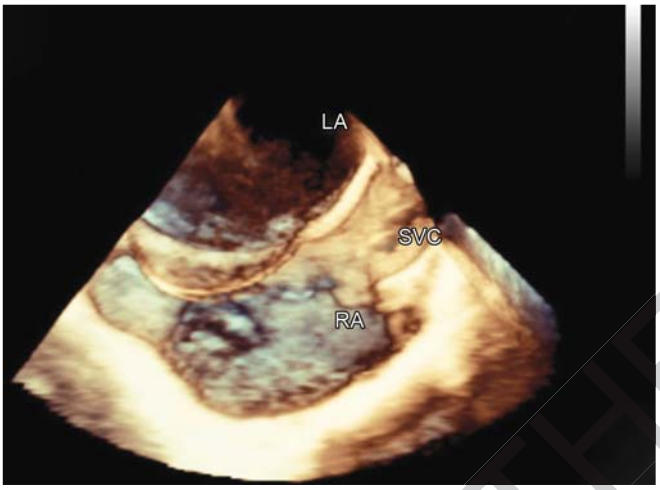

Fig. 11.30: 3D TEE bicaval view showing bulging septum towards the RA
Abbreviations: LA, left atrium; SVC, superior vena cava; RA, right atrium
(*Courtesy*: Dr S Sivasankaran, Dr Anees T, SCTIMST, Trivandrum)

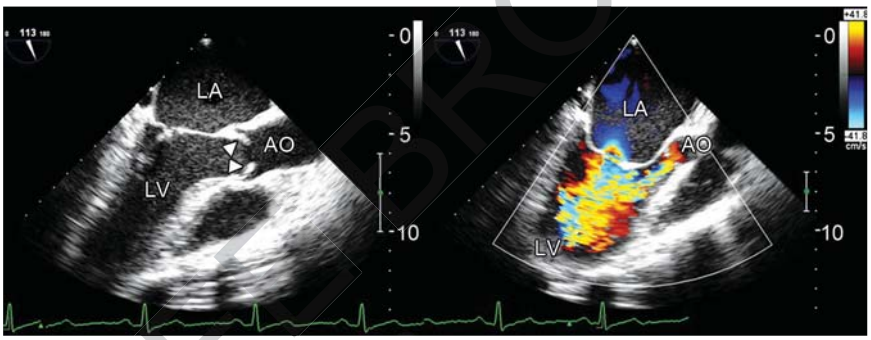

Fig. 11.31: TEE pictures showing thickened and doming aortic valve (arrowheads—panel A) and color flow mapping showing severe turbulence across mitral valve and mild-moderate aortic regurgitation in a patient with aortic and mitral valve disease. Since, the aortic valve disease was mild-moderate, patient underwent successful PMV.
Abbreviations: LA, left atrium; LV, left ventricle; AO, aorta

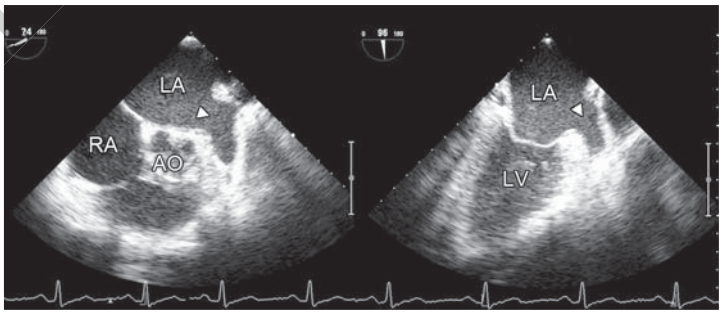

Fig. 11.32: TEE pictures showing the SAX (left) and LAX (right) views of the normal LAA without thrombus or LASEC
Abbreviations: RA, right atrium; LA, left atrium; LV, left ventricle; AO, aorta

JAYPEE BROTHERS

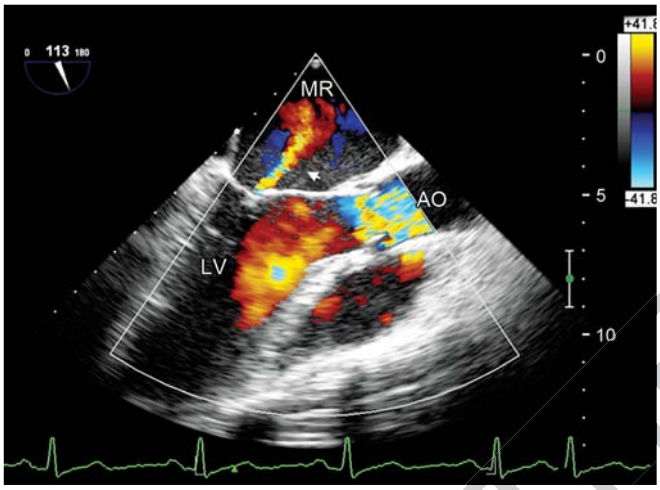

Fig. 11.33: TEE picture (110°) showing thin central jet of MR. This indicates mild MR
Abbreviations: MR, mitral regurgitation; LV, left ventricle; AO, aorta

DOPPLER ASSESSMENT OF MITRAL VALVE

Assessment of mitral valve by Doppler is important in assessing the severity of valve lesion, the response to balloon dilatation and also the presence and severity of mitral regurgitation.

The diastolic jet of mitral stenosis (MS) is usually M-shaped (Fig. 11.34). The initial peak is the E wave of early diastole and later peak is the A wave of atrial systole. In mitral stenosis, there is no gap between the two as the pressure gradient is never zero, indicating that there is no diastasis or equalization of atrial and ventricular diastolic pressures. In atrial fibrillation, the A wave will be absent.

The Doppler assessment of MV is usually done in the A4C view, where the flow is aligned to the probe. Color flow can aid in getting a good Doppler signal. Continuous wave Doppler is preferred.

Once the flow signals are obtained, the morphology of the signal and the quantification of the signal gives information about the severity of the valve lesion.

Since, the flow can vary with each cardiac cycle, it is ideal to measure three cardiac cycles and obtain the average even in those patients in sinus rhythm. In AF it is recommended to measure 5 cardiac cycles and average to get the correct gradient and the valve area.

This mean gradient represents the mean of the multiple instantaneous gradients ($p = 4V^2$) and is not calculated from the calculated mean velocity.[15] We have to record the heart rate always, as the mitral valve gradient will increase proportional to the heart rate.

Once the mitral inflow velocity signals are traced out, the integrated software in the echocardiographic equipment will calculate and give the mean and peak velocities. The mean gradient is the most important.

JAYPEE BROTHERS

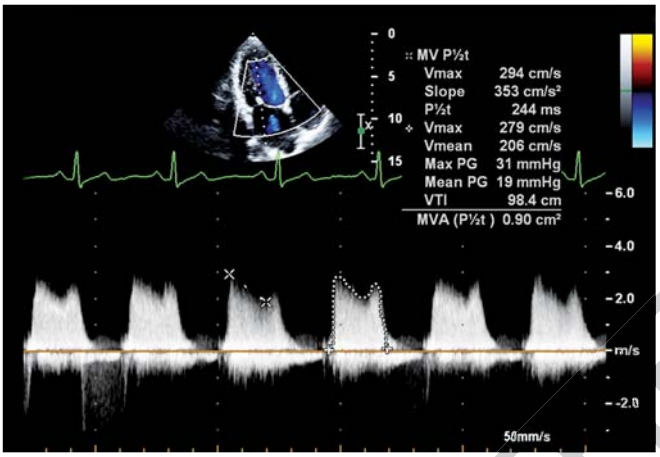

Fig. 11.34: Mitral inflow velocities in a patient in sinus rhythm showing "M" pattern. This shows the measurement mitral valve gradients in a patient with severe MS, the mean gradient here is 19 mm Hg and peak gradient is 31 mm Hg. The picture also shows the calculation of valve area using the pressure half time method. Valve area obtained is 0.9 cm^2

Maximal or the peak gradient which is derived from the peak mitral velocity, is influenced by left atrial compliance and LV diastolic function.[6]

In the presence of significant MR or high cardiac output states, there is a significant disproportionate increase in the early transmitral velocity and gradient, compared to the mean gradient. This exaggerated early pressure gradient can be a clue to the presence of unrecognized MR in mitral stenosis.

Even though the mean gradient is considered a more reliable marker, it is also influenced by heart rate, mitral regurgitation and cardiac output.

PRESSURE HALF-TIME

Pressure half-time (PHT) analysis is another method used to assess the MVA. PHT is defined as the time interval in milliseconds between the maximum mitral gradient in early diastole and the time point where the gradient becomes half of the peak initial value. Since, it is found that the decline of the velocity of diastolic transmitral blood flow is inversely proportional to mitral valve area, MVA is derived using the empirical formula—MVA = 220/PHT (Table 11.3).

PHT is estimated by tracing the deceleration slope of the E-wave on Doppler spectral display of transmitral flow. Then the valve area is automatically calculated by the software integrated with the echocardiographic equipment. In patients with atrial fibrillation, we should avoid measurement of mitral flow from short diastoles and average at least five different cardiac cycles.[6]

The deceleration slope is sometimes bimodal, the decline of mitral flow velocity being more rapid in early diastole than during the following part of the E-wave (Fig. 11.35). In these cases, it is recommended that the deceleration slope be traced in mid-diastole rather than in early disatole.[6,13]

JAYPEE BROTHERS

Table 11.3: Severity of MS based on pressure half-time

Severity of MS	*PHT (msec)*
Mild	<150
Moderate	150–219
Severe	>220

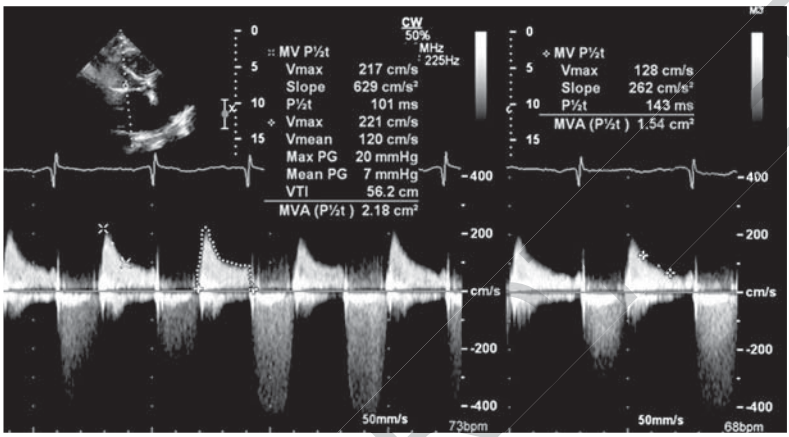

Fig. 11.35: The fallacy in estimating MVA by PHT method. When the initial part of the tracing is used, the MVA is coming as 2.18 cm^2, but when the middle part of the tracing is used, the MVA is only 1.54 cm^2

Advantages of Pressure Half-time

1. Less dependent on heart rate.
2. Less dependent on flow across the valve.
3. Useful in patients with varying R-R intervals like AF or other arrhythmias.
4. In the presence of ASD following PMV.

Disadvantages of Pressure Half-time

1. Diastolic dysfunction of the LV can alter PHT (e.g. LVH). Older patients with MS who have associated systemic hypertension or aortic stenosis may have LVH.
2. Aortic regurgitation: Underestimates the severity of MS. AR increases the left ventricular pressure more quickly in diastole and shortens the PHT.
3. The compliance changes which happens during PMV can affect the PHT. So, it is better to wait for 48–72 hours to calculate the MVA using PHT method as the compliance properties get settled in 2–3 days following PMV.[14]
4. Significant MR underestimates the MVA obtained by PHT. The explanation is the exaggeration of early transmitral flow velocity and gradients across the mitral valve.[15]
5. In some patients with the mitral valve pressure tracing having a concave shape, PHT measurement may not be feasible.

JAYPEE BROTHERS

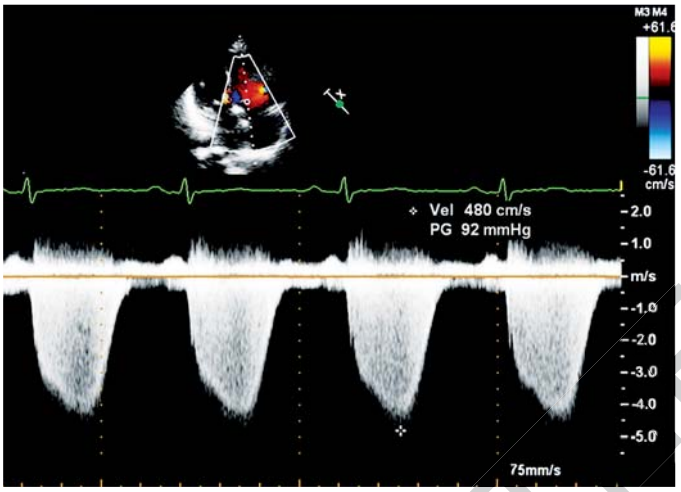

Fig. 11.36: TR velocity being measured to indirectly assess pulmonary hypertension. Here the estimated PA systolic pressure is 92 + 10 = 102 mm Hg

PULMONARY HYPERTENSION

Assessment of pulmonary hypertension is important when evaluating a patient for PMV. Presence of pulmonary hypertension influences the decision whether the patient should be sent for PMV or not.

Pulmonary hypertension is usually estimated indirectly from measuring the TR jet velocity and adding the estimated RA pressure to the RV-RA gradient (Fig. 11.36). The details of this measurement is given in Chapter 57. Also the mean PA pressure can be estimated from the PR jet also, by measuring the peak PR and the end PR velocities.

PERIPROCEDURAL MONITORING

During PMV, monitoring by echocardiography is a must. TTE is the most commonly used modality since TEE requires intubation and ventilation. TTE is used in the following situations:

1. To see the response to PMV (commissural splitting) with each balloon dilatation and to facilitate graded dilatation.
   Since, the pressure tracings in the laboratory may vary depending on the heart rate or filling pressure, it may not always be reliable to be guided by the pressure data alone. So, imaging by echocardiography helps in choosing the size of the next balloon. 2D imaging and planimetry is the preferred modality as it remains independent of the loading conditions, heart rate and mitral regurgitation.
2. To assess MR. Increase in the grade of MR by two or development of moderate-to-severe MR is an indication to stop the procedure. One grade increase in MR should not deter the operator from using higher balloon diameters and planning further dilatations.

JAYPEE BROTHERS

3. To assess complications related to transseptal puncture-pericardial tamponade and pericardial effusion. To detect pericardial effusion, echocardiography is a must in the cathlab. To assess the response to pericardial aspiration also, echocar-diography is essential.
4. To aid in balloon entry into the left ventricle. In patients with very large left atria, entry into the LV may be difficult. TTE aids in such situations where the valve orifice can be located and the balloon directed accurately.
5. To aid in transseptal puncture.

Successful PMV

A successful PMV procedure is defined as a split of one or more mitral valve commissures (Figs 11.37 and 11.38) with:

1. An increase in mitral valve area of at least 50% from the basal
2. A final valve area of >1.5 cm^2
3. Absence of sellers grade of >2 MR.

POST-PMV ASSESSMENT (FIGS 11.37 and 11.38)

Echocardiography is the imaging modality of choice immediately following PMV and also on follow-up. Planimetric measurement of MVA using 2D echocardiography is the technique of choice as it is not affected by MR and also shunting through the iatrogenic ASD. Since, stretching of the valve during PMV can overestimate the valve area, it is advisable to measure the valve area on the next day prior to discharge.

If the PMV result is inadequate, the symptoms of the patient should be reassessed and MVR or OMV should be considered as an option.

MR should be assessed and the grade and the mechanism of MR evaluated in detail. This is important in planning management of those patients who

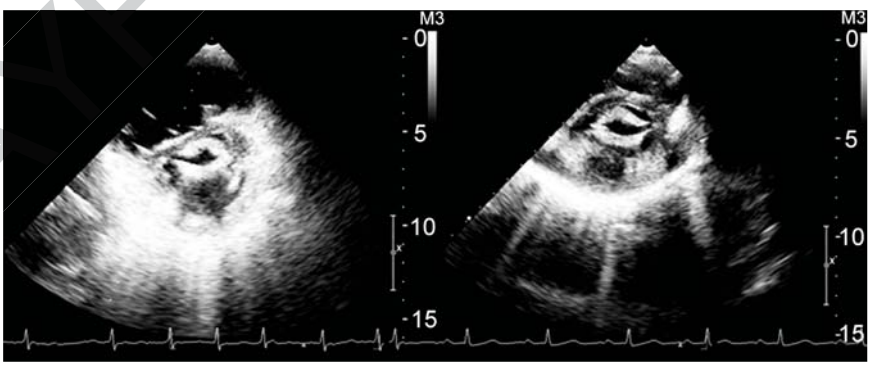

Fig. 11.37: Post-PMV echocardiography. Left picture showing a valve with fully open medial commissure and the right picture showing a valve with a fully open lateral commissure

JAYPEE BROTHERS

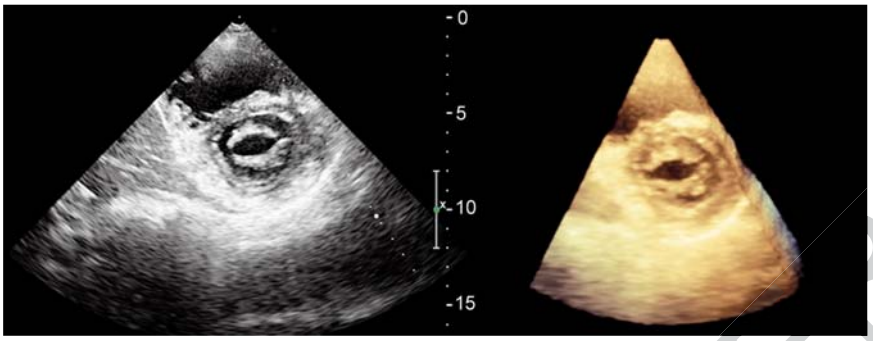

Fig. 11.38: Post-PMV echocardiography. Left picture showing a valve with a fully open commissures and the right picture showing the same valve imaged by 3D matrix array probe, showing both the commissures which are open

develop moderate-to-severe mitral regurgitation after PMV. Commissural MR usually regresses on follow-up. But MR is usually progressive if it is due to either tear of the valve or damage to the chordal structures and needs to be tackled by surgery as early as possible.

LEFT ATRIAL FUNCTION (SEE CHAPTER 14)

Assessment of left atrial function is important when evaluating a patient prior to PMV. The detailed description of assessment of left atrial function is provided in Chapter 14.

Mitral Regurgitation

The mechanism of MR in rheumatic mitral stenosis is restriction of leaflet motion. The exception to this is the MR which occurs after percutaneous mitral commissurotomy. It can occur by three mechanisms, tear of the leaflet, damage to the subvalvar structures or excessive split of commissures (Figs 11.39 and 11.40). It is reported that there are three characteristic anatomic features associated with the development of significant MR after PMV: (a) uneven mitral leaflet thickening, (b) severe and extensive subvalvular deformation, and (c) commissural calcification.[16]

EXERCISE ECHOCARDIOGRAPHY

Exercise increases the heart rate and the flow across the mitral valve due to increase in cardiac output. Increase in HR reduces the diastolic filling period and increases the gradients. In patients with disproportionate symptoms and low resting gradients, we re-evaluate the gradients after exercise and if the gradients are high, we advise intervention.

JAYPEE BROTHERS

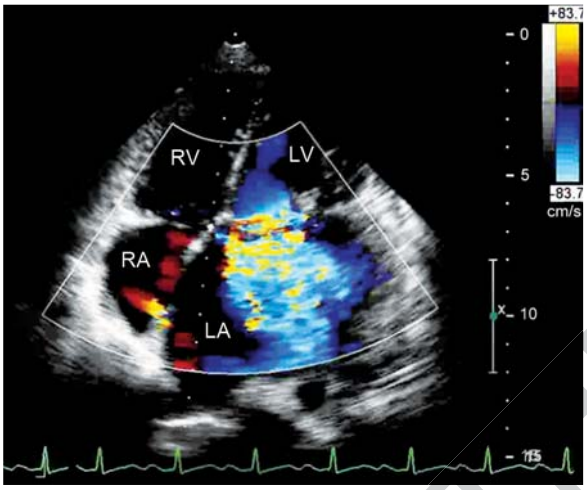

Fig. 11.39: TTE picture showing moderate-to-severe MR following PMV. Iatrogenic ASD following transseptal puncture shunting left to right is also seen
Abbreviations: LA, left atrium; RA, right atrium; LV, left ventricle; RV, right ventricle

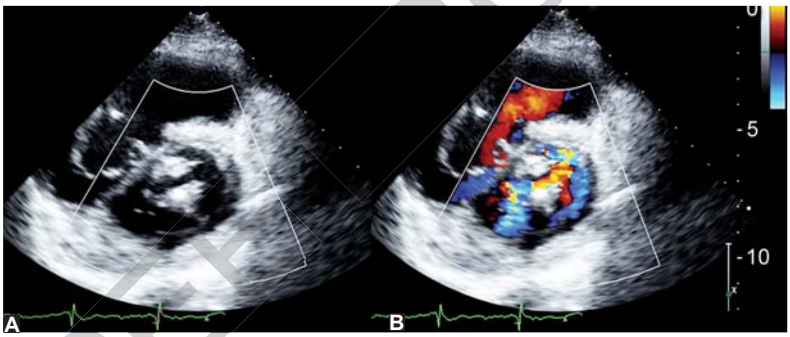

Fig. 11.40: Commissural MR. This echocardiographic image in PSAX view showing a very fibrotic mitral valve following a successful PMV with both commissures open (left). The image on the right shows color flow imaging revealing MR through both the commissures. MR through the commissures are usually benign and will come down on follow-up

Influence of MS in the Assessment of Other Valve Lesions

The severity of AS may be underestimated as the decreased stroke volume due to MS reduces the aortic gradient. By the same principle presence of severe TS can underestimate the severity of MS.

PREDICTIVE VALUE OF ECHOCARDIOGRAPHIC ASSESSMENT OF MV MORPHOLOGY BEFORE PMV

It is a known fact that the outcome of PMV is influenced by the morphology of the valve, the severity of the lesion, the presence of associated lesions and the chamber anatomy and morphology.

JAYPEE BROTHERS

Initial reports stressed on the predictive value of valve anatomy on the outcomes, as assessed by echocardiography.[9,17–19] Subsequent publications have been less enthusiastic and found only a weak correlation[20–22] or none at all[23] between echocardiographic scores and the initial increase in mitral valve area (MVA). Also, data concerning the value of anatomy for prediction of severe MR were even more controversial.[24]

This shows that anatomy is only a relative predictor of immediate results. Other factors must be taken into consideration, such as old age, history of previous commissurotomy, higher NYHA class, atrial fibrillation, female gender, small initial MVA, higher degree of MR before PMV or large left atrial size.[25,26]

So, the prediction of immediate results of PMV is multifactorial based on anatomic, clinical and procedural variables.[27] Numerous factors have been studied till now, many of which were found either univariate or multivariate predictors of poor outcome post-PMV.

Echocardiographic Variables and Their Predictive Value

The major echocardiographic variables assessed when a patient is evaluated prior to PMV are:

A. Morphology of the mitral valve
B. Pre-procedural mitral regurgitation (Figs 11.41 and 11.42)
C. Mitral valve area prior to PMV
D. Left atrial size.

Morphology of the Mitral Valve

Several studies were performed to evaluate the echocardiographic parameters by which the outcome of the procedure can be predicted. Reid et al.[10,11] estimated the flexibility of the MV by two-dimensional echocardiography, using a ratio of the angulation of mid leaflet in mid diastole and the leaflet length (Fig. 11.43).

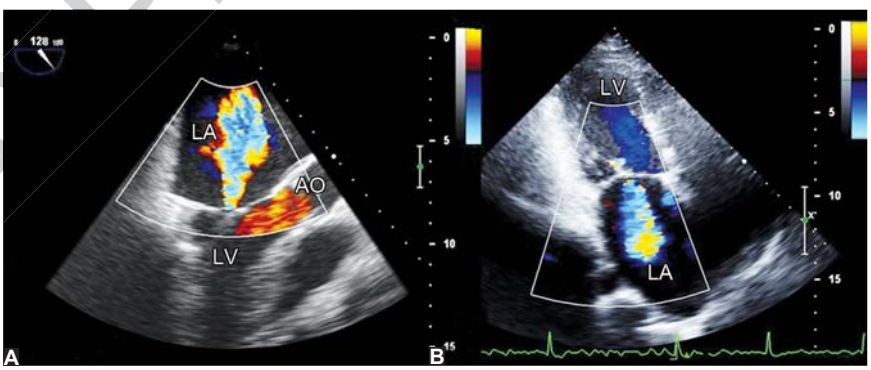

Fig. 11.41: Left-TEE imaging shows central jet, 2-3+ MR. Right-TTE imaging showing central jet of MR. This is not usually a contraindication for PMV since the mechanism of MR is leaflet restriction. This can sometimes decrease following PMV

Abbreviations: LA, left atrium; LV, left ventricle; AO, aorta

JAYPEE BROTHERS

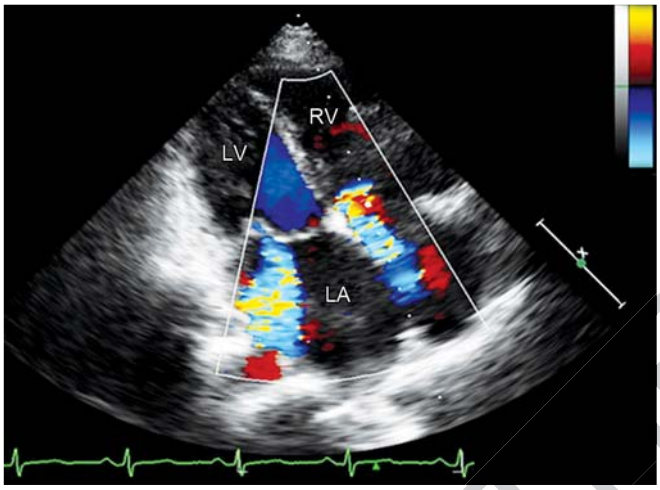

Fig. 11.42: TTE picture showing lateral jet of MR reaching up to the pulmonary veins. This indicates moderate MR and is usually considered a contraindication to PMV. TR jet also is shown indicating moderate TR
Abbreviations: LV, left ventricle; RV, right ventricle; LA, left atrium

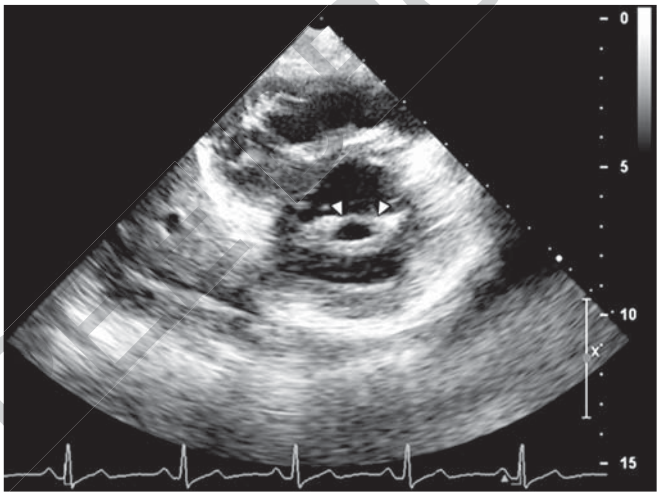

Fig. 11.43: Non-uniform thickening of the valve. In this valve we can see that the middle of the AML is less thickened (between the arrows) than the other areas of the valve and the commissures

Mitral Valve Echocardiographic Scoring Systems

Wilkins scoring system: In 1988, Wilkins' and coworkers[9] from "Massachusetts General Hospital" in Boston (USA), proposed a scoring system to predict the outcome of PMV. They used 4 parameters which were found by previous reports on surgical commissurotomy to predict outcome; MV calcification, thickening, mobility, and subvalvular fibrosis (Table 11.4). A total score is then calculated. They found their score to be the only independent predictor of immediate

JAYPEE BROTHERS

Table 11.4: Grading of the mitral valve characteristics from the echocardiographic examination

Grade	*Leaflet mobility*	*Valvular thickening*	*Subvalvular thickening*	*Valvular calcification*
1	Highly mobile valve with restriction of only the leaflet tips	Leaflets near normal (4–5 mm)	Minimal thickening of chordal structures just below the valve	A single area of increased echo brightness
2	Midportion and base of the leaflet have reduced mobility	Mild leaflet thickening, marked thickening at the margins	Thickening of chordae extending up to one third of chordal length	Scattered areas of brightness confined to leaflet margin
3	Valve leaflets move forward in diastole mainly at the base	Thickening extends through the entire leaflets (5–8 mm)	Thickening extending to the distal third of the chordae	Brightness extending to the midportion of the leaflets
4	No or minimal forward movement of the leaflets in diastole	Marked thickening of all leaflet tissue (>8–10 mm)	Extensive thickening and shortening of all chordae extending to the papillary muscles	Extensive brightness through most of the leaflet tissue

The total echocardiographic score was derived from an analysis of mitral leaflet mobility, valvular and subvalvular thickening, and calcification, which were graded from 0 to 4 according to the above criteria. This gave a total score of 0 to 16 (Wilkins et al, 1988[9])

outcome. These findings were supported by two other reports published by the same group.[19,22]

However, they found that their score could not predict outcome uniformly in all patients. All patients with score <9 had optimal results and those with score >11 had suboptimal results. The score failed to predict outcome in patients with score of 9 to 11.[9]

Reid scoring system: In 1989, Reid and associates,[10] from the University of Southern California in the United States, proposed another scoring system. They used the following 4 parameters; leaflet motion, thickness, subvalvular disease and commissural calcium. A score 0 was assigned to each grade of mild, 1 to moderate and 2 to each grade of severe. Commissural calcium was scored as 0, 1 or 2 based on the number of commissures with calcium (Table 11.5).

JAYPEE BROTHERS

Table 11.5: Two-dimensional echocardiographic assessment of mitral valve morphology (Reid et al.1989[10])

Morphologic feature	*Definition*	*Grade*	*Score*
Leaflet motion	H/L ratio: • ≥0.45 • 0.26–0.44 • <0.25	 Mild Moderate Severe	 0 1 2
Leaflet thickness	MV/PWAo ratio: • 1.5–2 • 2.1–4.9 • ≥5.0	 Mild Moderate Severe	 0 1 2
Subvalvular disease	• Thin faintly visible chordae tendineae • Areas of increased density equal to endocardium • Areas denser than endocardium with thickened chordae tendineae	Absent-mild Moderate Severe	0 1 2
Commissural calcium	• Homogenous density of mitral valve orifice • Increased density of anterior/posterior • Increased density of both commissures	Absent One commissure Two commissures	0 1 2

H: Height of doming of mitral valve; L: Length of dome of mitral valve; MV: Mitral valve; PWAo: Posterior wall of aorta

Iung and Cormier score: Another scoring system which is popular is the Iung and Cormier score developed by the French interventionists (Table 11.6).

Table 11.6: The French Three – Group Grading (Iung and Cormier score)[27]

Echocardiographic group	*Mitral valve anatomy*
Group 1	Pliable noncalcified AML and mild subvalvular disease (thin chordae, >=10 mm long)
Group 2	Pliable noncalcified AML and severe subvalvular disease (thick chordae, <10 mm long)
Group 3	Calcification of mitral valve of any extent, as assessed by fluoroscopy, whatever the state of subvalvular apparatus

The Iung and Cormier scoring system is simpler and unique in that it considers the length of the chordae.

Another scoring system which is specific in predicting the development of mitral regurgitation is the MR score.

JAYPEE BROTHERS

MR Echocardiographic Score (Padial LR[24]): Thorough examination of surgically excised mitral valves revealed that 3 characteristic anatomic features were associated with the development of significant mitral regurgitation after PMV. They are uneven mitral leaflet thickening, severe and extensive subvalvular deformation, and commissural calcification. The original Wilkins mitral valve echocardiographic score was modified, with special emphasis on these three factors. This MR echocardiographic score could predict the development of severe MR following PMV with high sensitivity and specificity.

Ain Shams Scoring: A group from Ain Shams University in Egypt,[25] in 2008 suggested a novel scoring system for assessing the MV before PMV consisting only of 2 variables:

a. *Scoring of calcification*: Calcification was identified by localized areas of bright echo reflection affecting MV leaflets, seen in parasternal short-axis view at MV level. The absence of calcification was given a score of 0. Calcification localized to leaflet margins was given a score of 2, that extending to leaflet bodies was given a score of 4, while that involving the commissures (whether one or both) was given a score of 6. Calcification score was expressed out of 6.
b. *Scoring of subvalvular involvement*: Subvalvular involvement was identified by thickening of chordae tendineae and/or papillary muscles, seen in parasternal long-axis and apical four chamber views. The absence of subvalvular involvement was given a score of 0. Thickening involving less than half the chordal length was given a score of 2, that involving half or more a score of 4, while that involving the whole chordal length and papillary muscles was given a score of 6. The score of subvalvular involvement was expressed out of 6.

The total novel score is the sum of the calcification score and the score of subvalvular involvement, expressed out of 12.

This score at a cutoff point of 4 compared to Wilkins' score at a cut off value of 8 successfully predicted poor outcome with a higher sensitivity (86.7% versus 60%), higher specificity (82.9 versus 74.3%), and a better positive and negative predictive value (68.4 versus 50%, and 93.5 versus 81.3%, respectively). In multivariate logistic regression analysis it was the only independent predictor of poor outcome.

3D Echocardiographic Scoring System for Mitral Valve: Lastly, another group from Al-Azhar University in Egypt coworking with Erasmus University Medical Center in The Netherlands[28] introduced a real-time three-dimensional echcardiographic score (RT3DE score) for the assessment of MV morphology.

The new RT3DE morphology score (Table 11.7) was derived to include both MV leaflets and the subvalvular apparatus, guided by Wilkins's score. Each leaflet was divided into 3 scallops (anterolateral, A1 and P1; middle, A2 and P2; and posteromedial, A3 and P3) and scored separately (Figs 11.44A and B). The subvalvular apparatus was divided into 3 cut sections of the anterior and posterior chordae at 3 levels: proximal (valve level), middle, and distal (papillary muscle level). Each cut section was scored separately for chordal

JAYPEE BROTHERS

Table 11.7: RT3DE score of the mitral valve

	Anterior leaflet			*Posterior leaflet*		
	A1	**A2**	**A3**	**P1**	**P2**	**P3**
Thickness (0–6) (0 = normal, 1 = thickened)*	0–1	0–1	0–1	0–1	0–1	0–1
Mobility (0–6) (0 = normal, 1 = limited)*	0–1	0–1	0–1	0–1	0–1	0–1
Calcification (0–10) (0 = no, 1–2 = calcified)†	0–2	0–1	0–2	0–2	0–1	0–2
	Subvalvular apparatus†					
	Proximal third		*Middle third*		*Distal third*	
Thickness (0–3) (0 = normal, 1 = thickened)	0–1		0–1		0–1	
Separation (0–6) (0 = normal, 1 = partial, 2 = no)	0, 1, 2		0, 1, 2		0, 1, 2	

*Normal = 0, mild = 1 to 2, moderate = 3 to 4, severe $ 5.
†Normal = 0, mild = 1 to 2, moderate = 3 to 5, severe $ 6.

(Anwar et al. 2010)[55]

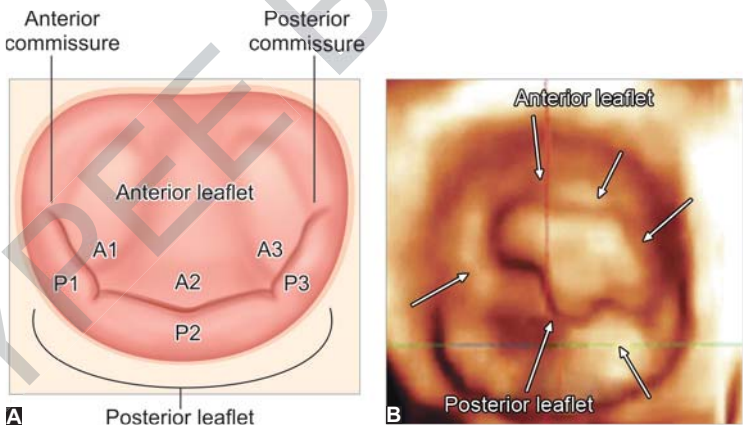

Figs 11.44A and B: (A) Schematic diagram showing the 3 scallops of each leaflet (A1, A2, A3, P1, P2, and P3). (B) Real-time three-dimensional echocardiographic en face view of the MV as seen from the ventricular aspect (Anwar et al. 2010) with permission from Elsevier, J Am Soc Echocardiogr. 2010;23(1):13-22

thickness and the separation in between. Thickness, mobility, and calcification for each MV scallop were assessed qualitatively and scored as follows: normal thickness and mobility were scored as 0 and abnormal thickness or restricted mobility as 1. An absence of calcification was scored as 0, calcification in middle

JAYPEE BROTHERS

scallop (A2 or P2) was scored as 1, and calcification of the commissural scallops of both leaflets (A1, A3, P1, and P3) was scored as 2. Scoring of the subvalvular apparatus included chordal thickness and the distance of separation between the chordae as follows: normal thickness was scored as 0 and abnormal thickness as 1, normal chordal separation (distance in between >5 mm) was scored as 0, partial separation (distance in between <5 mm) as 1, and absence of separation was scored as 2.

The individual RT3DE score points of leaflets and subvalvular apparatus is summed to calculate the total RT3DE score, ranging from 0 to 31 points. A total score of mild MV involvement is defined as <8 points, moderate MV involvement as 8 to 13 points, and severe MV involvement as ≥14 points.

The limitations of this RT3DE score are the limited availability of RT3DE machines, and the potential complexity of this score compared to the currently used Wilkins' score. Further assessment of this score and prospective validations from multi-institutional studies are needed.[29]

Global Echo-Doppler Scoring System

Another scoring system proposed is the Global Echo-Doppler Scoring System (GEDS).[30] It uses Wilkins score, ratio of leaflet lengths of anterior and posterior mitral leaflets, left atrial diameter, grade of MR, AV compliance, systolic Pulmonary artery pressure (PAP – mmHg)—each scoring from 1 to 2. A score of >7 gives a poor outcome.[30]

Problems Associated with Scoring Systems

The controversy of the published reports regarding the influence of echocardiographic scoring systems in the outcome of PMV may be related to the following factors:

1. Grading of the various anatomic features is a subjective, semiquantitative mode of evaluation and is thus exposed to a significant variability, particularly when it involves multiple investigators.[27]
2. Subvalvular disease is an important predictor of successful PMV and risk predictor of MR, and is often underestimated by both TTE and TEE.[27,31]
3. Absence of assessment of commissures in Wilkins' score.[27]
4. Most of the early reports compared patients undergoing procedures with different gadgets, which may have its influence on the outcome.
5. Most of the early reports were on the early learning curve of the technique used, which may have its influence on the outcome.
6. The components of the Wilkins' score may not have the same effect on the outcome, while the total echo score assumes that each of these variables is equally important. Thus, differential weightage of the individual components could result in a more predictive scoring system.[22]

However, some of the more recently published reports still find echocardiographic scoring as an independent predictor of outcome.[27,32]

Also, Stefanadis et al.[33] using the nontransseptal PMV in 441 patients (a multicenter experience), found the echocardiographic score, male gender,

JAYPEE BROTHERS

preprocedural MR and previous commissurotomy to be significant unfavorable predictors of immediate outcome. Balloon type was also a significant multivariate predictor of outcome. They found that patients with a score ≤8 had significantly higher rates of procedural success, greater final MVA and a lower incidence of significant postprocedural MR, compared to patients with higher scores.

Also, several reports showed that Wilkins' score can predict late outcome; restenosis and event free survival.[32,34]

So, echocardiographic assessment of the MV morphology is now used only as a guide for clinical decision-making, especially for selection of the appropriate balloon catheter size and balloon sizing.[31] In spite of its limitations (Table 11.8), Wilkins' score is still the most widely used score before PMV.

Table 11.8: Limitations of Wilkins' score (Goldstein and Lindsay, 2010 with permission)[29]

1. Echocardiography limited in ability to differentiate nodular fibrosis from calcification
2. Does not assess commissural involvement
3. Does not account for uneven distribution of pathologic abnormalities
4. Does not account for relative contribution of each variable (no weighting of variables)
5. Frequent underestimation of subvalve disease
6. Does not use results from transesophageal echocardiography or three-dimensional echocardiography

Recently, Massachusetts General Hospital coworking with 2 centers in Spain,[32] in a trial to improve the predictive power of Wilkins' score incorporated it in a multifactorial score including clinical, hemodynamic and other anatomic variables. These variables were selected based on multivariate analysis. Score constructed by an arithmetic sum of the number of PMV success predictors (age <55 years, NYHA classes I and II, pre-PMV MVA ≥1 cm^2, pre-PMV MR grade <2, echocardiographic score ≤8, and male sex) present for each patient. This multifactorial score showed a better sensitivity and specificity compared to Wilkins' score with an incremental ability to predict procedural success (defined as MVA ≥1.5 cm^2 with final MR grade <3) with a predictive power of 100% with a score of 6.

Preprocedural Mitral Regurgitation

The preprocedural mitral regurgitation was not found to predict the results after PMV in many reports,[19,21–24] but the importance of this factor is increasingly being recognized in many recent reports which evaluated either the univariate[35] or multivariate predictors of outcome.[24]

Iung et al. found that the benefit of using a larger balloon was observed only in the absence of significant initial MR.[35] Zhang et al. found that patients with pre-existing MR have relatively smaller MVA after PMV and higher incidence of later cardiac events.[36] These patients had a lower incidence of bicommissural splitting. The explanation of all these appears to be multifactorial:[37]

JAYPEE BROTHERS

1. These patients have more calcified MVs, more incidence of atrial fibrillation[36,37] and more valvular and subvalvular scarring than patients without MR.[27]
2. This cohort of patients has large left atrium.
3. A more conservative approach could have been used when dilating the valves of patients with mild MR in an attempt to prevent worsening of MR.[36]

Preprocedure MVA

Patients with smaller MVA would be expected to have more severe deformities of the MV structure and therefore a poorer result. This was found in most reports, which studied this factor.[27,35]

On the contrary, this variable failed to predict outcome in early reports from Massachusetts General Hospital.[19,22] But the same group in more recent reports found pre-PMV MVA to predict outcomes.[9,17] They explained their findings by the fact that, the patients included in their early studies had severe mitral stenosis with MVA in the range of 0.4 to 1 cm^2, which might obscure the effect of the initial MVA on outcome. They suggested that the effect of the initial MVA on the outcome may appear in reports including patients with larger MVA with less valve pathology who are expected to have more improvement in MVA by PMV.[9]

Left Atrial Size

Left atrial diameter was a significant predictor of outcome in most of the reports either as univariate[18,19] or multivariate.[19] Alfonso et al[20] found that patients with aneurysmally dilated left atrium (> 6 cm) had the following characteristics:

1. They were older, more symptomatic and had atrial fibrillation.
2. They had higher echo score usually as the result of thickened mitral leaflets with more severe subvalvular involvement.
3. They had larger left ventricles and a higher incidence of MR.
4. They had more frequently difficulties in crossing the interatrial septum, and also a higher rate of dilatation failure.

Other less proven factors which could influence the outcome of PMV are the mitral valve annulus diameter and the presence of significant TR.

Other Morphologic Variables Assessed Following PMV

However, not all patients with commissural splitting after the procedure were found to have an optimal MVA.[38] This suggested that the mechanism of successful PMV may be more complex than reported previously. Short-term improvements in MVA and symptoms that occur when commissures are not split may be attributed to other mechanisms, such as improvement of leaflet mobility secondary to disruption of the diseased submitral tissue.[26] The historical obsession of the MVA limited more creative ways of looking at

JAYPEE BROTHERS

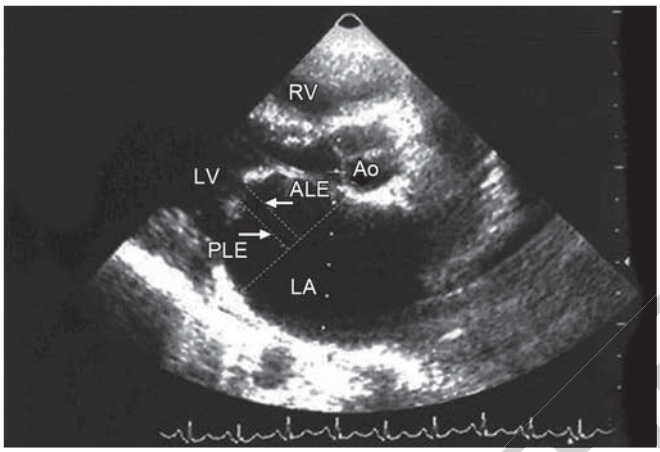

Fig. 11.45: Anterior and posterior leaflets excursion measured in parasternal long axis view

Abbreviations: RV, right ventricle; LV, left ventricle; LA, left atrium; Ao, aorta; ALE, anterior leaflet excursion; PLE, posterior leaflet excursion (Hasan-Ali, et al. 2007, with permission)[12]

the MV. It is assumed that assessment of the other changes produced in MV morphology may have an adjuvant value to the conventional measurement of the MVA.[12] These morphologic measurements are:

Valve mobility: It is assessed by measuring the anterior and posterior leaflets excursion. To measure the excursion; in the parasternal long axis view, at maximum doming in early diastole, a line is drawn at the level of the MV annulus (at the base of the leaflets), and then 2 perpendicular lines were dragged from the tips of the leaflets to that line (Fig. 11.45).

Subvalvular splitting: It is assessed by measuring the area subtended by the papillary muscles and chordae tendineae below the MV, measured at maximum doming of the valve leaflets in early diastole in apical long axis view; where the 2 papillary muscles and the chordae could be seen separated in profile. The subvalvular splitting area was found to increase significantly after PMV.[12]

Degree of commissural splitting: It is assessed in short axis parasternal view as regards the depth score of the splitted commissure. The score is assessed in each commissure as follows (No commissural splitting = 0, partial splitting of the commissure = 0.5, complete splitting of the commissure =1); then the score of both commissures is summed to give a total score of commissural splitting.[12]

CONCLUSION

As we have seen, echocardiographic evaluation is crucial in patient selection for PMV. It is also vital in periprocedural monitoring and also for follow-up of these patients undergoing PMV.

JAYPEE BROTHERS

REFERENCES

1. Perloff JK, Roberts WC. The mitral apparatus. Functional anatomy of mitral regurgitation. Circulation. 1972;46(2):227–39.
2. Silverman ME, Hurst JW. The mitral complex. Interaction of the anatomy, physiology, and pathology of the mitral annulus, mitral valve leaflets, chordae tendineae, and papillary muscles. Am Heart J. 1968;76(3):399–418.
3. Selzer A, Cohn KE. Natural history of mitral stenosis: a review. Circulation. 1972;45(4):878–90.
4. Lachman AS, Roberts WC. Calcific deposits in stenotic mitral valves. Extent and relation to age, sex, degree of stenosis, cardiac rhythm, previous commissurotomy and left atrial body thrombus from study of 164 operatively-excised valves. Circulation. 1978;57(4):808–15.
5. Harken De, Dexter L, Ellis LB, Farrand RE, Dickson JF 3rd. The surgery of mitral stenosis. III. Finger-fracture valvuloplasty. Ann Surg. 1951;134(4):722–42.
6. Helmut Baumgartner, Judy Hung, Javier Bermejo, et al. Echocardiographic assessment of valve stenosis: EAE/ASE recommendations for clinical practice. Eur J Echocardiography. 2009:10;1-25.
7. Vimal Raj BS, George P, Jose VJ. Mitral leaflet separation index-a simple novel index to assess the severity of mitral stenosis. Indian Heart J. 2008;60(6):563–6.
8. Holmin C, Messika-Zeitoun D, Mezalek AT, Brochet E, Himbert D, Iung B,et al. Mitral leaflet separation index: a new method for the evaluation of the severity of mitral stenosis? Usefulness before and after percutaneous mitral commissurotomy. J Am Soc Echocardiogr. 2007;20(10):1119-24.
9. Wilkins GT, Weyman AE, Abascal VM, Block PC, Palacios IF. Percutaneous balloon dilatation of the mitral valve: an analysis of echocardiographic variables related to outcome and the mechanism of dilatation. Br Heart J. 1988;60(4):299–308.
10. Reid CL, Otto CM, Davis KB, Labovitz A, Kisslo KB, McKay CR. Influence of mitral valve morphology on mitral balloon commissurotomy: immediate and six-month results from the NHLBI Balloon Valvuloplasty Registry. Am Heart J. 1992;124(3):657–65.
11. Reid CL, Chandraratna PA, Kawanishi DT, Kotlewski A, Rahimtoola SH. Influence of mitral valve morphology on double-balloon catheter balloon valvuloplasty in patients with mitral stenosis. Analysis of factors predicting immediate and 3-month results. Circulation. 1989;80(3):515–24.
12. Hasan-Ali H, Shams-Eddin H, Abd-Elsayed AA, Maghraby MH. Echocardiographic assessment of mitral valve morphology after Percutaneous Transvenous Mitral Commissurotomy (PTMC). Cardiovasc Ultrasound. 2007;5:48.
13. Gonzalez MA, Child JS, Krivokapich J. Comparison of two-dimensional and Doppler echocardiography and intracardiac hemodynamics for quantification of mitral stenosis. Am J Cardiol. 1987;60(4):327–32.
14. Harvey Feigenbaum. Fiegenbaum's Echocardiography. 6 Edition P 234, Chapter 8, Hemodynamics.
15. Mohan JC, Mukherjee S, Kumar A, Arora R, Patel AR, Pandian NG. Does chronic mitral regurgitation influence Doppler pressure half-time-derived calculation of the mitral valve area in patients with mitral stenosis? Am Heart J. 2004;148(4):703–9.
16. Hernandez R, Macaya C, Banuelos C, Alfonso F, Goicolea J, Iniguez A, et al. Predictors, mechanisms and outcome of severe mitral regurgitation complicating percutaneous mitral valvotomy with the Inoue balloon. Am J Cardiol. 1992; 70:1169-74.

JAYPEE BROTHERS

17. Nobuyoshi M, Hamasaki N, Kimura T, Nosaka H, Yokoi H, Yasumoto H, et al. Indications, complications, and short-term clinical outcome of percutaneous transvenous mitral commissurotomy. Circulation. 1989;80(4):782-92.
18. Vahanian A, Michel PL, Cormier B, Vitoux B, Michel X, Slama M, et al. Results of percutaneous mitral commissurotomy in 200 patients. Am J Cardiol. 1989;63(12):847–52.
19. Herrmann HC, Wilkins GT, Abascal VM, Weyman AE, Block PC, Palacios IF. Percutaneous balloon mitral valvotomy for patients with mitral stenosis. Analysis of factors influencing early results. J Thorac Cardiovasc Surg. 1988;96(1):33–8.
20. Alfonso F, Macaya C, Iniguez A, Banuelos C, Hernandez R, Goicolea J, et al. Comparison of results of percutaneous mitral valvuloplasty in patients with large (greater than 6 cm) versus those with smaller left atria. Am J Cardiol. 1992;69(4):355-60.
21. Herrmann HC, Ramaswamy K, Isner JM, Feldman TE, Carroll JD, Pichard AD, et al. Factors influencing immediate results, complications, and short-term follow-up status after Inoue balloon mitral valvotomy: a North American multicenter study. Am Heart J. 1992;124(1):160–6.
22. Abascal VM, Wilkins GT, O'Shea JP, Choong CY, Palacios IF, Thomas JD, et al. Prediction of successful outcome in 130 patients undergoing percutaneous balloon mitral valvotomy. Circulation. 1990;82(2):448–56.
23. Post JR, Feldman T, Isner J, Herrmann HC. Inoue balloon mitral valvotomy in patients with severe valvular and subvalvular deformity. J Am Coll Cardiol. 1995;25(5):1129–36.
24. Padial LR, Abascal VM, Moreno PR, Weyman AE, Levine RA, Palacios IF. Echocardiography can predict the development of severe mitral regurgitation after percutaneous mitral valvuloplasty by the Inoue technique. Am J Cardiol. 1999;83(8):1210–3.
25. Rifaie O, Esmat I, Abdel-Rahman M, Nammas W. Can a novel echocardiographic score better predict outcome after percutaneous balloon mitral valvuloplasty? Echocardiography. 2009;26(2):119-27.
26. Levin TN, Feldman T, Bednarz J, Carroll JD, Lang RM. Transesophageal echocardiographic evaluation of mitral valve morphology to predict outcome after balloon mitral valvotomy. Am J Cardiol. 1994;73(9):707–10.
27. Iung B, Cormier B, Ducimetière P, Porte JM, Nallet O, Michel PL, et al. Immediate results of percutaneous mitral commissurotomy. A predictive model on a series of 1514 patients. Circulation. 1996;94(9):2124–30.
28. Anwar AM, Attia WM, Nosir YFM, Soliman OII, Mosad MA, Othman M, et al. Validation of a new score for the assessment of mitral stenosis using real-time three-dimensional echocardiography. J Am Soc Echocardiogr Off Publ Am Soc Echocardiogr. 2010;23(1):13–22.
29. Goldstein SA, Lindsay J Jr. Do we need more echo scores for balloon mitral valvuloplasty? J Am Soc Echocardiogr Off Publ Am Soc Echocardiogr. 2010;23(1):23–5.
30. Mahfouz RA, Dewedar A, Elzayat A, Elawady W. Usefulness of the Global Echo-Doppler Score (GEDS) in selection of patients with mitral stenosis for percutaneous balloon mitral valvuloplasty. Cardiol J. 2014;21(2):152–7.
31. Lau KW, Hung JS, Ding ZP, Johan A. Controversies in balloon mitral valvuloplasty: the when (timing for intervention), what (choice of valve), and how (selection of technique). Cathet Cardiovasc Diagn. 1995;35(2):91–100.
32. Cruz-Gonzalez I, Sanchez-Ledesma M, Sanchez PL, Martin-Moreiras J, Jneid H, Rengifo-Moreno P, et al. Predicting success and long-term outcomes

JAYPEE BROTHERS

of percutaneous mitral valvuloplasty: a multifactorial score. Am J Med. 2009;122(6):581.e11–19.
33. Stefanadis CI, Stratos CG, Lambrou SG, Bahl VK, Cokkinos DV, Voudris VA, et al. Retrograde nontransseptal balloon mitral valvuloplasty: immediate results and intermediate long-term outcome in 441 cases—a multicenter experience. J Am Coll Cardiol. 1998;32(4):1009–16.
34. Palacios IF, Block PC, Wilkins GT, Weyman AE. Follow-up of patients undergoing percutaneous mitral balloon valvotomy. Analysis of factors determining restenosis. Circulation. 1989;79(3):573–9.
35. Iung B, Garbarz E, Doutrelant L, Berdah P, Michaud P, Farah B, et al. Late results of percutaneous mitral commissurotomy for calcific mitral stenosis. Am J Cardiol. 2000;85(11):1308–14.
36. Alfonso F, Macaya C, Hernandez R, Bañuelos C, Goicolea J, Iñiguez A, et al. Early and late results of percutaneous mitral valvuloplasty for mitral stenosis associated with mild mitral regurgitation. Am J Cardiol. 1993;71(15):1304–10.
37. Zhang HP, Yen GS, Allen JW, Lau FY, Ruiz CE. Comparison of late results of balloon valvotomy in mitral stenosis with versus without mitral regurgitation. Am J Cardiol. 1998;81(1):51–5.
38. Fatkin D, Roy P, Morgan JJ, Feneley MP. Percutaneous balloon mitral valvotomy with the Inoue single-balloon catheter: commissural morphology as a determinant of outcome. J Am Coll Cardiol. 1993;21(2):390–7.

JAYPEE BROTHERS

for detailed information on cardiology books, visit our website www.jaypeebrothers.com, for detailed information on cardiology books, visit

PERCUTANEOUS MITRAL VALVOTOMY

Salient Features

- Provides comprehensive and detailed information on all aspects of percutaneous mitral valvotomy, and also offers practical guidance on how to safely and efficiently perform the procedure
- 72 experts in this field from 14 countries are sharing their expertise and experience
- Starting with careful patient selection based on echocardiographic evaluation, the succinct text takes you through the procedural details in the catheterization lab and the interpretation of hemodynamic data
- Also discusses the different gadgets available for the procedure and specifies how to recognize and treat all potential complications
- Complemented by outstanding still images and a DVD of procedural videos.



Harikrishnan S MD DM FRCP FACC is currently Professor of Cardiology at the Sree Chitra Tirunal Institute for Medical Sciences and Technology (SCTIMST), Thiruvananthapuram, Kerala. He obtained his medical graduation from Medical College Thiruvananthapuram, MD in General Medicine from Medical College Calicut, and DM in Cardiology from SCTIMST. As a Commonwealth Fellow, he got trained in interventional cardiology at Leeds University in the United Kingdom. He also completed the public health leadership training program—PH LEADER from Emory University, USA in 2014-15. Widely published in national and international journals, he has more than 100 publications in peer-reviewed international journals.

Available at all medical bookstores
or buy online at www.jaypeebrothers.com

JAYPEE BROTHERS
Medical Publishers (P) Ltd.
www.jaypeebrothers.com

Join us on facebook.com/JaypeeMedicalPublishers

Shelving Recommendation
CARDIOLOGY

ISBN 978-93-86056-82-5