r website **www.jaypeebrothers.com,** for detailed information on dermatology books, visit our website **www.jaypeebrothers.com**

Sclerotherapy in Dermatology





Sacchidanand S
Nagesh TS

Foreword
Dinker Belle Rai

JAYPEE

Contents

1. Venous Anatomy 1
Aniketh Venkataram
Superficial Veins 2
Deep Veins 6
Perforating Veins 7
Histology 9
Related Nerves 10
2. Pathophysiology of Varicose Veins 13
Nirmal B
Physiology of Venous System of Lower Limbs 14
Venous Pathophysiology 15
3. Skin Changes in Venous Insufficiency 19
Shashikumar BM, Savitha AS
Cosmetic Concerns 20
Edema 20
Corona Phlebectatica Paraplantaris (Ankle Flare) 21
Superficial Thrombophlebitis 21
Hemorrhage 21
Pigmentation 22
Pressure Erythema 22
Eczema 22
Lipodermatosclerosis 23
Atrophie Blanche 24
Ulceration 24
Other Rare Complications 26
4. Evaluation of Varicose Veins 29
Shilpa K, Lakshmi DV, Divya Gorur K
History 29
Bedside Tests 31
Imaging Studies 34
5. Compression Therapy following Sclerotherapy 41
Late GR Ratnavel
Compression Therapy 41
Types of Compression after Sclerotherapy 43
What do Guidelines and Studies Say 44
Time of Application of Compression Bandage 44

6. Sclerosing Solutions 46
Akhilesh A
General Mechanism of Action of Sclerosants 46
Detergents 47
Osmotic Solutions 51
Chemical Irritants 54
Sequential Injections of Different Sclerosing Solutions 56
Ideal Sclerosant 57
7. Sclerotherapy for Varicose Veins 63
Nagesh TS, Sacchidanand S, Dinker Belle Rai
History 63
Indications of Sclerotherapy in Varicose Veins 64
Contraindications 64
Sclerosing Solutions 65
Pre-procedure Assessment 66
Sclerosant Concentrations 67
Principles of Varicose Vein Sclerotherapy 67
Patient Preparation 67
Techniques 68
8. Foam Sclerotherapy 75
Savitha AS, Sujala S
History 75
Methods of Foam Preparation 75
Foam Stability 76
Types of Foam 77
Requirements 77
Patient Position 78
Sclerosing Agents 78
Indications and Contraindications 78
Procedure 79
Postprocedure 80
Complications 81
Advantages of Foam Sclerotherapy 82
9. Complications of Sclerotherapy 85
Teresita S Ferrariz, Agnes E Thaebtharm
Prevention of Complications 85
Complications 86
Management of Complications 94
Conflicts of Interest 98
Acknowledgment 98

10. Sclerotherapy for Cystic and Benign Vascular Lesions 100
Sacchidanand S, Nagesh TS, Shruthi C
Sebaceous Cyst/Epidermoid Cyst 100
Mucous Cyst and Ranula 101
Steatocystoma Multiplex 104
Lymphangioma Circumscriptum 104
Pyogenic Granuloma 106
Acknowledgments 109
11. Surgical Treatment of Varicose Veins 111
Durganna T
History 111
Saphenofemoral Ligation and Long Saphenous Stripping 112
Saphenopopliteal Junction Ligation and Lesser Saphenous Stripping 114
Perforator Ligation 115
Phlebectomies 116
Conservative Venous Ligation 117
Postoperative Instructions 118
Complications of Standard Varicose Vein Surgery 118
Minimal Invasive Methods 118
Radiofrequency Ablation 120
Recurrent Varicose Veins 120
Comparison of Interventions 121
Index 123

CHAPTER 4

Evaluation of Varicose Veins

Shilpa K, Lakshmi DV, Divya Gorur K

INTRODUCTION

Chronic venous insufficiency is a complex and chronic condition, with varied clinical manifestations, etiologies and underlying pathophysiology. A thorough stepwise workup is essential to assess the nature of a patient's underlying venous disease. This should begin in the clinical setting itself with a careful medical history, physical examination and bedside diagnostic tests. These need to be supplemented by confirmatory diagnostic testing, including duplex ultrasonography, venography, plethysmography and ambulatory venous pressure measurement. Based upon the results of these examinations, venous disease can be classified according to standardized classification schemes, which in turn helps in selection of an appropriate treatment strategy.

HISTORY

Initial evaluation should begin in the office setting with a thorough history. The history should include:

- Symptoms suggestive of venous insufficiency (Box 4.1)
- Worsening of symptoms during the course of the day and with prolonged standing
- Specific features of the pain that should be noted include the degree to which the pain interferes with the patient's occupation or lifestyle
- The duration of time the patient can stand before the onset of pain or swelling
- The age of onset of varicose veins should be recorded (early onset in congenital abnormality such as Klippel–Trenaunay syndrome)
- History of deep vein thrombosis or pulmonary embolism
- History of past treatments for varicose veins, including operative and percutaneous procedures

A proper history should be followed by thorough physical examination which includes general physical examination along with careful examination of lower extremities.

JAYPEE BROTHERS

Box 4.1: Symptoms suggestive of venous insufficiency.

- Pain
- Tightness
- Skin irritation
- Pruritus
- Heaviness
- Tingling
- Muscle cramps
- Cosmetically unacceptable linear swellings
- Edema
- Skin pigmentation
- Ulceration

Prerequisites

- Examination should be done in a well-lit and warm room
- Patient should be examined in standing position
- It is suitable to undress the patient allowing complete exposure of lower limbs from groin to toes

Examination

Inspection

The location and distribution of all major subcutaneous varicosities should be noted. The findings should be recorded using charts or line diagrams. Large varicosities especially over the anatomical areas of perforators should be noted. Presence or absence of edema, vascular malformation should be noted. Spider veins if any should be recorded. Cutaneous changes like pigmentation, scars, atrophie blanche, lipodermatosclerosis, ulceration (Figs. 4.1A to C) should be documented.

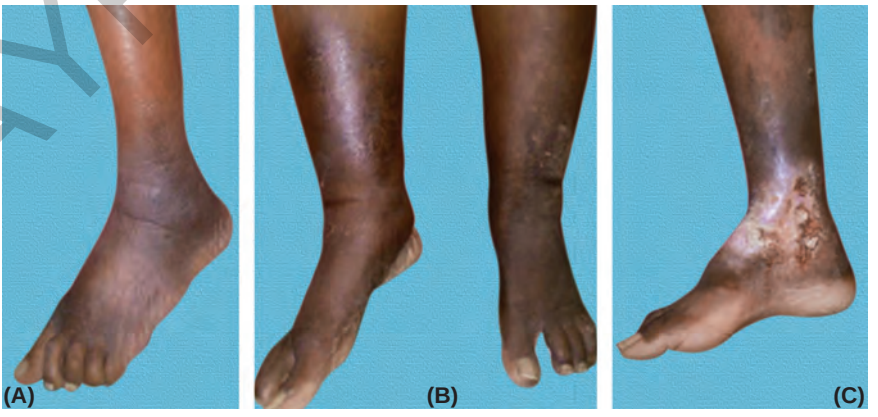

Figs. 4.1A to C: Cutaneous changes due to varicose veins, (A) pigmentation, (B) lipodermatosclerosis and (C) healing ulcer with scarring and depigmentation.

JAYPEE BROTHERS

Palpation

All the inspectory findings should be confirmed by palpation. Palpation of the limbs may detect additional varicosities that are not readily appreciated by inspection especially the terminal segments of the greater saphenous vein (GSV) (inner thigh) and lesser saphenous vein (LSV) (calf) where they join the femoral and popliteal veins, respectively. Palpation also throws light on presence of areas of induration, firm subcutaneous cords (due to previous episodes of thrombophlebitis) and presence of temperature difference between the legs.

BEDSIDE TESTS

Cough Impulse Test[1,2]

This test is performed while the patient is in standing position. Proximal part of the thigh at fossa ovalis (Fig. 4.2) is palpated and the patient is asked to cough. A palpable thrill at the saphenofemoral junction (SFJ), as a result of turbulent retrograde flow, indicates reflux at the SFJ. The drawback of the test is, it is difficult to perform in obese individuals.

Tap Test or Percussion Test[3,4]

This test is also performed while palpating the SFJ in standing position. The GSV is tapped at the level of the knee. A palpable transmitted impulse at the SFJ suggests that the GSV is distended with blood. Conversely, the SFJ is then tapped while the GSV is palpated at the knee. A palpable transmitted pulse at

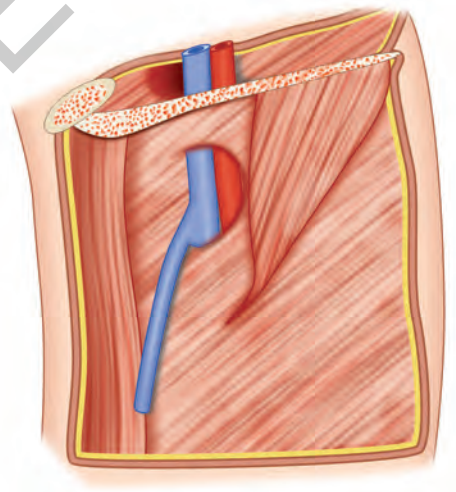

Fig. 4.2: Fossa ovalis an oval opening in the upper mid-part of the fascia lata of the thigh which lies 3–4 cm below and lateral to the pubic tubercle and is about 3 cm long and 1.5 cm wide and transmits great saphenous vein.

JAYPEE BROTHERS

the knee with this maneuver indicates incompetence of GSV valves between the SFJ and the knee.[4]

Brodie-Trendelenburg Test[5]

Brodie-Trendelenburg test is done to differentiate between perforator and GSV incompetence. The Brodie-Trendelenburg test is highly sensitive for the identification of superficial and perforator reflux (91%), although poorly specific (15%).[4] The test is performed with patient in supine position. First the superficial lower extremity veins are drained by raising the lower limbs to 45° and gently stroking the limb along the course of the major veins from foot towards thigh. A tourniquet is applied as close to the groin as possible and tight enough to prevent reflux in superficial veins. Then the patient is made to stand and leg is examined for refilling of veins (Fig. 4.3). If the distal veins remain collapsed for 15 to 30 seconds after standing, the tourniquet is released.[6] Interpretation of the test is given in the Table 4.1.

Modified Trendelenburg Test

In this test, firstly, the leg is elevated and the veins are emptied. The tourniquet is applied to control the saphenous vein near fossa ovalis. The patient then stands up and the tourniquet is removed at once. The sudden filling of



Fig. 4.3: Demonstration of Brodie-Trendelenburg test.

JAYPEE BROTHERS

Table 4.1: Interpretation of Brodie-Trendelenburg test.

Observation	Inference
If the caudal veins fill rapidly when the patient stands with the tourniquet in place	Perforator incompetence is suggested
The location of the incompetent perforator can then be determined by varying the position of the tourniquet	
Rapid filling of the varices with a tourniquet in the suprapatellar position	Incompetent mid-thigh perforator
Rapid filling with the tourniquet below the knee	Incompetent lower leg perforators
If the distal veins fill rapidly upon release of the tourniquet	SFJ incompetence

varicose veins from above down indicates a reflex through a saphenous femoral valve and valvular incompetence.[7]

Perthes Test[8]

Perthes test is highly sensitive but poorly specific similar to Trendelenburg test. It is performed with the patient in standing position with a tourniquet positioned below the knee (Fig. 4.4). The patient is asked to raise heel ten times to activate the calf muscle pump.[8] Interpretation of Perthes test is given in Table 4.2.

Modified Perthes Test

The leg is elevated and the veins are emptied. A tourniquet is applied to the upper thigh to constrict the saphenous vein return flow. The patient then walks around the room for five minutes. Absence of pain in the calf or definite swelling of the foot and ankle indicates patent deep veins.[3]



Fig. 4.4: Demonstration of Perthes test.

JAYPEE BROTHERS

Table 4.2: Interpretation of Perthes test.

Observation	Inference
Emptying of the varicose veins	The site of reflux is cranial to the tourniquet, namely the SFJ, saphenopopliteal junction (SPJ), or thigh perforators
Persistence of distended varicose veins	The site of reflux caudal to the tourniquet, that is, calf perforators
Pain associated with heel raising	It suggests the possibility of deep venous obstruction

Validation of Bedside Tests in Varicose Veins

A validation study conducted by Kim J et al. to determine the accuracy of clinical tests compared to color duplex imaging in patients with primary varicose veins using a prospective, blinded comparison study showed that the cough test had low sensitivity (0.59) and specificity (0.67). The tap test had low sensitivity (0.18) and high specificity (0.92). The Trendelenburg test had high sensitivity (0.91) but low specificity (0.15), and Perthes test had a high sensitivity (0.97) but low specificity (0.20). Hand-held Doppler assessment of reflux at the SFJ, in the long saphenous vein and at the SPJ had high sensitivity (0.97, 0.82 and 0.80 respectively) and specificity (0.73, 0.92 and 0.90 respectively) of detecting reflux. They also concluded that clinical tests used in the examination of patients with primary varicose veins are inaccurate.[1]

IMAGING STUDIES

Clinical evaluation based on the distribution of the venous abnormality can suggest a pattern of incompetence. However, treatment decisions based solely upon clinical evaluations are often encountered with errors, as several different patterns of incompetence can result in a similar appearance of abnormalities clinically. Therefore, it is strongly recommended that all patients undergoing evaluation for lower extremity varicose veins should be subjected to imaging studies before planning treatment. Several modalities have been used for this purpose including venography, Doppler ultrasound, computed tomography (CT), and magnetic resonance imaging (MRI); however, all of these methods have limitations.

Venography

Venography is a procedure in which a special dye is injected into the veins followed by X-ray of the veins, called a venogram, is taken (Fig. 4.5).[9] The dye has to be injected constantly via a catheter, making it an invasive procedure.

JAYPEE BROTHERS



Fig. 4.5: Venogram, taken after injecting special dye into the veins followed by X-ray of the veins.

Normally the catheter is inserted in the groin and moved to the appropriate site by navigating through the vascular system.

Contrast venography[10] is the gold standard for judging diagnostic imaging methods for deep venous thrombosis although; because of its cost, invasiveness, and other limitations this test is rarely performed.

Venography gives an image of the entire length of the lower extremity veins; yet, the image may often be inadequate despite the use of a large volume of contrast medium. Hence, this diagnostic technique is not advocated nowadays.

Doppler Ultrasound[11,12]

Duplex ultrasonography (DUS) is an essential part of the evaluation of patients with most forms of superficial venous insufficiency (Figs. 4.6A and B). Although other techniques exist, DUS is an inexpensive, portable and reproducible means of simultaneously assessing both the venous anatomy and physiology.

Indication

Patients undergoing evaluation for lower extremity varicose veins edema, or venous cutaneous changes (CEAP clinical stage 2–6) should also undergo an ultrasound evaluation of the superficial venous system to determine the pattern(s) of incompetence prior to making treatment recommendations. Patients with spider veins (CEAP clinical stage 1), particularly those in typical distributions such as on the lateral thigh area, generally do not require US evaluation. However, when the spider veins are found in the distribution of

JAYPEE BROTHERS



Figs. 4.6A and B: (A) Doppler ultrasound machine and (B) examination of veins.

a large truncal veins such as the GSV, it is recommended that DUS be performed. If truncal vein reflux is identified and contributory in these cases, treatment of reflux may be warranted prior to treatment of the spider veins.[13]

Procedure

When evaluating patients for reflux, the examination should be performed in the standing position. The patient is usually positioned on a stand to elevate the legs, which facilitates the performance of the examination. The patient is asked to turn the leg under examination, outward to allow scanning of the inner thigh and calf. Generally, the examination begins at the SFJ (Fig. 4.7). Further the great saphenous veins and short saphenous veins are followed downwards tracing their course and also the course of any tributaries that might lead to the abnormal veins. Competence of perforators are also evaluated (Fig. 4.8). It is important to be aware of the standard tributary anatomy of the GSV and to recognize the frequent variations that are found.

Doppler ultrasound is noninvasive and provides morphological and hemodynamic information, but it takes time for scanning the entire leg, and the accuracy and quality of assessment depends on the skill of the assessor/radiologist.

Still, Doppler ultrasound is the most recommended and widely performed diagnostic procedure in evaluation of varicose veins.

Ambulatory Venous Pressure

Ambulatory venous pressure (AVP) is the test of the efficiency of the calf musculovenous pump.[14]

JAYPEE BROTHERS



Fig. 4.7: Doppler ultrasonography showing SFJ (Real time B mode image).



Fig. 4.8: Doppler ultrasonography showing perforator incompetence (Real time B mode image).

JAYPEE BROTHERS

Procedure

A small needle is placed into one of the veins on the back of the foot and the needle is connected to a blood pressure measurement machine. The subject is then asked to stand up and the standing venous pressure is measured. In a normal subject, the standing venous pressure is around 90 mm Hg. The subject is then asked to perform ten heel raise exercises to work the musculovenous

Table 4.3: Interpretation of Ambulatory venous pressure (AVP) test.

Observation	Inference
No fall in the pressure	Indicates that the calf pump is not working effectively
Pressure rises rather than to fall during exercise	Indicates that the deep veins occlusion
AVP returns to the standing pressure too quickly	Indicates reflux in either the deep or superficial veins due to absent or damaged valves

pump during which AVP is recorded. During exercise, this should fall to around 30 mm Hg. Later, the subject is asked to rest again in the standing position and the rate at which the ambulatory pressure returns to the standing pressure is measured, called the refilling time. Normally, after exercise, the fallen AVP should rise slowly over half a minute or so back to the standing pressure.

Results are analyzed as in Table 4.3.

Ambulatory venous pressure measurement is a specialist, invasive test which is only performed in patients with clinical evidence of chronic venous insufficiency (CEAP 3-6). Photoplethysmography is used as an alternative in patients with varicose veins only (CEAP 2).

Plethysmography

Plethysmography is a noninvasive test that measures and records the variations in volume and pressure as blood flows through the tissues.[15] In diagnosing varicose veins and CVD, either strain gauge plethysmography or air plethysmography is used to evaluate the function of the calf muscle, global venous reflux, and obstructions to venous outflow. Gloviczki et al.[16] stated that although venous plethysmography is not used as often for patients suffering from simple varicose veins, the test can be used for patients who have more advanced stages of varicose veins and CVD, and is considered complementary to venous duplex scanning when venous reflux or outflow obstruction is suspected but is not visualized with the duplex scan.

Computed Tomography[17]

Though Doppler ultrasonography (US) has been used for evaluation of varicose veins, computed tomographic venography is useful when varicose veins arise from an unexpected anatomic source (Fig. 4.9). CT can provide an overview of the varicose veins in these cases.

Doppler US with complementary CT venography is useful for determining the precise cause of varicose veins. The use of CT venography aids in the overall understanding of varicosities and suspicious causes. The radiologist

JAYPEE BROTHERS



Fig. 4.9: CT scan showing pelvic vascular lesion causing varicose veins due to pressure effects.

can evaluate varicosities and determine their precise cause in most cases, particularly in unusual causes, with the combined strategy of Doppler US and CT venography is used.[14]

Magnetic Resonance Imaging

Magnetic resonance imaging is rarely indicated for patients who present with simple varicose veins because duplex scanning is usually enough to locate any obstructions or venous abnormalities. However, MRI may be helpful in identifying obstructions in the pelvic venous system or the iliac vein when proximal obstructions are suspected.[18] These tests can identify left renal vein compression, gonadal vein incompetence and pelvic venous congestion syndrome, and MRI with gadolinium contrast is helpful in evaluating CVD in patients with vascular malformations, such as congenital varicose veins.

CONCLUSION

Dermatologist often encounter with cases of varicose veins due to their varied cutaneous manifestations. Though good history, clinical examination, bedside tests can suggest a pattern of incompetence; they need to be confirmed by imaging studies especially when a therapeutic intervention is planned. Doppler being inexpensive, portable and reproducible mode of diagnostic technique is the most recommended and preferred method in evaluation of varicose veins. CT and MRI rarely indicated for patients who present with simple varicose veins, only useful when varicose veins arise from an unexpected anatomic source or identifying obstructions in the pelvic venous system or the iliac vein or when proximal obstructions are suspected.

JAYPEE BROTHERS

REFERENCES

1. Jones RH, Carek PJ. Management of varicose veins. Am Fam Physician. 2008; 78(11):1289-94.
2. Dodd H. Diagnosis of varicose veins. Postgrad Med J. 1947;23(263):427-40.
3. Pedrycz A, Budzyńska B. Diagnosis of varicose veins of the lower limbs–funtional tests. Arch Physiother Glob Res. 2016;20(3):29-32.
4. Kim J, Richards S, Kent PJ. Clinical examination of varicose veins: a validation study. Ann R Coll Surg Engl. 2000;82(3):171-5.
5. Browse NL, Burnand KG, Irvine AT, et al. Diseases of the Veins (2nd edition). London: Arnold Publishers; 1999. pp. 169-89.
6. Krishnan S, Nicholls SC. Chronic venous insufficiency: clinical assessment and patient selection. Semin Intervent Radiol. 2005;22(3):169-77.
7. Pratt GH. Test for incompetent communicating branches in the surgical treatment of varicose veins. JAMA. 1941;117(2):100-1.
8. Devi AS, Aathi MK. Prevention of varicose veins. Int J Adv Nur Management. 2014;2(1):40-5. J Nur Sci Prac. 2014;4(1):23-9.
9. Muir IF, Muklow EH, Rains AJ. Venography and the approach to varicose veins. Br J Sur. 1954;42(173):276-82.
10. Naidich JB, Feinberg AW, Karp-Harman H, et al. Contrast venography: reassessment of its role. Radiology. 1988;168(1):97-100.
11. Jung SC, Lee W, Chung JW, et al. Unusual causes of varicose veins in the lower extremities: CT venographic and Doppler US findings. Radiographics. 2009;29(2): 525-36.
12. Meissner MH, Moneta G, Burnand K, et al. The hemodynamics and diagnosis of venous disease. J Vasc Sur. 2007;46(6):S4-S24.
13. Khilnani NM, Min RJ. Imaging of venous insufficiency. Semin Intervent Radiol. 2005;22(3):178-84.
14. Dix FP, McCollum CN. Role of ambulatory venous pressure measurement in the assessment of venous disease. Phlebology. 2003;18:23-9.
15. Roberts D. Nursing assessment: musculoskeletal system. In: Lewis SL, Dirksen SR, Heitkemper MM, et al. (Eds). Medical-Surgical Nursing: Assessment and Management of Clinical Problems (8th edition). St Louis, MO: Mosby; 2011. pp. 1568-82.
16. Gloviczki P, Comerota AJ, Dalsing MC, et al. The care of patients with varicose veins and associated chronic venous diseases: clinical practice guidelines of the Society for Vascular Surgery and the American Venous Forum. J Vasc Surg. 2011;53(5):2S-48S.
17. Min SK, Kim SY, Park YJ, et al. Role of three-dimensional computed tomography venography as a powerful navigator for varicose vein surgery. J Vasc Surg. 2010;51(4):893-9.

JAYPEE BROTHERS

for detailed information on dermatology books, visit our website **www.jaypeebrothers.com,** for detailed information on dermato

Sclerotherapy in Dermatology

The book *Sclerotherapy in Dermatology* is an attempt to present a simple and comprehensive manual for clinicians and postgraduate students to arouse interest in sclerotherapy. The contributors include internationally renowned specialists practicing sclerotherapy. This book aims to provide a comprehensive guide for the practitioners to start sclerotherapy. The book has covered various aspects of venous disease including basic venous anatomy, pathophysiology of varicose veins, sclerosing solutions and various techniques of sclerotherapy. Along with these, it also has a chapter on the use of sclerotherapy for other indications like cysts and vascular lesions. Hope the readers find this book useful and can incorporate the technique in their clinical practice.



Sacchidanand S DVD MD FRCP is presently Director of Medical Education and Dean/Director Bangalore Medical College and Research Institute. He was formerly Professor and Head of the Department of Dermatology, STD and Leprosy at Bangalore Medical College and Research Institute, Bengaluru. His skills are spread across several domains and he has excelled in teaching, administration, organization, academics and research activities. He has worked at various levels in Indian Association of Dermatologists, Venereologists and Leprologists and was its President during 2008–09. He has also served as Secretary General of SARAD (2005–07). He is currently the President of Association of Cutaneous Surgeons of India {ACS(I)}. He has conducted around 20 conferences so far both at National and International levels. He has several articles in indexed journals to his credit. He has been a guide to several young postgraduate students of various faculties like Medicine, Dental and Pharmacy. He has been conferred a Fellowship (FRCP) from the University of Glasgow (2012). He is a pioneer in starting fellowship courses in Dermatosurgery (2005), Medical Cosmetology (2007), Pediatric Dermatology (2010) and Trichology (2012). He has authored chapters in various textbooks and is currently the Chief Editor of the 4th Edition of *IADVL Textbook of Dermatology*. He has co-edited and co-authored several undergraduate and postgraduate books in Dermatology. The present book on sclerotherapy is just another addition to his illustrious career.



Nagesh TS MD DNB completed his MD in Dermatology from the prestigious Bangalore Medical College and Research Institute, Bengaluru. He has done his thesis on sclerotherapy in the management of varicose veins and its complications. He has presented about sclerotherapy in various National and International conferences and also has conducted various workshops. He is currently the Professor and Head, Department of Dermatology at the Sapthagiri Institute of Medical Sciences and Research Center, Bengaluru.

Available at all medical bookstores
or buy online at www.jaypeebrothers.com



JAYPEE BROTHERS
Medical Publishers (P) Ltd.
www.jaypeebrothers.com

Join us on facebook.com/JaypeeMedicalPublishers

Shelving Recommendation
DERMATOLOGY

