edicine & toxicology books, visit our website **www.jaypeebrothers.com,** for detailed information on forensic medicine & toxicology books

Jaypee's Video Atlas of Medicolegal Autopsy



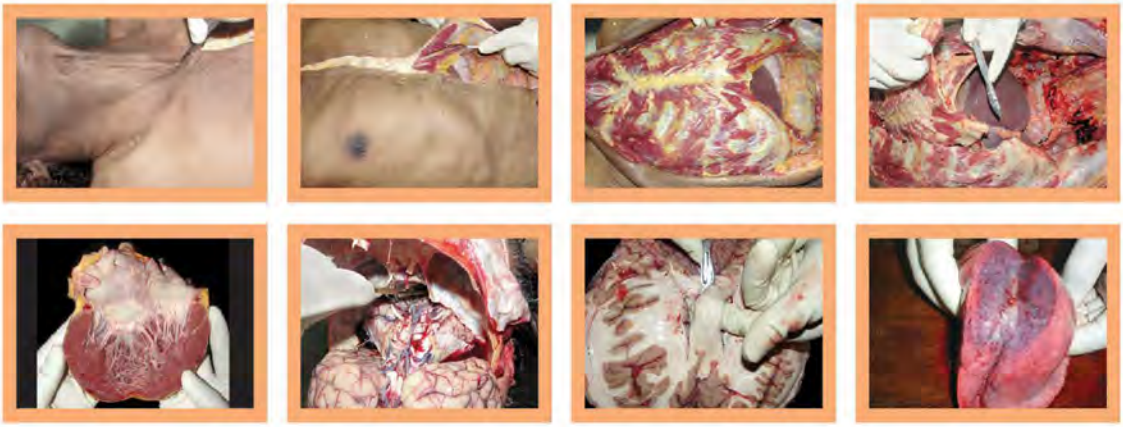



Includes Interactive DVD-ROM
Containing 2 Videos
Duration 2 hours 30 minutes

Sujith Sreenivas C
Prasannan K
Thomas Mathew

Foreword
MR Chandran

JAYPEE

CONTENTS

SECTION 1: MEDICOLEGAL AUTOPSY PROCEDURE 1

1. Objectives of Medicolegal Autopsy 3
2. Prerequisites, procedures and formalities in Medicolegal Autopsy 4
3. Autopsy Procedures and Techniques 4
4. Medicolegal Autopsy Procedure 5
5. Dissection of the Viscera 20
6. Dissection of the Heart and Brain 25
7. Layer Dissection of the Neck in a Bloodless Field 41
8. Medicolegal Autopsy Guidelines and Checklist 41
9. Fetal Autopsy 42
10. Osler Keeps his Distance 44

SECTION 2: MEDICOLEGAL AUTOPSY—CASES 45

11. Mechanical Injuries 47
12. Traumatic Brain Injury 62
13. Complication of Central Vein Cannulation 74
14. Firearm Injuries 74
15. Electric Burns 76
16. Burns 77
17. Shock 79
18. Asphyxia 81
19. Drowning 87
20. Poisoning 90
21. Natural Diseases 93
22. Postmortem Changes 103

Section 1

MEDICOLEGAL AUTOPSY PROCEDURE

JAYPEE BROTHERS

The word Autopsy means to "see for oneself" and is synonymously used with necropsy or postmortem examination. Medicolegal examinations are reports prepared by authorized medical practitioners at the instance of the magistrate or any other investigating authorities. After conducting a preliminary inquiry into offences resulting in sudden and unnatural death, the police officer or the magistrate is authorized to forward the dead body for examination to the nearest civil surgeon or other qualified medical man appointed in this behalf by the state government. The medical officer's report is sent to the magistrate of the district (or his subdivisional magistrate). The medical report is admitted as evidence after it has been deposed by the concerned doctor, to and recorded by the magistrate in the presence of the accused. The present law in India insists that all unnatural deaths, deaths under suspicious circumstances and sudden unexpected deaths are to be evaluated for establishing the actual cause and circumstance of death. The police who represents the state hands over the body back to the relatives after all the medicolegal formalities are over.

"Forensic" is derived from the Latin forum, the market place, because the Romans, whose law code still remains today the basis of our own, held their court of justice there.

OBJECTIVES OF MEDICOLEGAL AUTOPSY

1. Determination of cause of death
2. Determination of time since death
3. Identification of the deceased if identity is not known/ estimation of approximate age.
4. To gather information which will help in arriving at a conclusion regarding the manner of death, i.e. whether death was accidental, suicidal or homicidal.
5. Infant autopsies will help in knowing whether the child was live born, viable, still born or dead born and if live born to arrive at the cause of death and time since death.
6. Examination of skeletal remains—Determination of age/sex/cause of death/time since death.
7. Collection of material objects for further investigation purpose.

The early use of medical knowledge for legal purposes can be traced in the ancient codes. "The medical expert is not used to proper or greatest advantage, if he is regarded simply as an ordinary witness appearing for one side or for the other side; his function is rather to assist the judiciary by impartial interpretation and opinion based on his specialized knowledge".

Justinian code

JAYPEE BROTHERS

PREREQUISITES, PROCEDURES AND FORMALITIES IN MEDICOLEGAL AUTOPSY

1. Medicolegal autopsy should be carried out only on the receipt of a written requisition in the prescribed format from an authority (investigating police officer or executive magistrate).
2. The dead body must be accompanied by a civil police officer whose identity will be mention in the requisition and he has to identify the dead body by comparing and confirming the identification marks mentioned in the requisition letter (Kerala police form 102).
3. The permission of the relatives is not required for conducting medicolegal autopsy.
4. On identifying the dead body, a receipt may be issued to the civil police officer noting the date and time of receipt of the dead body for autopsy.
5. Unauthorized persons should not be permitted admission into the autopsy room during the procedure.
6. After a thorough complete examination of the dead body, all the findings should be documented and a preliminary postmortem report should be prepared then and there itself.
7. Material objects collected during autopsy should be packed, sealed and handed over to the police with a forwarding note in a sealed cover for onward transmission through proper channel.
8. After completion of the autopsy, the body may be handed over back to the civil police officer and a receipt obtained.
9. A statement regarding the postmortem findings, opinion and other relevant facts should be given to the investigating police officer on his request after the autopsy. Cr PC 162 (Statement to police not to be signed).

AUTOPSY PROCEDURES AND TECHNIQUES

Autopsy techniques may vary in the order in which the organs are removed, in the method of sectioning and in the removal of organ/organ systems.

Virchow's Techniques

Organs are removed one by one. The cranial cavity is exposed followed by the spinal cord through the back. Then the thoracic, cervical and abdominal organs are removed.

Rokitansky Technique

In situ dissection of the internal organs are done and the organs mass is removed en bloc.

Ghon's Technique

Thoracic, cervical, abdominal and urogenital system are removed as organ blocks.

JAYPEE BROTHERS

Letulle Technique

Thoracic, cervical, abdominal and pelvic organs are removed en masse and subsequently dissected into organ blocks.

MEDICOLEGAL AUTOPSY PROCEDURE

Dead bodies brought to the mortuary for preservation are stored in cold chambers and the temperature maintained at 3–8°C as freezing of dead bodies will result in crystallization of intracellular fluid. The autopsy room is equipped with autopsy tables, instruments for dissection and other materials for preservation of material objects, body fluids or tissues for further laboratory analysis. The civil police officer in charge of the dead body identifies the body brought by comparing the identification marks on the body and the requisition in Kerala Police Form 102. General examination includes measurement of height, weight, examination of the clothes worn by the deceased for tears, stains, blood, etc.

The eyes are opened and cornea, conjunctiva and position of the pupils examined. Lips are reflected and bluish discoloration of cyanosis or pallor due to blood loss is looked for. Ears are examined for discharge or blood. The dental configuration and details of lost tooth/Dental works like artificial tooth/dentures are observed as they will be of great use for identification. Nails are examined for pallor or cyanosis.

The inner aspect of the thighs and external genitalia are examined in details for recent or old injuries, the appearance of the hymen, dilatation of vaginal opening and rugosities of the vagina. A high and low vaginal swab is taken for detection of sperm or semen if any. As the dependent portion of the vagina is the posterior fornix in the lying down position, it is preferable to take the high vaginal swab from posterior fornix.

Rigor mortis is the postmortem stiffening of muscles due to the depletion of ATP. The involuntary muscles are involved earlier followed by the involvement of smaller muscles and then later the larger skeletal muscles. The march of rigor mortis is examined by opening the eyelids and jaws, flexing the neck, and by moving the upper and lower limbs. The stiffening of muscles across the joints results in fixation of the joints. As the muscle mass is relatively smaller in children, rigor mortis appears and disappears earlier in children.

Postmortem staining is the staining of the skin at the dependent areas due to the stasis of blood and extravasation due to the effect of gravity. The postmortem staining commences as mottling which coalesce and will be seen as uniform pattern of discoloration. Over areas of persistent postmortem pressure the staining will be absent and the area will be pale relative to the surrounding area of postmortem staining. This is known as contact pallor. Fixation of the postmortem staining and the absence of blanching by finger pressure is due to the extravasation of blood from the small blood vessels due to prolonged hypostasis and is seen after a postmortem interval of six to twelve hours.

JAYPEE BROTHERS

The anal orifice is examined for injuries, laxity of sphincters, discharge or presence of lubricants as evidence of unnatural sex offence.

The common incision for autopsy is a chin to pubis incision which extends from the under aspect of chin along the midline coursing along the side of umbilicus and extending up to pubic symphysis (Figures 1 to 3). The flap of skin, subcutaneous tissues and muscles are reflected to both sides (Figures 4 to 7). The costochondral junction is incised if cartilaginous or a bone cutter used if ossified or calcified (Figure 8). The sternal plate is lifted (Figures 9 and 10) and removed after dividing the sternoclavicular joint (Figures 11 and 12). The muscles of the submandibular region and floor of mouth are separated by cutting along the lower jaw margin and neck structures reflected dividing the attachments to the cervical vertebral bodies (Figures 13 to 15). Structures of the thoracic inlet are released by cutting, for the evisceration of neck structures along with the thoracic and abdominal viscera. The chest cavities are exposed. Collection of blood, fluids, or the presence of adherence of lungs to the chest wall is looked for (Figures 16 and 17). Both the domes of diaphragm are cut (Figure 18). The neck structures, thoracic and abdominal viscera are removed enmasse by releasing the attachments to the vertebral bodies and cutting the major blood vessels at the level of sacrum (Figures 19 and 20). The breasts are incised from within for the presence of contusions during sexual violence. The abdominal muscles are also incised from within to look for contusions. The peritoneal cavity is examined (Figure 21). The transverse colon is lifted on its mesentery and duodenojejunal junctions identified as the small intestine enters into the peritoneal cavity (Figure 22). The site is tied and cut in between ligatures to prevent spilling of the contents into the peritoneal cavity (Figures 23 and 24). The mesentery of the small intestine is cut along its entire length (Figure 25). The cecum and appendix identified. The ascending colon, transverse colon and descending colon is released up to the rectum (Figures 26 to 28). The urinary bladder is opened and examined (Figure 29). The presence of pneumothorax is looked for by filling the flap of skin and soft tissues overlying the chest wall which are reflected sideways with water and chest wall punctured with the scalpel blade under water (Figure 30). The presence of air under tension within the chest cavity will be seen escaping as bubbles through the incisions. For the detection of air embolism, the sternal plate is reflected before cutting open the great veins of the necks. The pericardial sac is opened anteriorly and the pericardial cavity filled with water. The right ventricle is incised under water and escape of air as bubbles looked for as death due to air embolism is due to the air lock of pulmonary artery due to accumulation of air bubbles within the right ventricle (Figure 31). A minimum of 50 mL of air is required to result in death due to air embolism. The stomach is removed by cutting the esophageal and pyloric end between ligatures to prevent the spilling of gastric contents (Figure 32). The stomach and contents are placed in a kidney tray. The stomach contents are examined by opening along the entire length of

JAYPEE BROTHERS

the wall in between the lesser curvature and greater curvature. The contents are examined, smell appreciated and mucosa looked for loss of rugosities, congestion or erosions (Figure 33). In deaths due to suspected neck violence, neck structures are dissected after removal of thoracic and abdominal viscera and the removal of the brain, so that the blood within the blood vessels of neck are drained off and the dissection of the neck can be done in a bloodless field (Figures 34 to 36). The thoracic and abdominal viscera are removed en block by releasing the attachment to vertebral bodies. The chest cavities are inspected. The carotid arteries are opened and the looked for obstruction due to atherosclerosis or the presence of intimal tear at the site of neck pressure due to neck violence or constrictive forces around the neck as in ligature constrictions. The entire length of vertebral bodies and intervertebral disc are examined for fractures or rupture of cartilaginous intervertebral disc. The pubic symphysis is palpated for fracture separation. The testicles are delivered outside through the inguinal canal and examined by incising for the presence of any injuries (Figure 37). Uterus and appendages are removed by cutting the broad ligament and vaginal wall. The ovaries, Fallopian tubes and uterus are examined. Uterus is split open by incising vertically and the cavity of the uterus is examined for products of conception, polyps, fibroids or evidence of any instrumentation. Injuries like uterine perforation, cervical injuries and endometrial tears are seen in soft gravid uterus during attempts of criminal abortion. The spinal column is opened and examined when spinal cord injury or fracture of vertebral column is suspected. cervical spinal cord is exposed by incising the back of neck vertically along the midline. After reflecting the paraspinal muscles sideways the laminae on both the sides are divided along the entire length with a bone cutter. The spinal cord is exposed by opening the dura mater.



Fig 1: Chin to pubis incision

JAYPEE BROTHERS



Fig. 2: Incision chest



Fig. 3: Incision abdomen



Fig. 4: Peritoneum opening

JAYPEE BROTHERS



Fig. 5: Reflecting abdominal muscle



Fig. 6: Reflecting neck



Fig. 7: Thoracic cage exposed

JAYPEE BROTHERS



Fig. 8: Cutting costochondral junction

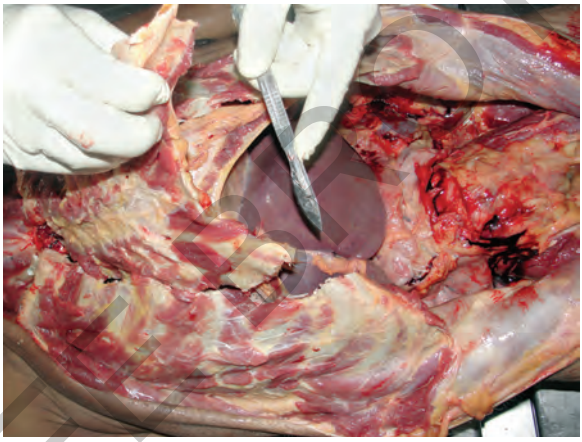

Fig. 9: Removal of sternal plate

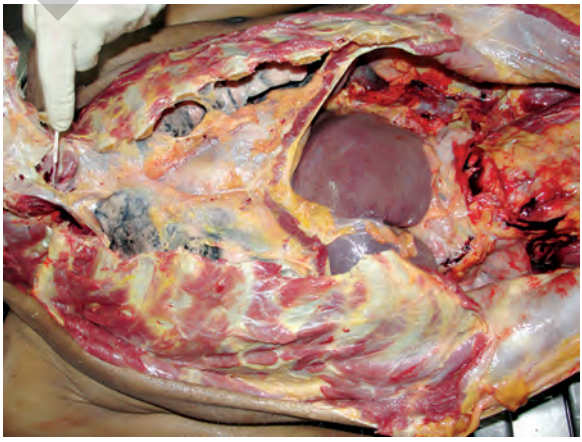

Fig. 10: Sternal plate removed

JAYPEE BROTHERS

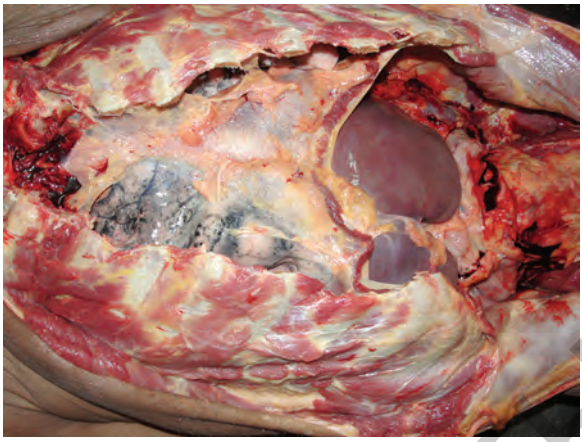

Fig. 11: Mediastinum exposed



Fig. 12: Cutting sternoclavicular junction



Fig. 13: Neck muscle exposed

JAYPEE BROTHERS



Fig. 14: Cutting deeper neck structure

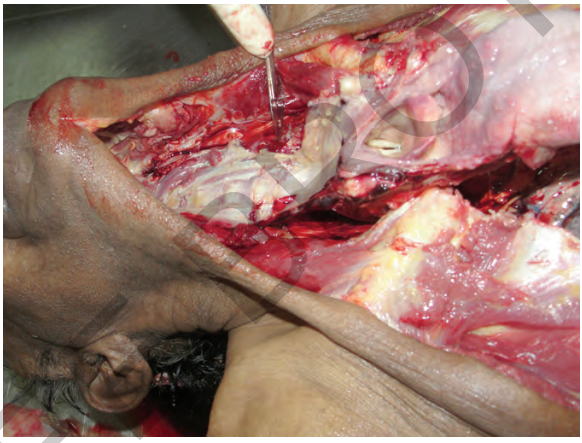

Fig. 15: Removal of tongue and neck muscles

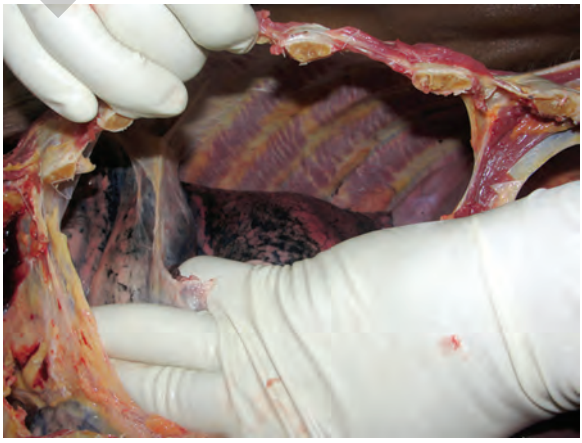

Fig. 16: Examination of chest caviy

JAYPEE BROTHERS



Fig. 17: Removal of thoracic viscera

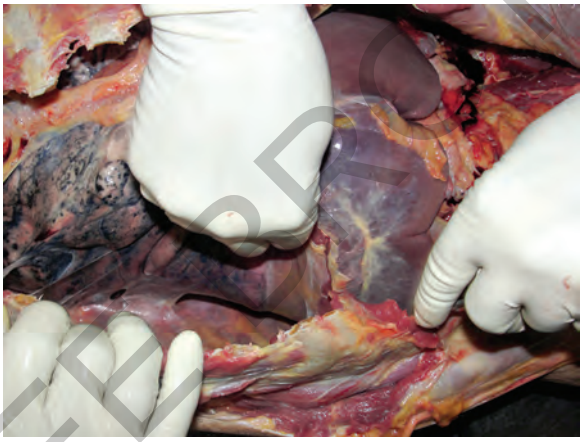

Fig. 18: Cutting diaphragm

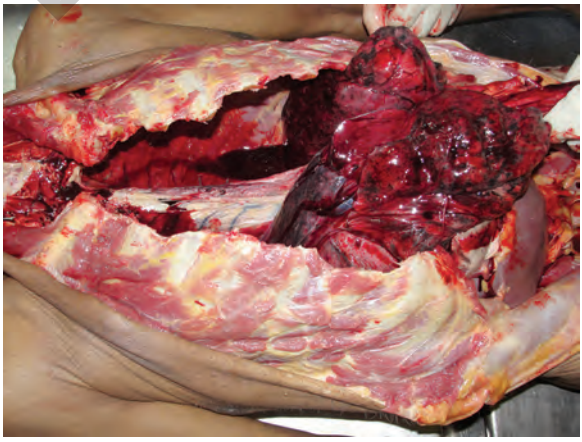

Fig. 19: Evisceration thorax

JAYPEE BROTHERS



Fig. 20: Evisceration abdomen

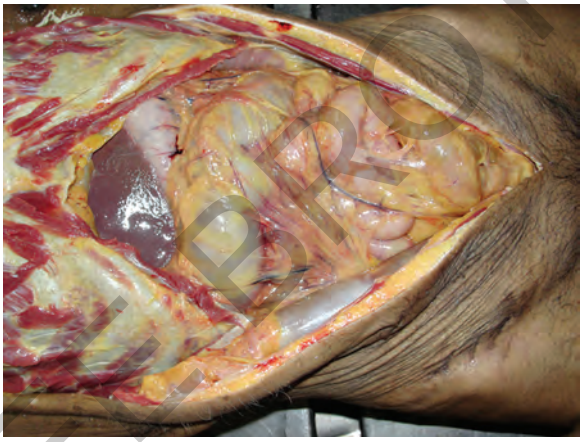

Fig. 21: Abdominal viscera

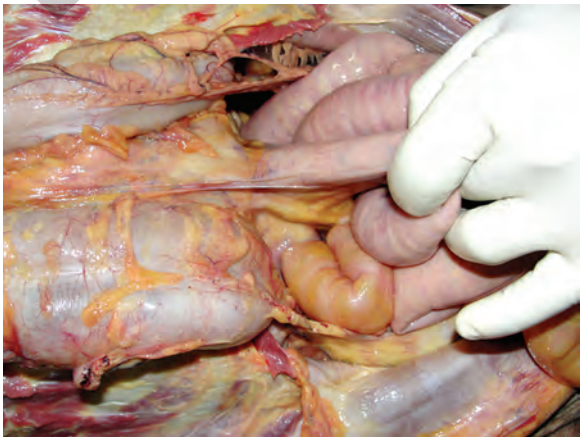

Fig. 22: Identifying duodenojejunal junction

JAYPEE BROTHERS

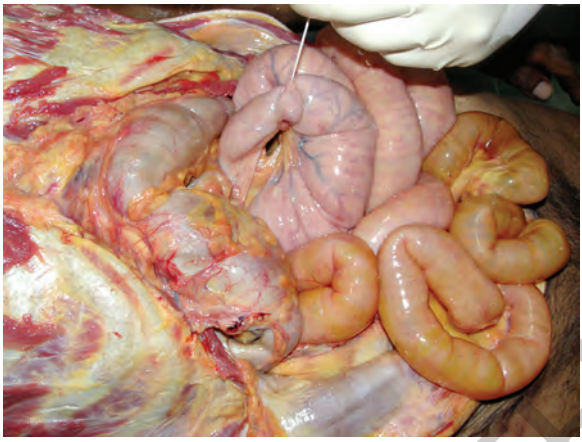

Fig. 23: Tying the bowel

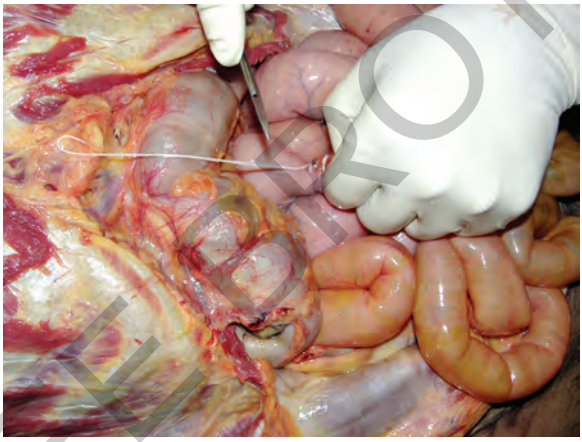

Fig. 24: Cutting between ligatures

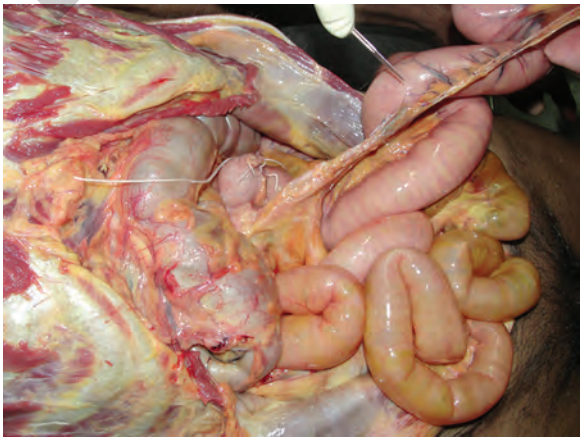

Fig. 25: Cutting mesentery of small bowel

JAYPEE BROTHERS



Fig. 26: Cutting transverse mesocolon

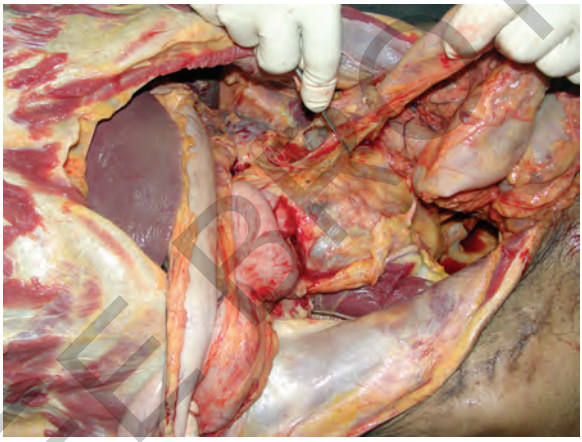

Fig. 27: Cutting distal large bowel

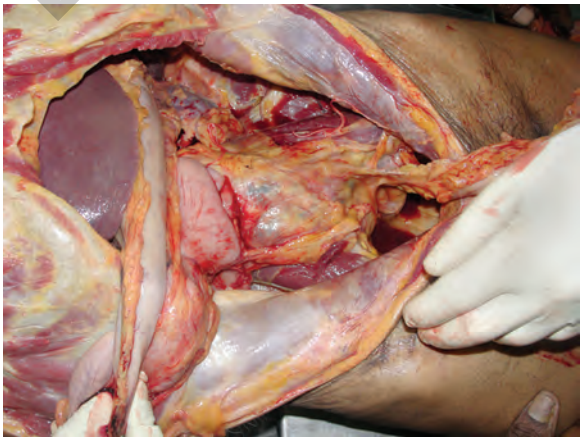

Fig. 28: Releasing sigmoid and rectum

JAYPEE BROTHERS

or detailed information on forensic medicine & toxicology books, visit our website **www.jaypeebrothers.com,** for detailed information

System requirement:

Windows:

- Operating System:
  - o Windows Vista or above
  - o Macintosh OS X or above
- Recommended Web Browser—Google Chrome & Mozilla Firefox
- Essential plugins—Java & Flash player
  - o If facing problems in viewing content—enable/re-install Java plugin on your web browser setting.
  - o If Videos don't show up—enable/re-install Flash Player or manage Flash setting on your web browser settings.
  - o You can test Java and Flash by using the links from the help section of the CD/DVD.

Accompanying CD/DVD Rom is compatible and playable only in Computers and not in DVD player.

CD/DVD has Autorun function (only for Windows based systems). If Autorun feature doesn't works, then follow the steps below to access the contents manually:

Windows:

- Click on My Computer
- Select the CD/DVD drive and click open/explore—this will show list of files in the CD/DVD
- Find and double click file—"launch.html"

Mac:

Double click the file "launch.html" located on the root after inserting the CD/DVD. The Mac OSX operating system does not support an Autorun feature.

For more information about troubleshoot of Autorun click on:
http://support.microsoft.com/kb/330135

**Available at all medical bookstores
or buy online at www.jaypeebrothers.com**



**JAYPEE BROTHERS
Medical Publishers (P) Ltd.
www.jaypeebrothers.com**

Join us on facebook.com/JaypeeMedicalPublishers

Shelving Recommendation
FORENSIC MEDICINE
AND TOXICOLOGY

ISBN 978-93-5270-236-7

