mation on pediatric books, visit our website www.jaypeebrothers.com, for detailed information on pediatric books, visit our website www.jaypeebrothers.com

Celebrating 50 Years
Passion, Quality and Innovation in Healthcare Publishing

Differential Diagnosis in PEDIATRICS

(Including Color Atlas)



6th Edition

Suraj Gupte

Foreword
EA Robert

JAYPEE

Contents

SECTION 1: Color Atlas

SECTION 2: Differential Diagnosis of Common Pediatric Presentations

1. Abdominal Distension 55
2. Abdominal Pain 58
3. Ambiguous Genitalia (Intersex) 65
4. Anemia 68
5. Ataxia 72
6. Blood in Stools 74
7. Chest Pain 77
8. Child Abuse and Neglect 79
9. Clubbing 82
10. Coma 85
11. Constipation 89
12. Seizures 93
13. Cough 100
14. Cyanosis 103
15. Deafness 106
16. Delayed Puberty 109
17. Diarrhea 111
18. Dyspnea 117
19. Dysuria 130
20. Edema 132
21. Encopresis 138
22. Enuresis 140
23. Epistaxis 142
24. Floppy Baby Syndrome 144
25. Failure to Thrive 148
26. Frequency of Micturition 153
27. Feeding Problems 155
28. Gingivostomatitis 159
29. Halitosis 161
30. Headache 163
31. Heart Murmurs 166
32. Hematemesis 170
33. Hematuria 173
34. Hemoptysis 177
35. Hepatomegaly 179
36. Hoarseness 188
37. Involuntary Movements 190
38. Irritability 193
39. Jaundice 195
40. Joint Pain 203
41. Large Head 209
42. Limping 213
43. Lethargy 218
44. Lymphadenopathy 220
45. Mass in Abdomen 225
46. Mouth Breathing 233
47. Nystagmus 235
48. Obesity 237
49. Precocious Puberty 239
50. Purpura 242
51. Fever of Unknown Origin 246
52. Rash 254
53. Short Stature 259
54. Small Head 265
55. Splenomegaly 267
56. Stiff Neck 272
57. Stridor 275
58. Sudden Infant Death Syndrome 278
59. Tall Stature 280
60. Vertigo 283
61. Vomiting 285
62. Wheezing 289

SECTION 3: Differential Diagnosis of Selected Clinical Signs

63. Differential Diagnosis of Selected Clinical Signs 295
    - Micrognathia 295
    - Stridor in First Few Days of Life 295
    - Macrocephaly 295
    - Microcephaly 295
    - Sparse and Light-colored Scalp Hair 296
    - Frontal/Parietal/Occipital Bossing 296

- Large Anterior Fontanel 296
- Craniotabes 296
- Rickets with Mental Retardation 296
- Bulging Anterior Fontanel 296
- Low-Set Ears 297
- Short Neck 297
- Depressed Bridge of Nose 297
- Hypertelorism 297
- Hypotelorism 297
- Periorbital Edema 297
- Mongoloid (Upward and Lateral) Slant of Eyes 297
- Epicanthal Folds 298
- Antimongoloid (Downward and Lateral) Slant of Eyes 298
- "Sunset" Sign 298
- Ptosis 298
- Proptosis (Exophthalmos) 299
- Blue Sclera 299
- Subconjunctival Hemorrhage 299
- White Reflex (Cat's Eye) 299
- Cataract 299
- Discoloration of Teeth 299
- Macroglossia 299
- Gingival Hyperplasia 300
- Blindness 300
- Pinpoint Pupil 300
- Iris Coloboma 300
- Acute Uveitis 300
- Deafness (Hearing Loss) 300
- Parotid Swelling 300
- Preauricular Tags/Pits 301
- Retarded (Delayed) Speech 301
- Pectus Carinatum (Pigeon Chest) 301
- Pectus Excavatum (Funnel Chest) 301
- Harrison Sulcus 301
- Costochondral Beading 301
- Senile Appearance 302
- Congenital Limb Hypertrophy 302
- Clinodactyly 302
- Polydactyly 302
- Knock-Knee Deformity (Genu Valgum) 302
- Bowleg Deformity (Genu Varus) 302
- Painful Swelling of Thigh 302
- Dry, Scaly, Hyperkeratotic Skin 303
- Skin Tuberculosis 303
- Scrofuloderma 303
- Sinus Bradycardia 303
- Sinus Tachycardia 303
- Paroxysmal Supraventricular Tachycardia 303
- Innocent Cardiac Murmur 304
- Cardiomegaly without Murmur 304
- Atrial Flutter or Fibrillation 304
- Umbilical Hernia 304
- Scoliosis 304
- Flat Foot 304
- Talipes Equinovarus (Club Foot) 304
- Congenital Goiter 304
- Gynecomastia 305
- Simian Crease 305
- Cafe-au-lait Spots 305
- Drug-induced Lupus 305
- Butterfly Rash 305
- Recurrence of Fever in Meningitis (on Treatment) 305
- Recurring Meningitis 305
- Opisthotonos 305
- Neck Rigidity (Stiffness) 305
- Acute Ataxia 305
- Chronic Ataxia (Static) 306
- Chronic Ataxia (Progressive) 306
- Calf Hypertrophy 306
- Painful/Tender Hepatic Enlargement 306
- Dull Percussion Note (Chest) 306
- Pigeon Chest Deformity 306
- Hemihypertrophy 306
- Microorchidism 306
- Macroorchidism 306
- Micropenis 306
- Vaginal Bleeding 306
- Syndrome of Inappropriate Secretion of ADH 306
- Ascites 306
- Gastroenteritis with Arthritis 307
- Gastrointestinal Bleeding 307
- Ulcerative Colitis-like Manifestations 307
- Soft Neurologic Signs 307
- Premature Graying of Hair 307
- Potter Facies and Syndrome 307

SECTION 4: Differential Diagnosis of Salient Laboratory Findings

64. Differential Diagnosis of Salient Laboratory Findings 311

- Normocytic Anemia 311
- Increased Mean Corpuscular Volume (Macrocytic Anemia) 311
- Hypochronic Anemia 311
- Decreased Mean Corpuscular Volume (Microcytic Anemia) 311
- Increased Mean Corpuscular Hemoglobin Concentration 311
- Target Cells 311
- Basophilic Stippling 311
- Howell–Jolly Bodies 311
- Tear Drop Cells 312
- Elliptocytosis 312
- Acanthocytosis 312
- Rouleaux Formation 312
- Stomatocytes 313
- Neutrophilia (Neutrophil Leukocytosis) 313
- Neutropenia (Neutrophil Leukopenia) 313
- Eosinophilia 313
- Eosinopenia 314

- Lymphocytosis 314
- Lymphopenia 314
- Monocytosis 314
- Leukemoid Reaction 315
- Thrombocytopenia 315
- Poor Thrombocytopoiesis 315
- Poor Platelet Survival 315
- Sequestration of Platelets 315
- Thrombocytosis 315
- Hypocellular Bone Marrow 315
- Hypercellular Bone Marrow 315
- Megakaryocytic Hyperplasia 316
- Megakaryocytic Hypoplasia (Depression) 316
- Erythroid Hyperplasia 316
- Erythroid Hypoplasia 316
- Low-Serum Proteins (Total) 316
- High-Serum Proteins (Total) 316
- Low-Serum Albumin 316
- High-Serum Albumin 316
- Low Alpha-1 Globulin 316
- High Alpha-1 Globulin 316
- Low Alpha-2 Globulin 316
- High Alpha-2 Globulin 316
- High Beta Globulin 317
- Low Gamma Globulin 317
- High Gamma Globulin 317
- High Immunoglobulin G 317
- Low Immunoglobulin G 317
- Low Immunoglobulin A 317
- High Immunoglobulin A 317
- Low Immunoglobulin M 317
- High Immunoglobulin M 317
- High Immunoglobulin E 317
- Low Complement (C3, C4) 317
- High C-reactive Protein 317
- High Alpha-1-Fetoprotein 317
- High Creatine Phosphokinase 317
- High Serum Glutamic Oxaloacetic Transaminase or Aspartate Aminotransferase 318
- High Serum Glutamic-Pyruvic Transaminase or Alanine Aminotransferase 318
- High Alkaline Phosphatase 318
- Low Alkaline Phosphatase 318
- High Serum Amylase 318
- High Serum Lactate Dehydrogenase 318
- High Serum Calcium 318
- Low Serum Calcium 318
- High Serum Phosphate 318
- Low Serum Phosphate 318
- High Serum Magnesium 319
- Low Serum Magnesium 319
- High Serum Urea (Azotemia) 319
- Low Serum Urea 319
- High Serum Urea–Creatinine Ratio 319
- Low Serum Urea–Creatinine Ratio 319
- Aminoaciduria 319
- Phosphaturia 319
- Smell and Taste as Clues to Diagnosis 319
- Simple Observation on Urine as a Clue to Diagnosis 319
- Frothy: Albuminuria 319
- Hyaline: Normal 319
- Pathognomonic Jejunal Biopsy Findings 319
- High Sweat Chloride 320
- False Negative Sweat Chloride 320
- False Negative Tuberculin (Mantoux) Test 320
- Xanthochromic Cerebrospinal Fluid 320
- Albuminocytological Dissociation 320

SECTION 5: Differential Diagnosis of Selected Radiologic Signs

65. Differential Diagnosis of Selected Radiologic Signs 323

- Mediastinal Shift 323
- Hilar Enlargement 323
- Enlargement of Anterior Mediastinum 323
- Enlargement of the Superior Mediastinum 324
- Enlargement of the Middle Mediastinum 324
- Enlargement of the Posterior Mediastinum 324
- Multiple Finely Granular Shadows (Miliary Mottling) in the Lungs 324
- Solitary Lung Densities 325
- Multiple Lung Densities 325
- Large Lung Density 326
- Overwhelming Interstitial Changes in Lung Field 326
- Unilateral Increase in Lung Radiolucency 326
- Pulmonary Edema (Unilateral) 326
- Pulmonary Metastases 327
- Middle Lobe Consolidation 327
- Enlarged Cardiac Shadow 327
- Air Bronchogram 327
- Opaque Hemithorax 327
- Kerley Lines in Chest X-ray 328
- Nodular Opacities in Chest X-ray 328
- Calcification in Chest X-ray 328
- Reticular Granular Pattern in Chest X-ray 328
- Soap Bubble Appearance in Abdomen Film of Neonates 328
- Left Ventricular Enlargement 328
- Left Atrial Enlargement 328
- Right-sided Heart 328
- Abnormal Intra-abdominal Air Collection 328
- Bowel Showing Opaque Material (Calcification/Opacities) in Abdominal Film 329
- Intra-abdominal Cyst 329

- Unilateral Small Kidney 329
- Bilateral Small Kidney 329
- Unilateral Large Kidney 329
- Bilateral Large Kidney 329
- Double Bubble Appearance 329
- Multiple Air-Fluid Levels 330
- Absent Radii 330
- Wormian Bones 330
- Hair-on-end Appearance (Skull) 330
- Abnormal Skull Shape 330
- Craniosynostosis 331
- J-shaped Sella Turcica 331
- Intracranial Calcification 331
- Sutural Diastasis 331
- Silver/Copper-beaten Appearance 332
- Increased Bone Density 332
- Enhancing Lesions (Neuroimaging) 332
- Nonenhancing Lesions (Neuroimaging) 332
- Calcification (Neuroimaging) 333
- Metacarpal Sign 333
- Pathologic Fractures 333

Index *335*

CHAPTER 3

Ambiguous Genitalia (Intersex)

JAYPEE BROTHERS

BACKGROUND

The term, a*mbiguous genitalia,* denotes discrepancy between the actual sex and the bizarre external genitalia (Box 3.1). The external genitalia are characteristic of neither a male nor a female. The entity is also called *hermaphroditism* (*herm* referring to "good" and *aphroditism* to "goddess").

Ambiguity results from excessive virilization of a female (female hermaphroditism) or defect in masculinization of a male (male hermaphroditism).

Hermaphroditism must be suspected in any male child with a small penis, hypospadias and undescended testes. Any girl with a doubtful mass in the labia majora or groin needs to be examined to be certain if the mass could be testes.

BOX 3.1: Broad classification of ambiguous genitalia (intersex).

46, XX intersex (46, XX—virilized)
Androgen exposure:
Fetal source—21-hydroxylase deficiency, 11-beta-hydroxylase deficiency
Maternal source—virilizing ovarian or adrenal tumor, androgenic drugs
Ambiguous source—in association with genitourinary or gastrointestinal malformations

46, XY intersex (46, XY—undervirilized)
Testicular differentiation defects:
- WAGR syndrome
- Denys-Drash syndrome

Testicular hormone deficiency:
- Persistent Müllerian duct syndrome
- Receptor defects for anti-Müllerian hormone
- Leydig cell aplasia

Androgen action defect:
- Androgen receptor defects
- Androgen insensitivity syndrome, both partial and complete
- Smith-Lemli-Opitz syndrome
- 5-alpha reductase II mutations

True gonadal intersex:
XX, XY, XX/XY, chimeras

HISTORY

The history should trace the presence of intersex siblings or such other close relatives and the mode of inheritance. A history of consanguinity is of vital importance. Was the mother on hormonal therapy during the pregnancy? What was the time sequence of appearance of secondary sex characters in the child with ambiguous sex problem?

PHYSICAL EXAMINATION

The physical examination should confirm the presence or absence of testes (in the scrotum or inguinal canal), the degree of labioscrotal fusion, size of penis or clitoris, hypospadias, and uterus through rectal examination. Search should also be made for renal, anal and other congenital anomalies.

Presence of two labioscrotal masses confirms the existence of two testes. Possibility of female pseudohermaphroditism is thereby immediately rule out.

INVESTIGATIONS

Investigations include the following:
- Buccal smear to know the real gonadal sex (negative in male hermaphroditism and positive in true hermaphroditism and female pseudohermaphroditism)
- 17-ketosteroids and pregnantriol in urine
- Serum electrolytes
- Chromosomal studies
- Radiologic studies
- Gonadal biopsy is a must when gonads are in the abdomen and in certain other vague cases.

In many instances, laparotomy may be warranted to be certain of the diagnosis.

Flow chart 3.1 presents a diagnostic approach to ambiguous genitalia.

Flow chart 3.1: Algorithmic approach to diagnosis of ambiguous genitalia.

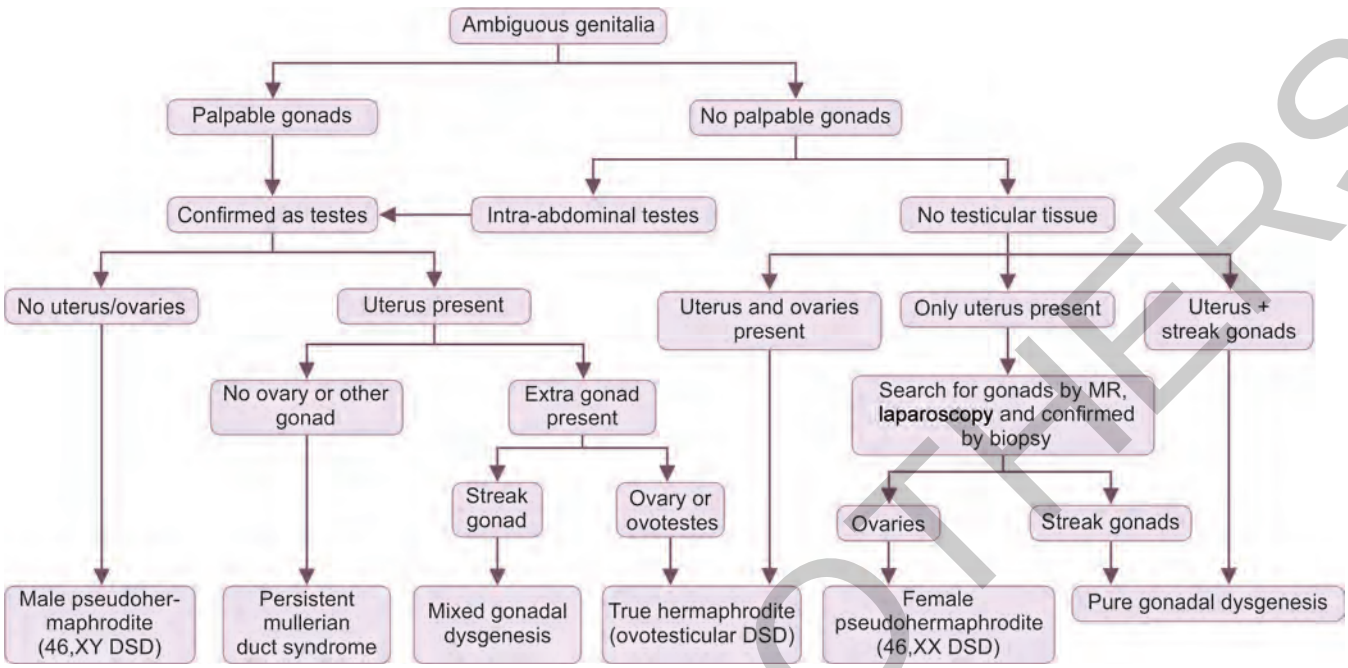

(*Source:* Adapted with permission from Chavhan GB, Parra DA, Oudjhane K, et al. Imaging of ambiguous genitalia: classification and diagnostic approach. *Radiographic* 2008;28:1891-1904)

IMPORTANT DIFFERENTIALS

True Hermaphroditism

This condition is quite rare. A sheer over 500 cases are on record. In this state, both ovarian and testicular tissues are present either in the same or in the opposite gonads. The external genitalia are usually ambiguous. The phenotype may, however, be male or female. Ovotestis is the most frequently seen gonad in true hermaphroditism. The testicular tissue in such an ovotestis is, however, defective. As a result, secretion of androgens and anti-Müllerian hormone is grossly inadequate. A true hermaphrodite is best brought up as a female with selective removal of testicular tissue.



Fig. 3.1: Male pseudohermaphroditism. Note that the external genitalia are confusing. Whether the child has a small penis with hypospadias or it is indeed a virilized clitoris is apparently not clear. What indeed clinched the diagnosis in this child was palpability of two testes in the so-called "labioscrotal" sac. Gonadal biopsy showed purely testicular tissue that was dysgenetic.

Male Pseudohermaphroditism

This condition is generally characterized by male phenotype. The penis is small with hypospadias (Fig. 3.1). Testes are undescended. Labioscrotal folds are fused. A casual look gives an impression of female genitalia. The genotype is XY. Incomplete virilization of the external genitalia is the main problem. Its causes include defects in testicular differentiation Its causes include defects in testicularharacterized by differentiation (Campomelic syndrome characterized by sex reversal i.e. chromosomally male but have female genitalia and reproductive system in association with skeletal dysplasia), pure gonadal dysgenesis (Swyer syndrome characterized by one X chromosome and one Y chromosome, normally present in males, have a female appearance), gonadal agenesis (embryonic testicular regression syndrome), and defects in testicular hormones (uterine hernia syndrome), and

JAYPEE BROTHERS

defects in androgen action (5-alpha reductase deficiency, testicular feminization syndrome, Reifenstein syndrome). In one-third male hermaphrodites, no cause is determined.

Female Pseudohermaphroditism

This is the most common type of hermaphroditism. It is characterized by masculinization of the genetically female child. Ovaries are present. Clitoris is large enough and looks like penis. Labia majora is large and may be fused, giving the appearance of a scrotal sac. Its causes include excessive intake of androgens by the mother, congenital adrenal hyperplasia and maternal virilizing tumors.

Congenital adrenal hyperplasia is by and large the most common cause of female hermaphroditism. Masculinization may be to the extent of development of a false penile urethra. The child looks a male with cryptorchidism. Degree of virilization is greater in salt-losers than nonsalt-losers. It is highest with 21-hydroxylase and 11-beta-hydroxylase defects.

FURTHER READING

1. Chavhan GB, Parra DA, Oudjhane K, et al. Imaging of ambiguous genitalia: classification and diagnostic approach. *Radiographics* 2008;28:1891-1904.
2. Rapaport R. Intersex. In: Kliegman RM, St Geme III, Blum NJ, et al (Eds). *Nelson Textbook of Pediatrics*, 21st edn. Philadelphia: Elsevier 2020:2394-2403.
3. White PC, Speiser PW. Congenital adrenal hyperplasia due to 21-hydroxylase deficiency. *Endocr Rev* 2000;21:245-291.

JAYPEE BROTHERS

for detailed information on pediatric books, visit our website www.jaypeebrothers.com, for detailed information on pediatric books, visit our website www.jayp

Differential Diagnosis in PEDIATRICS (Including Color Atlas)

The sixth edition of Suraj Gupte's *Differential Diagnosis in Pediatrics*, which has dominated the scene over the last 4 decades, stands fully revised, updated and enlarged. Addressed to the undergraduates, interns, postgraduates, residents, practising pediatricians, family physicians, etc., it is as a dependable source of yet more state-of-the-art knowledge in a reader-friendly format.

Outstanding Features

- Color Atlas, providing over 300 visual illustrations of instructive clinical situations with comments from point of view of differential diagnosis—your best source for the visual diagnosis of pediatric disorders
- Descriptive differential diagnosis of 62 major clinical situations, including highlights in the history and physical examination and the features of each disorder with illustrations
- Differential diagnosis of clinical signs with illustrations
- Differential diagnosis of important laboratory findings
- Differential diagnosis of radiologic findings with illustrations
- Illustrative clinical pictures, images, diagrams, flowcharts/algorithms, tables/boxes, etc. to drive home important points.

"The book which every student and clinician—be a UG, PG, house-physician, resident, teacher or practitioner—must possess…"
— Indian Pediatrics, New Delhi

"…provides most of the need-to-know information on pediatric differential diagnosis."
— Indian Journal of Pediatrics, New Delhi

"…rich contents presented in a easy-to-understand manner are an asset that render the book a compulsive reading… strongly recommended work…"
— Hong Kong Journal of Paediatrics

"… Down-to-earth approach in differential diagnosis is the most commendable feature of this versatile book… most relevant for the Indian subcontinent…"
— EC Paediatrics, London

Suraj Gupte MD FIAP FSAMS (Sweden) FRSTMH (London) hails from the alumni of the prestigious Postgraduate Institute of Medical Education and Research, Chandigarh, India. Over and above stint as WHO Regional Advisor, he is presently Professor and Head (Emeritus), Postgraduate Department of Pediatrics, Mamata Medical College and Mamata General and Superspecialty Hospitals, Khammam, Hyderabad, Telangana, India. He occupies a pride of place as an outstanding pediatric educationist, researcher, innovator and author of national and international repute. Besides receiving several prestigious awards and Fellowships/Professorships, he has represented India at scores of international conferences, workshops, symposia and seminars, etc. globally as a Guest Speaker, Chairperson, Rapporteur, Visiting Fellow/Professor, etc. Besides the international series, *Recent Advances in Pediatrics*, he has authored/edited scores of world class child health books of high esteem. He has published/presented around 250 papers in national and international periodicals/forums. He has been on several academic task forces, and editorial boards of reputed pediatric periodicals, both national and international, as an Adviser, Editor, Member and Peer-reviewer. In the Indian Academy of Pediatrics (IAP) and its Subspecialty Chapters, he held several important positions, including Founder and Vice-President of the Nutrition Chapter, and Founder and Secretary of the Child Neurology Chapter. He remained National Executive member for several terms. He was Adviser, 8th International Congress of Tropical Pediatrics and National Executive member, 8th Asian Congress of Pediatrics. At the International Nestle Nutrition Workshop held in Taiwan in 1989, he was the solo official representative of the IAP. Over and above, being Faculty Selection Expert for State and Union Public Service Commissions as also All India Institute of Medical Sciences (AIIMS), he is an examiner in several reputed universities and apex institutions, including AIIMS (New Delhi), PGIMER (Chandigarh), SGPGIMS (Lucknow), SKIMS (Srinagar), IGNOU (New Delhi) and National Board of Examination (DNB). He figures in most of the national and international Who's Who volumes, including the Morqui's Who's Who—a pre-eminent database of outstanding global personalities.

Available at all medical bookstores or buy online at www.jaypeebrothers.com

JAYPEE BROTHERS
Medical Publishers (P) Ltd.
www.jaypeebrothers.com

Join us on facebook.com/JaypeeMedicalPublishers

Shelving Recommendation
PEDIATRICS

ISBN 978-93-5270-247-3