astroenterology books, visit our website **www.jaypeebrothers.com,** for detailed information on gastroenterology books

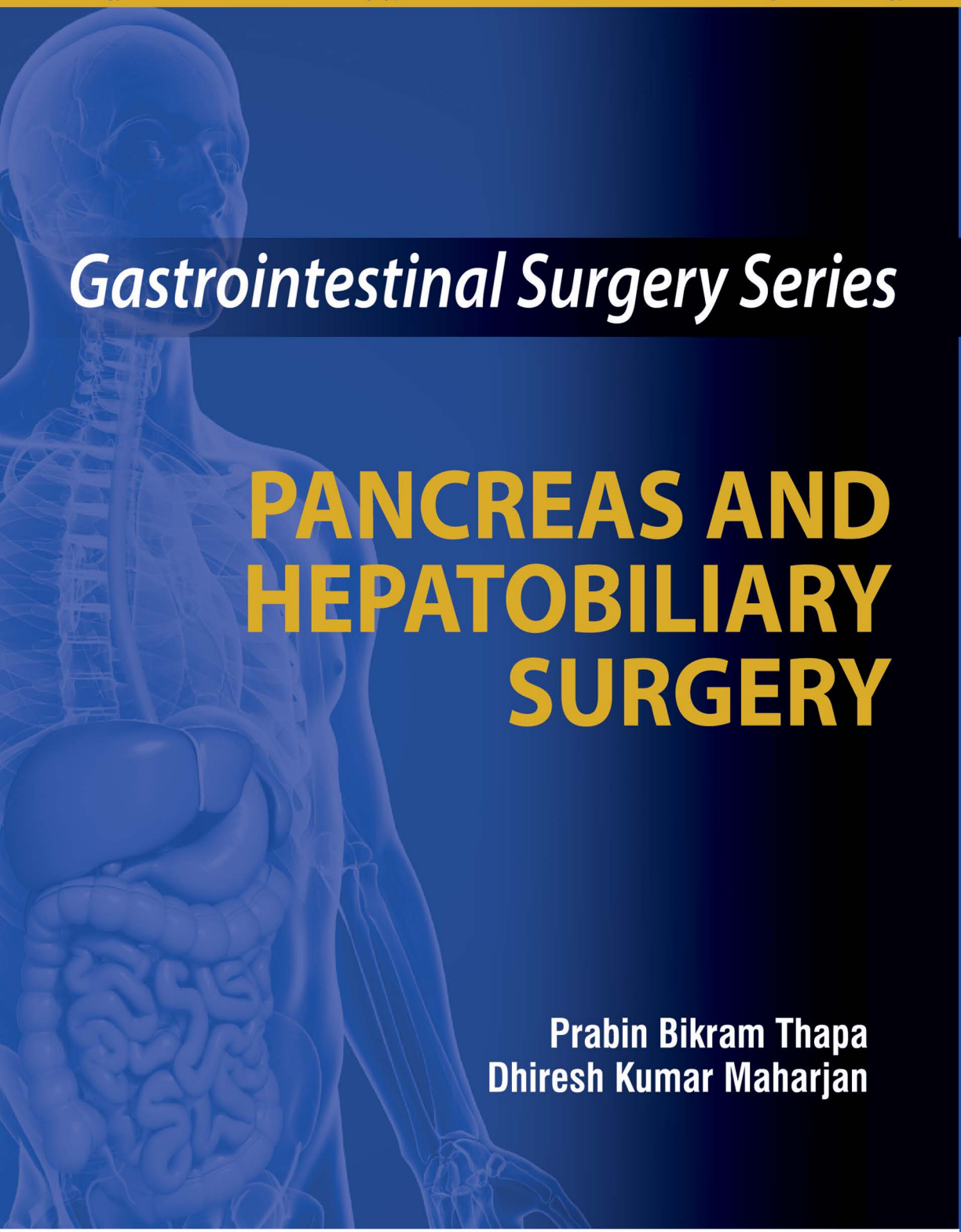

Gastrointestinal Surgery Series

PANCREAS AND HEPATOBILIARY SURGERY

Prabin Bikram Thapa
Dhiresh Kumar Maharjan

Foreword
Samiran Nundy

JAYPEE

Contents

1. **Superior Mesenteric Artery First in Pancreaticoduodenectomy: When and How?** **1**
   Savio G Barreto, Jagpreet Singh Deed, Mahesh Goel, Shailesh V Shrikhande
2. **Laparoscopic Pylorus-Preserving Pancreaticoduodenectomy** **8**
   Goro Honda
3. **Vascular Resection and Reconstruction in Pancreaticoduodenectomy** **18**
   Anne Waage, Dyre Kleive, Knut Jorgen Labori
4. **Management of Pancreatic Remnant after Pancreaticoduodenectomy** **26**
   Mallika Tewari
5. **Distal Pancreatectomy with en bloc Celiac Axis Resection for Advanced Pancreatic Body Cancer** **47**
   Satoshi Hirano, Paudel Saseem
6. **Pancreatic Necrosectomy** **53**
   Sachin Daga, R Phani Krishna, R Pradeep, GV Rao
7. **Evaluation and Management of Hepatic Hilar Blocks** **62**
   Vinay Kumaran
8. **Hilar Plate Resection: Extended Hilar Bile Duct Resection without Hepatectomy** **76**
   Takehiro Noji, Satoshi Hirano
9. **Hepatocellular Carcinoma—Resection versus Transplantation** **85**
   Prashant Bhangui
10. **Changing Trends in Management of Carcinoma of Gallbladder** **104**
    Seema Khanna, VK Shukla
11. **Biliovascular Injury** **112**
    Joy Abraham, Ashok Kumar, Anu Behari, VK Kapoor

Index *125*

CHAPTER 4

Management of Pancreatic Remnant after Pancreaticoduodenectomy

Mallika Tewari

INTRODUCTION

Pancreatic remnant after pancreaticoduodenectomy (PD) essentially comprises of body and tail of the pancreas. Exocrine secretions of the remnant pancreas are drained into the jejunum or stomach in an attempt to save the glands' exocrine and endocrine functions. This entails anastomosis between the solid pancreas and a hollow viscus and is beset with complications. Eventually, surgeons have resorted to a multitude of technical variations of managing the pancreatic stump after PD ranging from complete removal of the pancreas and pancreatic duct ligation to varying forms of pancreaticoenteric anastomosis in a bid to minimize complications after PD, principally life-threatening pancreatic fistula (PF).

The incidence of PF correlates with the texture of the pancreatic parenchyma. High incidence of PF (predicted fistula rate of 20–40%) is often reported in patients with a soft, fragile pancreas with small pancreatic duct and active exocrine function (as in patients with periampullary cancer) than in patients with a fibrotic, firm pancreas, with a dilated pancreatic duct (as in patients with pancreatic adenocarcinoma with chronic pancreatitis) (predicted fistula rate of 0–10%).[1-5] During the last decade, the operative mortality rate of PD has significantly decreased (<5%) although the incidence of morbidity after PD still remains high (40–50%).[6,7] This drop in the mortality rate after PD can be attributed to improved anesthesia, surgical dexterity in successfully performing complex pancreatic resections and better postoperative management. In high volume centers, the outcome after PD has improved. In one such study, Birkmeyer et al.[8] reported that for pancreatic resection, adjusted in-hospital or 30-day mortality rate in very-low volume (<1 case/year) hospitals (16.3%) was 12.5% higher than in very-high volume (>16 cases/year) hospitals (3.8%).

A major drawback of published series reporting data regarding outcomes after PD is a lack of comparability due to heterogeneous definitions used in individual studies for categorizing postoperative complications. However, with the efforts put in by dedicated pancreatic specialists, international consensus statements for important and common complications after PD such

JAYPEE BROTHERS

as PF, hemorrhage, and delayed gastric emptying have been recently published and are being increasingly incorporated during data collection and evaluation.[9-11]

This chapter summarizes some of the important techniques of management of the pancreatic remnant after PD and also provides a glimpse of the history of how pancreatic surgery has evolved to its present state.

PANCREATICODUODENECTOMY

The evolution of management of pancreatic remnant has evolved paripassu with the evolution of PD over ages. It was in 1884 that Billroth reported complete removal of the pancreas with success but soon after another doyen, Mikulicz, pointed out the enormous increase in mortality and morbidity with removal of the stomach, if the pancreas in any way was included.[12]

Codivilla has been recognized as the pioneer of PD.[13] He reported his attempt to partially excise the pancreas and duodenum in 1898 but he ligated the pancreatic duct and left the pancreatic remnant unanastomosed with intestine. The patient died at 18 days postoperative from cachexia resulting from steatorrhea.[14] Halsted (1899) reported the first successful resection for ampullary cancer. He described it in his own words—"to give the growth a wide margin, a large piece of the duodenum was excised, a wedge shaped piece with the apex at the mesenteric border of the intestine. About three-quarters of an inch of the common duct and a shorter piece of the pancreatic duct was excised". Cholecystoduodenostomy was added as a drainage procedure in a second stage operation.[15]

Walther Kausch first attempted the resection of the majority of the duodenum en-bloc with a significant portion of the pancreas. At the time of his first operation in 1909, there were only three prior reports (Halsted, Koerte, and Mayo) describing the management of carcinoma of the papilla of Vater and none were complete in the extent of resection.[16] This operation was another significant milestone and some still regard that the apt name for the so-called Whipple procedure should be the Kausch–Whipple procedure. For it was not until 25 years later that Whipple (1935) described the procedure bearing his name.[12] Prior to 1935, PD was rare and success rate so meager and the mortality so high that this operation never gained any degree of popularity. Despite pessimism surrounding pancreatic resection, sporadic cases of limited resection of pancreas for various indications started surfacing in the literature.

The leadership was provided by Whipple in 1935 in his original communication describing a two-stage operation.[12] The many disadvantages of two-stage procedure soon became evident as more cases were done. With the discovery of the ability to control the bleeding tendency in jaundiced patients with vitamin K, one of the foremost reason for the two-stage procedure was

JAYPEE BROTHERS

overcome, and again in 1940 Whipple performed the maiden operation of radical one-stage PD.[17] In 1940, Hunt added a pancreaticojejunostomy (PJ) to avoid leakage of the pancreatic stump.[18] Refinements in the PJ followed and an early detailed procedure was outlined by Child in 1944.[19] Thus, historically PD procedure gained some maturity before attention was drawn to the management of pancreatic stump—the villain of the show!

PANCREATICOJEJUNOSTOMY

Pancreaticojejunostomy has rightly been described as the "Achilles heel" of PD, as the failure of the anastomosis is often fatal.[20] PJ is commonly favored by most surgeons but several studies have reported a high-anastomotic leak rate when performed using the traditional technique. The PJ leak rate is so preoccupying that to minimize leak rates over 70 technique variations of PJ have been suggested but, whether the modifications of PJ really reduce leak rates is still a matter of debate.[21]

A few surgeons are also contemplated total pancreatectomy instead of pancreaticoenterostomy in adenocarcinoma of the pancreas stating it to be a more complete oncologically sound procedure with wider margins and lymph node clearance (as pancreatic cancer may be multicentric in about 30% cases) with absent morbidity of pancreaticoenteric anastomosis.[22] But due to the huge associated metabolic complications, onset of brittle diabetes and without improvement in morbidity, mortality, or survival, the procedure now stands abandoned except for a few selected indications.[21,22]

Pancreatic Duct Occlusion

Duct occlusion after PD, once practiced, is now also abandoned due to high rate of complications, PF, and exocrine gland dysfunction.[23-25] However, Tran et al. conducted a randomized study comparing PJ with pancreatic duct occlusion and did not find any significant difference in postoperative complications, mortality, or exocrine insufficiency between the two groups, although the incidence of diabetes mellitus was significantly higher in the duct occlusion group.[26] Another prospective randomized study compared the results of PJ (n = 18) versus duct occlusion but using external drains to create a temporary controlled pancreaticoenteric fistula (n = 17). The duct occlusion group had significantly lower morbidity (24% vs 56%; $p < 0.01$) and shorter hospital stay (26.4 days vs 42.2 days; $p < 0.01$) and no mortality. There were two postoperative deaths in the PJ group and both were due to PF.[27]

Conventional Pancreaticojejunostomy

There are two widely used methods to accomplish a PJ after PD—(1) end-to-side/end-to-end invagination PJ (or dunking the pancreatic remnant into

JAYPEE BROTHERS

the jejunum) or (2) end-to-side duct-to-mucosa pancreaticojejunostomy (DMPJ).

The method of suturing pancreas with the intestine may differ amongst surgeons from one-layer suture, in which pancreatic parenchyma and intestinal wall are sutured around the cut surface of the pancreas to a two-layer suture, wherein the pancreas and intestinal wall are sutured at second time to cover the first-layer suture. Again, the stitches may be taken in an interrupted or continuous fashion. Examples include the Child[19] and modified Child end-to-end PJ[28] (Fig. 4.1).

Duct-to-mucosa pancreaticojejunostomy was introduced by Warren in 1955 and remains a popular choice.[29] In addition, it has been shown that DMPJ maintains the diameter of the pancreatic duct and implying maintenance of exocrine function.[30] Continuous suture DMPJ anastomosis has been described as being safer with a significantly lower leakage rate.[31] In cases with a normal pancreas, it is technically difficult to anastomose a narrow pancreatic duct with a fragile parenchyma to the jejunal or gastric wall. To overcome the technical difficulties of performing pancreaticoenterostomy of soft pancreas, a novel technique of "duct-to-mucosa contact method" has been described using a fast absorbable suture (an irradiated polyglactin 910 suture material) and a temporary stent tube (Fig. 4.2).[32]

Some retrospective studies have reported significantly lower rate of PF with DMPJ compared to invagination PJ.[33-35] Two randomized controlled trials have also shown lower rate of PF in DMPJ compared to invagination PJ.[36,37] Bassi and his coauthors[36] randomized 144 patients with soft pancreas undergoing PD to either a two-layer DMPJ or a single-layer end-to-side PJ that was not invaginated. PFs were seen in 14% of patients of which 13% were in the DMPJ group and 15% in the end-to-side PJ group (p = not significant), and there was no difference in complications between groups (DMPJ 35% vs PJ 38%). Chou FF et al.[37] reported results on 93 patients in their trial. Patients

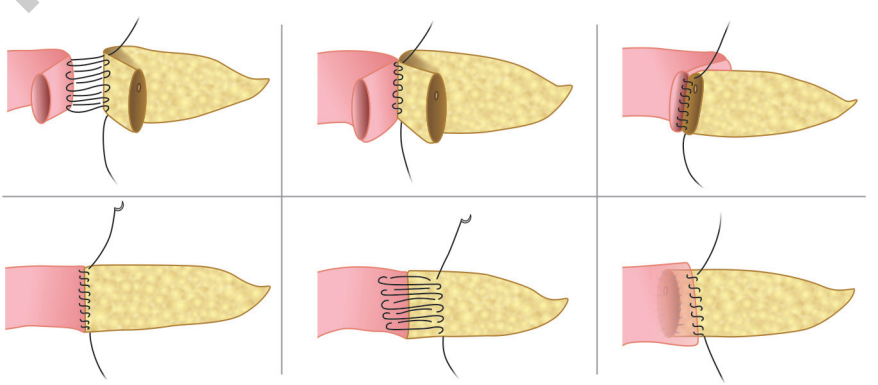

Fig. 4.1: Diagrammatic illustration of modified child pancreaticojejunostomy.[28]

JAYPEE BROTHERS

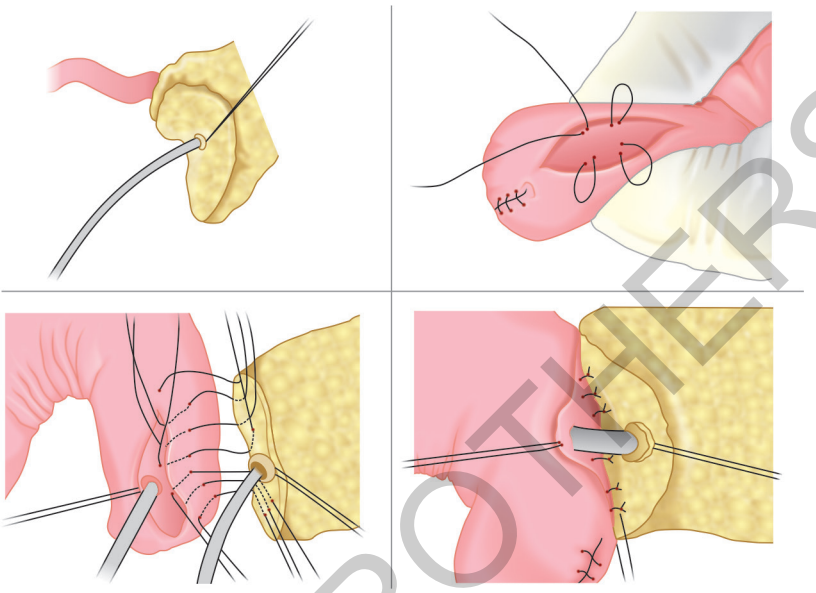

Fig. 4.2: Diagrammatic illustration of "duct-to-mucosa" contact method of pancreaticojejunostomy.[32]

with DMPJ (n = 47) had lower incidence of pancreatic leak (4% vs 15%), morbidity (21% vs 33%), and mortality (6% vs 9%) compared to those who underwent invaginated PJ (n = 46), respectively.

However, another trial by Berger et al.[5] found significantly lower pancreatic leak rates with invagination PJ (DMPJ 24% vs PJ 12%; $p < 0.05$). This trial randomized 197 patients first on the basis of pancreatic texture into soft pancreas (n = 101) and hard pancreas (n = 96) groups. Next each of these groups was further stratified into conventional PJ versus DMPJ subgroups. Subgroup analysis revealed higher PF rate with DMPJ in patients with soft pancreas (DMPJ 36% vs PJ 18%; $p = 0.06$) as compared to hard pancreas (DMPJ 11% vs PJ 6%; $p = 0.7$) though the difference was not significant. Overall, PF was significantly more common in patients with DMPJ (DMPJ 24% vs PJ 12%; $p < 0.05$).[5]

In an analysis of the causes of PF in PJ, it was revealed that 40% originated from the parenchyma or a small side-branch of the pancreatic duct and appeared to be as common with DMPJ anastomosis.[38] In soft pancreas, no pancreatic duct dilatation is usually detected; thus, duct-to-mucosa anastomosis might be difficult. The disadvantage with the invagination method is that during covering the pancreas with the outer layer of intestine, fragile pancreatic tissue is often torn during suturing.

Further, the problem with the aforementioned anastomosis techniques is that there is always potential gap between the adjacent stitches, which could become the breaking point for pancreaticoenteric leakage. In addition, there

JAYPEE BROTHERS

are needle holes on the surface of the anastomotic site after needle penetrating the seromuscular layer. In case the needle penetrates a small branch of pancreatic duct, pancreatic juice could leak from the needle hole. To overcome this problem, Ohwada et al.[39] meticulously sutured the small branches of pancreatic duct at the cut surface of the pancreas remnant and used fibrin glue to seal these small ducts without closing the remnant. They also devised DMPJ anastomosis by continuous running suture and parachuting, which obviates the gap between the adjacent stitches. The needle holes, however, are still there with a potential for leakage.

Blumgart[23] has described a novel technique of DMPJ with transpancreatic "through-and-through" sutures that are free from tangential tension and shear forces. It is thereby possible to cover the pancreatic cut end completely with jejunal serosa and protect the knots from cutting through the pancreatic tissue and tying the knots carefully at the ventral wall of the jejunum (Figs. 4.3A and B). This technique has been clinically tested and has yielded favorable results especially with soft pancreas.[24,40] Kakita et al. too published a modified duct-to-mucosa anastomosis by fixation of the pancreatic duct and jejunal mucosa with sutures after insertion of a pancreatic tube, and approximation of pancreas and jejunal wall with penetrating sutures.[41] Some others have applied fibrin glue to further seal the pancreaticoenteric anastomosis.[42]

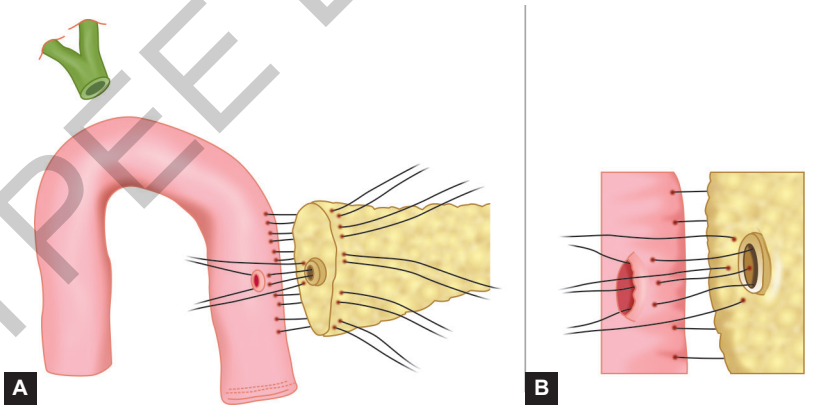

Figs. 4.3A and B: Diagrammatic illustration of Blumgart pancreaticojejunostomy using transpancreatic "through-and-through" sutures.[23]

A. Interrupted mattress full thickness "through-and-through" pancreatic sutures are placed. Sutures are taken from anterior to posterior through the pancreatic gland, continuing with a seromuscular bite of jejunum and then back through the pancreas from posterior to anterior. Needles are retained.
B. Interrupted duct-to-mucosa sutures are then placed before the "through-and-through" sutures are tied.

Subsequently (not shown in the figure), the anterior ductal sutures are placed and tied. Anterior pancreaticojejunal sutures are next taken using the previously placed posterior sutures and the anastomosis is completed. This imbricates the anterior seromuscular jejunum over the pancreas.

JAYPEE BROTHERS

Technique of Pancreaticojejunostomy based on Vascular Supply of Pancreas

The normal pancreatic parenchyma is fragile and thus if contracted with sutures or clamped with forceps, pancreatic laceration, or impaired circulation in the stump may occur.[43] Furthermore, as pancreatic juice has proteolytic action, reduced blood flow in the stump causes autolysis resulting in pancreatic leakage.[44] From the anatomical point of view, the pancreatic neck is a vascular watershed between celiac and superior mesenteric arterial supply. Hence, advices to evaluate the blood supply at the cut surface of the pancreas during pancreaticoenteric anastomosis. Strasberg et al.[45] alluded that ischemia at anastomosis in the course of pancreatic neck transection may contribute to the development of pancreatic leakage. If deemed inadequate, the pancreas should be cut back 1.5–2.0 cm to improve the blood supply (Fig. 4.4). They achieved a very low rate of anastomotic failure (3.2%) in their series by using this technique combining meticulous attention to placement and suture tying under magnification together with optimization of blood supply to the pancreatic remnant.

Binding Pancreaticojejunostomy

Driven by the fact that leakage from a pancreatic anastomosis can start at a point where a needle inadvertently penetrates a pancreatic ductule, or a suture lacerates the fragile pancreatic parenchyma on suturing or on tying a knot, Peng et al. introduced the concept of albeit complex and technically demanding binding pancreaticojejunostomy (BPJ).[46,47]

In this technique (Fig. 4.5), 3 cm of the distal cut end of the jejunum is everted and its mucosa destroyed either by electrical coagulation or 10%

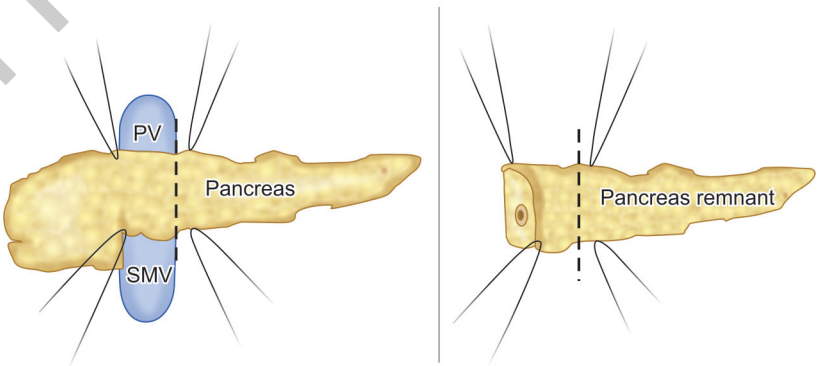

Fig. 4.4: Diagrammatic illustration of the concept of pancreaticojejunostomy based on the vascular supply of the pancreatic remnant. (SMV: Superior mesenteric vein; PV: Portal vein)

JAYPEE BROTHERS

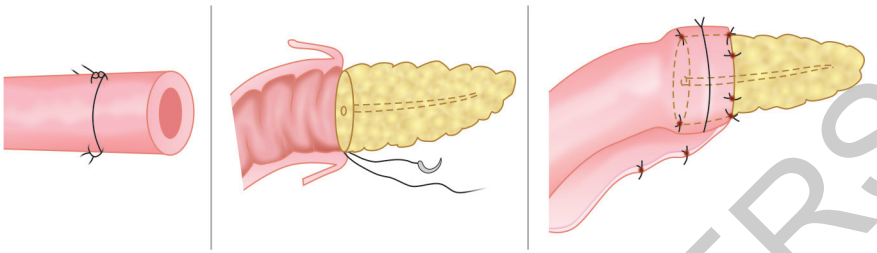

Fig. 4.5: Diagrammatic illustration of binding pancreaticojejunostomy.[47]

carbolic. The everted jejunum is next approximated to the cut edge of the pancreas suturing only the mucosa of the jejunum with the pancreas. Thus, if there is a leakage, the pancreatic juice goes into the gut lumen. The jejunal flap devoid of its mucosa is then turned over to cover the pancreatic remnant. The gap between deepithelialized jejunum and pancreatic stump is sealed by compressing from the outside with a binding ligature. Healing between the jejunum and the pancreas is promoted by destroying the jejunal mucosa with carbolic acid. The real anastomotic site is at the binding ligature where no sutures are applied. The reason why the anastomosis can be established only by a binding ligature is that the pancreas is a solid instead of a hollow organ. Compression from outside exerted by the binding ligature onto the intussuscepting and intussuscepted organs, i.e. the jejunum and the pancreas remnant, can seal the gap in-between, rendering them to be approximated closely, so as to create a water-tight closure. This is why the probability of pancreatic anastomotic leakage can be eradicated.

In a prospective randomized controlled trial by the same group, 217 patients were randomized to either a conventional PJ (n = 111) or BPJ (n = 106). No patient had pancreatic leak in the BPJ group compared to 8 in the conventional group (p = 0.014). Overall postoperative complications (26% vs 36.9%; p = 0.048) and hospital stay (18.4 ± 4.7 days vs 22.4 ± 10.9 days; p < 0.001) were significantly less in the BPJ group confirming its better safety profile.[48]

Anatomy—specific Pancreatic Stump Management

The anatomical features of the stump of the pancreatic remnant namely the location of the pancreatic duct, shape, and thickness of the pancreatic stump vary greatly among patients, making it difficult to perform a safe pancreaticoenteric anastomosis in the same manner for all patients.

Tajima et al.[49] have proposed that the location of the pancreatic duct has a significant impact on a patient's predisposition to develop a PF after pancreatic head resection and advocate different methods of placement of sutures during PJ when the remnant pancreatic stump is oval/round, flat, or when

JAYPEE BROTHERS

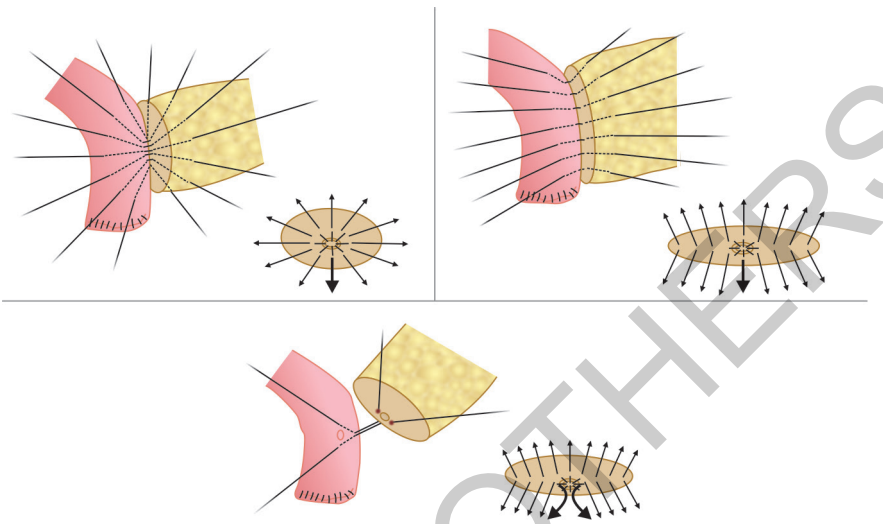

Fig. 4.6: Diagrammatic illustration of anatomy-specific pancreatic stump management.[49]

the pancreatic duct is very close to the posterior margin (Fig. 4.6). Within the body and tail of the pancreas, the pancreatic duct lies slightly cephalad to a line drawn midway between the superior and inferior edges of the pancreas, and the duct is also more posterior than anterior. In their study, the average thickness of the pancreatic stump and that of the pancreatic parenchyma beneath the pancreatic duct was found to be 16.5 mm and 4.1 mm, respectively. A pancreatic duct, located close to the posterior cut edge within a distance of 3 mm, was a feature highly associated with PF, although neither the thickness/width of the pancreatic stump nor the distance between the pancreatic duct and the anterior, superior, or inferior cut edge of the pancreas had any effect on the development of PF.

Mesh Reinforcement of Pancreaticojejunostomy

This method has been suggested to have several advantages.[50] First, the mesh forms safe "clothing" around the remnant pancreas for anchoring sutures, thus preventing the possibility of parenchymal laceration and bleeding from the sutures in soft pancreatic parenchyma caused by the suture. Second, since the shape of the pancreatic stump can be modified and reduced by the mesh, it is more convenient to make an invagination. Third, placement of posterior single layer continuous sutures is simple and require less time. Fourth, it is very convenient to perform polypropylene mesh-reinforced PJ under different conditions and the time required is less than single end-to-end invagination. The mesh in the anastomosis can promote fibroblast attachment and enhance the anastomotic healing process.

JAYPEE BROTHERS

PANCREATICOGASTROSTOMY

Pancreaticogastrostomy (PG) was first described by Waugh and Clagett from the Mayo Clinic in 1946.[51] Flaunter et al. popularized the technique and published their series in 1985.[52,53] Numerous theoretical and technical advantages are attribute to PG to explain the apparent safety of this procedure[54] including—(1) inactivation of pancreatic enzymes due to the low pH of the gastric lumen and lack of enterokinase in the gastric mucosa; (2) the alkaline pancreatic secretions may help to protect the pancreaticogastric anastomosis against marginal ulceration; (3) the anatomical proximity of the posterior gastric wall to the pancreatic remnant allows for a very secure anastomosis without tension, (4) the thick gastric wall with its excellent blood supply holds sutures very well; and (5) postoperative gastric decompression is easily performed and provides constant removal of pancreatic and gastric secretions thereby allowing less tension on the pancreaticogastric anastomosis.

Pancreaticogastrostomy has commonly been performed either by invagination method[55] or by duct-to-mucosa method[56] with some modifications.

Observational individual studies have reported lower overall leak rates with PG when compared to PJ.[57-66] Single center nonrandomized studies are often flawed by insufficient sample size, selection bias, lack of uniform definitions of various outcomes such as PF and other possible confounding factors such as surgeon's preferences. A large controlled but nonrandomized study by Takano et al. also showed that there were significantly less PF with PG compared to PJ (PG 0% vs PJ 13%; $p = 0.014$).[67]

To overcome the drawbacks of nonrandomized studies, three randomized controlled trials have been conducted to compare the two most preferred techniques (PJ vs PG) and have found no significant difference between the two methods contrary to the data of individual reports reporting excellent outcomes for PG.[68-70] However, the randomized controlled trial by Bassi et al. reported biliary fistula, postoperative collections, and delayed gastric emptying to be significantly reduced in patients treated by PG.[70]

Duct-to-Mucosa Pancreaticogastrostomy

Studies have reported a higher incidence of early postoperative gastrointestinal hemorrhage after PG than PJ.[57,59,63,71] According to these reports, bleeding commonly occurs from the cut edge of the invaginated pancreatic stump. It is believed that this complication can mostly be prevented by using the duct-to-mucosa method, because the pancreatic stump is closely fixed to the submucosal wall of the stomach. This has led to recommending the duct-to-mucosa pancreaticogastrostomy (DMPG) to prevent intragastric bleeding. The technique has been successfully used and reported by Murakami et al.[72] and others.[73]

JAYPEE BROTHERS

Technique of Duct-to-Mucosa Pancreaticogastrostomy[72]

After pancreaticoduodenal resection with or without preservation of the pylorus, the pancreatic stump is dissected from the superior mesenteric and splenic vein for a distance of 2 cm. A 3-cm incision in the seromuscular layer of the posterior gastric wall is then made. Seromuscular layer of the posterior gastric wall is approximated to the anterior wall of the pancreas (approximately 0.5 cm from the cut edge of the pancreas) using interrupted 4-0 nonabsorbable monofilament sutures. A 0.5-cm incision of the exposed gastric submucosa/mucosa is made at the opposite to the main pancreatic duct. A duct-to-mucosa anastomosis is made with interrupted 5-0 absorbable monofilament sutures. Finally, the anastomosis is completed by applying a row of interrupted 4-0 nonabsorbable monofilament sutures between the seromuscular layer of the posterior gastric wall and the posterior wall of the pancreas. Both external and internal stents can be used with DMPG. If an external drainage of pancreatic juice is deemed appropriate, the pancreatic tube inserted into the main pancreatic duct and exteriorized through the anterior gastric wall and the anterior abdominal wall (Fig. 4.7). A pancreaticogastric stent may also be placed as an internal drain of the pancreatic juice to the stomach. This stent is extruded spontaneously within 1 or 2 months after surgery.

Binding Pancreaticogastrostomy

Peng et al. have also described their experience with 105 cases of sutureless binding PG with no anastomotic leakage.[47] The technique is summarized in Figure 4.8.

Anterior Gastrostomy and Pancreaticogastrostomy and Our Experience

This technique of fashioning PG accessed through anterior gastrostomy has been reported by a few authors with excellent outcomes.[62,73-76] We have a personal experience with this technique of over 10 years and have published our early results in 2005.[77] No report about the anterior gastrostomy technique has been published in indexed medical literature from India. We prefer constructing the PG after Whipple's PD by retracting the cut end of the stomach and in pylorus preserving PD by the creating an anterior gastrostomy as depicted in Figure 4.9. We have found it particularly useful in pylorus preserving (PD) with the following benefits:

- The anastomosis is carried out under direct vision, and is technically easier to construct and ensures adequate hemostasis of the suture line, thereby preventing suture line hemorrhage that may result in life-threatening postoperative gastrointestinal bleed or predispose to leak.

JAYPEE BROTHERS

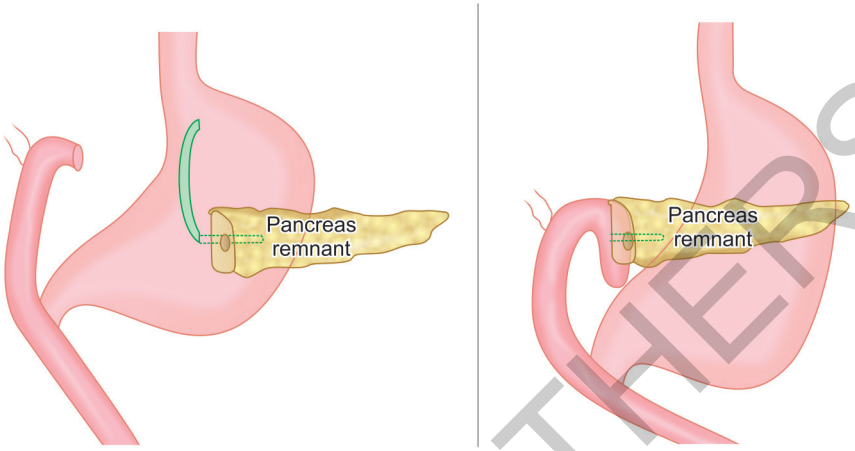

Fig. 4.7: Diagrammatic illustration of the use of pancreatic stents (external and internal) across pancreaticoenteric anastomosis.

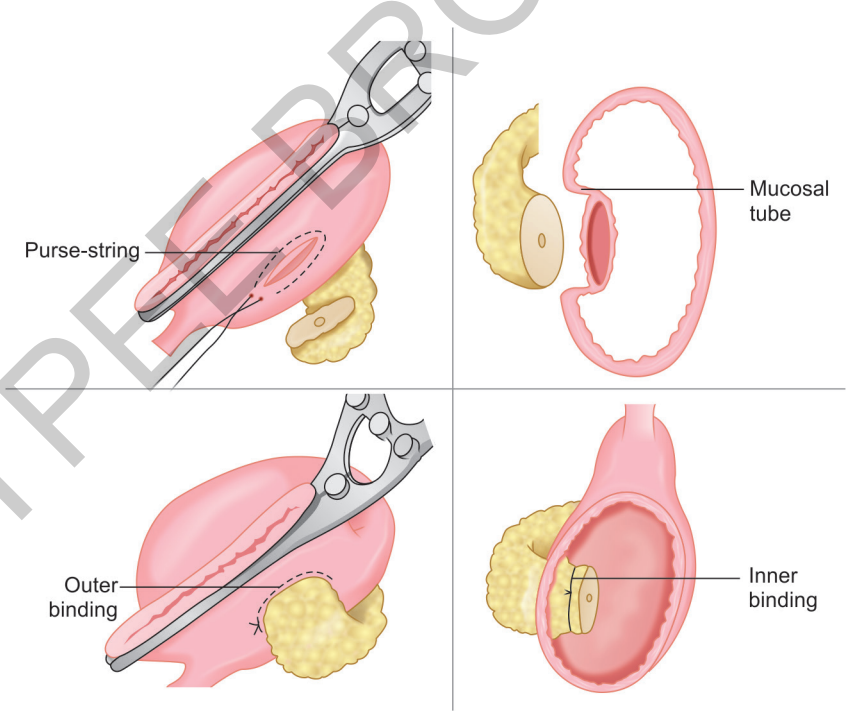

Fig. 4.8: Diagrammatic illustration of binding pancreaticogastrostomy.[47]

- The technique obviates the need for blind invagination of the pancreas that can result in uncontrolled or disproportionate tension on the suture line, accidental inclusion of the pancreatic duct or undue tightening.

JAYPEE BROTHERS

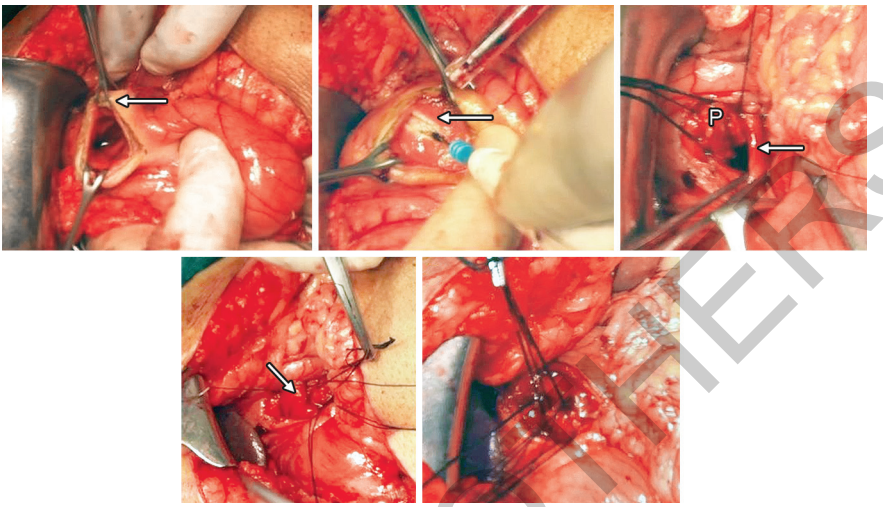

Fig. 4.9: Operative photographs depicting the technique of anterior gastrostomy and pancreaticogastrostomy as being followed in our unit.

It is well known that undue tension at the time of invagination of the pancreatic stump can result in cutting of sutures through the friable pancreas and stump pancreatitis has been attributed to a tight anastomotic technique or due to accidental occlusion of the pancreatic duct by suture. By testing for ductal patency after construction of PG, which is possible only by the anterior gastrostomy technique, one can cross-check patency.[61]

- The total operating time required is also reduced.

Bassi et al. have also published their series of 50 cases using the reconstructive technique of anterior transgastric PG after pylorus-preserving PD in 50 patients with "soft" residual parenchyma with "encouraging" results.[78]

STENT VERSUS NO STENT

Internal or external stent across pancreaticoenteric anastomosis (*see* Fig. 4.7) is commonly used by many surgeons, but the benefit remains controversial because of scarce data from randomized controlled trials. Theoretically, a stent may help to divert away the pancreatic secretion from the anastomosis, and it also allows more precise placement of sutures for duct-to-mucosa anastomosis. Internal stent across PJ anastomosis has been shown to reduce pancreatic leakage in some retrospective studies.[79,80] In contrast, a recent prospective randomized trial found that the use of a short internal stent did not reduce the frequency or the severity of PF after PD.[81] However, this trial has been criticized for not standardizing the technique of PJ anastomosis, as the use of duct-to-mucosa or invagination technique was at the discretion of the surgeons and hence the benefit of stents in a small pancreatic duct could

JAYPEE BROTHERS

have been missed. In a randomized trial involving 120 patients, Poon et al.[82] showed that an external pancreatic duct stent significantly reduces leakage rate of PJ anastomosis and hospital stay after PD with DMPJ. Small pancreatic duct and no stent were the two independent risk factors of PF in the multivariate analysis in this trial.

Compared with a short internal stent, an external stent has the theoretical advantage of more complete diversion of pancreatic secretion away from the PJ anastomosis and prevention of activation of pancreatic enzymes by bile. Moreover, a long external stent could decrease the chance of stent migration. In addition, it has also been suggested that the presence of a stent reduces severity in case a leakage occurs. The fistula can be managed with continued drainage of the stent together with octreotide in stented patients. However, one concern on the use of external drainage stent for PJ anastomosis is the potential complication associated with the stent.[81] Ohwada et al. reported two cases of local peritonitis after removal of the stent tube in 37 patients with an external stent after PJ anastomosis.[83] This complication is preventable by careful suturing of the serosa of the jejunal loop around the exit site of the tube to the peritoneum of anterior abdominal wall and allowing sufficient time (approximately 6 weeks) for formation of adhesions, which reduces the chances of intestinal content leakage.

The incidence of PF showed no significant differences between internal drainage (26%) and external drainage (20%) after PD in a randomized controlled trial by Tani et al.[84] Further, the group clarified that there was no difference in the PF rate in soft pancreas between groups with internal and external drainage tubes. Overall median postoperative hospital stay was shorter ($p = 0.016$) in the internal drainage group (21 days) versus the external drainage group (24 days).

What is the Optimal Technique of Management of Pancreatic Remnant after PD?

Results of Meta-analysis of Various Methods of Pancreaticoenteric Anastomosis

Three meta-analyses have been published on the subject.[85-87]

McKay et al. carried out a meta-analysis that included 11 articles—one randomized controlled trial, two nonrandomized prospective trials, and eight observational cohort studies carried out since 1990. They found a higher rate of PF with PJ [relative risk (RR) 2.62 (95% confidence interval (CI) 1.91–3.60)]. A higher overall morbidity rate was also demonstrated in this group [RR 1.43 (95% CI 1.26–1.61)], as was a higher mortality rate [RR 2.51 (95% CI. 1.61–3.91)]. They concluded that PG is safer though with a note of caution that much of the evidence comes from observational cohort study data.[85]

JAYPEE BROTHERS

Wente et al. also carried out a meta-analysis on 16 articles published until end of March 2006 comparing PJ and PG after PD. Results of three randomized controlled trials revealed no significant difference between PJ and PG regarding overall postoperative complications, PF, intra-abdominal fluid collection, or mortality. On the contrary, analysis of 13 nonrandomized observational clinical studies showed significant results in favor of PG (decreased rates of PF and mortality). Hence, they came to the conclusion that both PJ and PG are equally good techniques and the observational studies suffer a publication bias.[86]

Yang et al. recently in 2011 published the results of their systematic review and meta-analysis that included a total of 10 randomized controlled trials involving 1,408 patients to determine the effectiveness of methods of anastomosis after PD. The authors conducted an extensive literature search in the Cochrane Controlled Trials Register Databases, Medline, and other resources irrespective of language from database inception through March 2010 including only randomized controlled trials. The meta-analysis showed that the PF, postoperative complications, biliary fistula, mortality, reoperation, and length of hospital stay were not statistically different between the PG and PJ groups. The PF, postoperative complications, mortality, and reoperation were not statistically different between the DMPJ and PJ groups. However, BPJ was seemed to significantly decrease the PF rate and postoperative complications compared with conventional PJ. The PF, postoperative complications and mortality were not found to be statistically different between ligation of the pancreatic duct without anastomosis versus PJ. No pancreatic reconstruction technique after PD was found to be applicable to all kinds of pancreatic remnants in their systematic review and meta-analysis.[87]

INDIAN EXPERIENCE

A literature search reveals eight studies exploring the outcome following different pancreaticoenteric anastomotic techniques.[77,88-94] The only multicentric study published from India reported acceptable perioperative outcomes after PD with median number of PDs per surgeon per year of 16 (range 7–38) amongst the seven participating institutions.[89] However, no randomized trials have been conducted on the subject.

CONCLUSION

The available data from randomized controlled trials does not support the superiority of any one pancreaticoenteric anastomotic technique. A definitive picture may emerge when the results of more multicenter randomized controlled trials involving a large cohort of patients eventually becomes apparent. Some new approaches, such as BPJ and modified PG, seem to be new

JAYPEE BROTHERS

promising techniques that still need wider validation in randomized controlled trials. It seems that the best anastomosis after PD probably ultimately rests on the surgeon's preference and experience.

REFERENCES

1. van Berge Henegouwen MI, De Wit LT, Van Gulik TM, et al. Incidence, risk factors, and treatment of pancreatic leakage after pancreaticoduodenectomy: drainage versus resection of the pancreatic remnant. J Am Coll Surg. 1997;185:18-24.
2. Fujino Y, Suzuki Y, Ajiki T, et al. Risk factors influencing pancreatic leakage and the mortality after pancreaticoduodenectomy in a medium-volume hospital. Hepato Gastroenterology. 2002;49:1124-9.
3. Lin JW, Cameron JL, Yeo CJ, et al. Risk factors and outcomes in post pancreaticoduodenectomy pancreaticocutaneous fistula. J Gastrointest Surg. 2004;8: 951-9.
4. de Castro SM, Busch OR, van Gulik TM, et al. Incidence and management of pancreatic leakage after pancreatoduodenectomy. Br J Surg. 2005;92:1117-23.
5. Berger AC, Howard TJ, Kennedy EP, et al. Does type of pancreaticojejunostomy after pancreaticoduodenectomy decrease rate of pancreatic fistula? A randomized, prospective, dual institution trial. J Am Coll Surg. 2009;208:738-47; discussion 747-9.
6. Kawai M, Yamaue H. Analysis of clinical trials evaluating complications after pancreaticoduodenectomy: a new era of pancreatic surgery. Surg Today. 2010;40:1011-7.
7. Winter JW, Cameron JL, Campbell KA, et al. 1423 Pancreaticoduodenectomies for pancreatic cancer: a single-institution experience. J Gastrointest Surg. 2006;10:1199-211.
8. Birkmeyer JD, Siewers JE, Finlayson EVA, et al. Hospital volume and hospital mortality in the United States. N Engl J Med. 2002;346:1128-37.
9. Bassi C, Dervenis C, Butturini G, et al. Postoperative pancreatic fistula: an international study group (ISGPF) definition. Surgery. 2005;138: 8-13.
10. Wente MN, Veit JA, Bassi C, et al. Postpancreatectomy hemorrhage (PPH): an International Study Group of Pancreatic Surgery (ISGPS) definition. Surgery. 2007;142:20-5.
11. Wente WM, Bassi C, Dervenis C, et al. Delayed gastric emptying (DGE) after pancreatic surgery: a suggested definition by International Study Group of Pancreatic Surgery (ISGPS). Surgery. 2007;142:761-8.
12. TM VII. Resection at the pancreas. Report of a case. Ann Surg.
13. Sauve L. Des pancréatectomies et spécialement de la pancreatectomy céphalique. Rev chir. 1908;37:113-52 and 335-85.
14. Schnelldorfer T, Adams DB, Warshaw AL, et al. Forgotten pioneers of pancreatic surgery: beyond the favorite few. Ann Surg. 2008;247:191-202.
15. Halsted WS. Contributions to the surgery of the bile passages, especially of the common bile-duct. Boston Med Surg J. 1899;141:645-54.
16. Kausch W. Das Carcinom der Papilla duodeni und seine radikale Entfernung. Beitrage zur Klinische Chirurgie. 1912;78:439-86.
17. Whipple AO. The rationale of radical surgery for cancer of the pancreas and ampullary region. Ann Surg. 1941;114:612.

JAYPEE BROTHERS

18. Hunt VC. Surgical management of carcinoma of the ampulla of Vater and of the periampullary portion of the duodenum. Ann Surg. 1941;114:570-602.
19. Child CG. Pancreaticojejunostomy and other problems associated with the surgical management of carcinoma involving the head of the pancreas. Report of five additional cases of radical pancreaticoduodenectomy. Ann Surg. 1944;119:845-55.
20. Gulbinas A, Barauskas G, Pundzius J. Pancreaticojejunal anastomosis: the "Achilles heel" of pancreaticoduodenectomy. Medicina (Kaunas). 2004;40: 927-34.
21. Tewari M, Hazrah P, Kumar V, et al. Options of restorative pancreaticoenteric anastomosis following pancreaticoduodenectomy: A review. Surg Oncol. 2010;19:17-26.
22. Sarr MG, Behrns KE, van Heerden JA. Total pancreatectomy. An objective analysis of its use in pancreatic cancer. Hepatogastroenterology. 1993;40:418-21.
23. Blumgart LH. Cephalic Pancreaticoduodenectomy. In: Blumgart (ed). Video Atlas. Liver, Biliary and Pancreatic Surgery. Amsterdam: Elsevier; Pp. 165-75.
24. Kleespies A, Rentsch M, Seeliger H, et al. Blumgart anastomosis for pancreaticojejunostomy minimizes severe complications after pancreatic head resection Br J Surg. 2009;96:741-50.
25. Benzoni E, Zompicchiatti A, Saccomano E, et al. Postoperative complications linked to pancreaticoduodenectomy. An analysis of pancreatic stump management. J Gastrointestin Liver Dis. 2008;17:43-7.
26. Tran K, Van Eijck C, Di Carlo V, et al. Occlusion of the pancreatic duct versus pancreaticojejunostomy: a prospective randomized trial. Ann Surg. 2002;236:422-8.
27. Reissman P, Perry Y, Cuenca A, et al. Pancreaticojejunostomy versus controlled pancreaticocutaneous fistula in pancreaticoduodenectomy for periampullary carcinoma. Am J Surg. 1995;169:585-8.
28. Yang YL, Xu XP, Wu GQ, et al. Prevention of pancreatic leakage after pancreaticoduodenectomy by modified Child pancreaticojejunostomy. Hepatobiliary Pancreat Dis Int. 2008;7:426-9.
29. Warren KW. Surgical considerations in the management of chronic relapsing pancreatitis. Surg Clin N Am. 1955:35:785-99.
30. Tani M, Onishi H, Kinoshita H, et al. The evaluation of duct-to-mucosal pancreaticojejunostomy in pancreaticoduodenectomy. World J Surg. 2005;29:76-9.
31. Lee SE, Yang SH, Jang JY, Kim SW. PF after pancreaticoduodenectomy: a comparison between the two pancreaticojejunostomy methods for approximating the pancreatic parenchyma to the jejunal seromuscular layer: interrupted vs. continuous stitches. World J Gastroenterol. 2007;13:5351-6.
32. Hakamada K, Narumi S, Toyoki Y, et al. An easier method for performing a pancreaticojejunostomy for the soft pancreas using a fast-absorbable suture. World J Gastroenterol. 2008;14:1091-6.
33. Matsumoto Y, Fujii H, Miura K, et al. Successful pancreatojejunal anastomosis for pancreatodenectomy. Surg Gynecol Obstet. 1992;175:555-62.
34. Tsuji M, Kimura H, Konishi K, et al. Management of continuous anastomosis of pancreatic duct and jejunal mucosa after pancreaticoduodenectomy: historical study of 300 patients. Surgery. 1998;123:617-21.
35. Hwang TL, Jan YY, Chen MF. Secural pancreaticojejunal anastomosis for the pancreaticoduodenectomy. Hepatogastroenterology. 1996;43:275-7.

JAYPEE BROTHERS

36. Bassi C, Falconi M, Molinari E, et al. Duct-to-mucosa versus end-to-side pancreaticojejunostomy reconstruction after pancreaticoduodenectomy: results of a prospective randomized trial. Surgery. 2003;134:766-71.
37. Chou FF, Sheen-Chen SM, Chen YS, et al. Postoperative morbidity and mortality of pancreaticoduodenectomy for periampullary cancer. Eur J Surg. 1996;162: 477-81.
38. Nguyen JH. Distinguishing between parenchymal and anastomotic leakage at duct-to-mucosa pancreatic reconstruction in pancreaticoduodenectomy. World J Surg. 2008;21:6648-54.
39. Ohwada S, Iwazaki S, Nakamura S, et al. Pancreaticojejunostomy-securing technique: duct-to mucosa anastomosis by continuous running suture and parachuting using monofilament absorbable thread. J Am Coll Surg. 1997;185:190-4.
40. Grobmyer SR, Kooby D, Blumgart LH, et al. Novel pancreaticojejunostomy with a low rate of anastomotic failure-related complications. J Am Coll Surg. 2010;210:54-9.
41. Kakita A, Yoshida M, Takahashi T. History of pancreaticojejunostomy in pancreaticoduodenectomy: development of a more reliable anastomosis technique. J Hepatobiliary Pancreat Surg. 2001;8:230-7.
42. Ochiai T, Sonoyama T, Soga K, et al. Application of polyethylene glycolic acid felt with fibrin sealant to prevent postoperative PF in pancreatic surgery. J Gastrointest Surg. 2010;14:884-90.
43. Matsumoto Y, Fujii H, Miura K, et al. Successful pancreatojejunal anastomosis for pancreaticoduodencetomy. Surg Gynecol Obstet. 1992;175:555-62.
44. Goldsmith HS, Ghosh BC, Huvos AG. Ligation versus implantation of the pancreatic duct after pancreaticoduodencetomy. Surg Gynecol Obstet. 1971;132:87-92.
45. Strasberg SM, Drebin JA, Mokadam NA, et al. Prospective trial of a blood supply-based technique of pancreaticojejunostomy: effect on anastomotic failure in the Whipple Procedure. J Am Coll Surg. 2002;194:746-58.
46. Peng SY, Mou YP, Cai XJ, et al. Binding pancreaticojejunostomy is a new technique to minimize leakage. Am J Surg. 2002;183:283-5.
47. Peng SY, Wang JW, Hong de F, et al. Binding pancreaticoenteric anastomosis: from binding pancreaticojejunostomy to binding pancreaticogastrostomy. Updates Surg. 2011;63:69-74.
48. Peng SY, Wang JW, Lau WY, et al. Conventional versus binding pancreaticojejunostomy after pancreaticoduodenectomy: a prospective randomized trial. Ann Surg. 2007;245:692-8.
49. Tajima Y, Kuroki T, Tsuneoka N, et al. Anatomy-specific pancreatic stump management to reduce the risk of PF after pancreatic head resection. World J Surg. 2009;33:2166-76.
50. Huang DY, Wang XF, Zhou W, et al. Polypropylene mesh-reinforced pancreaticojejunostomy for periampullar neoplasm. World J Gastroenterol. 2007;13: 6072-5.
51. Waugh JM, Clagett OT. Resection of the duodenum and head of the pancreas for carcinoma. Surgery. 1946;20:224-32.
52. Flautner L, Tihanyi T, Szecseny A. Results in 101 cases of pancreaticoduodenectomy in the management of chronic pancreatitis. Method of pylorus preservation versus Whipple's operation. Orv Hetil. 1985;126:2943-9.
53. Flautner L, Tihanyi T, Szecseny A. Pancreaticogastrostomy: an ideal complement to pancreatic head resection with preservation of pylorus in the treatment of chronic pancreatitis. Am J Surg. 1985:150:608-11.

JAYPEE BROTHERS

54. Delcore R, Thomas JH, Pierce GE, et al. Pancreatogastrostomy: A safe drainage procedure after pancreatoduodenectomy. Surgery. 1990;108:641-7.
55. Mackie JA, Rhoads JE, Park CD. Pancreaticogastrostomy: A further evaluation. Ann Surg. 1975;181:541-5.
56. Telford GL, Mason GR. Pancreaticogastrostomy: Clinical experience with a direct pancreatic-duct-to-gastric-mucosa anastomosis. Am J Surg. 1984;147:832-7.
57. Miyagawa S, Makuuchi M, Lygidakis NJ, et al. A retrospective comparative study of reconstructive methods following pancreaticoduodenectomy—pancreaticojejunostomy vs pancreaticogastrostomy. Hepatogastroenterology. 1992;39:381-4.
58. Baumel H, Huguier M, Manderscheid JC, et al. Results of resection for cancer of the exocrine pancreas: a study from the French Association of Surgery. Br J Surg. 1994;81:102-7.
59. Mason GR, Freeark RJ. Current experience with pancreaticogastrostomy. Am J Surg. 1995;169:217-9.
60. Tuech JJ, Pessaux P, Duplessis R, et al. Pancreatojejunal or pancreatogastric anastomosis after cephalic duodenopancreatectomy. A comparative retrospective study. Chirurgie. 1998;123:450-5.
61. Arnaud JP, Tuech JJ, Cervi C, et al. Pancreaticogastrostomy compared with pancreaticojejunostomy after pancreaticoduodenectomy. Eur J Surg. 1999;165:357-62.
62. Takano S, Ito Y, Oishi H, et al. A retrospective analysis of 88 patients with Pancreaticogastrostomy after pancreaticoduodenectomy. Hepatogastroenterology. 2000;47:1454-7.
63. Arkossy P, Toth P, Kovacs I, et al. New reconstructive surgery of remnant pancreas in cases of cancer of Vater's papilla. Hepatogastroenterology. 2002;49:255-7.
64. Schlitt HJ, Schmidt U, Simunec D, et al. Morbidity and mortality associated with pancreatogastrostomy and pancreatojejunostomy following partial pancreatoduodenectomy. Br J Surg. 2002;89:1245-51.
65. Aranha GV, Hodul P, Golts E, et al. A comparison of pancreaticogastrostomy and pancreaticojejunostomy following pancreaticoduodenectomy. J Gastrointest Surg. 2003;7:672-82.
66. Oussoultzoglou E, Bachellier P, Bigourdan JM, et al. Pancreaticogastrostomy decreased relaparotomy caused by PF after pancreaticoduodenectomy compared with pancreaticojejunostomy. Arch Surg. 2004;139:327-35.
67. Takano S, Ito Y, Wantanabe Y, et al. Pancreaticojejunostomy versus Pancreaticogastrostomy in reconstruction following pancreaticoduodenectomy. Br J Surg. 2000;87:423-7.
68. Yeo CJ, Cameron JL, Maher MM, et al. A prospective randomized trial of Pancreaticogastrostomy versus pancreaticojejunostomy after pancreaticoduodenectomy. Ann Surg. 1995;222:580-92.
69. Duffas JP, Suc B, Msika S, et al. A controlled randomized multicenter trial of pancreatogastrostomy or pancreatojejunostomy after pancreatoduodenectomy. Am J Surg. 2005;189:720-9.
70. Bassi C, Falconi M, Molinari E, et al. Reconstruction by pancreaticojejunostomy versus pancreaticogastrostomy following pancreatectomy. Results of a comparative study. Ann Surg. 2005;242:767-73.
71. Aranha GV, Hodul PJ, Creech S, et al. Zero mortality after 152 consecutive pancreaticoduodenectomies with pancreaticogastrostomy. J Am Coll Surg. 2003;197:223-31.

JAYPEE BROTHERS

72. Murakami Y, Uemura K, Hayashidani Y, et al. No mortality after 150 consecutive pancreatoduodenctomies with duct-to-mucosa Pancreaticogastrostomy. J Surg Oncol. 2008;97:205-9.
73. Hyodo M, Nagai H. Pancreatogastrostomy (PG) after pancreatoduodenectomy with or without duct to mucosa anastomosis for the small pancreatic duct: short and long term results. Hepatogastroenterology. 2000;47:1138-41.
74. Takano S, Iwai S, Tanaka T. Improved technique for pancreaticogastrostomy with implantation method after pancreaticoduodenectomy. Int Surg. 1998;83:128-30.
75. Takada T, Yasuda H, Uchiyama K, et al. Pancreatic enzyme activity after a pylorus preserving PD reconstructed with pancreaticogastrostomy. Pancreas. 1995;11:276-82.
76. Yamamoto J, Shimamura Y, Nakahara H, et al. Simple technique for Pancreaticogastrostomy and histologic findings of pancreaticogastric anastomosis. Arch Surg. 1997;132:785-8.
77. Tewari M, Shukla HS. Anterior gastrotomy technique of fashioning pancreaticogastrostomy following pancreatico-duodenectomy for pancreatic head and periampullary cancer. Indian J Surg. 2005;67:339-41.
78. Bassi C, Butturini G, Salvia R, et al. Open pancreaticogastrostomy after pancreaticoduodenectomy: a pilot study. J Gastrointest Surg. 2006;10:1072-80.
79. Yoshimi F, Ono H, Asato Y, et al. Internal stenting of the hepaticojejunostomy and pancreaticojejunostomy in patients undergoing pancreatoduodenectomy to promote earlier discharge from hospital. Surg Today. 1996;26:665-7.
80. Shibuya T, Uchiyama K, Imai S, et al. Improvement of pancreaticojejunostomy in pancreatoduodenectomy. Int Surg. 1995;80:57-60.
81. Winter JM, Cameron JL, Campbell KA, et al. Does pancreatic duct stenting decrease the rate of PF following pancreaticoduodenectomy? Results of a prospective randomized trial. J Gastrointest Surg. 2006;10:1280-90.
82. Poon RTP, Fan ST, Lo CM, et al. External drainage of pancreatic duct with a stent to reduce leakage rate of pancreaticojejunostomy after pancreaticoduodenectomy. A prospective randomized trial. Ann Surg. 2007;246:425-35.
83. Ohwada S, Tanahashi Y, Ogawa T, et al. In situ vs ex situ pancreatic duct stents of duct-to-mucosa pancreaticojejunostomy after pancreaticoduodenectomy with Billroth I-type reconstruction. Arch Surg. 2002;137:1289-93.
84. Tani M, Kawai M, Hirono S, et al. A prospective randomized controlled trial of internal versus external drainage with pancreaticojejunostomy for pancreaticoduodenectomy. Am J Surg. 2010;199(6):759-64.
85. McKay A, Mackenzie S, Sutherland FR, et al. Meta-analysis of pancreaticojejunostomy versus pancreaticogastrostomy reconstruction after pancreaticoduodenectomy. Br J Surg. 2006;93:929-36.
86. Wente MN, Shrikhande SV, Muller MW, et al. Pancreaticojejunostomy versus pancreaticogastrostomy: systematic review and meta-analysis. Am J Surg. 2007;193:171-83.
87. Yang SH, Dou KF, Sharma N, et al. The methods of reconstruction of pancreatic digestive continuity after pancreaticoduodenectomy: a meta-analysis of randomized controlled trials. World J Surg. 2011;35:2290-7.
88. Mishra PK, Saluja SS, Gupta M, et al. Blumgart's technique of pancreaticojejunostomy: an appraisal. Dig Surg. 2011;28:281-7.
89. Shukla PJ, Barreto SG, Bedi M, et al. Peri-operative outcomes for pancreaticoduodenectomy in India: a multi-centric study. HPB (Oxford). 2009;11:638-44.

JAYPEE BROTHERS

90. Shrikhande SV, Barreto G, Shukla PJ. PF after pancreaticoduodenectomy: the impact of a standardized technique of pancreaticojejunostomy. Langenbecks Arch Surg. 2008;393:87-91.
91. Kapoor VK, Sharma A, Behari A, et al. Omental flaps in pancreaticoduodenectomy. JOP. 2006;7:608-15.
92. Asopa HS, Garg M, Singhal GG, et al. Pancreaticojejunostomy with invagination of spatulated pancreatic stump into a jejunal pouch. Am J Surg. 2002;183:138-41.
93. Kapur BM, Misra MC, Seenu V, et al. Pancreaticogastrostomy for reconstruction of pancreatic stump after pancreaticoduodenectomy for ampullary carcinoma. Am J Surg. 1998;176:274-8.
94. Ramesh H, Thomas PG. Pancreaticojejunostomy versus pancreaticogastrostomy in reconstruction following pancreaticoduodenectomy. Aust N Z J Surg. 1990;60:973-6.

JAYPEE BROTHERS

for detailed information on gastroenterology books, visit our website **www.jaypeebrothers.com,** for detailed inform

Gastrointestinal Surgery Series

PANCREAS AND HEPATOBILIARY SURGERY

Gastrointestinal Surgery Series: Pancreas and Hepatobiliary Surgery is book covering extensive technical issues for pancreatic surgery and about liver and gallbladder surgery targeting for postgraduate students and young surgeons



Prabin Bikram Thapa MS is Professor of Department of Surgery, Kathmandu Medical College Teaching Hospital, Sinamangal, Kathmandu, Nepal. His work encircles exclusively the field of surgical gastroenterology with introduction of many noble techniques in surgical fraternity of Nepal including laparoscopic Whipple's operation and enhanced recovery after surgery (ERAS) in gastrointestinal (GI) Surgery. In Nepal, he has the distinction of pioneering laparoscopic surgery and for this achievement; he has been awarded Young Scientist Award by Nepal Academy of Science and Technology (NAST). Besides, he has been invited as Speaker in different national and international conferences.



Dhiresh Kumar Maharjan MRCSEd FCPS is a Lecturer in Department of Surgery, Kathmandu Medical College Teaching Hospital, Sinamangal, Kathmandu, Nepal. He has devoted his work in the field of surgical gastroenterology. He has been invited as Speaker in various national and international conferences. He has been part of BMJ Awards South Asia as a Jury Panel Member.

Available at all medical bookstores or buy online at www.jaypeebrothers.com

JAYPEE BROTHERS
Medical Publishers (P) Ltd.
www.jaypeebrothers.com

Join us on facebook.com/JaypeeMedicalPublishers

Shelving Recommendation
GASTROENTEROLOGY

ISBN 978-93-5270-260-2