peebrothers.com, for detailed information on anesthesia books, visit our website www.jaypeebrothers.com, for detailed information on anesthesia boo

Applications of Ultrasound in Anesthesia

A Handbook



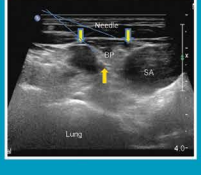

Kavita S Lalchandani

Foreword
MR Upadhyay

JAYPEE

CONTENTS

Chapter 1. **Basics of Ultrasound** **1**

- Parts of the Ultrasound Machine 3
- Different Types of Ultrasound 7
- Selecting an Ultrasound Transducer Probe Based on Frequency, Array and Footprint 9
- Learning to Scan 11
- Artifacts 12
- Ultrasound Terminology 14

Chapter 2. **Ultrasound-guided Central Venous Access** **16**

- Basic Principles 18
- Indications and Contraindications 18
- Equipment Specifications 20
- General Protocol for Central Line Placement 21
- General Consideration for Ultrasound-guided Vascular Access 25
- Ultrasound-guided Vascular Access Line Placement 34
- Technique for Internal Jugular Vein Cannulation 36
- Technique for Subclavian Vein 44
- Technique for Femoral Vein Cannulation 48
- Alternative Central Venous Cannulation Sites 49
- Documentation 51

Chapter 3. **Complications and their Management** **57**

- Complications of Central Venous Access 57
- Infectious Complications of Central Venous Catheterization and their Prevention 58
- Mechanical Complications 60
- Management of Arterial Trauma or Injury due to Central Venous Catheterization 62
- Thrombotic Complications 63

Chapter 4. **Ultrasound-guided Peripheral Venous Access 66**

- Peripheral Venous Access 66
- Technique for Ultrasound-guided Peripheral Venous Access 68

Chapter 5. **Introduction of Ultrasound-guided Regional Block 75**

- History 75
- Local Anesthetic Agents 76
- Regional Anesthesia 78
- Ultrasound-guided Regional Blocks 83

Chapter 6. **Upper Extremity Nerve Blocks 86**

- Brachial Plexus Block 87
- Ultrasound-guided Forearm Block 103

Chapter 7. **Lower Extremity Nerve Blocks 110**

- Ultrasound-guided Femoral Nerve Block 110
- Ultrasound-guided Popliteal Sciatic Nerve Block 113

Chapter 8. **Transversus Abdominis Plane Block 119**

- Anatomy 119
- Indications 121
- The Landmark Technique for TAP Block 122
- Ultrasound-guided TAP Block 122
- Ultrasound Anatomy 122
- Technique of TAP Block 125
- Complications 129

Index *131*

4

Chapter

Ultrasound-guided Peripheral Venous Access

JAYPEE BROTHERS

PERIPHERAL VENOUS ACCESS

Introduction

- Peripheral veins are usually easy to access directly but in certain conditions like burns, trauma, obesity it may be difficult to access directly peripheral vein, in such conditions deep veins which are not visualized or felt can be cannulated using ultrasound
- Usually peripheral veins are easily seen but sometimes if it lying deep they can be made prominent by dependent position or by applying tourniquet proximally. They are thin walled.

Important Points to Cannulate Peripheral Veins

- Peripheral veins are easily accessed at "branch points" where two smaller veins merge into a larger one
- Always start with distal veins before proximal ones
- The upper extremity is preferred to the lower extremity
- Do not attempt over a joint—for catheter security, to improve flow through the catheter, and for maximum patient comfort and mobility

- Avoid peripheral venous access through overlying infected skin, or in the same extremity as a significant traumatic injury, burn, or edema
- Avoid cannulation of an extremity with an arteriovenous fistula or other dialysis access.

Indications and Contraindications

- For medication or intravenous contrast administration
- Laboratory testing of venous blood, fluid resuscitation in situations like shock, trauma.

Peripheral cannulation should be avoided when sclerosing or vasoactive medications or extraordinarily concentrated solutions need to be infused. In such conditions central venous access is preferred.

Special Considerations, Complications, and Pearls and Pitfalls

- External jugular vein or deep brachial vein is preferred first when other sites for peripheral veins are difficult
- While performing procedure under ultrasound guidance veins are seen as black (fluid-filled, hypoechoic) circular structures that are nonpulsatile and easily compressible.

Following are certain conditions where ultrasound will be very much helpful for peripheral venous line placement.

- Obesity
- Dark-skinned patient
- An intravenous drug abuser
- At the extremes of age
- Hypotensive patient
- Patient having multiple injuries limiting the number of limbs available for use
- Patients on chemotherapy

JAYPEE BROTHERS

- Patients with end-stage renal disease
- Nursing home patients with multiple IV scars
- The upper limb peripheral cannulation is the preferred site over lower limb because of the increased incidence of thrombophlebitis and thrombosis with lower limb infusions, as well as the need to often immobilize the patient if a drip is sited in the lower limb. The non-dominant upper limb is preferred as an initial option.

TECHNIQUE FOR ULTRASOUND-GUIDED PERIPHERAL VENOUS ACCESS

- As such technique remains same as the central venous access
- Three main peripheral veins of the antecubital region are: (1) Basilic, (2) cephalic, and (3) brachial veins (Fig. 1). Any other peripheral vein can also be cannulated under ultrasound guidance using same method
- These veins are variable in location and are surrounded by nerves. Hence, ultrasound guidance is helpful when cannulating these veins. The basilic vein passes upward and anteromedially to the elbow, where it receives the medial cubital vein. Then it continues on the medial to the biceps brachii, deep to the fascia, until it joins the brachial vein and becomes the axillary vein at the border of the teres major.

  Figure 2 shows probe position for brachial vein cannulation and Figure 3 demonstrates correct positioning of the transducer for cephalic vein cannulation. The cephalic vein lies laterally in the superficial fascia of the antecubital fossa and it ascends along the lateral side of the forearm and upper arm. As with central venous access, place the transducer in the short-axis view and scan the vessels in the antecubital fossa. Move the probe from lateral to medial to assess vessel location.

JAYPEE BROTHERS

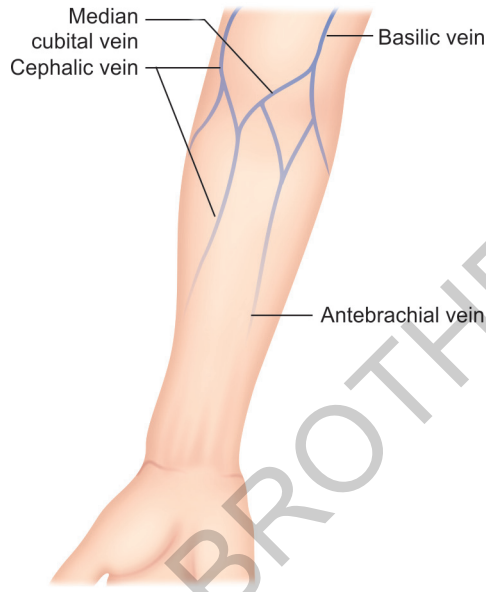

Fig. 1: Anatomic positioning of the major vessels of the antecubital region. The basilic, cephalic and brachial veins



Fig. 2: Transducer position for brachial vein cannulation

JAYPEE BROTHERS



Fig. 3: Probe position for cephalic vein cannulation

Equipment Required for US-guided Peripheral Venous Access

- High-frequency linear transducer, gel
- Gloves
- Topical local anesthetic (especially for pediatric patients)
- Catheter and needle device
- Gauze, tape, and transparent dressing
- Antiseptic solution or wipe
- Tourniquet
- IV tubing, flushes, syringe.

Technique for Peripheral Venous Access

- *Position of the patient:* Patient should be positioned in supine position with the extremity of choice extended on a flat surface, palm up
- *Transducer position:* Horizontally in antecubital fossa

JAYPEE BROTHERS

- Start scanning from lateral to medial side without giving much pressure as veins are easily compressible. You may need to tilt transducer to find out the vein
- Now bring the image of vein in the middle of the screen and confirm with color Doppler
- Then insert the needle out of plane at a 45° angle to the skin
- As soon as the needle is inserted in the skin, attempt to find out the tip by sweeping distally with the probe. Aspirate to confirm the needle position
- Now thread the catheter over the needle tip to cannulate the vein and secure the catheter
- The position of catheter can also be confirmed by changing the plane of transducer.

Ultrasound Guidance for Peripherally Inserted Central Catheter

- Peripherally inserted central venous catheters (PICCs) are nowadays used as alternative to central venous access in patients requiring long-term intravenous therapy
- Advantages of the PICC include:
  - Chances of complications like air embolism, pneumothorax, DVT, major arterial puncture hence hematoma etc. are decreased compared to central venous access
  - Procedure is easy and can be performed bedside
  - Cost-effective.

Advantages of Ultrasound Guidance for PICC Placement

- Increased success rate
- Easy to visualize vessel
- Reducing the risk of arterial puncture.

JAYPEE BROTHERS

Technique for Ultrasound-guided Peripherally Inserted Central Catheter Placement

- The most common site for venous access for a PICC is obtained through an antecubital vein. The success rate with basilica vein is high compared to cephalic vein as the course of cephalic vein is tortuous
- The procedure should be carried out under full antiseptic precaution same as mentioned above for basilica or cephalic vein cannulation
- The ultrasound guidance should be used to confirm the position of guidewire and catheter.

Sometimes catheter tip may move cephalic so to confirm proper position three different techniques are used:

- Ultrasound guidance helps to confirm PICC placement by visualizing agitated saline from an intravenous flush in the right atrium of the heart after placement
- Electrocardiographic guidance helps to confirm the tip position
- Post-procedure X-ray chest should be carried out.

Ultrasound Guidance for Arterial Access Procedures

Arterial access is used for invasive blood pressure monitoring as well as for procedural purposes. Ultrasound guidance helps in identifying and accessing the arterial lumen in patients that have good external anatomic landmarks as well as in patients whose external landmarks are less well-defined.

US-guidance for arterial access is particularly useful:

- In patients with obesity
- Altered anatomy

JAYPEE BROTHERS

- Low systemic perfusion, or nonpulsatile blood flow
- Patients in whom previous cannulation attempts have been unsuccessful.

Common sites for arterial access include femoral, radial, brachial, axillary, and dorsalis pedis arteries.

The radial artery cannulation is safe because of its accessibility, predictable location, and low complication rates associated with both its access and use. It is usually easily palpable and is also not typically the sole blood supply to the distal extremity, unlike the axillary, brachial, and femoral arteries.

Technique for Ultrasound-guided Arterial Access

The technique for ultrasound-guided aterial access remains same except following points:

- Arteries should be identified and differentiated from veins using color Doppler and pulse wave Doppler
- Identification of plaque, arterial spasm, hematoma, or decreased luminal diameter with ultrasound helps to avoid futile cannulation attempts and directs the operator to a more desirable location
- For radial artery cannulation, an Allen test for collateral perfusion should be performed
- For optimal positioning of the wrist put support below the wrist joint that should include a support that allows the wrist to be approximately 45° extended (more than 45° may cause the vessel to be compressed)
- Conditions such as hypotension, low cardiac output, and an excessive limb circumference that contribute to arterial cannulation failures with a landmark-guided technique may be equally challenging despite ultrasound guidance
- The rest of the procedure is same as in central and peripheral venous cannulation.

JAYPEE BROTHERS

BIBLIOGRAPHY

1. Feldman R. General principles of intravenous access. In: Reichman EF, Simon RR (Eds). Emergency medicine procedures. New York: McGraw-Hill; 2004;314-37.
2. Keyes LE, Frazee BW, Snoey ER, et al. Ultrasound-guided brachial and basilica vein cannulation in emergency department patients with difficult intravenous access. Ann Emerg Med. 1999;34(6):711.
3. Lewis GC, et al. Critical skills and Procedures in Emergency Medicine: Vascular Access skills and procedures. Emerg Med Clin North Am. 2013;31(1):59-86.
4. Mbamalu D, Banerjee A. Methods of obtaining peripheral venous access in difficult situations. Postgrad Med. 1999;75(886):459.
5. Reichman EF, Oakes JL. Vascular access. In: Wolfson AB, (Ed). Harwood-Nuss' Clinical Practice of Emergency Medicine. 4th edition. Philadelphia: Lippincott Williams & Wilkins; 2005;43-55.
6. Roseman JM. Deep, percutaneous antecubital venipuncture: an alternative to surgical cutdown. Am J Surg. 1983;146(2):285.
7. Sierzenski PR, Gukhool J, Leech SJ. Emergency ultrasound. In: Knoop KJ, (Ed). The Atlas of Emergency Medicine. 3rd edition. New York: McGraw-Hill; 2010.
8. Stroud S, Rodriguez R. Arterial puncture and cannulation. In: Reichman EF, Simon RR, (Eds). Emergency Medicine Procedures. New York: McGraw-Hill; 2004;398-410.

JAYPEE BROTHERS

for detailed information on anesthesia books, visit our website **www.jaypeebrothers.com,** for detailed information on anesthesia books, visit our websi

Applications of
Ultrasound in Anesthesia
A Handbook

Salient Features

- A handy user-friendly book
- Presents the text in simple language
- Provides practical tips about ultrasound-guided procedures in anesthesia
- Includes basic terminologies of ultrasound along with neat and clean images
- Helpful to the readers while performing the ultrasound-guided procedures
- A must for the students, beginners and practitioners of ultrasound.



Kavita S Lalchandani MD DA (Anesthesiology) Fellow in Emergency Medicine is working as Associate Professor in the Department of Anesthesiology at SSG Hospital and Medical College, Vadodara, Gujarat, India. She has 23 years of experience in the field of anesthesia. She has also worked in emergency medicine department for four years.

Available at all medical bookstores
or buy online at www.jaypeebrothers.com

JAYPEE BROTHERS
Medical Publishers (P) Ltd.
www.jaypeebrothers.com

Join us on facebook.com/JaypeeMedicalPublishers

Shelving Recommendations
ANESTHESIA, RADIOLOGY

ISBN 978-93-5270-270-1