ebrothers.com, for detailed information on respiratory medicine books, visit our website www.jaypeebrothers.com, for detailed information on respiratory medici

Celebrating 50
Passion, Quality and Innovation in He

BRONCHOSCOPY CASES

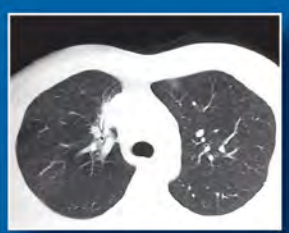

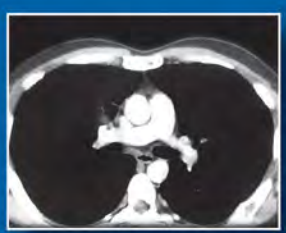

Raj Kumar

Foreword
Digambar Behera (Padma Awardee)

JAYPEE

CONTENTS

Section 1: Pulmonary Tuberculosis

Case 1 1
Case 2 3
Case 3 5
Case 4 7
Case 5 9
Case 6 11
Case 7 13
Case 8 15
Case 9 17
Case 10 19
Case 11 21
Case 12 23
Case 13 25
Case 14 27
Case 15 29
Case 16 31
Case 17 33
Case 18 35
Case 19 37
Case 20 39
Case 21 41
Case 22 43
Case 23 45
Case 24 47
Case 25 49

Section 2: Sarcoidosis

Case 1 51
Case 2 54
Case 3 57
Case 4 59
Case 5 61
Case 6 63
Case 7 66
Case 8 68
Case 9 71
Case 10 74
Case 11 76
Case 12 78
Case 13 80
Case 14 82

Section 3: ILD-CTD

Case 1 85
Case 2 88
Case 3 90
Case 4 92
Case 5 94
Case 6 96
Case 7 98
Case 8 100

Section 4: ILD-IPF/NSIP

Case 1 103
Case 2 106
Case 3 108
Case 4 110
Case 5 112
Case 6 114

Case 7 116
Case 8 118
Case 9 120
Case 10 123
Case 11 125
Case 12 127
Case 13 129
Case 14 131
Case 15 133
Case 16 135
Case 17 137
Case 18 139
Case 19 141
Case 20 143
Case 21 145
Case 22 147
Case 23 149
Case 24 151
Case 25 153
Case 26 155
Case 27 157
Case 28 159
Case 29 161
Case 30 163
Case 31 165
Case 32 167

Section 5: Hypersensitivity Pneumonitis

Case 1 170
Case 2 173
Case 3 175
Case 4 177
Case 5 179
Case 6 181

Case 7 184
Case 8 186
Case 9 188
Case 10 190
Case 11 192

Section 6: Malignancy

Case 1 195
Case 2 197
Case 3 199
Case 4 201
Case 5 203
Case 6 205
Case 7 207
Case 8 209
Case 9 211
Case 10 213
Case 11 215
Case 12 217
Case 13 219
Case 14 221
Case 15 223
Case 16 225

Section 7: Miscellaneous

Case 1 228
Case 2 230

Index 233

Section 3: ILD-CTD

CASE 1

Clinical profile

56-year-old female

- **History:**
  - Breathlessness for 4 years: Insidious, persistent, progressive, mMRC grade 3 at presentation
  - Cough for 1.5 years: Intermittent, mucoid scanty sputum, no diurnal variation, and no hemoptysis
  - No history of fever, weight loss, loss of appetite, chest pain, dysphagia, joint pain, dry eyes, Raynaud's phenomenon
- **Past history:** ATT taken (23/8/2013 to 18/2/2014)
  - No h/o DM/ HTN/ CAD
- **Personal history:** Ex-smoker, started at the age of 15 years, 2–3 cigarettes per day
- **Chest auscultation:** Bilateral vesicular breath sound, bilateral fine inspiratory crepts

Work up

- **Hemoglobin:** 12.4 g/dL
- **TLC:** 8,300 cells/cmm
- **Blood urea/S. creatinine:** 13/0.5 mg/dL
- **Induced sputum for AFB:** Negative
- **Mantoux:** 25 mm
- **S. ACE:** 42 (N 8–65) U/L
- **S. calcium:** 8.40 mg/dL
- **Scl-70:** Positive
- **ANA:** Positive
- **6MWT:** Distance covered: 200 meters desaturation, from 96% to 84%

Radiology

Radiology showing left lower zone cavity with haziness. CT showing ground glass opacity with multiple nodules, consolidation with cavity in left lower lobe and interseptal thickening.


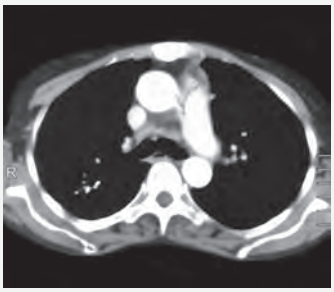
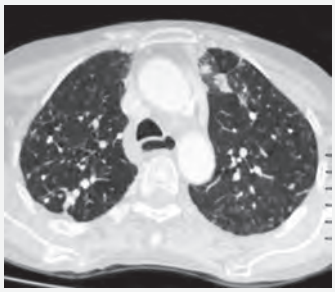

Continued

JAYPEE BROTHERS

Continued

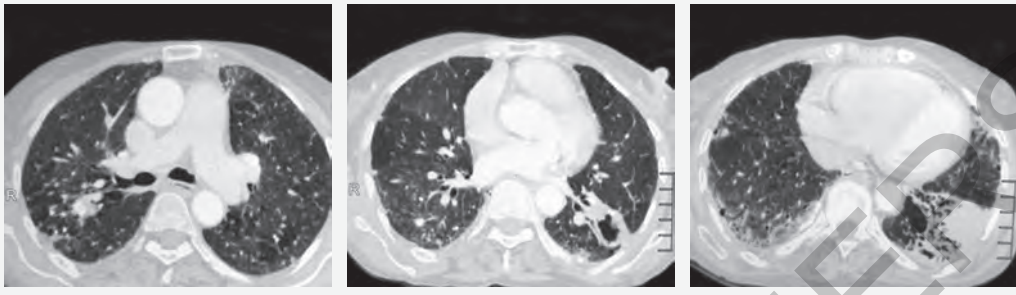

Pulmonary Function Testing

Moderately severe impairment and moderately diffusion impairment.

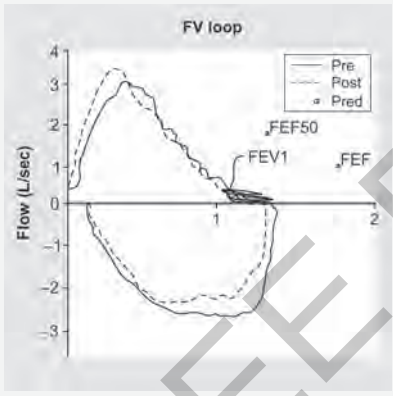

	PRE (percent predicted)	POST (percent predicted)	Percent change
FEV1/FVC (%)	85	86	1
FEV1 (L/s)	0.91 (58)	0.93 (60)	2
FVC (L)	1.26 (53)	1.321 (55)	2
FET (s)	7.96	8.72	
RV (L)	0.93 (81)		
TLC (L)	2.52 (66)		
DLCO	13.67 (61)		
DLCO/VA	6.77 (124)		

Bronchoscopy

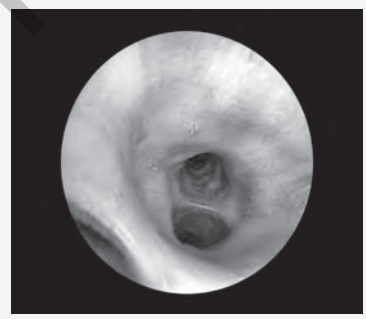

Grossly: Normal ***(For color version, see Plate 5)***

Microscopic

- **Bronchial aspirate:** Negative for acid-fast bacillus (AFB), pyogenic, fungus, and atypical cells
- **Transbronchial lung biopsy:** Chronic nonspecific changes
- **Endobronchial biopsy:** Chronic nonspecific changes

JAYPEE BROTHERS

Summary

- A 56-year-old female with progressive exertional dyspnoea and cough.
- Chest radiology showed ground glass opacity with multiple nodules, consolidation with cavity in left lower lobe and interseptal thickening.
- Pulmonary function test showed moderately severe impairment and moderately diffusion impairment.
- Bronchoscopy biopsy showed nonspecific changes. Scl-70: Positive, ANA: Positive.
- 6-minute walk test: Positive.

Final Diagnosis

ILD Scleroderma

Management

Steroids started

JAYPEE BROTHERS

CASE 2

Clinical profile

45-year-old female

- **History:**
  - Breathlessness for 4 years: Insidious, persistent, progressive, mMRC and grade 3 at presentation
  - Cough for 3 years: Intermittent, mucoid scanty sputum, no diurnal variation, and no hemoptysis
  - No h/o fever, weight loss, loss of appetite, chest pain, dysphagia, no joint pain, dry eyes, or Raynaud's phenomenon
- **Past history:** Taken antiepileptics for 10 years
  - No h/o DM/ HTN/CAD
- **Personal history:** Ex-smoker, started at the age of 15 years, 2–3 cigarettes per day
- **Chest auscultation:** Bilateral vesicular breath sounds with fine end-inspiratory crepts

Work up

- **Hemoglobin:** 10.4 g/dL
- **TLC:** 10,300 cells/cmm
- **Blood urea/S. creatinine:** 13/0.5 mg/dL
- **Induced sputum for AFB:** Negative
- **Mantoux:** Negative
- **ANA:** Negative
- **Scl-70:** Positive
- **6MWT:** Distance covered 500 meters, desaturation from 97% to 93%

Radiology

Radiology showing basal reticular shadows. Right more than left. CT scan showing ground glass opacity, nodularity, interlobular septal thickening with traction bronchiectasis.

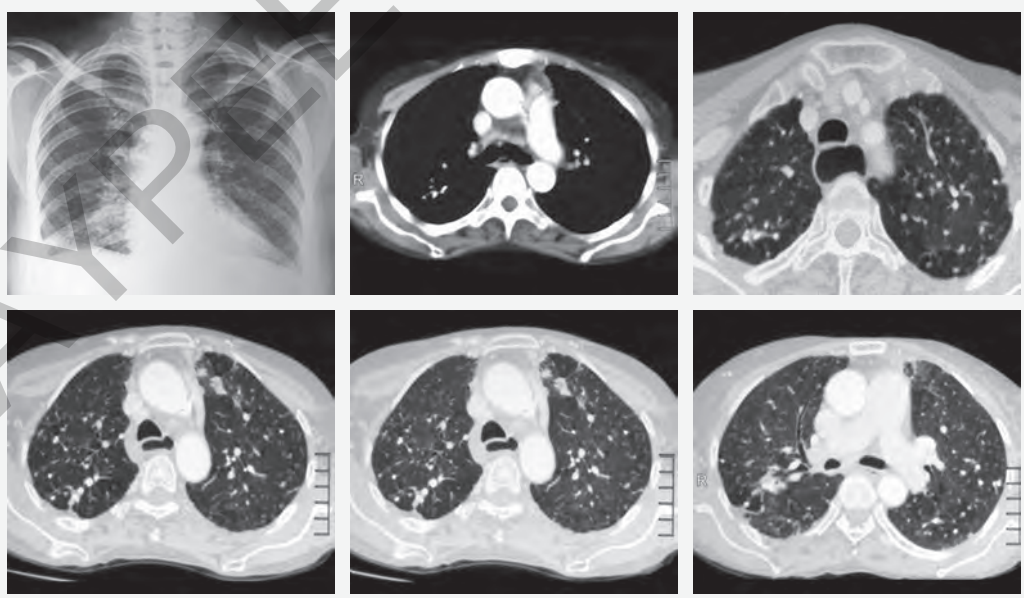

JAYPEE BROTHERS

Pulmonary Function Testing

Moderately severe impairment and moderately diffusion impairment.

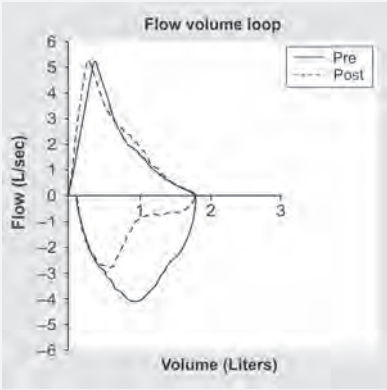

	PRE (percent predicted)	POST (percent predicted)	Percent change
FEV1/FVC (%)	79	80	1
FEV1 (L/s)	1.19 (47)	1.26 (49)	2
FVC (L)	1.5 (50)	1.57 (52)	2
FET (s)	2.51	2.59	
RV (L)	1.22 (79)		
TLC (L)	2.72 (59)		
DLCO	13.05 (55)		
DLCO/VA	6.77	124	

Bronchoscopy

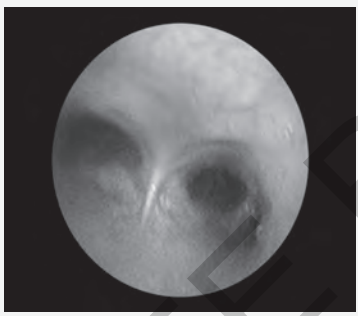

Grossly: Normal *(For color version, see Plate 6)*

Microscopic

- **Bronchial aspirate:** Negative for acid-fast bacillus (AFB), pyogenic, fungus, and atypical cells
- **Transbronchial lung biopsy:** Chronic nonspecific changes
- **Endobronchial biopsy:** Chronic nonspecific changes

Summary

- A 45-year-old female with progressive exertional dyspnea and cough.
- Chest radiology showed basal reticular shadows, right more than left. CT scan showing ground glass opacity, nodularity, interlobular septal thickening with traction bronchiectasis.
- Pulmonary function test showed moderately severe impairment and moderately diffusion impairment.
- Bronchoscopy biopsy showed nonspecific changes negative stains for *Mycobacterium* and fungi.
- Scl-70 was positive.
- 6-minute walk test was positive.

Final Diagnosis

ILD Scleroderma

Management

Steroids started

JAYPEE BROTHERS

CASE 3

Clinical profile

35-year-old non-smoker male

- **History:**
  - Breathlessness for 1 year: Insidious, persistent, progressive, and mMRC grade 2 at presentation
  - Cough for 1 year: Intermittent, dry, no diurnal variation, and no hemoptysis
  - No h/o fever, weight loss, loss of appetite, chest pain, joint pains, dysphagia, dry eyes, or Raynaud's phenomenon
- **Past history:** No h/o DM/HTN/CAD
- **Chest auscultation:** Revealed bilateral vesicular breath sounds with bilateral crepts
  - No significant extrapulmonary abnormality observed

Work up

- **Hemoglobin:** 12.6 g/dL
- **TLC:** 8,040 cells/cmm
- **DLC:** N82/L10/M6/E2
- **Blood urea/S. creatinine:** 23/0.8 mg/dL
- **Induced sputum for AFB:** Negative
- **Mantoux:** 0 mm
- **RA factor, Anti-CCP:** Negative
- **Scl-70:** Positive
- **6MWT:** Distance covered—300 meter with desaturation from 96% to 90%

Radiology

Radiology showing centrilobular nodules with nodule in right lower lobe.

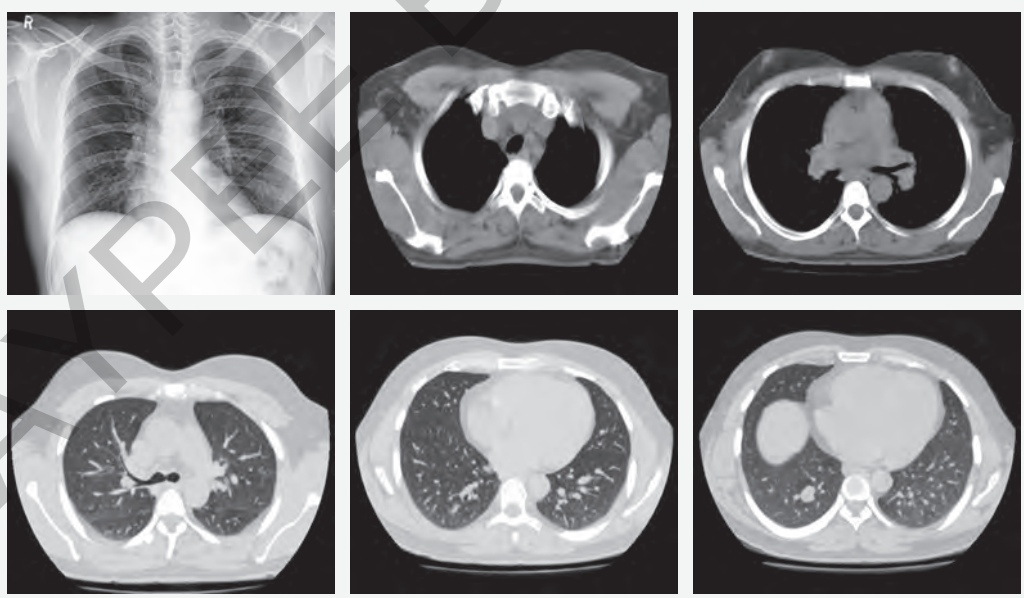

JAYPEE BROTHERS

Pulmonary Function Testing

Spirometry showed mild airflow limitation with significant reversibility.

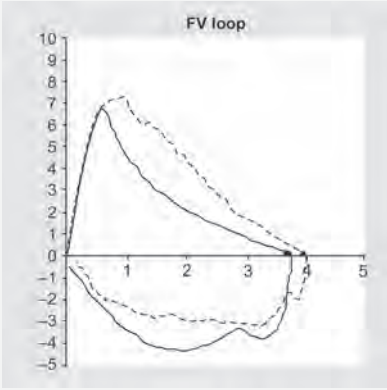

	PRE (percent predicted)	POST (percent predicted)	Percent change
FEV1/FVC (%)	71 (85)	83 (100)	16
FEV1 (L/s)	2.7 (71)	3.35 (88)	24
FVC (L)	3.78 (83)	4.04 (89)	6
FET (s)	8.04	9.02	

Bronchoscopy

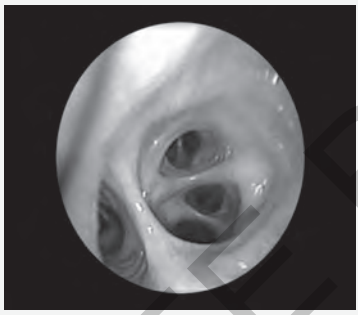

Grossly: Normal ***(For color version, see Plate 6)***

Microscopic

- **Bronchial aspirate:** Negative for acid-fast bacillus (AFB), pyogenic, fungus, and atypical cells
- **Transbronchial lung biopsy:** Nonspecific changes

Summary

- A 35-year-old non-smoker male with progressive exertional dyspnea and dry cough.
- Chest radiology showed centrilobular nodules with nodule in right lower lobe.
- Pulmonary function test showed mild airflow limitation with significant reversibility.
- Bronchoscopy showed nonspecific changes.
- Scl-70 was positive.
- 6-minute walk test was positive.

Final Diagnosis

ILD Scleroderma

Management

Steroids started

JAYPEE BROTHERS

CASE 4

Clinical profile

55-year-old female

- **History:**
  - Cough for 2 years: Persistent
  - Breathlessness: 5 years, exertional, persistent, and grade 2
  - Dysphagia: 2 years
- **Past history:** No h/o DM/hypertension/CAD/ATT
- **Chest auscultation:** Revealed bilateral vesicular breath sounds

Work up

- **Hemoglobin:** 8.9 g/dL
- **TLC:** 6,300 cells/cmm
- **DLC:** N56/L36/M2
- **Sputum for AFB:** Negative
- **RA factor:** Negative
- **ANA:** Positive
- **Scl-70:** Positive

Radiology

Radiology showing bilateral interlobular and interstitial septal thickening, bilateral honeycombing, and traction bronchiectasis.

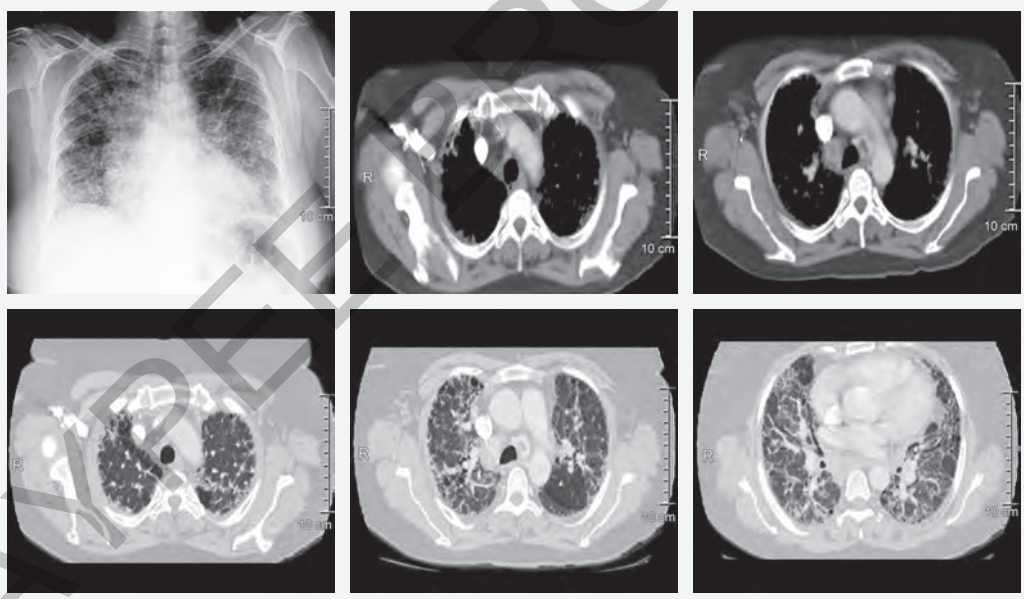

JAYPEE BROTHERS

Pulmonary Function Testing

Pulmonary function test suggestive of restrictive pattern.

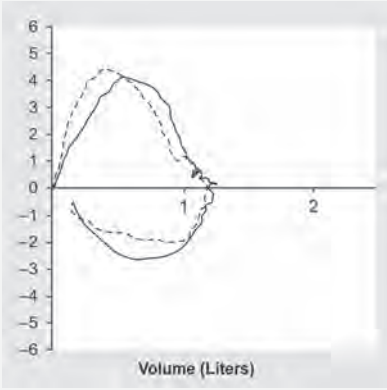

	PRE (percent predicted)	POST (percent predicted)	Percent change
FEV1/FVC (%)	77	82	
FEV1 (L/s)	81	86	
FVC (L)	71	74	
FET (s)			
RV (L)	124		
TLC (L)	112		
DLCO	46		
DLCO/VA			

Bronchoscopy

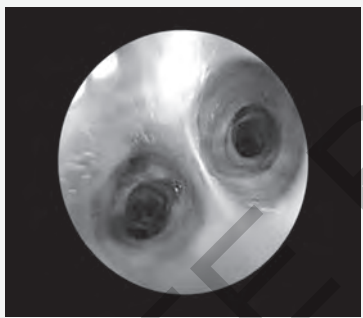

Grossly: Normal *(For color version, see Plate 6)*

Microscopic

- **Bronchial aspirate:** Pyogenic, acid-fast bacillus (AFB), fungus—negative. No atypical cells seen
- **Transbronchial lung biopsy:** Nonspecific changes

Summary

- A 55-year-old female with cough for 2 years and breathlessness for 5 years.
- Chest radiology showed bilateral interlobular and interstitial septal thickening, bilateral honeycombing, and traction bronchiectasis.
- Histological findings was nonspecific.
- Scl-70 was positive.

Final Diagnosis

ILD Scleroderma

Management

Steroids started

JAYPEE BROTHERS

CASE 5

Clinical profile

42-year-old female

- **History:**
  - Cough for 5 years, chronic, persistent, nonproductive
  - Breathlessness for 5 years, chronic, exertional, grade 2
  - Joint pains and myalgia for 5 years
- **Past history:** No history of DM/hypertension/CAD/ATT
- **Chest auscultation:** Revealed bilateral vesicular breath sounds and crepts

Work up

- **Hemoglobin:** 8.5 g/dL
- **TLC:** 7,200 cells/cmm
- **DLC:** N78/L12/M5
- **Sputum for AFB:** Negative

Radiology

Radiology showing bilateral patchy ground glass opacity, with interstitial septal thickening.

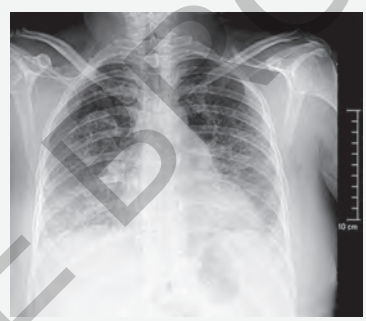

Pulmonary Function Testing

Pulmonary function suggestive of restrictive pattern.

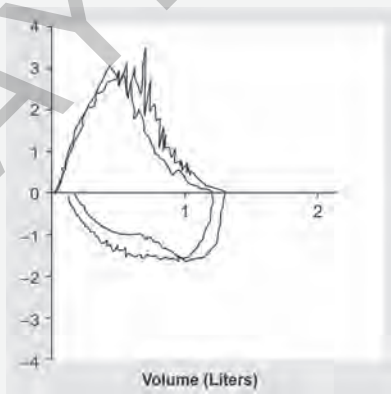

	PRE (percent predicted)	POST (percent predicted)	Percent change
FEV1/FVC (%)	77	90	
FEV1 (L/s)	78	80	
FVC (L)	82	90	
FET (s)			
RV (L)	111		
TLC (L)	87		
DLCO	54		
DLCO/VA			

JAYPEE BROTHERS

Bronchoscopy

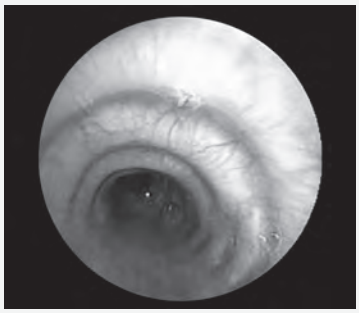

Grossly: Normal *(For color version, see Plate 6)*

Microscopic

- **Bronchial aspirate:** Pyogenic, acid-fast bacillus (AFB), fungus—negative. No malignant cells seen
- **Transbronchial lung biopsy:** Nonspecific changes

Summary

- A 42-year-old female with cough and breathlessness for 5 years.
- Chest radiology showed bilateral patchy ground glass opacity, with interstitial septal thickening.
- Histopathological findings revealed nonspecific changes with negative stains for pyogenic and fungi and AFB.

Final Diagnosis

ILD-CTD

Management

Steroids started

JAYPEE BROTHERS

CASE 6

Clinical profile

46-year-old female

- **History:**
  - Breathlessness for 1 year, persistent, progressive, grade 2
  - Cough for 1 year back for 1 month
  - Myalgia for 1 year
  - Joint pain: Small joint, 2 months
- **Past history:** History of antitubercular treatment (ATT) intake 3 years back for eye complaints, no records available. H/o HTN for 12 years, on Tab Amlodipine 5 mg OD. No h/o DM /CAD
- **Chest auscultation:** Revealed bilateral vesicular breath sounds with crepts

Work up

- **Hemoglobin:** 12.6 g/dL
- **TLC:** 7,000 cells/cmm
- **DLC:** N70/L18/M7
- **Sputum for AFB:** Negative
- **RA factor/anti CCP/Scl-70:** Negative

Radiology

Radiology showing bilateral centrilobular nodules and ground glass opacity.

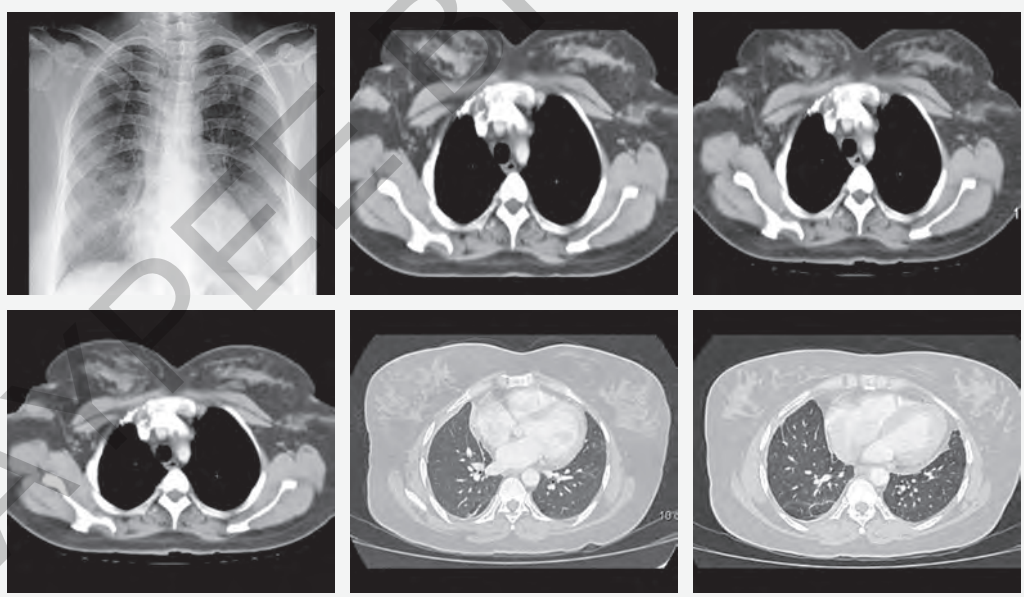

JAYPEE BROTHERS

for detailed information on respiratory medicine books, visit our website www.jaypeebrothers.com, for detailed information on respiratory medicine books, visit o

BRONCHOSCOPY CASES

Salient Features

- This book on Bronchoscopy contains dynamic examples of bronchoscopy cases and final diagnoses
- It comprises of 7 sections with 108 cases, such as Pulmonary Tuberculosis, Sarcoidosis, ILD-CTD, ILD-IPF/NSIP, Hypersensitivity Pneumonitis, Malignancy and miscellaneous cases
- Each case of every section starts with the history and ends-up with management of respiratory disorders
- Patient's clinical profile, past history, microscopic analysis, and case summary are the pearls of each section
- Rich pictorial illustrations of chest radiographic images is the beauty of the book
- Keen practical examination(s) by the author, presented throughout the book
- Important aspects of bronchoscopy is discussed in each and every corner of the book
- This book is a ready reckoner for practicing professionals as well as undergraduates and postgraduate students.

Raj Kumar is working as Director, Vallabhbhai Patel Chest Institute (VPCI), Delhi, a premier research Institute funded by Ministry of Health and Family Welfare, Government of India and maintained by the University of Delhi. He is a renowned pulmonary physician, with nearly 3 decades of illustrious teaching experience to the students in the area of DM/MD/DTCD (Pulmonary Medicine)/PhD. He has contributed vastly to the research activities related to chest and allied diseases, with proven excellence in quality patient care. Dr Kumar has vast administrative experience too.

His contribution has been widely acclaimed all over the country/world in the field of Allergic Bronchopulmonary Aspergillosis, Food Allergy, Respiratory Allergy, Allergy Testing and Immunotherapy, Indoor Air Pollution and Health, Smoking Cessation, Bronchoscopy, Biomass Fuel used and their association with common respiratory diseases Asthma, Lung Cancer, COPD and Tuberculosis and Multidrug resistant Tuberculosis (MDR-TB).

Dr Kumar has published 421 research papers in peer reviewed National and International periodicals. He authored 16 books and 16 abstract books of National and International repute. He has supervised about 33 Research thesis also. Dr Kumar is holding various positions in National/International Academic/Scientific Societies/Associations and has been a recipient of various National and International awards/honours.

Available at all medical bookstores
or buy online at www.jaypeebrothers.com



JAYPEE BROTHERS
Medical Publishers (P) Ltd.
www.jaypeebrothers.com

Join us on facebook.com/JaypeeMedicalPublishers

Shelving Recommendation
MEDICINE

ISBN 978-93-5270-277-0

