website www.jaypeebrothers.com, for detailed information on orthopedic books, visit our website www.jaypeebrothers.com

Recent Advances in ORTHOPEDICS-2

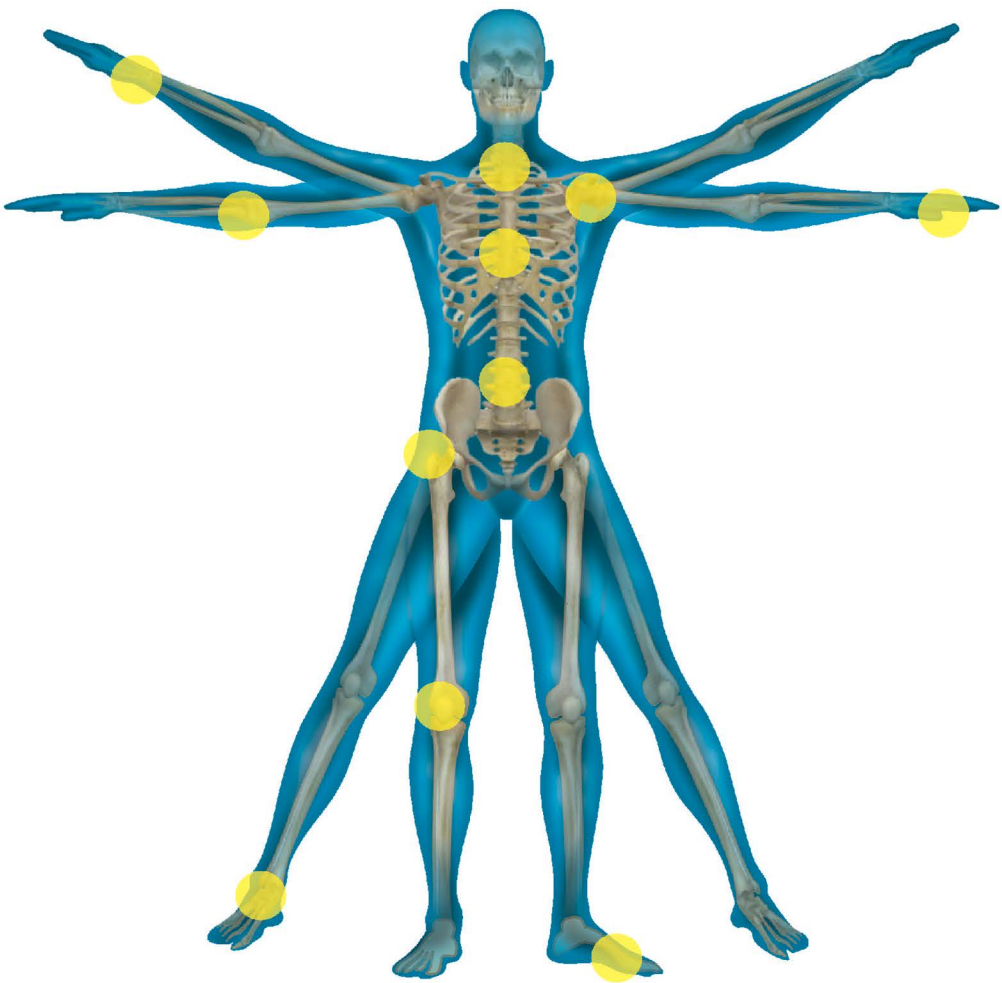

P Maxwell Courtney

JAYPEE

Contents

Chapter 1	What's new in spinal surgery? *Bradley M Anderson, D Greg Anderson*	1
Chapter 2	What's new in hip joint preservation surgery? *Lucas A Anderson, Frank R Avilucea, Christopher E Pelt, Jill A Erickson, Christopher L Peters*	8
Chapter 3	What's new in total hip arthroplasty? *Harlan Levine, Gregg R Klein*	37
Chapter 4	What's new in knee arthroplasty? *Yale A Fillingham, Carl A Deirmengian, Jess H Lonner*	49
Chapter 5	What's new in revision arthroplasty? *Christopher M Melnic, Ryan S Charette, Wayne G Paprosky*	63
Chapter 6	What's new in sports medicine? *Daniel Lim, James Carey*	81
Chapter 7	What's new in shoulder and elbow surgery? *Charles L Getz, Daniel E Davis, J Gabriel Horneff*	89
Chapter 8	What's new in orthopedic trauma? *Gerard Chang, James Krieg*	96
Chapter 9	What's new in hand surgery? *Kevin Lutsky, Asif Ilyas, Jonas Matzon, Pedro Beredjiklian*	113
Chapter 10	What's new in orthopedics: Asian perspective—hip? *Tetsuya Jinno, Toshifumi Watanabe, Kazuyoshi Yagishita*	130
Chapter 11	What's new in orthopedics: Asian perspective—knee? *Toshifumi Watanabe, Kazuyoshi Yagishita, Tetsuya Jinno*	143
Chapter 12	What's new in knee arthroplasty: South American perspective? *David Figueroa, Rafael Martínez, Maria Jesus Tuca, Francisco Figueroa*	150
Chapter 13	What's new in hip arthroplasty: South American perspective? *Claudio Diaz-Ledezma, Ivan Radovic*	162

Chapter 14 What's new in basic orthopedic science? 169
Blair Ashley, Liane Miller
Chapter 15 What's new in pediatric orthopedics? 191
Philip Ashley, Daniel Bouton, Andrew Tice, John S Vorhies, Stephan Zmugg, David A Podeszwa
Index *201*

Chapter 2

What's new in hip joint preservation surgery?

Lucas A Anderson, Frank R Avilucea, Christopher E Pelt, Jill A Erickson, Christopher L Peters

INTRODUCTION

Over the course of the last two decades, there has been a rapidly expanding understanding of the spectrum of hip pathomorphology and the surgical treatment thereof. In addition to open surgical options, advances in arthroscopic skill and techniques have expanded the surgeon population attempting to understand and manage these disorders. In this review, we provide an update on recent evidence and clinical implications of hip preservation surgery for the management of young adult hip pathomorphology including hip dysplasia, intra-articular and extra-articular hip impingement, as well as the sequelae of pediatric hip disease.

DYSPLASIA

Since its introduction more than 20 years ago,[1] the Bernese periacetabular osteotomy (PAO) has been adopted as the preferred contemporary surgical treatment in adults with symptomatic hip dysplasia. Advantages of this osteotomy include the following: The, blood supply to the articular fragment is maintained; the posterior column is left intact providing initial construct stability, early patient mobilization and healing. The technique enables acetabular reorientation such that both anterior and lateral coverage can be achieved. Additionally, the operation allows for correction of acetabular version; either antevert or retrovert the acetabulum as patient morphology necessitates (increasing anterior coverage in classic dysplasia and reducing anterior coverage in retroverted hips).[2-4]

The surgical goals of PAO include pain relief, improved function and quality of life, and preventing or delaying secondary development of osteoarthritis (OA) that may necessitate total hip arthroplasty (THA). To date, there is global acceptance and application of PAO as evidenced by a nearly fourfold increase in the number of operations completed in the adult population since 2005.[5] Biomechanically, there is evidence that PAO, by normalizing acetabular coverage, may decrease contact stress and reduce stress on the labrum, which may delay the onset of hip OA.[6,7] Abraham et al.[6] and Knight et al.[7] emphasize the need for longer follow-up using biomechanical analyses to better understand the role of PAO in preventing OA.

A number of studies have reported acceptable survival at mid- and long-term clinical follow-up. Matheney et al.[8] reported the intermediate to long-term results of 135 hips, 17 hips were converted to THA, with a survivorship of 96% at 5 years and 84% at 10 years. Similarly, Troelsen et al.[9] hip joint survival rates of 81.6% at 9.2 years. They noted several negative predictive factors including age greater than 45 years, preoperative center edge angle

JAYPEE BROTHERS

(CEA) less than 0°, postoperative CEA less than 30° or greater than 40°, pre- or postoperative joint space less than 3 mm, preoperative Tönnis OA grade greater than or equal to 2, and preoperative os acetabuli. Steppacher et al.[10] reported the long-term results of 68 hips followed for a minimum of 19 years. At 20 years, there was a one-grade difference in Tönnis grade of OA, a 60.5% hip survival rate, and consistently good patient report evaluations. Interestingly, hips with a low preoperative (0 or 1) Tönnis grade had a survivorship of 75%, whereas a higher score (2 or 3) had a survivorship of only 13%. Using comparative statistical approaches, several factors have been identified to predict a poor outcome: age above 30 at surgery, patients with preoperative Merle d'Aubigné and Postel scores of 14 or less, and those with preoperative OA grade of 2 or more. In addition to conventional radiographic studies to assess grade of OA, Cunningham et al.[11] found the dGEMRIC (delayed gadolinium-enhanced magnetic resonance image of cartilage) index, used to detect early OA, to be the most important predictor of failure of PAO surgery. Their follow-up study showed that anterior dome cartilage was the most important factor in survivorship.[12]

Most recently, Lerch et al.[13] looked at the initial 75 hips treated with PAO for classic acetabular dysplasia from 1984 to 1987. They found at 30-year follow-up that one-third of hips had good clinical results, no progression of OA, and survived without need for THA. Conversely, two-third of hips ended up with progression of symptoms, OA, and eventual THA. Negative prognostic indicators included age at surgery more than 40 years, preoperative impingement signs or limited range of motion (specifically IR < 20), Tönnis grade greater than 1, postoperative acetabular retroversion, and low preoperative PROs.

Sharifi et al.[14] recently performed a cost-analysis study based upon the above clinical survivorship data, and argued that PAO is more cost-effective than THA, if hips survived more than 18 years and primary THA was more cost-effective than PAO, if hips had Tönnis grade 2 or greater OA.

Addressing intra-articular pathology at the time of periacetabular osteotomy

Periacetabular osteotomy reestablishes the normal acetabular coverage of the femoral head. The reorientation of the acetabulum, however, may create iatrogenic femoroacetabular impingement (FAI), especially in the presence of a cam-type deformity.[15,16] Additionally, existing chondrolabral lesions can cause symptoms that mitigate the clinical success of PAO. As such, arthrotomy during PAO or arthroscopy simultaneously, before, or after PAO for intra-articular inspection and chondrolabral lesion treatment is being utilized by many surgeons.

Several studies address not only the degree of intra-articular pathology seen at the time of PAO, but inquire whether intra-articular inspection and treatment of identified pathology results in an difference in outcome.[17,18] Ginnetti et al.[19] reported on a retrospective series of 151 patients who underwent PAO and hip arthrotomy and compared the outcome to 39 patients who underwent PAO alone. Labral lesions were found in 20% of hips and loose bodies in 5%. Additionally, 85% had a decreased head-neck offset that was corrected with femoral osteochondroplasty but it was less well, understood whether this would negatively affect survivorship or symptomatology. More recently, several reports advocating less invasive surgical approaches without intra-articular inspection have shown excellent short- to mid-term results (Peters RS papers X2 and Soballe, Witt papers).[20-23] In contrast, there are also several recent reports on simultaneous or staged PAO and hip arthroscopy to correct

JAYPEE BROTHERS

intra-articular pathology, which also demonstrate excellent short- to mid-term outcomes.[17,18,24] Thus, in 2017 there are differing approaches being employed to the issue of intra-articular pathology at the time of PAO with no clear evidence of superiority.

Periacetabular osteotomy for acetabular retroversion

Patients with significant acetabular retroversion often have anterior overcoverage and deficient posterior wall coverage that leads to the cross-over sign that is tempting to resolve through resecting anterior acetabular bone and cartilage through arthroscopic or open surgeries. The PAO allows reorientation of the acetabular surface relative to the femoral head relieving abnormal anterior impingement and restoring normal posterior coverage. Siebenrock et al.[16] reported on a series of 29 hips (22 patients) that underwent an anteversion-producing PAO. At a minimum follow-up of 2 years, 26 of 29 hips had a good or excellent result. Peters et al.[2] reported the results of reverse PAO for acetabular retroversion in 30 patients and found significantly improved clinical outcomes [based on Harris hip scores (HHS)] and 28 of 30 hips had a good or excellent result. The Berne group analyzed their treatment of hips with symptomatic acetabular retroversion.[4] They report on 67 hips treated with PAO and 57 hips treated with rim trimming via surgical dislocation and found no difference in survivorship at 5 years, but a significant difference at 10 years (79% vs 23%).

Borderline dysplasia and the role of arthroscopy

In the setting of borderline dysplasia (CEA 20°–25°), the labrum may hypertrophy in response to increased load and subsequently assume a more important role as a weight-bearing surface in addition to a greater role in joint stability. Decreasing acetabular coverage leads to greater joint reaction forces imparted on the labrum, raising the risk for developing labral tears, degeneration, and detachment. Additionally, the reduced acetabular articular surface results in increased contact pressure, which may result in articular cartilage degeneration.

An early series by Byrd et al.[25] included a series of 48 hips that underwent hip arthroscopy for symptomatic dysplasia or borderline dysplasia with a minimum of 1-year follow-up (12–60 months, mean 27 months), there was an improvement of 27 points on a modified HHS with no difference noted in outcomes in dysplastic versus borderline dysplastic hips. Hips with OA did worst (two underwent THA), and hips with focal full thickness chondral injuries did mediocre. Chandrasekaran et al. (2017)[26] reported on 55 cases of mild hip dysplasia (CEA 18–25°) who underwent capsular plication and labral repair of which 84% had good to excellent results and 89% required no further surgery at a minimum of 2-year follow-up.

Despite some reports demonstrating favorable outcomes with arthroscopic intervention, there is concern as cases of accelerated arthritis[27,28] and instability[29] have been reported following arthroscopic labral debridement. Cvetanovich et al.[30] reported on arthroscopic treatment of FAI hips with borderline DDH (LCEA 18–25°) and compared them to a matched group of normal acetabular hips with FAI and found no difference at minimum 2 years follow-up in HOS-ADL or percentage of patients seeing clinical improvement or requiring subsequent surgery.

While PAO remains the optimal treatment for acetabular dysplasia, debate remains in the literature regarding the appropriate intervention for the borderline dysplastic hip with intra-articular pathology, such as a labral tear. From a patient point-of-view, hip arthroscopy may seem preferable to the invasive description of the PAO. However, a recent study of patients who had undergone a prior hip arthroscopy compared head to head dysplastic hips treated solely with PAO versus hips treated with hip scope and subsequent PAO found that at

JAYPEE BROTHERS

1 year there was a statistically significant difference in mHHS, hip outcome score (HOS), and international hip outcome tool (iHOT) scores.[31]

The role of arthroscopic intervention may, at this time, play a larger role in staging borderline hip dysplasia prior to osteotomy. Fujii et al.[17] reported on an observational study in 121 patients (121 hips) who underwent PAO and combined arthroscopy at the index procedure. Arthroscopic findings of exposed subchondral bone and full-thickness labral tears, particularly at the anterosuperior portion of the acetabulum, and pre- and postoperative joint incongruity were strongly correlated to OA progression and unsatisfactory clinical scores at a mean follow-up of 9.9 years.

FEMOROACETABULAR IMPINGEMENT

Femoroacetabular impingement can be found in a number of patterns: cam, pincer, and mixed cam-pincer type FAI. Other unusual sources of intra-articular impingement may also be found (psoas tendon or ligamentum teres), and more recently emphasis has also been placed on identification and treatment of extra-articular sources of symptomatic impingement.

INTRA-ARTICULAR FEMOROACETABULAR IMPINGEMENT

Classic FAI is an osseous pathomorphologic variant predisposing the joint to potentially symptomatic intra-articular pathology, specifically labral tears and chondral lesions that lead to early hip arthritis and need for THA.[32] In cam-type FAI, impingement most commonly occurs with hip flexion and internal rotation when an aspherical portion of the femoral head enters the acetabulum causing increased shear forces to the acetabular chondrolabral margin (**Figures 2.1 and 2.2**).[33] The impingement often occurs at the anterolateral acetabulum and frequently spares the capsular margin of labrum until late in the disease process. Cam-type FAI has been shown to produce a characteristic chondral injury, hyaline cartilage delamination, at the area of impingement, which can adversely affect surgical treatment outcome and complicate surgical decision making.[34]



Figure 2.1 The right lateral radiograph shows a significantly decreased femoral-head neck offset and presence of calcified labrum, findings consistent with cam-type femoroacetabular impingement.

JAYPEE BROTHERS



Figure 2.2 Lateral of the hip following surgical dislocation to increase the head-neck offset and treat the intra-articular pathology.



Figure 2.3 Anteroposterior pelvic radiograph demonstrating a posterior wall sign of the left hip and a significantly increased lateral center edge angle measured greater than 40°. These are common findings seen in pincer-type femoroacetabular impingement.

Pincer-type FAI is an acetabular-based pathomorphology where the acetabular rim and labrum impact the femoral neck or head-neck junction (**Figure 2.3**). This impingement mechanism may lead to labral attenuation, gradual ossification, and over time, the potential for posterior joint damage (contrecoup injury pattern) due to shear forces as the hip levers at the anterior neck-rim contact.[33] Pincer-type FAI can arise from acetabular retroversion, focal or global acetabular overcoverage. Pincer-type FAI is often radiographically characterized by findings consistent with acetabular retroversion (crossover sign, a posterior wall sign, an ischial spine sign) and acetabular overcoverage (LCEA > 40°, negative acetabular index, and acetabular protrusio). While coxa profunda (defined as medial acetabular fossa in contact or projecting medial to the ilioischial line) was often considered diagnostic of pincer FAI, several recent studies show that it is both a common and nonspecific finding.[35,36]

JAYPEE BROTHERS

Often hips have components of both cam- and pincer-type FAI, which has been termed mixed type FAI. The pincer component combined with the cam lesion can lead to earlier impingement with intra-articular shear forces consistent with cam FAI. This can lead to an array of chondrolabral injuries including labral tears, labral detachments, and acetabular delamination.[33,34] Typically, femoral articular cartilage is preserved until very late in the disease process.

Counter-intuitively, cam-like femoral deformities can occur in the setting of acetabular dysplasia (**Figure 2.4**). The deformity is often a relative lack of femoral head-neck offset more than an aspherical overgrowth of the physis and it is unclear whether the femoral morphology is a contributor to joint dysfunction in the setting of acetabular dysplasia.[33,37] However, at least two observations of recent treatment trends may be noted. First, isolated treatment of the femoral head-neck offset deformity in the setting of dysplasia may result in inferior surgical outcomes, likely exacerbating a tendency toward instability, particularly if the labrum is resected.[28,38] Second, definitive treatment of acetabular dysplasia via PAO may create the potential for subsequent impingement due to reorientation of the acetabulum into a position of impingement with preexisting decreased head-neck offset.[15,19,32] In fact, inadvertently retroverting the acetabulum was identified by Ganz et al.[32] as a common cause of PAO failure and lead to the diagnosis and early understanding of FAI.

Open treatment of femoroacetabular impingement

The understanding of FAI evolved from treatment of dysplasia and a growing understanding of young hip pathology, including Perthes and SCFE (slipped capital femoral epiphysis) (retroversion, FAI).[39-42] This understanding highlights the need for a surgical intervention to address not only intra-articular lesions, but also correct the underlying deformity which was leading to pathologic impingement.[32] Open surgical dislocation and osteochondroplasty (SDO) was initially reported by Ganz et al.[43] SDSDO revolutionized treatment and understanding of FAI, and has proved workhorse for the treatment of FAI and its more dramatic causes including SCFE and Perthes.[44,45]

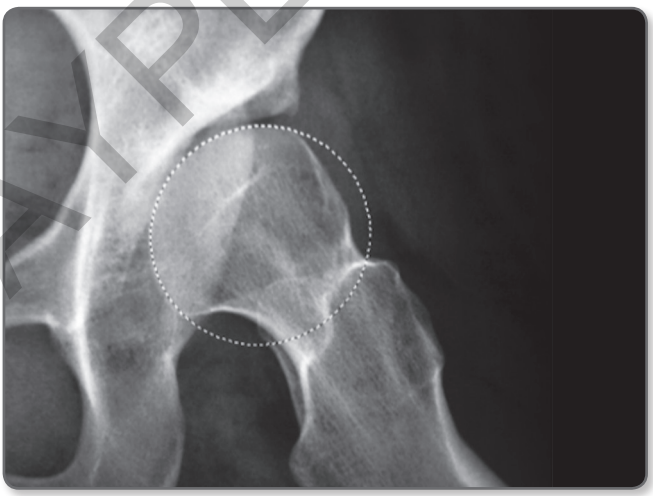

Figure 2.4 Frog-leg lateral radiograph of the left hip showing lack of femoral head-neck offset consistent with cam-type femoroacetabular impingement in the setting of an upward sloping sourcil consistent with concomitant acetabular dysplasia.

JAYPEE BROTHERS

Regarding SDO outcomes, Beck et al.[44] reported in 2004, good to excellent results in 13 of 19 hips seen with a mean follow-up of 4.7 years; a Tönnis grade of 2 or greater was associated with increased risk of failure. Peters et al.[46] reported improved HHS of 27 points with a mean 13.3% rate of conversion to THA HHS in 30 hips treated with surgical dislocation at a mean follow-up of 2.7 years. A systematic review by Botser et al.[47] reports a mean HHS improvement of 20 points with a mean follow-up of 2.5 years. Risk of failure 10 years after surgery for FAI includes presence of acetabular rim cysts, cartilage damage greater than 60°, sabertooth osteophyte off superior acetabular fossa.[48] Known complications include trochanteric nonunion and trochanteric fixation failure but minimal risk of avascular necrosis (AVN) with good technique.[43,46,47] That said, the invasiveness of this procedure requires prolonged rehabilitation compared to arthroscopic intervention.[48,49] Numerous studies that have addressed clinical outcomes following various treatments of FAI.[44,46,50-54]

A less invasive open Hueter approach to improvement of anterior head-neck offset and labral repair has been utilized by a number of centers.[55,56]

There is even new evidence that early degenerative changes of the hip can be reversed with adequate treatment of the bony pathomorphology of FAI. Beaule et al.[57] looked at high resolution MRI to evaluate proteoglycan levels in cartilage and bone density changes on CT before and after FAI surgery for CAM FAI in 10 male patients. They found favorable reversal of negative changes both of sclerotic acetabulum and improvement in hyaline cartilage characteristics in the anterosuperior quadrant on follow-up imaging at a mean 24.5 months.

Labral refixation versus debridement

Early series out of Switzerland reported better outcomes with refixation of the labrum compared to resection.[58] Larsen et al.[59] noted good to excellent results in 68% of the focal debridement group and 92% of the refixation group at a mean 3.5 year follow-up. Despite reports to the contrary, the labrum does not appear to regenerate after excision and hips after excision have inferior results compared to hips that underwent labral repair or reconstruction.[60] In cadavers, labral seal affect to the hip is best restored by repair over resection or reconstruction.[61,62]

Labral reconstruction

Labral reconstruction using allograft or autograft tissue, iliotibial band,[63] allograft tendon/tissue,[64] indirect head of rectus tendon,[65] and even capsular advancement to the rim[66] have all been described with varying degrees of clinical follow-up and success. From both a biomechanical and clinical perspective, best results at recreating normal mechanics and preserving hip function and longevity is permitted by retaining as much labrum as possible and reconstructing the deficient labrum.[61,67-69] How much labrum is sufficient for labral seal and optimized hip function and when to reconstruct the labrum is a question to be answered by future studies.

Chondral lesion patterns

Chondral lesions of the hip were historically graded using the Outerbridge Classification System borrowed from sports medicine for the grading of knee chondromalacia from 0 to IV: 0 is normal cartilage, grade I is softening, grade II is superficial fraying, III is partial thickness loss, and grade IV is areas of full loss down to bone.[70] Beck et al.[33] proposed a now well-

JAYPEE BROTHERS

accepted grading scale for acetabular articular cartilage involvement: Beck score: 1, normal cartilage; 2, softening or malacia; 3, debonding or carpet lesions; 4, cleavage/flap lesions with free edge; 5, full thickness defect. The location of involvement is described using a clock face description with 3 o'clock always being anterior regardless of right or left hip. Lesions are described based on their location on a clock face and distance from the rim that the lesion extends. Additionally, Beck et al.[33] classified labral involvement: Beck score: 1, normal labrum; 2, degeneration, thinning or frayed labrum; 3, full-thickness tearing of labrum; 4, labral detachment; 5, labral ossification. These were used with the clock face to describe location and extent of labral lesions.

CHONDRAL TREATMENT OPTIONS

Debridement and microfracture

Unstable cartilage cannot heal autonomously and so careful cartilage probing and examination is required to locate these lesions. The goal of debridement of chondral lesions is to eliminate unstable cartilage that will progress to loose bodies or instability of adjacent cartilage while preserving stable cartilage.[71] Using larger shavers and shavers of various angles avoid gouging the cartilage or clogging the shaver tip.

The goal of microfracture in the treatment of cartilage lesions of the hip is to perforate the cortical bone at the base of the lesion to permit undifferentiated mesenchymal stem cells (MSCs) and growth factors that fill the defect with fibrocartilage, a reparative cartilage of inferior biomechanical quality to hyaline cartilage. Ideally, the lesion should be focal and contained so that the bleeding bone can form a chondrogenic clot and not larger than 4 cm^2.[72] As the lesions are often at the rim and associated with labral tears, it may be necessary to repair the labrum as well to help "contain" the cartilage rim lesion. The advantage of microfracture or drilling is that they are inexpensive, efficient, and technically simple, requires only one surgery and requires no special preoperative planning. The surgeon must first debride the lesion of loose or frayed cartilage and create a stable border with a shaver or ring curette. Then the lesion base needs to be curetted of the calcified cartilage layer. Finally, the bone awl is used to perforate the bone deep enough to breach the cortex, typically 4 mm depth. The perforations are spaced 3–4 mm apart across the entire lesion including immediately adjacent to the stable cartilage/lesion border. Given the tight anatomy of the hip, various portals and lesion locations, a variety of hip-specific awls may be necessary to create vertical awl penetration without skiving. Additionally, there is some evidence that drilling causes less distortion and damage to the subchondral plate than microfracture with an awl.[73] Specially developed arthroscopic drill bits and guides are now available to drill perpendicular to the bone.

When there is an acetabular rim hyaline cartilage delamination lesion adjacent to a labral tear, microfracturing under the chondral flap and then using fibrin glue to fix it down can be combined with the repair of the labrum.[71] This leads to MSCs being held beneath the flap and promotes healing of the flap down to subchondral bone. When there is delamination adjacent to an intact labrum with no chondrolabral separation there are two options: (1) the labrum can be sharply freed up from the rim, so as to microfracture under cartilage before repairing the labrum back to bone; and (2) the other option is to microfracture through the chondral flap while leaving the labrum undisturbed.

One of the earliest studies on microfracture for acetabular high-grade cartilage lesions was published by Philippon et al.[74] which demonstrated good filling of lesions by fibrocartilage

JAYPEE BROTHERS

but no clinical results. Eleven out of 12 studies showed good results after microfracture of chondral lesions in 267 patients undergoing arthroscopy for FAI in a systematic review by MacDonald et al.[75] All publications used focal high-grade lesions as the indication for microfracture and limited weight bearing after surgery for some period, usually 4–8 weeks.

Resection and labral advancement

Espinosa et al.[58] and Anderson et al.[76] have both described resection with labral advancement of high-grade rim lesions and report favorable outcomes. The negative of this technique is the risk of iatrogenic acetabular dysplasia and need for resultant PAO. Anderson/Parvizi/Peters et al. could not determine difference in clinical and radiographic outcomes between microfracture, debridement, or resection/labral advancement for high-grade rim lesions.[77]

Allograft/autograft: acetabular and femoral osteochondral transplantation

Osteochondral grafts have the advantage of providing high-quality hyaline cartilage firmly attached to a bony carrier that osteointegrates with host bone. The negatives are surgical exposure difficulties for perpendicular insertion and limited weight bearing required for ingrowth and graft protection. Antegrade grafts are challenging due to exposure and angle of insertion issues. Surgical dislocation permits 360° exposure for visualization and instrumentation of the femoral head and acetabulum. Earlier studies have worked to map chondral surface thickness for potential donor site and recipient site requirements.[78] Antegrade femoral osteochondral allograft/autograft transplantation have been described with encouraging results for both traumatic lesions and for osteochondritis dissecans (OCD) lesions in a Perthes hip using graft from the knee.[79-81] Osteochondral autografts taken from the femoral osteochondroplasty/head[79-81] debulking have been used to treat OCD lesions in Perthes hips, similar if not better outcomes than Perthes hips without OCD lesions at a mean follow-up of 45 months.[82] Bastian and associates[83] described successful outcome at 2 years after harvesting autograft from the inferior head in a case of a superior femoral head impaction fracture. Khanna et al.[84] report on a series of patients that had femoral head allografts placed using SDO. The reviewed 17 patients who were diagnosed with OCD (n = 8), AVN (n = 6), Perthes (n = 2), and one with a femoral head fracture. Thirteen patients were considered to have fair to good outcomes, and four were either converted to THA or awaiting THA. Finally, Cetinkaya et al.[85] described a retrograde technique using arthroscopy and fluoroscopy to guide tunnel placement and retrograde insertion of the plug in two cases. They reported good short- and mid-term outcomes, both clinically and radiographically.

Biological treatments and technology

A number of treatments involve harnessing biological technology to encourage chondral healing in full thickness chondral lesions. Most of these were first utilized in the knee before recently being borrowed for hip pathology and so most have limited data in the hip literature on outcomes.

Stem cells or MSCs augmentation can enhance the healing and quality of the reparative cartilage.[86,87] Bone marrow aspiration concentrate (BMAC) can be harvested and injected into the joint through a needle as an outpatient procedure 6 weeks after a microfracture treatment to augment the biologics of the microfracture healing process and quality of repair cartilage.

JAYPEE BROTHERS

Autologous matrix-induced chondroplasty (AMIC) is a single surgery procedure that combines microfracture with application of a porous resorbable type I and III collagen matrix over the defect.[71] This traps the microfracture-induced MSCs within the defect and provides a porous membrane to facilitate stable growth of a cartilage-like tissue. The membrane is held in place by creating a sharp border to the chondral defect and from the pressure of the femoral head; otherwise, the addition of fibrin glue can be helpful for membrane fixation.

Microfragmented adipose tissue transplantation (MATT) with or without microfracture has been suggested as an ideal treatment for delamination lesions.[71,88] The advantage of microfracture and MATT is that it requires only one surgical intervention and is readily available without preoperative planning. Jannelli and Fontana[71] report that adipose tissue is chondrogenic, a source of large quantity MSCs comparable to bone marrow aspirate but less invasive and requires simpler preparation. Further, they suggest that when a delamination lesion is noted, adipose tissue from the lateral thigh can be harvested through one of the arthroscopic portals and then washed with saline before injecting below the delamination lesion or into the joint with a needle at the end of the arthroscopy procedure.

Matrix-induced autologous chondrocyte implantation (MACI) is a two-stage surgical procedure that first requires biopsy of chondrocytes from the hip or removal of unstable cartilage fragments at time of initial diagnostic scope and chondral debridement.[71] The chondrocytes are then cultured on a matrix that functions as a scaffold and then the matrix, or membrane, is implanted over the defect during a second surgery.[88] Protein and carbohydrate matrices and artificial polymers have all been proposed as the membrane of choice.[71] As confidence in imaging grows and biologic treatment becomes mainstream one can imagine diagnosing a lesion on MRI and deciding to harvest cartilage form an unaffected joint, such as the knee.

Matrix-associated stem cell transplantation (MAST) is similar to MACI in that it is a two-step process that is laboratory intensive. However, instead of using chondrocytes, MAST cultures stem cells, which can be harvested without biopsing cartilage.[88] Stem cells are cultured in a monolayer for 4 weeks, transferred to a matrix in an undifferentiated medium for a week, then spend 3 more weeks in a chondrogenic medium before the matrix is arthroscopically placed over the chondral defect. This has been clinically successful at 2-year follow-up with complete defect filling and integration with native cartilage in a series of patients.[88]

Comparing chondral treatment results

There are limited studies in the literature comparing outcomes between treatments for chondral lesions in the hip. Domb et al.[89] compared outcomes of FAI patients with chondral lesions treated with and without microfracture after a minimum follow-up period of 2 years. All patients significantly improved but no significant difference between groups was noted. Comparing 5 year results of microfracture versus AMIC treatments for full thickness acetabular lesions, Fontana et al.[90] reported that both did equally well at a year but while results deteriorated in the microfracture group they were stable in the AMIC group over the following 4 years. Similarly, Fontana also noted improvement up to 3 years after AMIC for grade iii and iv acetabular lesions in 201 hips with sustained 40-point improvement in HHS at a mean follow-up of 5 years.[91] When comparing AMIC to MACI, Fontana found similar results with medium sized lesions but noted the benefit of one surgery with AMIC over the two stage MACI.[92] Other groups have reported similar outcomes.[93]

JAYPEE BROTHERS

Chondral treatment algorithm

Jannelli and Fontana[71] proposed a treatment algorithm based on their experience and current outcomes studies (**Flowcharts 2.1 and 2.2**).[71] They recommended debridement of partial thickness lesions, microfracture with near full chondral thickness lesions but small in diameter (less than 2 cm^2). MACI or autologous chondrocyte implantation matrix-induced chondrogenesis (AMIC) were recommended for full thickness lesions greater than 2 cm^2. Microfragmented adipose tissue transplantation (MATT) or microfracture with chondrolabral refixation and fibrin glue was suggested for delamination lesions. The advantage of microfracture, AMIC, and MATT is one surgical intervention while MACI and MAST require harvesting chondrocytes and stem cells, respectively, and culturing them for a future reimplantation. Furthermore, Jannelli and Fontana[71] cautioned that addressing pathomorphology that caused the cartilage lesions, such as cam lesions, was necessary for success. Finally, they discouraged chondral treatment in Tönnis grades 2 or greater due to high failure rates.

Future technology and advancements in chondral repair undoubtedly are on the horizon. Unfortunately, it will take years and large well-designed studies to know what patient and chondral lesion factors will lead to the optimal treatment and outcomes.

Open versus arthroscopic treatment of femoroacetabular impingement

Early hip arthroscopy was utilized to debride the labrum and remove loose bodies but in many cases was less effective at addressing bony pathomorphology (cam and pincer lesions) that were leading to the chondrolabral pathology.[28] When analyzing arthroscopic failures, Haefeli et al.[94] noted that a pathologically increased LCEA preoperatively and an inadequately restored femoral head/neck offset correlated to clinical and radiographic failure of hip preservation surgery while treatment of the labral pathology did not correlate with clinical results. Globally overcovered hips improved but not as much as cam-type FAI hips by hip arthroscopy in a series by Chandrasekaran et al.[95] As the understanding of FAI increased, the technical skills of hip arthroscopists expanded to address the bony pathology as well. Soon there was evidence that arthroscopy could restore head-neck

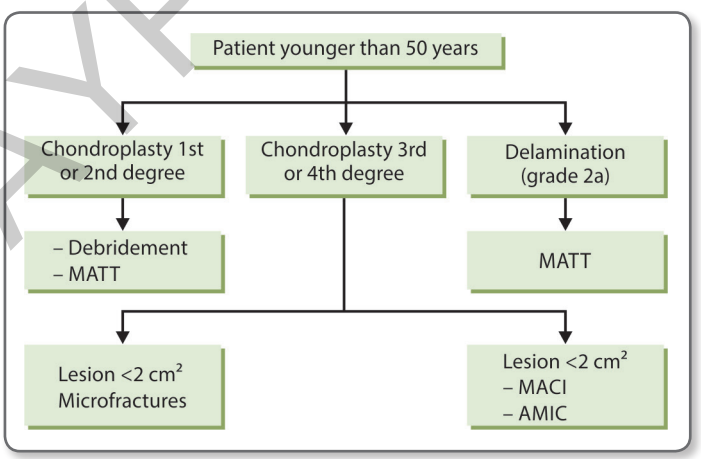

Flowchart 2.1 A decision tree developed by Jannelli and Fontana to assist in the treatment of choice for chondral lesions in patients younger than 50 years.
Source: Reprinted with permission from Jannelli E, Fontana A. Arthroscopic treatment of chondral defects in the hip: AMIC, MACI, microfragmented adipose tissue transplantation (MATT) and other options. SICOT J. 2017;3:43.

JAYPEE BROTHERS

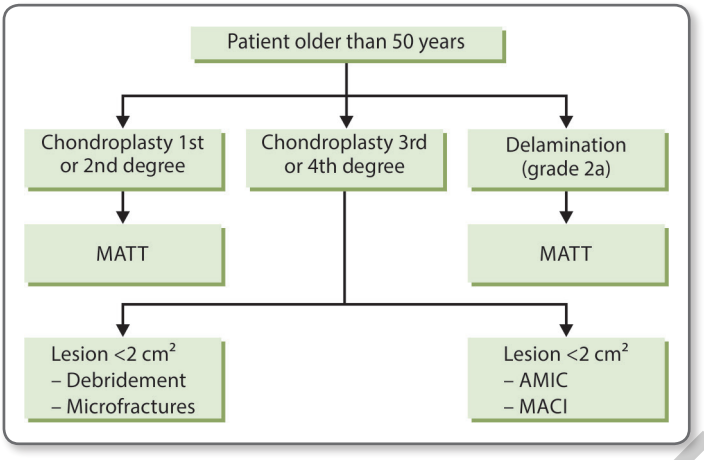

Flowchart 2.2 A decision tree developed by Jannelli and Fontana to assist in the treatment of choice for chondral lesions in patients older than 50 years. *Source:* Reprinted with permission from Jannelli E, Fontana A. Arthroscopic treatment of chondral defects in the hip: AMIC, MACI2, microfragmented adipose tissue transplantation (MATT) and other options. SICOT J. 2017;3:43.

offset in a cam lesion similar to open techniques as well as address resect pincer lesions of the acetabular rim.[47,96,97] Early outcomes of arthroscopic treatment of FAI report 67–90% success rates.[98,99] Numerous retrospective studies have been completed in an effort to identify factors associated with improved clinical outcome. Acetabular rim trimming and labral repair provide good to excellent results in 90% of cases,[59,100] labral debridement and treatment of bony impingement resulted in good to excellent results in 83% of cases,[101] and treatment of bony deformity improves HHS and decreases the rate of early failure.[102] Technical advances enabled an expansion of applications, including the treatment of injuries to the ligamentum teres, capsular laxity, and numerous extra-articular pathologies.

Complications related to arthroscopic intervention have been noted, including heterotopic ossification and lateral femoral cutaneous neuropraxia.[47] Iatrogenic hip microinstability or even macroinstability leading to hip dislocation has also been seen following hip arthroscopy.[29,103-105]

Due to the various advantages of hip arthroscopy, including a potentially accelerated recovery compared to open surgery, the prevalence of arthroscopic surgery for FAI has quickly become the predominant surgical modality over the last decade, a surgical trend noted to increase 18-fold among American Board of Orthopaedic Surgery candidates.[106]

Capsular laxity, deficiency, repair, and reconstruction

While failure of early hip arthroscopy was often due to failure to treat the bony deformity of cam lesions over the last 15 years, knowledge of associated pathomorphology and arthroscopic techniques to address these pathologies have improved. A less common complication has become apparent with respect to hip arthroscopy; capsular instability. As larger bony deformities and labral reconstructions were undertaken, larger capsular portals were required. Interportal capsulotomy and later T capsulotomy became the workhorses of hip arthroscopy, enabling the surgeon to debride larger cam lesion and even reconstruct a labrum from gracilis graft. These larger portals were often re-approximated as an afterthought with several stitches that may or not heal completely. Reports of hip dislocations following hip arthroscopy when initially reported was dramatic but by many considered an anomaly in an otherwise minimally invasive surgical movement.[29,104] However, over time it became clear

JAYPEE BROTHERS

for detailed information on orthopedic books, visit our website www.jaypeebrothers.com, for detailed information on orthope

Recent Advances in ORTHOPEDICS-2

Salient Features

- Up-to-date information on the 'hot topics' of orthopedic surgery from renowned surgeons
- What's new in orthopedics around the world? Contributions from South America and Asia written by internationally recognized authors
- More in-depth discussion of current debates in each subspecialty including minimally invasive approaches to the spine, developments in cartilage basic science and surgical techniques in joint preservation
- New chapter on revision arthroplasty
- Each chapter has been updated from the last edition with new topics and information with over 50 images and illustrations.

Available at all medical bookstores or buy online at www.jaypeebrothers.com

JAYPEE BROTHERS
Medical Publishers (P) Ltd.
www.jaypeebrothers.com
Join us on facebook.com/JaypeeMedicalPublishers

Shelving Recommendation
ORTHOPEDICS

ISBN 978-93-5270-287-9