website www.jaypeebrothers.com, for detailed information on dermatology books, visit our website www.jaypeebrothers.com

Celebrating 50 years
Passion, Quality and Innovation in Healthcare Publishing

Chemical Peels
A Global Perspective



Editors
Rashmi Sarkar
Wendy E Roberts

Foreword
Valerie D Callender

JAYPEE

Contents

1. **The History of Chemical Peels** 1
   Rashmi Sarkar, Zubin K Mandlewala
2. **Histology of the Skin and Wound Healing** 5
   Lark G Guss, Seaver L Soon
3. **Definition and Classification of Chemical Peels** 14
   Doris Hexsel, Carlos G Wambier
4. **Basic Chemistry and Technical Variables while Applying Peels** 22
   Rashmi Sarkar, Sneha Ghunawat
5. **Priming, Prepeel and Postpeel Care** 27
   Rashmi Sarkar, Sneha Ghunawat
6. **Patient Assessment and Counseling** 30
   Sneha Ghunawat, Rashmi Sarkar
7. **Glycolic Acid Peels** 37
   Shankila Mittal, Rashmi Sarkar, Sneha Ghunawat
8. **Procedure of Glycolic Acid Peel** 50
   Sumit Sethi
9. **Salicylic Acid Peels** 59
   Surabhi Sinha, Rashmi Sarkar
10. **Trichloroacetic Acid Peels** 64
    Jaishree Sharad
11. **Lactic Acid Peels** 72
    Surabhi Sinha, Gunjan Verma
12. **Mandelic Acid Peels** 78
    Seemal R Desai, Jacob R Stewart
13. **Pyruvic Acid Peel** 82
    Ishad Aggarwal
14. **Jessner's and Resorcinol Peels** 86
    Sonali Langar

15. **Tretinoin and Retinol Peels** 96
Latika Arya

16. **Phytic Acid Peel** 102
Rashmi Sarkar, Sneha Ghunawat

17. **Medium-depth Peeling with Special Consideration to Ethnic Skin** 108
Sidharth Sonthalia

18. **Phenol Peels and Its Modifications for Skin of Color** 122
Sidharth Sonthalia

19. **Medium-depth Peels** 131
Fischer Sabrina, Borelli Claudia

20. **Deep Peels: A Review of Chemical Peels for All Skin Types** 141
Peter P Rullan

21. **Sequential Peels** 158
Aarti Sarda, Abhishek De

22. **Yellow Peels** 163
Shehnaz Z Arsiwala

23. **Arginine Peel** 170
Ishad Aggarwal, Manmit K Hora

24. **Ferulac Peel** 174
Aarti Sarda, Abhishek De

25. **Combination Peels** 180
Rashmi Sarkar, Zubin K Mandlewala

26. **Proprietary Peels** 192
Mukta Sachdev, Rachana Shilpakar

27. **Combination Therapy: Chemical Peels with Other Technologies** 203
Mukta Sachdev, Rachana Shilpakar

28. **Chemical Peels in Melasma** 209
Sahar MF Ghannam, Zubin K Mandlewala, Rashmi Sarkar

29. **Chemical Peels for the Treatment of Postinflammatory Hyperpigmentation** 218
Nisha V Parmar, Rashmi Sarkar

30. **Chemical Peels for Acne and Acne Scars in Dark Skin** 223
Monica B Dassi

31. **Special Scenario: Peels for Photoaging** 239
Sonali Langar

32. **Special Scenario: Chemical Peeling in Sensitive Skin** 248
Surabhi Sinha

33. **Party Peels** 252
Atula Gupta

34. **Extra-facial Peeling** 259
Meenaz Khoja, Sourabh Jain

35. **Home-based Peeling Systems** 270
Ishad Aggarwal, Manmit K Hora

36. **Innovations with Chemical Peels in Dark Skin** 274
Geraldine Jain

37. **Chemical Peels in Dark Skinned Patients: Asian and African Skin** 286
Nicole A Negbenebor, Kaveri Korgavkar, Kachiu C Lee

38. **Chemical Peels in Ethnic Skin: Latin American Skin** 297
Carlos G Wambier

39. **Complications of Chemical Peels and How to Deal with Them** 302
Shehnaz Z Arsiwala

40. **Recent Advances in Treatment with Chemical Peels** 309
Sakshi Srivastava, Sidharth Sonthalia

41. **Chemical Peel Pearls** 318
Wendy E Roberts

Appendix 321

Index 323

3
CHAPTER

Definition and Classification of Chemical Peels

Doris Hexsel, Carlos G Wambier

INTRODUCTION

Chemical peels are a popular and well-known cosmetic procedure. They are probably among the first cosmetic procedures in history with reports since ancient times.[1] Currently, many exfoliating agents are available. Although it was believed that chemical peels could be replaced by laser/ablative technologies, they are still used routinely and have high efficacy rates.[2,3] Their efficacy in skilled hands and low cost of consumables have undisputed balance of cost-effectiveness. Therefore, chemical peels are still irreplaceable in the cosmetic surgery weaponry.

Chemical peels are chemical agents with keratolytic or caustic properties that cause ablation of skin layers. The use of these agents targets and damages specific layers of the epidermis and/or dermis leading to an accelerated exfoliation of the skin for either cosmetic or therapeutic purposes.

The usual classification of chemical peels is defined by the depth of penetration into the skin, which can be superficial, medium or deep.[4] The success of the procedure depends much on the understanding of the chemical and biological characteristics of the agent applied and on the proper patient evaluation, selection and preparation.

DEFINITION

Chemical peels consist in the ablation of skin layers induced by the application of chemical agents with keratolytic or caustic effects. The objective of chemical peels is to damage specific layers of the epidermis and/or dermis leading to an accelerated exfoliation of the skin. The ablated skin is thus spontaneously eliminated over the days after the procedure and subsequent regeneration of tissues occur with the induction of repair mechanisms.

Chemical peels are used either for cosmetic or therapeutic purposes. Indications include pigmentary disorders such as melasma, post-inflammatory hyperpigmentation (PIH), freckles and lentigines; epidermal growths such as seborrheic keratoses, actinic keratoses and sebaceous hyperplasia among others; acne and acne scars; superficial scars; photoaging changes; wrinkles and textural alterations can be treated with this procedure.[5-12] The histologic depth of a lesion or the condition to be treated defines the particular peel to be utilized for a desired outcome.

JAYPEE BROTHERS

CLASSIFICATION

Chemical peels are usually classified by the depth of penetration into the skin as shown in table 1. In general, the depth of the chemical peel is directly proportional to the discomfort during and after the procedure, the need for sedation, the healing time, the rate of the potential side effects, the need for training and the clinical results.[2]

Very Superficial Chemical Peels

Very superficial chemical peels cause minimal exfoliation of the skin as they target only the stratum corneum. The most commonly used agents are:

- Salicylic acid 20–30% in ethanol or 30% in polyethyleno glycol (PEG)
- Glycolic acid 30–50% applied briefly (1–5 minutes)
- Jessner's solution, 1–3 coats
- Modified Jessner's solution (Fig. 1)
- Resorcinol 20–30%, applied briefly (5–10 minutes)

TABLE 1: Classification of chemical peels according to the depth[4]

Depth of the peel	Target skin layer
Very superficial	Destruction of the stratum corneum without creating a wound below the stratum granulosum
Superficial	Destruction of part or all of the epidermis, anywhere from the stratum granulosum to the basal cell layer
Medium	Destruction of the epidermis and part or all of the papillary dermis
Deep	Destruction of the epidermis and papillary dermis, extending into the reticular dermis



FIG. 1: Very superficial peels with 4 coats of modified Jessner's solution. Pseudofrosting from crystallization of salicylic acid from the evaporation of ethanol. Clinical endpoint: diffuse, even erythema.



FIG. 2: Superficial 5% retinoic acid in a "gold peel", containing also melatonin and Curcuma longa extract for additional anti-inflammatory and anti-oxidant properties.

- Trichloroacetic acid (TCA) 10–20%, 1 coat
- Retinoic acid 3–5%, for 4–6 hours (Figs. 2 and 3)
- Mandelic acid 30–40%.

Previous priming is not required in fair skinned patients but one should do it in dark skinned patients. Usually, these peels require a series of 3–6 sessions every 7–30 days to achieve results. There is not much downtime with very superficial chemical peels and thus patients can resume day-to-day activities with

JAYPEE BROTHERS

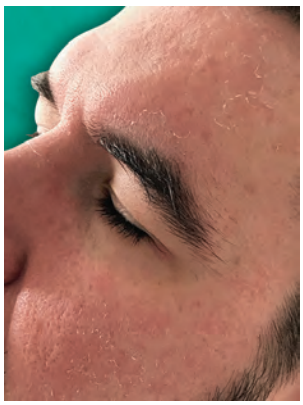

FIG. 3: Patient with mild scaling 3 days after a superficial peeling with 5% retinoic acid in the "gold peel", containing also melatonin and Curcuma longa extract for additional anti-inflammatory and anti-oxidant properties.

immediate effect. The common indications wherein very superficial chemical peels are utilized are: melasma, solar lentigines, acne and PIH.[13]

Superficial Chemical Peels

Superficial chemical peels produce an ablation anywhere between the stratum granulosum and the basal cell layer. The epidermis becomes thinner and its regeneration is caused by multiplication of the epidermal cells. In the superficial dermis, mild inflammation stimulates fibroblastic activity and thereby neocollagenesis signaling to fibroblasts and some new collagen synthesis. The most commonly used agents are:

- Glycolic acid 50–70%, until erythema
- Jessner's solution, more than 4 coats
- Modified Jessner's solution more than 4 coats
- TCA 20–35%
- Pyruvic acid 40–50%
- *Combination peels*: Salicylic acid 30% + TCA 20%
- Jessner's + TCA 20%
- Resorcinol 40–50%, applied for 30–60 minutes.

For superficial peels to produce desired effects, it is important to prepare the skin with a mild topical primer for at least 14 days, such as 0.1% adapalene, 0.01–0.05% retinoic acid, 10% glycolic acid or 15–20% azelaic acid. Like the very superficial peels, these are also performed in a series of 3–6 sessions every 15–30 days and do not require downtime (Fig. 3). Superficial peels are the most commonly performed chemical peels, and promote a "refreshed and rejuvenated look of skin". The increase in epidermal turnover improves skin color, texture and reduces comedones. This occurs faster than that which occurs through oral or topical therapies (Fig. 4). The common indications wherein superficial chemical peels are utilized are: photoaging, skin texture, acne, actinic keratoses, superficial dyschromias, solar lentigines, melasma, PIH and irregular tanning.[2,3,13]

Medium-depth Chemical Peels

The medium-depth chemical peels cause necrosis of all the epidermis and part or all of the papillary dermis. The regeneration of skin is mainly from cells of the hair follicles, which are present deeper than the areas destroyed by the peeling process. New layers of epidermis are formed and synthesis of collagen is stimulated. The most commonly used agents are:

- Jessner's solution + TCA 35%
- Modified Jessner's solution + TCA 35%
- Glycolic acid 70% + TCA 35%
- Solid carbon dioxide slush + TCA 35%
- *Alternatives in disuse*: TCA 50%, pyruvic acid >60%, pure phenol 88%.

In the case of medium-depth peels, priming is advised for regular and fast penetration of TCA. Since medium-depth peels are prone to cause PIH, in susceptible individuals, the use of bleaching agents, such as hydroquinone, in association with retinoic acid and a corticosteroid is advisable

JAYPEE BROTHERS

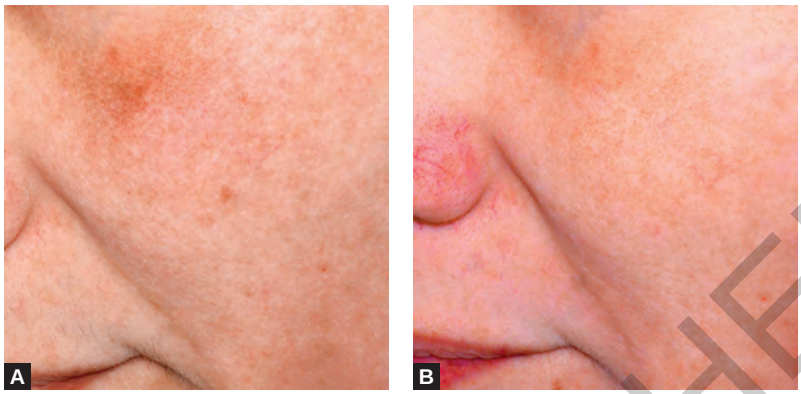

FIG. 4: A patient presenting with postinflammatory hyperpigmentation and melasma. **A,** Before; **B,** 14 days after one superficial peel with modified Jessner's solution.

(explained in subsequent chapters). In individuals with fair skin and without melasma, topical retinoids are enough. Priming works best if prescribed for over 30 days, and stopped 72–48 hours before the scheduled date of the peel. A single session is performed at 6–12 months intervals. These peels cause edema for the first 24–48 hours, with mild tenderness. After the first 48 hours, the skin turns dark and dry, until thick brown-black scales fall off (Fig. 5). Some patients are able to work with tinted sunscreen and moisturizers if the peel is performed before weekend, but most need to be absent from work because of the dark mask for at least 7 days (Fig. 6). Medium-depth chemical peels are mainly used to treat melasma, moderate photoaging, actinic keratosis (Fig. 7), lentigines, fine lines and wrinkles, PIH and superficial atrophic scars.[3,13] Wrinkles and acne scars display only a slight improvement with medium-depth chemical peels.[2]



FIG. 5: Five days post procedure of a combination of medium-depth peel of sequential modified Jessner's solution, followed by 35% trichloroacetic acid and deep chemical peel performed in the perioral area with Hetter's 1.6% croton oil in 35% phenol.

Deep Chemical Peels

The necrosis caused by deep chemical peels can reach up to the mid-reticular dermis. Although, necrosis itself isn't the most important factor in terms of the eventual effects with deep peels. The main chemical agent that makes deep chemical peels so different to dermabrasion, ablative lasers and microneedling is the direct action of phorbol esters in the protein synthesis and stem cell stimulation.[14-16] Even though some degree of focal apoptosis is inevitable, the overall rejuvenating effect is quite appreciable with deep peels. Generally, the epidermal architecture returns to normal, while the dermal layers may display a collagen band

JAYPEE BROTHERS

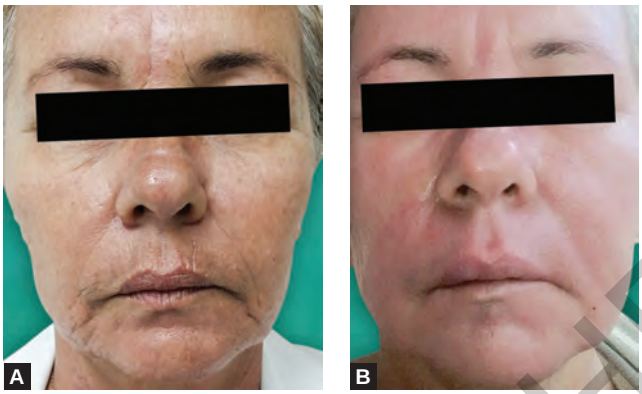

FIG. 6: **A,** Patient before a medium-depth peel with modified Jessner's solution, followed by 35% trichloroacetic acid, combined with a deep peel in the perioral area with Hetter's 1.6% croton oil in 35% phenol; **B,** Three months after the procedure, fine wrinkles, lentigines, and diffuse melanosis are no longer present.



FIG. 7: Medium-depth chemical peel with Jessner's solution followed by 35% trichloroacetic acid (illustrated), performed in a patient presenting with actinic keratosis and actinic cheilitis.

up to 2–3 mm thick. In the dermis, a new subepidermal band of collagen and a band 2–3 mm thick appears. It is located above the dermis where elastosis occurs, the part of the dermis unaffected by peeling. These modifications can be observed up to 20 years after phenol peeling.[17] In general, it is believed that the skin that underwent treatment with deep peeling is less susceptible to skin cancer.[18]Although occlusion is believed to increase penetration and to enhance results, this assumption lacks support from scientific data and is not performed by many specialists, who prefer simple ointments, such as Vaseline®.[19,20]

Croton oil, a deep peel causes an intense inflammatory reaction with heat-like pain caused by the swelling that usually peaks 3 hours post peeling and lasts up to 12 hours. Pain is controlled with opiates, nonsteroidal anti-inflammatory drugs, cold wind, water mist or saline compresses. The resulting edema reaches its peak and pain disappears on the following day. Edema usually lasts 72 hours. After the third day, it is common to observe purulent exudate, yellow crust formation and eschars (Fig. 8). The facial skin is usually completely healed in 7–10 days. After that, intense erythema reaches its peak 14 days after the procedure and takes 2–4 months to fade. The rejuvenation process continues until erythema persists.

The most commonly used agents are:

- Hetter's formulas (0.4–1.6% croton oil in 33–35% phenol) (Figs. 5, 6, 8 to 10)[21]
- Baker–Gordon's formula (2.1% croton oil in 50% phenol).

JAYPEE BROTHERS



FIG. 8: Patient presenting with purulent exudate, yellow crusts and erythema 5 days after a deep chemical peel with Hetter's 1.6% croton oil in 35% phenol.



FIG. 9: Deep peeling with Hetter's croton oil 1.6% in 35% phenol, in a patient presenting with severe acne scarring and moderate photoaging.



FIG. 10: A patient presenting with severe acne scarring. **A,** Before; **B,** 6 months after a deep peel with Hetter's croton oil 1.2% in 35% phenol.

Although priming is usually not necessary for deep peels, adapalene or retinoic acid generally improve penetration of the formula with increased uniformity of results. Sometimes, a smaller amount of the chemical agent is used to complete the procedure. Adequate priming is likely to reduce the time taken for the epidermis to heal completely. Usually, only a single session is performed, yet, a few patients with very thick/oily skin, may require an additional treatment. As results are long lasting, the procedure may be repeated after 6 months, if necessary. As these peels can cause significant downtime, it is advisable for patients to abstain from routine outdoor activities for atleast a week. Deep chemical peels are mainly indicated in—severe photoaging, dermal-type melasma, PIH, dyschromia, fine and coarse wrinkles, premalignant skin tumors and acne scars (Fig. 10).[2,3]

Although very effective, deep chemical peels are not as frequently performed as medium-depth and superficial peels. As

JAYPEE BROTHERS

deep peels may warrant a thoroughness in comprehending/managing the likelihood of side effects (e.g., cardiovascular toxicity), they should only be utilized by experienced hands. Postpeel, it is imperative that the treating physician clinically examine the patient routinely during the first week itself. Full-face procedures must be performed under multiparameter monitoring (in ICU facilities), with intravenous access for hyperhydration. The surgeon must be prepared to deal with arrhythmias and to control anxiety, blood pressure and pain. Deep peels are not performed in dark-skin types (V–VI) because of the high risk of hypertrophic scars and irregular pigmentation. Inhalation of phenol fumes during the procedure is an important concern for the physicians and staff. The authors recommend to perform the procedure in rooms equipped with air exhaustion and to wear activated charcoal masks during the peels.

CHEMICAL PEEL DEPTH

The peel classification mentioned above is routinely followed by many physicians, yet, it is important to note that there are many variables that can alter postpeel wound depth. These can be related to the chemical agent itself, to the technique, or to the patient (Table 2).[4,22,23] All these factors should be taken into account when performing the chemical peel as they will directly interfere in the depth of the peel and consequently in its outcomes. The choice of a particular agent primarily relies on the skin condition/disorder for which it is applied.

CONCLUSION

Chemical peels are best classified according to their depth of wounding. Many agents available in formulations with varying concentrations and also the techinque implented, allow physicians to individualize peel protocols for a particular patient. Their versatility and effectiveness serve as a major utility for physicians in treating numerous skin conditions.

TABLE 2: Factors affecting the depth of chemical peels[4,22,23]

Variables	
Chemical agent	• Agent nature • Agent concentration • Volume applied
The technique	• Number of coats • Pressure • Applicator used (brush, cotton ball, cotton-tipped applicator, and gauze) • Thickness of the layer applied • Saturation of the applicator • Degree of buffering (when applicable) • Occlusion • Exposure time • Frequency
The patient	• Type of skin (seborrheic, sebaceous gland density, and sun-damaged) • Integrity of epidermal barrier and presence of subclinical lesions (microtraumas) • Previous use of priming agents and other exfoliants • Cleansing and degreasing the skin before the peel • Anatomical location of the peel

TAKE HOME POINTS

- Chemical peels may be more effective than ablative technology
- Unmatched cost-effectiveness as a cosmetic treatment
- Versatile and easy to combine with other treatments.

JAYPEE BROTHERS

REFERENCES

1. Brody HJ, Monheit GD, Resnik SS, et al. A history of chemical peeling. Dermatol Surg. 2000;26(5):405-9.
2. Landau M. Chemical peels. Clin Dermatol. 2008;26(2): 200-8.
3. Fisher TC, Perosino E, Poli F, et al. Chemical peels in aesthetic dermatology: an update 2009. J Eur Acad Dermatol Venereol. 2010;24(3):281-92.
4. Rubin MG. Manual of Chemical Peels. Philadelphia: JB Lippincott; 1992. pp. 17-25.
5. Khunger N; IADVL Task Force. Standard guidelines of care for chemical peels. Indian J Dermatol Venereol Leprol. 2008;74 Suppl:S5-12.
6. Rendon MI, Berson DS, Cohen JL, et al. Evidence and considerations in the application of chemical peels in skin disorders and aesthetic resurfacing. J Clin Aesthet Dermatol. 2010;3(7):32-43.
7. Sarkar R, Garg V, Bansal S, et al. Comparative evaluation of efficacy and tolerability of glycolic acid, salicylic mandelic acid, and phytic acid combination peels in melasma. Dermatol Surg. 2016;42(3):384-91.
8. Sarkar R, Parmar NV, Kapoor S. Treatment of post-inflammatory hyperpigmentation with a combination of glycolic acid peels and a topical regimen in dark-skinned patients: a comparative study. Dermatol Surg. 2017;43(4):566-73.
9. Fabi SG, Goldman MP. Hand rejuvenation: a review and our experience. Dermatol Surg. 2012;38(7 Pt 2):1112-27.
10. Ghersetich I, Brazzini B, Peris K, et al. Pyruvic acid peels for the treatment of photoaging. Dermatol Surg. 2004;30(1):32-6.
11. Abdel Meguid AM, Elaziz Ahmed Attallah DA, Omar H. Trichloroacetic acid versus salicylic acid in the treatment of acne vulgaris in dark-skinned patients. Dermatol Surg. 2015;41(12):1398-404.
12. Puri N. Efficacy of Modified Jessner's Peel and 20% TCA Versus 20% TCA Peel Alone for the Treatment of Acne Scars. J Cutan Aesthet Surg. 2015;8(1):42-5.
13. Salam A, Dadzie OE, Galadari H. Chemical peeling in ethnic skin: an update. Br J Dermatol. 2013;169 Suppl 3:82-90.
14. Bensimon RH. Croton oil peels. Aesthet Surg J. 2008; 28(1):33-45.
15. Larson DL, Karmo F, Hetter GP. Phenol-Croton Oil Peel: Establishing an Animal Model for Scientific Investigation. Aesthetic Surg J. 2009;29(1):47-53.
16. Wambier CG, Brody HJ, Hetter GP. Comments: Hemiface comparative study of two phenol peels (Baker-Gordon and Hetter formulas) for the correction of facial rhytids. Surg Cosmet Dermatol. 2017;9(2):109-1.
17. Brown AM, Kaplan LM, Brown ME. Phenol induced histological skin changes: hazards, technique, and uses. Br J Plast Surg. 1960;13:158-69.
18. Baker TJ. Is the phenol-croton oil peel safe? Plast Reconstr Surg. 2003;112(1):353-4.
19. Stuzin JM, Baker TJ, Gordon HL. Chemical peel: a change in the routine. Ann Plast Surg. 1989;23(2):166-9.
20. Wambier CG, de Freitas FP. Combining Phenol-Croton Oil Peel. In: Issa MCA, Tamura B (Eds). Chemical and Physical Procedures. Cham: Springer International Publishing; 2017. pp. 1-13.
21. Hetter GP. An examination of the phenol-croton oil peel: part IV. Face peel results with different concentrations of phenol and croton oil. Plast Reconstr Surg. 2000;105(3): 1061-83.
22. Landau M, Ghannam SF. Chemical peels. In: Robinson JK, Hanke CW, Siegel DM, Fratila A (Eds). Surgery of the Skin: Procedural Dermatology, 3rd edition. Philadelphia: Saunders-Elsevier; 2015. pp. 393-408.
23. Matarasso SL, Glogau RG. Chemical face peels. Dermatol Clin. 1991;9(1):131-50.

JAYPEE BROTHERS

detailed information on dermatology books, visit our website www.jaypeebrothers.com, for detailed information on dermatolog

Key Features

- A comprehensive, highly practical manual featuring basic concepts as well as advancements in chemical peels
- Provides an absolute and definitive guide to all types of chemical peel treatments
- Includes clinical photographs throughout for better understanding of the subject
- Other highlight includes specific treatment effects of chemical peels in different races and ethnicities
- Authoritatively written by experts with immense knowledge and clinical experience
- An ideal reference tool for cosmetologists and dermatologists dealing with cosmetology.

Rashmi Sarkar MD MNAMS is a Professor of Dermatology at Maulana Azad Medical College and Associated LNJP Hospital, New Delhi, India. She has done her MD (Dermatology) from Postgraduate Institute of Medical Education and Research, Chandigarh, India. She is Editor-in-Chief, *Pigment International* and *World Clinics in Dermatology*; was the Founder Editor of *Asian Pigment Bulletin* (APB); was Associate Editor of *Journal of Cutaneous and Aesthetic Surgery* (JCAS) (2011–14); on the Editorial Board of *Indian Journal of Dermatology, Venereology and Leprology* (IJDVL), *Indian Journal of Pediatric Dermatology* (IJPD), *Indian Journal of Dermatology* (IJD) and *International Journal of Dermatology* (2014–17), *International Journal of Women's Dermatology* (IJWD) and *Journal of Clinical and Aesthetic Dermatology* (JCAD); besides being a reviewer for 20 journals. She has edited 8 books, has 160 publications in peer reviewed international and national journals and 60 chapters in textbooks of dermatology and pediatrics. She was the National Secretary General of Indian Association of Dermatologists, Venereologists, and Leprologists (2014–15); President IADVL Delhi State Branch (2018); Chief Founder and President of Pigmentary Disorders Society (PDS); and Founding President of Joint Women's Dermatologic Society-Indian Women's Dermatologic Society. She is also a recipient of several prestigious awards and honors including Maria Duran Fellowship from International Society of Dermatology (ISD), Member Making a Difference Award from American Academy of Dermatology (AAD), Career and Community Development Award from Women's Dermatologic Society, and other International Travel Awards from ISD, World Congress of Dermatology (WCD), and AAD. Dr Sarkar has been an invited speaker in many international and national conferences, including the prestigious Annual AAD Meetings since 2006.

She is Vice President, ISD; Secretary General of Asian Society of Pigment Cell Research (ASPCR) (2014–17); President-Elect ASPCR (2020–23); International Representative, Board of Directors in Women's Dermatologic Society (WDS) (2011–14; 2017–18); former Board of Directors in Skin of Color Society (SOCS); Co-Chair of International Mentorship Committee of ISD; and Chair of Women's Committee of International Federation of Pigment Cell Societies (IFPCS) and International Affairs Committee of WDS (2014–17), Member of International Affairs Committee of AAD. She is the Chair, National and International Committee of SOCS.

Wendy E Roberts MD is a graduate of Stanford Medical School with three postgraduate degrees, which include Surgery Internship and Residency PGY2, Dermatology Residency and Dermatopathology where she completed a fellowship at New York University Medical Center. She is Double Board Certified in Dermatology and Dermatopathology. She is Founding Director of Dermatopathology at Loma Linda University Medical Center. She alone, pioneered and developed Generational Dermatology™ which is a detailed system of age management. She is Founder and Chair of the Generational Dermatology Symposium which has become a national meeting venue for Dermatologists and Plastic Surgeons. She is founder of the Roberts Skin Type Classification System® as seen on The Today Show™. Dr Roberts has authored articles and contributed book chapters for various Dermatological subjects. Acne, Chemical Peeling, Melasma, Pigmentation disorders, Skin type, Esthetics, Skin of Color, Generational Dermatology, Geriatric Dermatology, Sunscreen Protection, Skin Cancer in Ethnic Skin of Color and Pollution of the Skin. Frequently quoted in national magazines, radio, television and news that includes NBC, New Beauty, W, WebMD, ReachMD, Oprah Magazine, CNN, Fox News Live, Self, Allure, Sisters to Sisters, Prevention, Readers Digest, Los Angeles Times, PS Life. She was cited by Essence Magazine as the Dermatologist to watch. She was named "Rockstar Dermatologist" by Glamour magazine and penned "The Youth Booster" and embraced by celebrities. She is a past president of both the Women's Dermatologic Society which is the third largest Dermatology organization in the country, and CALDERM, the California State Dermatologic Society. She is also a member of the American Dermatological Association which is an honor society for Dermatologists. She was Chair of the Geriatric session at the World Congress of Dermatology in Vancouver 2015. Known by the specialty for her innovation and energy she has been in her private practice in Rancho Mirage, California since 1994. Active in her local medical community as well, Dr Roberts has been voted as "Best Doctor" by her colleagues for the last 12 years by the Palm Springs Life Magazine. Dr Roberts was just selected as a Leading Physicians of the World by the prestigious International Association of Healthcare Professionals.

Available at all medical bookstores
or buy online at www.jaypeebrothers.com



JAYPEE BROTHERS
Medical Publishers (P) Ltd.
www.jaypeebrothers.com

Join us on facebook.com/JaypeeMedicalPublishers

Shelving Recommendation
DERMATOLOGY

