information on dental books, visit our website **www.jaypeebrothers.com,** for detailed information on dental books, visit our website **www.jaypeebrothers.com**

Essentials of Anatomy *for* Dental Students

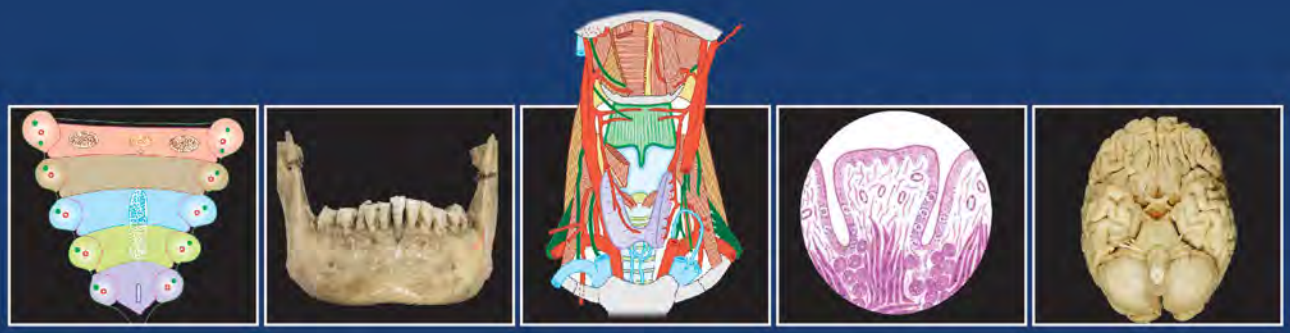

Embryology | Osteology | Gross Anatomy | Histology | Neuroanatomy

TL Selvakumari

Forewords
Rashmi
Padminee Krishnan
Jacinta Antony

JAYPEE

Contents

SECTION 1: EMBRYOLOGY

1. Cell Structure and Function 3

Structure of a cell 3
Structure of a chromosome 4
Functions of cells 5

2. Cell Division 6

Types of cell division 6

3. Gametogenesis 14

4. Ovarian Cycle 19

Changes during ovarian cycle 19
Menstrual cycle 22
Fertilization 24

5. Development of Human Embryo 26

Development of human embryo in the first week of gestation 26
Bilaminar germ disk 28
Trilaminar germ disk 29

6. Derivatives of Germ Layers 32

Structures derived from ectoderm 32
Structures derived from endoderm 33
Structures derived from mesoderm 33

7. Development of Notochord 35

Formation of notochord 35

8. Development of Neural Tube and its Derivatives 38

Development of neural tube and neural crest cells 38
Derivatives of neural tube 38
Derivatives of neural crest cells 40

9. Foldings of Embryo 42
Foldings 42

10. Development of Placenta 44
Components of placenta 44
Development of placenta 45
Functions of placenta 47
Placenta of twins 47

11. Pharyngeal Apparatus 50
Parts of pharyngeal apparatus 50
Developmental anomalies 55

12. Development of Heart 57
Development of heart tube 57
Aortic arch arteries and their derivatives 59

13. Development of Face 62
Development 62
Development of nose 65
Development of jaws and lips 66

14. Development of Teeth 70
Development of teeth 70

15. Development of Tongue 73
Development 73
Nerve supply 74
Developmental anomalies 75

16. Development of Palate 76
Development 76
Developmental anomalies 77

17. Development of Glands 79
Development of major salivary glands 79
Development of the thyroid gland 80
Development of pituitary gland 82

18. Development of Eye 84
Development 84
Congenital anomalies 86

19. Development of Ear 87
Development 87
Congenital anomalies 88

20. Development of Temporomandibular Joint 89
Development 89
Congenital anomalies 91

21. Development of Skull 92
Development 92
Congenital anomalies 94

22. Development of Vertebral Column 95
Development 95
Congenital anomalies 96

SECTION 2: **OSTEOLOGY**

23. Anatomical Terminology and Components of Skull 101
Anatomical terminology in relation to bones 101
Anatomical components of skull 103

24. Normas of Skull 105
Norma frontalis 105
Orbital cavity 110
Norma verticalis 115
Norma occipitalis 116
Norma lateralis 118
Norma basalis 122

25. Interior of Skull 129

26. Cervical Vertebrae 139

27. Individual Bones of Skull 151
Frontal bone 151
Parietal bone 154
Occipital bone 157
Temporal bone 163
Styloid apparatus 168
Maxilla 170

Zygoma 174
Mandible 176
Sphenoid bone 182
Palatine bone 187
Ethmoid bone 189
Vomer bone 190
Nasal bones 191
Lacrimal bone 192
Inferior nasal concha 193

28. Classification of Joints 194

SECTION 3: **GROSS ANATOMY**

29. Scalp 205
Nerve and blood supply of scalp 207

30. Face 212
Dermatomes of face 212
Blood supply of face 214
Venous drainage of face 216
Lymphatic drainage of the face 218
Muscles of facial expression 220
Orbicularis oculi 225
Orbicularis oris 227
Buccinator 229
Eyelid 230
Lacrimal apparatus 231

31. Salivary Glands 235
Parotid gland 235
Parotid duct 241
Otic ganglion 242
Submandibular and sublingual salivary glands; submandibular ganglion 244

32. Neck 252
Extent 252
Sternocleidomastoid muscle 253
Trapezius 254
Classification of triangles of the neck 255

Anterior midline structures of the neck 272
Suprahyoid group of muscles 291
Infrahyoid group of muscles 296

33. Back of the Neck 298

Suboccipital triangle 298
Prevertebral and paravertebral muscles 299
Scalenovertebral triangle 303
Craniovertebral joints 303

34. Nerves 307

Typical spinal nerve 307
Cervical plexus 309
Brachial plexus 311
Cranial nerves 314
Functional components of cranial nerve nuclei 362
Cervical sympathetic chain 366
Ciliary ganglion 368
Otic ganglion 369
Pterygopalatine ganglion 370

35. Blood Vessels of the Head and Neck 373

Blood vessels of the neck 373
Lymphatic drainage of the head and neck 406

36. Temporal and Infratemporal Regions 411

Temporal fossa 411
Infratemporal fossa 412
Pterygopalatine fossa 413
Temporomandibular joint 414
Muscles of mastication 420

37. Interior of Cranium 426

Meninges 426
Dural venous sinuses 430
Emissary veins 437
Pituitary gland or hypophysis cerebri 438
Trigeminal ganglion 442

38. Orbit 444

Contents of orbital cavity 444

39. Nose and Paranasal Air Sinuses 456
Nose 456
Paranasal air sinuses 464

40. Mouth 470
Boundaries 470
Parts 470
Palate 481

41. Larynx 486
Components of larynx 487

42. Pharynx 502
Subdivisions 502
Muscles of pharynx 506
Development and nerve supply 509
Auditory tube 510
Palatine tonsil 513

43. Ear 517
Parts 517
External ear 517
Middle ear cavity 522
Internal ear 526

SECTION 4: HISTOLOGY

44. Cell Structure 543
Cell 543

45. Epithelial Tissue 546
Epithelium 546

46. Connective Tissue 556
Classification 556

47. Muscles 566
Skeletal muscle 566
Smooth muscle 567
Cardiac muscle 568

48. Nervous Tissue 570
Microscopic studies 570

49. Lymphoid Tissue 574
Types 574

50. Salivary Glands 579
Classification 579

51. Blood Vessels 585
Artery and vein 585

52. Digestive System 589
Lips 589
Sagittal section of tongue 590
Esophagus or gastros 591
Stomach 592
Small intestine or enteron 593
Appendix 596
Large intestine or colon 597
Liver or hepatos 598
Gallbladder 599
Pancreas 600

53. Respiratory System 602
Epiglottis 602
Trachea 603
Lung or pulmones 603

54. Urinary System 605
Kidney or nephros 605
Ureter 606
Urinary bladder 607

55. Male Reproductive System 608
Testis 608
Prostate gland 609

56. Female Reproductive System 611
Ovary or oophoron 611
Uterus 612

57. Endocrine Glands 615
Types 615

58. Central Nervous System 620
Cerebrum 620
Cerebellum 621
Spinal cord: transverse section 622

59. Special Sensory Organs 625
Eye 625
Ear 629

60. Tooth 631
Histology of tooth 631

SECTION 5: **NEUROANATOMY**

61. Nervous System 637
Classification of nervous system 637
Brain 641

62. Cerebrum 644
Subdivisions of cerebrum 644

63. Diencephalon 659
Thalamus 659
Epithalamus 662
Hypothalamus 663
Interpeduncular fossa 665

64. Brainstem 666
Midbrain 666
Pons 669
Medulla oblongata 673

65. Cerebellum 679
Parts 679
Histology 680
Arterial supply 681
Connections 681
Relations 681

66. Blood Supply of Brain 682

Arterial supply 682
Venous drainage 683
Circle of Willis 684

67. Ventricles of Brain 687

Circulation of cerebrospinal fluid 687
Lateral ventricle 688
Third ventricle 691
Circumventricular organs 692
Fourth ventricle 693
Subarachnoid cisterns 695

68. Spinal Cord 697

SECTION 6: **GENETICS**

69. Terminology 711

70. Chromosome and Its Structure 714

Structure of a chromosome 715

71. Inheritance 719

Mendel's laws 719
Mode of inheritance 719

Index *727*

CHAPTER

2

Cell Division

TYPES OF CELL DIVISION

There are two types of cell division:
1. Mitosis or direct or somatic cell division
2. Meiosis or indirect or reduction division.

Mitosis

- Purpose of cell division by mitosis is to:
  - Increase the number of cells for development and growth of an embryo
  - Replacing the worn-out cells
  - Repair of wounds
  - Early stages of gonadal cell multiplication.
- There are four stages (Figs 2.1A to D):
  1. Prophase
  2. Metaphase
  3. Anaphase
  4. Telophase.

Prophase *(Fig. 2.1A)*

- Increase in size of the cell due to more protein synthesis
- The nuclear membrane and nucleolus disappear
- The centrosome forms two centrioles which are connected by spindle fibers
- The 46 chromosomes duplicate and have two short arms and two long arms, with a centromere.

Metaphase *(Fig. 2.1B)*

- The centrioles move to opposite poles
- Duplicated 46 chromosomes are randomly arranged in the equatorial plane
- The long axis of the chromosomes is parallel to the equator and they are held by spindle fibers.

JAYPEE BROTHERS

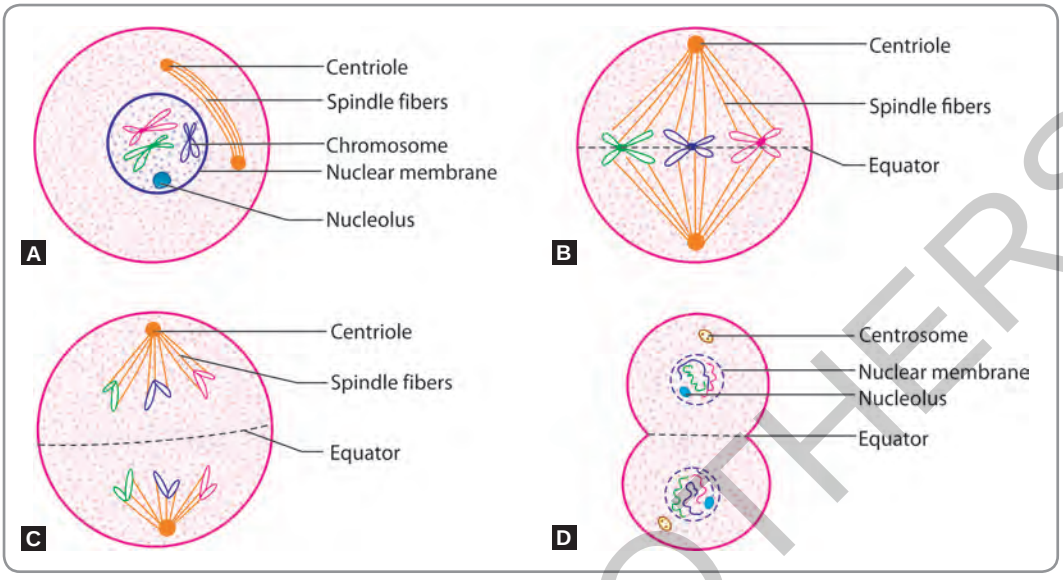

Figs 2.1A to D: Stages of mitosis. (A) Prophase; (B) Metaphase; (C) Anaphase; (D) Telophase

Anaphase *(Fig. 2.1C)*

- Spindle fibers contract
- Centromere divides
- 46 single chromosomes move to the opposite poles, towards the centrioles.

Telophase *(Fig. 2.1D)*

- Constriction of the cell membrane begins at the equator and it deepens to split the cytoplasm equally
- The centriole becomes the centrosome
- The nuclear membrane and nucleolus reappear
- The 46 single thread-like chromosomes become the chromatin reticulum.

Results

- Two daughter cells are formed
- They are smaller in size than the mother cell
- The genetic component of the mother cell and both the daughter cells are the same.

Meiosis

- Purpose of cell division by meiosis is to produce gametes which are specialized cells for reproduction
- There are two major phases in this type of cell division:
  1. Meiosis-I
  2. Meiosis-II.
- A gonadal cell that starts undergoing meiosis cell division (Fig. 2.2).

JAYPEE BROTHERS

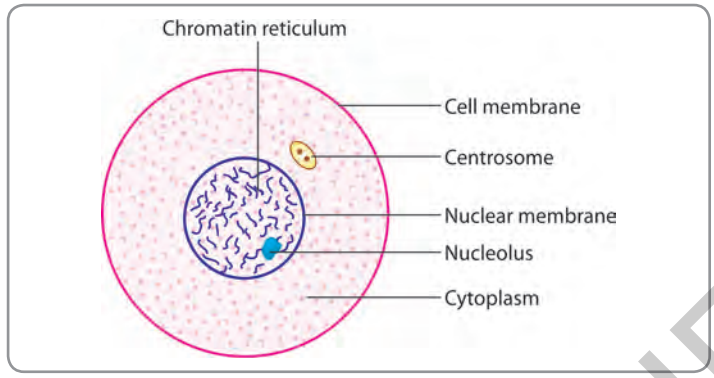

Fig. 2.2: Resting stage of cell

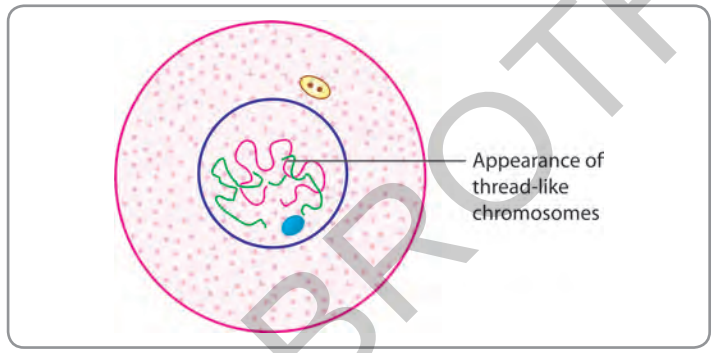

Fig. 2.3: Leptotene

Meiosis-I

The substages are:
- Prophase-I
- Metaphase-I
- Anaphase-I
- Telophase-I.

Prophase-I:
It has five substages:
1. Leptotene (Fig. 2.3)
   - The chromatin reticulum gets condensed to become thread-like structure.
2. Zygotene (Fig. 2.4)
   - 46 single chromosomes become 23 pairs
   - Each pair has a maternal and a paternal chromosome. This stage is synapsis or pairing.
3. Pachytene (Fig. 2.5)
   - Each chromosome duplicates. There are two short arms and two long arms
   - This stage is tetrad
   - The nonsister chromatids cross each other at multiple points. Each crossing point is chiasmata. This stage is crossing over
   - In each pair, the chromatids of maternal and paternal chromosomes are nonsister chromatids.

JAYPEE BROTHERS

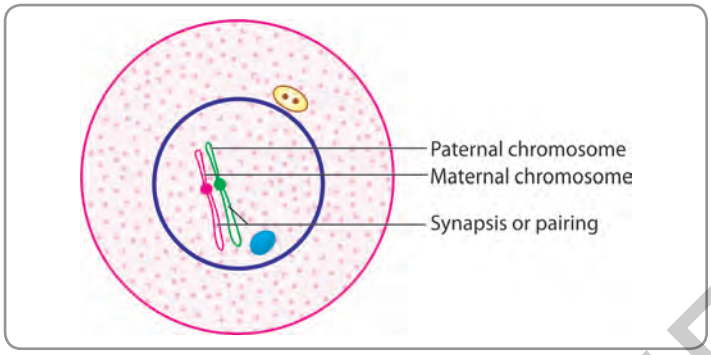

Fig. 2.4: Zygotene

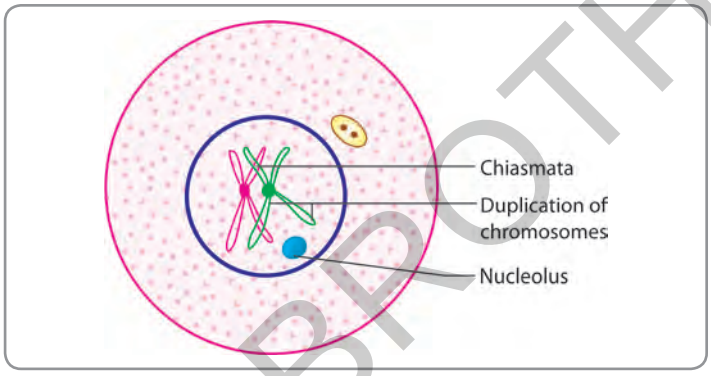

Fig. 2.5: Pachytene

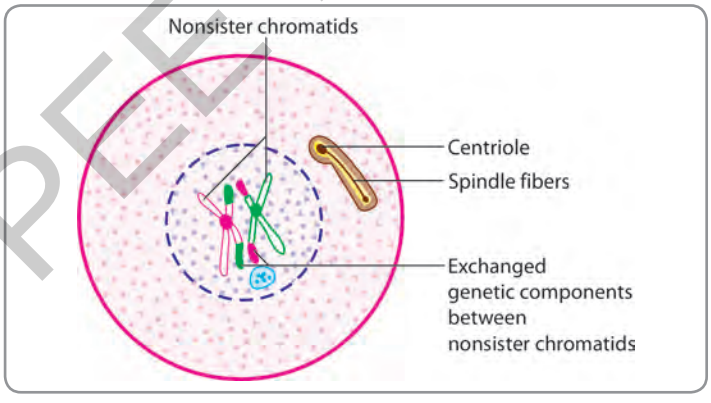

Fig. 2.6: Diakinesis

4. Diplotene
   - The segment of chromosome at the chiasmata is released and gets exchanged with the opposite chromatid.
5. Diakinesis (Fig. 2.6).
   - Release of crossing over. The nonsister chromatids lie adjacent to each other with the exchanged genetic components. By this time, the cell increases in size with more synthesis of proteins

JAYPEE BROTHERS

– Nuclear membrane and nucleolus disappear
– Centrosome forms two centrioles which move apart but connected by tubules.

Metaphase-I (Fig. 2.7):

- All the 23 pairs of duplicated chromosomes with exchanged genes are arranged in the equatorial plane of the cell
- The long axis of the chromosomes is parallel to equator
- They are held by the spindle fibers attached to the centrioles present in opposite poles.

Anaphase-I (Fig. 2.8):

- The spindle fibers contract
- The pair is separated. There is no division of the centromere
- The 23 duplicated chromosomes move away from each of its pair to opposite poles.

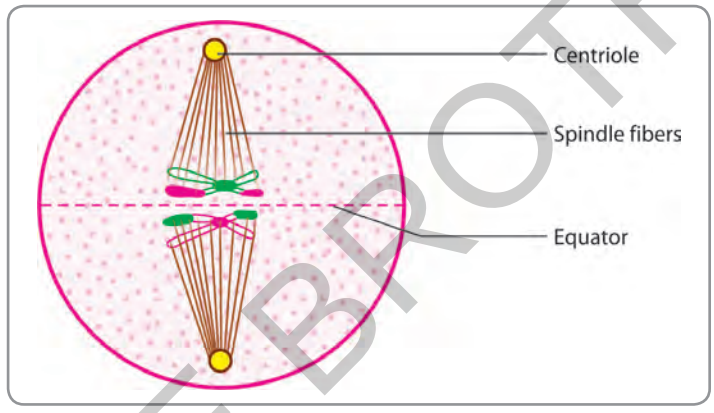

Fig. 2.7: Metaphase-I

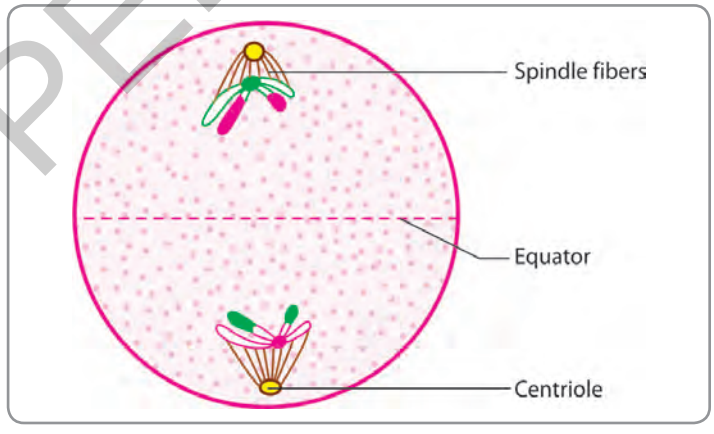

Fig. 2.8: Anaphase-I

JAYPEE BROTHERS

Telophase-I (Fig. 2.9):

- Constriction of the cell membrane starts at the equator and deepens to split the cytoplasm
- The nuclear membrane and nucleolus reappear
- The centriole becomes centrosome.

Results:

- Two daughter cells are formed
- They are smaller in size than the mother cell
- The genetic component of the mother cell and both daughter cells are different from each other
- The daughter cells have half the number of chromosomes or haploid in nature
- Meiosis-I is the reduction division.

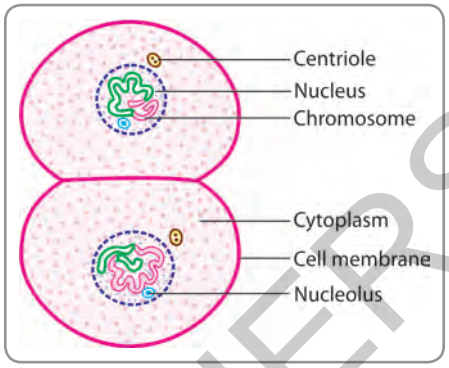

Fig. 2.9: Telophase-I

Meiosis-II

The substages are:

- Prophase-II
- Metaphase-II
- Anaphase-II
- Telophase-II.

Prophase-II (Fig. 2.10):

- The size of the cell increases. Protein synthesis is more
- No duplication of chromosomes occurs, because the 23 chromosomes are already in the duplicated state
- The nuclear membrane and the nucleolus disappear
- The centrosome becomes two centrioles, which migrate to the opposite poles
- The spindle fibers extend between them.

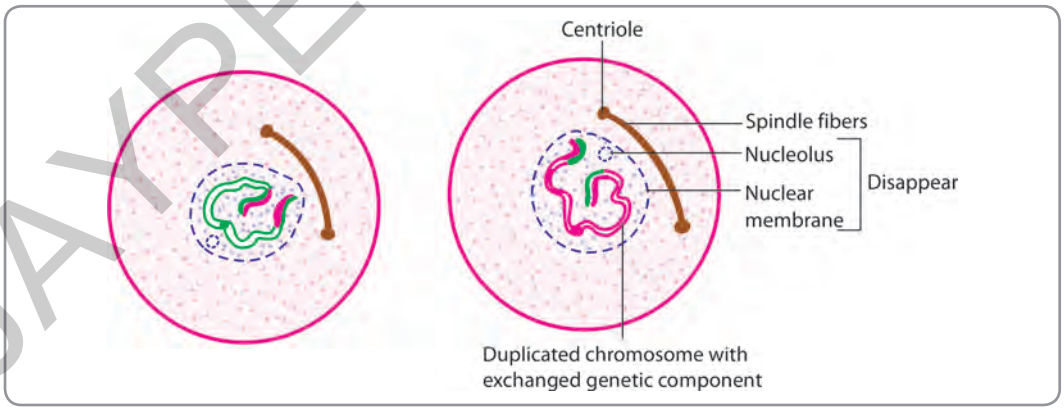

Fig. 2.10: Prophase-II

JAYPEE BROTHERS

Metaphase-II (Fig. 2.11):

- All 23 duplicated chromosomes are randomly arranged in the equatorial plane of the cell
- The long axis of the chromosome is parallel to the equator
- The spindle fibers hold them in position.

Anaphase-II (Fig. 2.12):

- The spindle fibers contract
- The centromere divides
- The 23 single chromosomes move apart, towards the opposite poles
- Each chromosome has a short arm and a long arm with centromere.

Telophase-II (Fig. 2.13):

- The cell membrane constricts at the equator and deepens to divide the cytoplasm
- The 23 single chromosomes become chromatin reticulum
- Centriole becomes the centrosome
- Nuclear membrane and nucleolus reappear.

Result:

- At the end of meiosis-II, four daughter cells are formed
- They are smaller in size than the mother cell

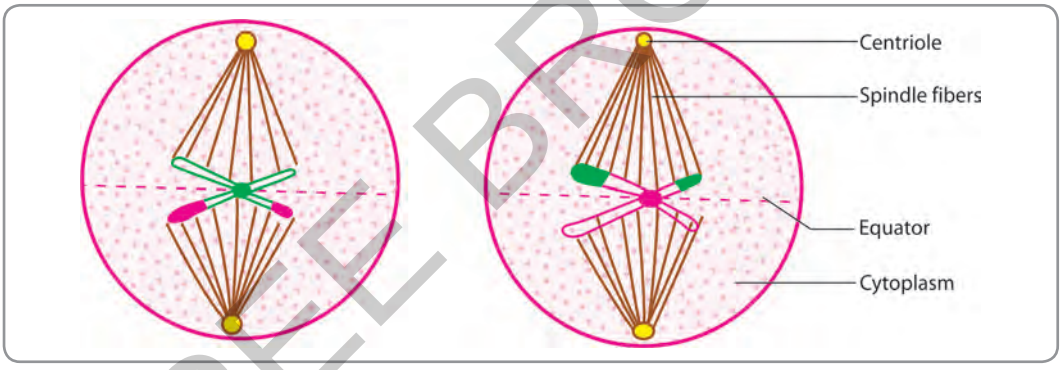

Fig. 2.11: Metaphase-II

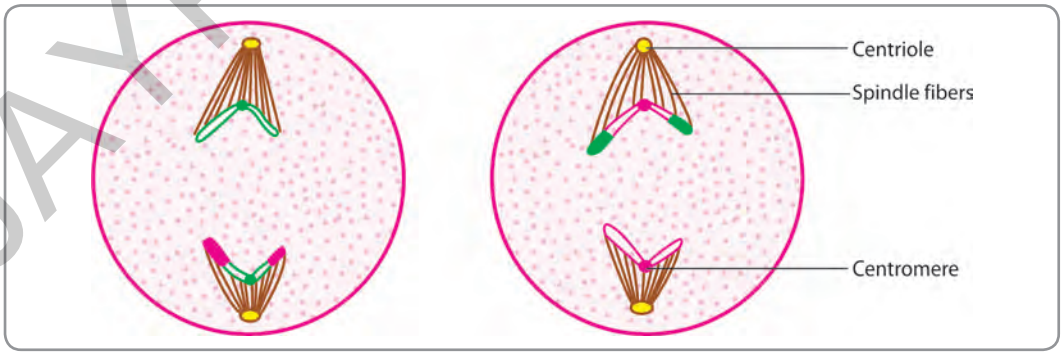

Fig. 2.12: Anaphase-II

JAYPEE BROTHERS

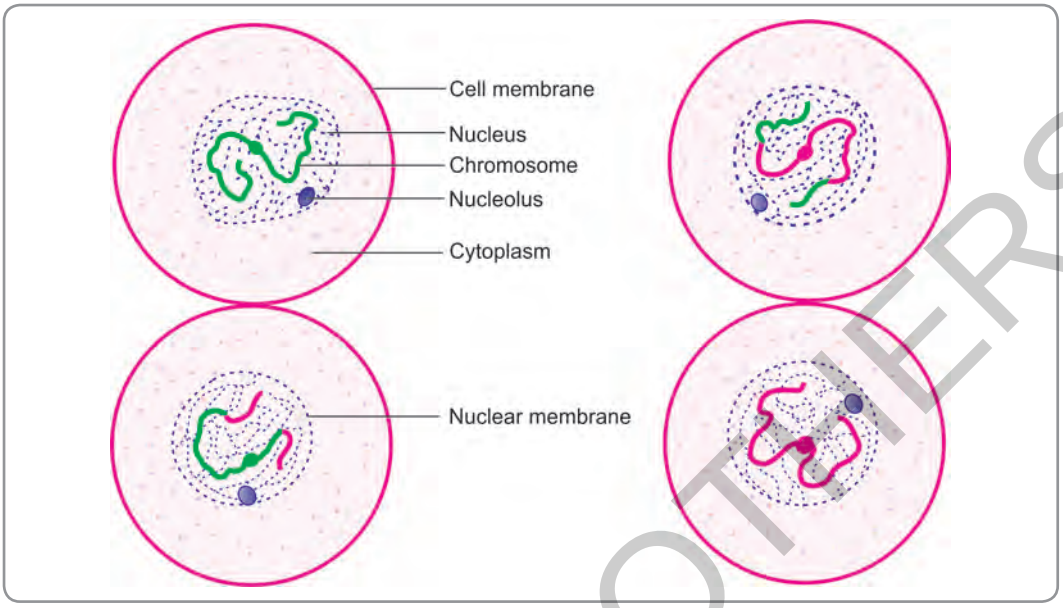

Fig. 2.13: Telophase-II

- They are haploid in nature with 23 single chromosomes
- They have different genetic component from that of mother cell and also differ from each other.

APPLIED ANATOMY

- Numerical abnormalities of chromosomes in the gametes occur due to nondisjunction of a homologous pair during anaphase-I stage or failure of division of centromere in anaphase-II stage
- Structural abnormalities of chromosomes can occur during prophase-I stage due to various reasons as follows:
  - Deletion: A part of a chromosome is lost during exchange of segments
  - Inversion: The exchanged segment is attached in an upside down position
  - Translocation: A segment of a chromosome joins with a nonhomologous chromosome
  - Isochromosome: Centromere divides in the horizontal axis of a chromosome that leads to both short arms on one side and both long arms on other side of the dividing cell. The daughter cells will have loss of some alleles and duplication of some other alleles
  - Ring chromosome: Ends of the short arm as well as the long arm are deleted and the remaining ends get attached, forming a ring shaped chromosome.
- Numerical anomalies of chromosomes can occur during mitotic cell division of a somatic cell
- Highly differentiated cells, e.g. neurons do not undergo cell division. Exception is olfactory neuron, which is formed once in three days
- Abnormal fast rate of cell division leads to malignancy or neoplasm.

JAYPEE BROTHERS

for detailed information on dental books, visit our website **www.jaypeebrothers.com,** for detailed information on dental books, visit our website **www.jaypee**

Essentials of Anatomy *for* Dental Students

Salient Features

- The required basic knowledge of anatomy for dental students is provided
- Simple way of presentation is done for understanding and remembering the facts about human body
- Diagrammatic and photographic pictures of the same histological tissues are given adjacently to help the students understand the details as well as to identify it under the microscope
- Photographs of real bone specimens are given to identify the features of a skull and individual bones of a skull easily. Students will find it easy and comfortable to revise osteology inside or outside the classroom
- Well illustrated diagrams are given along with description in each chapter
- Many Photographs of different clinical conditions are presented
- Multiple choice questions are given for self-assessment by students.

TL Selvakumari MBBS MD is Professor and Head, Department of Anatomy, Sri Venkateswara Dental College and Hospital, Thalambur, Chennai, Tamil Nadu, India. She did her MBBS and MD from Madras Medical College and Sri Ramachandra Medical College and Research Institute, respectively. She has also worked in SRM Dental College, Ramapuram. She is very dedicated and committed professor who has been a source of inspiration to dental students throughout her teaching career.



Available at all medical bookstores or buy online at www.jaypeebrothers.com

JAYPEE BROTHERS
Medical Publishers (P) Ltd.
www.jaypeebrothers.com

Join us on facebook.com/JaypeeMedicalPublishers

Shelving Recommendation
DENTISTRY

ISBN 978-93-5270-354-8