rothers.com, for detailed information on surgery books, visit our website www.jaypeebrothers.com, for detailed information on surgery books

VOLUME 15

SURGERY

Roshan Lall Gupta's

Recent Advances in SURGERY

Editor

Puneet



Contents

Chapter 1	Liver transplantation *Shaleen Agarwal, Subash Gupta*	1
Chapter 2	Gastrointestinal stromal tumors *Vivek Srivastava, Ravi Pandey, Puneet*	21
Chapter 3	Gastroesophageal junction tumors *Rajesh Panwar, Sujoy Pal*	41
Chapter 4	Management options for solid organ injuries *Dinesh Bagaria, Amit Gupta, Subodh Kumar*	64
Chapter 5	*Helicobacter pylori* and duodenal ulcer: What has changed in 35 years from 1982? *N Ananthakrishnan, R Kalayarasan, Mohsina Subair, Vikram Kate*	86
Chapter 6	Sphincter-saving procedures for low rectal cancer *Ashok Kumar, Ajit Kumar Mishra*	108
Chapter 7	Genetic testing in cancer diagnosis *Amit Verma, PK Julka, Jatinder Kaur*	125
Chapter 8	Retroperitoneal sarcoma *Neelesh Jain, Itisha Chaudhary, Durgatosh Pandey*	145
Chapter 9	Revascularization of lower extremity *AK Khanna, Zeeshan Hakim*	168
Chapter 10	Medical management of vascular surgery patients *Himanshu Verma, Ramesh K Tripathi*	192
Chapter 11	Management of ureteric calculi *Sameer Trivedi, Faiz Ahmed Khan*	210

Chapter 12 Ventral hernia 231
Arunima Verma, Sunil Kumar

Chapter 13 Breast imaging 249
Gaurav Agarwal, Namita Mohindra, Neeraj Jain, Selvi Radhakrishna

Chapter 14 Neuroendocrine tumors of pancreas 267
Vikram Chaudhari, Anant Ramaswamy, Manish Bhandare, Shailesh V Shrikhande

Chapter 15 Surgical management of primary hyperparathyroidism 290
Gaurav Agarwal, Kul Ranjan Singh, Gyan Chand

Index *313*

Chapter 2

Gastrointestinal stromal tumors

Vivek Srivastava, Ravi Pandey, Puneet

JAYPEE BROTHERS

INTRODUCTION

Gastrointestinal stromal tumor (GIST) is an uncommon mesenchymal tumor which arise mostly from the gastrointestinal tract. It accounts for 0.1–0.3% of all gastrointestinal neoplasm. These tumors can involve any segment of gastrointestinal (GI) tract, from esophagus to anus. The term GIST was first used in 1983 by Mazur and Clark to encompass gastrointestinal nonepithelial neoplasm that lacked the immunohistochemical features of Schwann cells and did not have the ultrastructural characteristic of smooth muscle cells. There has been considerable debate with regard to its nomenclature and diagnosis, in the past, these tumors were classified as leiomyomas, leiomyosarcoma, and leiomyoblastomas. With the discovery of mutational activation of c-KIT proto-oncogene in GIST by Hirota and colleagues in 1998, GIST has been increasingly thought to be a separate entity from its sarcoma counterpart. These tumors arise from interstitial cells of Cajal (ICC) which serve as a gut pacemaker as they create the basal electrical rhythm leading to peristalsis and segmentation of the smooth muscle. The largest density of these cells occurs within the GI tract, around the myenteric plexus, but they have also been reported to occur outside of the GI tract. The most common site of GISTs occur in the stomach (50–60%), followed by small intestine (30–40%). Colorectal and esophagus are the rare site accounting for 7% and 1%, respectively. The other less common site includes outside GI tract include mesentery, retroperitoneum, and omentum.

INCIDENCE

In the United States, the annual incidence of GIST is estimated between 3.2 and 7 per million. A greater incidence of 15–20 per million has been reported in Europe, Korea, and Hong Kong. The incidence of GIST, defined as the diagnosis of new cases, exponentially increased after 1998. This was

attributable to the discovery that c-KIT and platelet-derived growth factor receptor alpha (PDGFRA) were reliable biomarkers for these tumors. Review of the Surveillance, Epidemiology, and End Results (SEER) data revealed a step-wise increase in the proportion of mesenchymal tumors that were labeled as GIST from 24% in 1999 to 82% in 2002 which further increased to 90% in 2011. Therefore, the true incidence of GIST gradually has been better estimated by routine use of c-KIT and other molecular markers. This increase in incidence therefore marks the increased accuracy with which these tumors are now detected.

Gastrointestinal stromal tumors can arise at any age, but occur predominantly in the middle age or elderly individual with peak incidence in fifth and sixth decades of life. More than 80% GISTs are reported in individuals older than 50 years. However, the few patients who are younger than 20 years (about 0·4%), frequently have GIST associated with a syndrome. Both men and women are affected at a roughly similar frequency except for pediatric GISTs that occur predominantly in girls.

RISK FACTORS

Most of GISTs are sporadic and no risk factors are established. However, it may arise in various tumor syndromes as:

Familial gastrointestinal stromal tumors

Gastrointestinal stromal tumors occurs in the familial form as autosomal dominant. The heritable mutations in KIT exon 8, 11, 13, or 17 are associated with high-risk for developing GIST at an early age. Other associated findings include pigmented skin macules on the perineum, axilla, hands and face, and urticaria pigmentosa. The germline mutations in PDGFRA exon 12 are also at risk of developing GIST.

Carney's triad

The combination of gastric GIST, extra-adrenal paraganglioma, and pulmonary chondroma are known as Carney's triad. It is a nonheritable syndrome in young females. GISTs with Carney's triad patients show loss of expression of succinate dehydrogenase subunit B (SDHB) enzyme. The cause for this enzyme deficiency is unknown, because mutations in genes encoding succinate dehydrogenase subunits are not detected. These patients do not have KIT or PDGFRA mutations.

Carney-Stratakis syndrome

Gastrointestinal stromal tumors associated with Carney-Stratakis syndrome have same characteristic as that of Carney's triad associated GIST but without

JAYPEE BROTHERS

pulmonary chondroma or gender predominance. This syndrome shows autosomal dominant pattern of inheritance with incomplete penetrance.

Type 1 neurofibromatosis (von Recklinghausen's neurofibromatosis)

Gastrointestinal stromal tumors associated with neurofibromatosis type 1 in 5% cases usually presents in adults and is characterized by hyperplasia of interstitial cell of Cajal and multiple small GIST in small intestine without KIT mutations.

Succinate dehydrogenase deficient gastrointestinal stromal tumors: In this type of GIST the main oncogenic mechanism is loss of succinate dehydrogenase complex function instead of mutation in KIT or PDGFRA. It includes pediatric GIST, Carney-Stratakis syndrome and Carney's triad. This type of GIST occurs exclusively in stomach and not in intestine. It accounts for 7.5% of all gastric GIST. Succinate dehydrogenase (SDH) deficient GIST has an early onset and manifest before the age of 40 years. It is very difficult to predict the behavior of SDH deficient GIST. The tumor can be indolent without metastasis or recurrence to those that are metastatic at presentation. The prognosis or risk assessments cannot be made based on mitotic activity and tumor size. Thus, different criteria should be established for this type of tumor in the future.

CLINICAL PRESENTATION

The presentation of the disease is variable and depends on location and size of the tumor. Small tumors are diagnosed as incidental findings (20%) on operation, endoscopy, and imaging procedures for other diseases. Approximately 70% of the patients with GIST are symptomatic. The most common presentation of GIST is gastrointestinal bleeding leading to anemia, hematochezia or melena. It may also present as bleeding into the peritoneal cavity, perforation, obstruction, rupture, and peritonitis. Other nonspecific presentation may be postprandial fullness, bloating, weight loss, pain abdomen, early satiety. They may also present as abdominal lump with or without symptoms depending upon the size. The site-specific symptoms like dysphagia in esophageal lesion, constipation, and obstruction in colorectal or obstructive jaundice in duodenal GIST. Around 10% lesions are detected only during autopsy.

The most common site of metastasis in GIST is liver (65%) followed by peritoneum (21%). Other rare sites of metastasis are lymph nodes, bones, and lungs. Hypoglycemia as a paraneoplastic manifestation secondary to IGF-2 production has been reported. The few types of GISTs need special mention like micro and pediatric GIST. In micro GIST, lesions are less than 1 cm and

JAYPEE BROTHERS

are asymptomatic. The diagnosis is mostly incidental. Pediatric type GIST occurs more commonly in females in infancy or early childhood. These tumors are multifocal with metastasis to lymph nodes and liver. Despite dissemination, survival is good.

PATHOLOGICAL FEATURES

Gastrointestinal stromal tumor size varies from few millimeters to larger than 30 cm. Macroscopically, GIST appears as exophytic, intramural, or intraluminal growth. The exophytic growth may be attached to stomach or bowel and project in the peritoneal cavity displacing adjacent organ without infiltration. Large intramural lesion may protrude intraluminally and may present with ulcerated mucosa in 20–30%. On gross, they are smooth gray and white lesion which are well circumscribed, usually with pseudocapsule. Larger lesions may undergo significant necrosis and cyst formation. Small intestinal GISTs may appear as a diverticulum.

Three morphological patterns are seen in GISTs: spindle cell, epithelioid, and mixed. Spindle cell tumors are more common at all sites. Gastric GISTs on histology show spindle cell morphology in 50%, epithelioid in 30%, and mixed in 20%. Gastric GISTs have a solid or nested form, often with a hyalinized stroma that shows myxoid change. GISTs in the small intestine are more often spindled than epithelioid and may show paragangliomatous pattern. Another characteristic is the eosinophilic structures composed of collagen. Skeinoid fibers seen are extracellular eosinophilic structures composed of tangles of collagen. Colonic and anorectal GISTs appear to be morphologically more similar to intestinal than gastric GISTs, while esophageal GISTs typically resemble their gastric counterparts, usually appearing as cellular spindle cell lesions. Many extragastrointestinal stromal tumor (EGISTs) seem to resemble gastric stromal tumors, often showing an epithelioid morphology and may also show a myxoid stroma and perivascular hyalinization.

GENETICS AND MOLECULAR BIOLOGY

Central to GIST's pathogenesis are two mutations: that of the KIT gene (and its associated overexpression of the KIT receptor tyrosine kinase), and that of the platelet-derived growth factor receptor alpha (PDGFRA) gene. Approximately 95% of GISTs are positive for KIT (CD117), the receptor for stem cell factor (SCF) and 5–7% of GISTs have activating mutations in PDGFRA, the gene encoding a receptor for platelet derived growth factor alpha , which results in constitutive activation of PDGFRA tyrosine kinase activity in the absence of its ligand. The remaining GISTs have no detectable KIT or PDGFRA mutations and are termed wild-type GISTs. In 75% of the cases, the primary mutation is found in exon 11 of the c-KIT gene, which encodes for the juxtamembrane domain of the protein, leading to activation of the receptor regardless of

JAYPEE BROTHERS

the presence of its ligand (SCF). In 15% of cases, mutations are found in exon 9 encoding the extracellular domain. Exons 13 and 17, encoding the kinase domain of the protein are mutated. The exon 11 mutation of c-KIT is commonly present in subset of patients with familial GIST. In PDGFRA gene, most of these mutations (85%) are found in exon 18, encoding for the second kinase domain, and more rarely in exons 12 (juxtamembrane domain) and 14 (first kinase domain). Mutational status of c-KIT has emerged as a major prognostic and predictive factor in patients with GIST.

Approximately 10–15% of GISTs do not show detectable KIT or PDGFRA mutation and are called wild-type tumors. These wild-type GISTs include neurofibromatosis 1 (NF1 gene mutation), Carney-Stratakis syndrome, Carney's triad, BRAF mutation, succinate dehydrogenase subunit mutations (SDHA, SDHB, SDHC, SDHD) and RAS-family mutations. Wild-type GISTs without succinate dehydrogenase activity may have upregulation of hypoxia-inducible factor alpha (HIF 1A).

Approximately, 60–70% GISTs are also positive for CD34 and 30–40% for smooth muscle actin. Other markers are found only rarely, including S100 protein in 5%, desmin in 1–2%, and keratin in 1–2%. Gene microarray analysis has yielded additional markers for GIST, most notably the (FLJ10261) gene also known as discovered on GIST-1 (DOG-1) gene, which is ubiquitously expressed in GIST regardless of mutation status. These have been found to be positive in 97% of GIST and, together with c-KIT, they allow a 100% sensitivity in the detection of GIST. DOG1 antibodies are more sensitive for GIST than KIT antibodies especially in detecting gastric GIST and GIST with PDGFRA mutations. DOG1 immunoreactivity is not seen in other mesenchymal tumors, making this highly specific for GIST. These data have resulted in many centers using DOG1 as the key diagnostic biomarker for GIST.

INVESTIGATION

Preoperative investigations which aid in diagnosis are upper GI endoscopy, contrast-enhanced computed tomography (CECT), magnetic resonance imaging (MRI) and positron emission tomography (PET) scan. Upper GI endoscopy may show the lesion as submucosal mass with or without ulceration. Endoscopic ultrasonography (EUS) is helpful in detecting small lesion less than 2 cm. EUS can delineate the lesion, define the layer of origin and can guide biopsy. But it is of limited use in larger tumor due to small field of view which may underestimate the extent of disease. Endoscopic contrast-enhanced ultrasound is especially valuable for assessment of large gastric, duodenal, rectal, or rectovaginal GISTs. On barium studies, GIST appears as submucosal lesions with smoothly marginated filling defects. An area of central ulceration may be seen. Calcification is a rare finding. Lesions may also extend intraluminally, and shown as filling defect.

JAYPEE BROTHERS

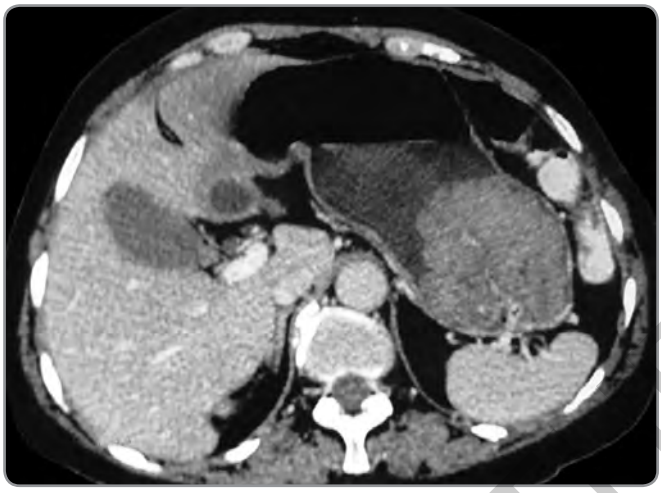

Figure 2.1A Lobulated homogenously enhancing soft tissue intraluminal mass lesion in stomach.



Figure 2.1B Excised specimen of lobulated mass lesion of stomach (histopathology confirms as gastrointestinal stromal tumor).

On contrast computed tomography (CT) scan, they appear as well-defined heterogenous masses with a peripheral enhancing border of variable thickness and central low attenuation represent necrosis, hemorrhage or cystic change (**Figs. 2.1 and 2.2**). However, small number of GIST demonstrate homogenous enhancement, and are typically benign lesion of less than 5 cm size. Large (>10 cm) or recurrent tumors with irregular margin

JAYPEE BROTHERS



Figure 2.2A Large necrotic soft tissue exophytic mass lesion arising from greater curvature of stomach with associated gastric wall thickening.



Figure 2.2B Excised cut open specimen showing tan white fleshy appearance with area of cystic degeneration.

JAYPEE BROTHERS

may have associated aggressive findings as distant or peritoneal metastases. Exophytic growth from stomach may extend to gastrohepatic, gastrosplenic ligaments or lesser sac (**Figs. 2.3A and B**). Tumors tend to enlarge with a smooth border, pushing rather than invading adjacent bowel loops and vessels. GISTs do not metastasize to lymph node. In contrast, lymphoma and adenocarcinoma are usually associated with lymphadenopathy. CT scan is



Figure 2.3A Large exophytic, homogenously enhancing soft tissue density mass lesion arising from lesser curvature of stomach, suggestive of gastrointestinal stromal tumor.

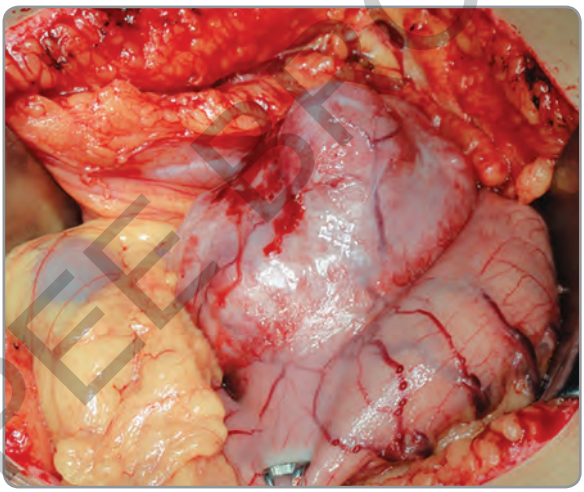

Figure 2.3B Operative photographs show large exophytic mass lesion arising from lesser curvature stomach.

JAYPEE BROTHERS

also useful in determining the site of origin of large tumors, adjacent organ and major vessel involvement (**Fig. 2.4**). Anorectal GIST may present as well-defined mural mass that expands the rectal wall.

Magnetic resonance imaging may also be used for staging and restaging, especially in younger patients to avoid exposure to repeated ionizing radiation. But the drawback of using MRI is that it is difficult to detect mesenteric metastatic disease due to the absence of oral contrast and the issue with respiratory gating. In GIST, solid components of the tumors are



Figure 2.4 Exophytic, smoothly marginated mass lesion arising from jejunum. Central lumen of the lesion show oral contrast opacification.

typically low signal on T1-weighted images, high signal on T2-weighted images and enhance following gadolinium. However, signal intensity at MRI may be variable due to necrosis, hemorrhage, and cyst formation.

Gastrointestinal stromal tumors are PET avid tumors because the receptor tyrosine kinase increases the glucose transport protein signaling. PET scan can detect small metastases which can even not picked up on CECT. It is also helpful in differentiating an active tumor from necrotic or inactive scar tissue. Changes in the metabolic activity of tumors precede anatomic changes detected on CECT, thus PET may be used to assess the response to tyrosine kinase inhibitor (TKI) therapy. The surveillance after resection is routinely not recommended with PET.

Preoperative imaging is done to evaluate the need for neoadjuvant, adjuvant therapy, and to determine the extent of resection. The risk of metastasis is higher in large size tumor with high mitotic index but small size tumor with low mitotic index may also metastasize. So, it is difficult to predict malignant potential of the tumor. The clinical diagnosis is based on imaging because the biopsy has the risk of hemorrhage, rupture of tumor and seeding of tract. Features of high-grade GIST includes liver metastasis, GI wall infiltration, large tumor volume, irregular surface, ill-defined margin, inhomogeneous enhancement, ascites, and peritoneal spread. Metastatic lymphadenopathy is not a typical feature of GIST, and if seen, an alternate diagnosis should be considered. About 50% patient present with metastatic disease at diagnosis. The liver is the most common site for metastasis followed by mesentery. The peritoneal surfaces are also a common site for metastatic disease following extension of the primary tumor beyond the serosa. Arterial, portal, and venous phase imaging is important because liver metastasis is

JAYPEE BROTHERS

hypervascular in arterial phase, washes out on venous phase and may be relatively occult in the portal venous phase.

MANAGEMENT

The treatment of choice for primary GISTs remains complete surgical resection with negative margins (R0 resection). The macroscopic margin of 1–2 cm is sufficient to achieve microscopically negative margins. Precaution is taken not to rupture tumor pseudocapsule as large lesions are typically soft, fragile with thin capsule. GISTs usually have exophytic growth without infiltrating the organ from which they arise. Similarly, they push the adjacent structure rather infiltrating them. Thus, wedge resections of the stomach and segmental resections of the small bowel are adequate (**Fig. 2.5**). Sometimes excision of mass with removal of neighboring organs or "block excision" becomes necessary then also a multivisceral resection should be avoided. Endoscopic removal is not recommended on esophagus and gastric tumors because of the difficulty to get R0 complete resections. Spontaneous or intraoperative capsule rupture should be considered as a very poor prognostic factor and hence should be avoided in all cases. All cases in which capsule break are best considered as disseminated lesion and all of them will relapse as disseminated unresectable peritoneal disease. Thus, all cases with capsular rupture are candidate for imatinib treatment. Preoperatively unresectability can be detected on CT demonstration of infiltration celiac trunk, superior mesenteric artery or to portal vein. Lymph node dissection is generally not indicated as lymph node metastases are rare. However, in pediatric, syndromic type and SDH deficient GISTs arising in young individual has lymph node metastases in 20–59% cases.

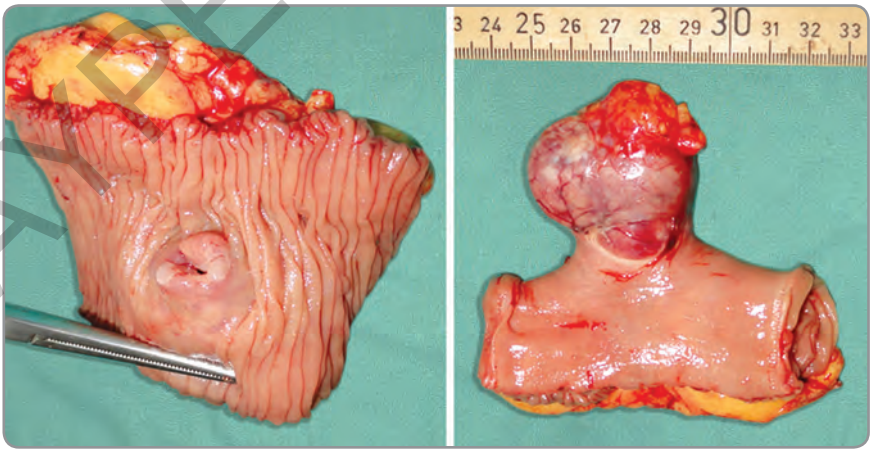

Figure 2.5 Excised specimen of ileal gastrointestinal stromal tumor, as exophytic growth from antimesenteric border. Intraluminal surface show submucosal tumor mass with central umbilication and ulceration.

JAYPEE BROTHERS

It is uncertain whether residual microscopic disease at resection margins (R1 resection) will affect outcome or not. Therefore, re-resection is recommended only when the site of microscopic disease left behind can be identified and operative procedure has no major morbidity. However, in very low to low-risk tumor, the wait-and-watch approach as opposed to aggressive surgery with permanent damage is recommended.

A laparoscopic approach may be considered for tumors in favorable anatomic locations by expert surgeons, only in situations where a complete resection without capsule rupture is feasible, and should be removed in a plastic bag. In this regard, a laparoscopic approach is strongly discouraged in patients with voluminous tumors.

The management of small gastric GIST (less than 2 cm) discovered incidentally is controversial. In the absence any high-risk features as diagnosed on EUS (echogenic foci, ulceration, irregular margins), some surgeons advocate serial monitoring of lesion with imaging or endoscopy. The endoscopic resection has disadvantage of positive margin, perforation, and tumor spillage. According to the current National Comprehensive Cancer Network (NCCN) guidelines for small gastric GISTs (less than 2 cm) in absence of high-risk features on EUS should have surveillance endoscopy done every 6–12 months.

Neoadjuvant treatment

In locally advanced and unresectable GIST, there are few cases that would eventually become resectable after induction treatment with imatinib. However, a cytoreductive treatment with imatinib can be attempted only for those GISTs where present location and size warrants a mutilating surgery. Preoperative imatinib should be considered when an extended procedure such as a Whipple's operation for duodenal GIST or abdominoperineal excision for rectal GIST is needed to remove the tumor. Imatinib is effective in reducing the size of the tumor prior to resection, increasing the likelihood of negative margins without significant morbidity. Early response assessment is needed, since surgery delay could hamper long-term results after an unsuccessful imatinib treatment. Mutational analysis should be mandatory due to the robust predictive value of some genotypes. Hence, exon 9 mutants would require 800 mg/day of imatinib; no induction treatment would be active in D842V mutants and it is doubtful that imatinib could be useful as an induction preoperative treatment for PDGFRA mutated and wild-type cases. A CT scan can suffice for early response assessment, but PET-scan seems advantageous given its ability to verify the efficacy of the treatment within a very short time. The recommended duration of preoperative treatment cannot be based on objective criteria. However, it is estimated that surgery could be performed within 6–12 months after starting imatinib, since maximal response and minimal risk of secondary resistance is expected in

JAYPEE BROTHERS

this time interval. GISTs of rectum or rectovaginal septum are not treated with local excision unless preoperative imatinib shrinks the tumor.

Prognostic factors and risk assessment

Researchers have examined many potential indicators of prognosis for GISTs over the years, including site, size, histomorphology, immunohistochemistry, and molecular genetics. The majority of GISTs (60–70%) are benign. An assessment of malignancy is based on tumor size, mitotic index (number of mitoses per 50 high power fields), and spreading outside the gastrointestinal tract. GISTs with high mitotic activity (greater than 50 mitoses per high power field) are considered high-grade and demonstrate aggressive behavior. Immunostaining for the Ki-67 antigen has been suggested as an alternative for mitosis counting. Tumor rupture before or during surgical procedure are identified as independent prognostic factors for recurrence. Gastric GISTs have a lower risk of recurrence compared with non-gastric GISTs. Small bowel GISTs appear to follow a more aggressive course, compared to gastric tumors of the same size.

The two main classification systems, the Fletcher and Miettinen, consisting of prognostic factors such as primary site, size, and mitotic index, facilitate the stratification of patients into low-, intermediate-, and high-risk groups of recurrence. In 2002 an index for assessment of risk factors was proposed by National Institute of Health (NIH) Consensus group [Fletcher et al] which was based on number of mitosis per 50 high power fields (HPF) and the size of the primary tumor (**Table 2.1**).

Miettinem et al. studied the risk assessment, based on size of the primary tumor, mitotic index and anatomic site (**Table 2.2**). This better reflects the high-risk population especially between the intermediate and low-risk groups. The risk of gastric cancer relapse varies from 2% in tumors with less than 5 mitosis per 50 HPF to 90% in GI tract GIST with tumor size more than 10 cm and less than 5 mitosis per 50 HPF.

Two nomograms have been proposed for risk estimation. Prognostic heat maps and contour maps which are based on nonlinear modeling of tumor size, mitotic count, tumor site, and rupture.

Adjuvant treatment

Recurrence rate of up to 50% is seen despite the fact that complete resection is feasible in most localized GIST cases. Imatinib is an oral, selective, small-molecule tyrosine kinase inhibitor, which targets the KIT protein and the PDGFRA. Its role as adjuvant treatment to prevent recurrence has been assessed in several American and European clinical trials like ACOSOG (American College of Surgeons Oncology Group) Z9001, SSGX-VIII/AIO, and EORTC 62024/GEIS-10 study. The studies have clearly shown a relapse-free survival (RFS) benefit with imatinib.

JAYPEE BROTHERS

Table 2.1: Risk group according to Fletcher et al.

Risk	*Size*	*Mitotic index (50 HPF)*
Very low-risk	≤2 cm	<5 mitosis
Low-risk	2–5 cm	<5 mitosis
Intermediate-risk	≤5 cm	6–10 mitosis
	5–10 cm	≤5 mitosis
High-risk	>5 cm	>5 mitosis
	>10 cm	Any number of mitosis
	Any size	>10 mitosis.

(HPF: High power fields).

Table 2.2: Risk group according to Miettinen et al.

Risk	*Size*	*Mitotic index (50 HPF)*	*Location*
Very low-risk	2–5 cm	≤5 mitosis	Gastric
Low-risk	≤10 cm	≤5 mitosis	Gastric
	2–5 cm	≤5 mitosis	Intestinal
Intermediate-risk	>10 cm	≤5 mitosis	Gastric
	≤10 cm	≤5 mitosis	Intestinal
	2–5 cm	>5 mitosis	Gastric
High-risk	2–5 cm	>5 mitosis	Intestinal
	>10 cm	≤5 mitosis	Intestinal
	≤10 cm	>5 mitosis	Gastric
	>10 cm	>5 mitosis	Gastric
	≤10 cm	>5 mitosis	Intestinal
	>10 cm	>5 mitosis	Intestinal.

(HPF: High power fields).

Imatinib was approved by the US Food and Drug Administration (FDA) and the European Medicine Agency (EMA) in 2008 and 2009, respectively to be used as adjuvant therapy for high-risk patients following complete surgical resection of GIST at a daily dose of 400 mg. Moreover, the SSGX-VIII/AIO study showed an increase of overall survival (OS) with 3 years of imatinib administration for over 1 year in high-risk patients.

In view of these results, both NCCN and European Society for Medical Oncology (ESMO) guidelines as well as consensus of the scientific community, recommend 3 years of adjuvant treatment with imatinib in high-risk patients. However, the optimal duration of therapy remains to be established. There are still many unclear areas concerning duration of adjuvant treatment to 5 years of imatinib in the highest risk tumors, defined as gastric GIST with

JAYPEE BROTHERS

detailed information on surgery books, visit our website **www.jaypeebrothers.com,** for detailed information on surgery books, visit our website

Roshan Lall Gupta's Recent Advances in SURGERY-15

Salient Features

- Latest topic with advances in the field of surgery covered
- Focused for young budding surgeons and postgraduate students
- Chapters are written by eminent surgeons and experts in their field
- Chapters tried to cover all relevant topic from each speciality
- Topic may change the clinical surgical practice with latest review



Puneet MS DNB (Surg) MNAMS FACS has completed his graduation and postgraduation from Institute of Medical Sciences, Banaras Hindu University, Varanasi, Uttar Pradesh, India. He has obtained DNB in Surgery from National Board of Examination and worked as Senior Registrar in Dr Ram Manohar Lohia Hospital, New Delhi, India. Thereafter, he has worked in different hospitals in various capacities. He was appointed as Assistant Professor in King George Medical College (KGMC), UP state colleges and Institute of Medical Sciences, Banaras Hindu University, Varanasi, Uttar Pradesh, India. However, he decided to join his alma mater. He has been elevated to Associate Professor, and then Professor in the Department of Surgery, Institute of Medical Sciences, Banaras Hindu University, Varanasi, Uttar Pradesh, India.

Professor Puneet has presented various papers and delivered lectures in India and abroad. He has best paper award and travelling fellowships to his credit. He has done his fellowship in hepatobiliary and pancreatic surgery from Queen Elizabeth Hospital, Birmingham, UK. He has published more than 65 National and International papers, authored/edited 5 books and written 16 chapters in various publications. He has been investigator to various research projects and reviewers to journals. He is also Fellow of American College of Surgeons, Chicago and Recipient of Citation from Oklahoma, USA.

Available at all medical bookstores or buy online at www.jaypeebrothers.com

JAYPEE BROTHERS Medical Publishers (P) Ltd.
www.jaypeebrothers.com

Join us on facebook.com/JaypeeMedicalPublishers

Shelving Recommendation
SURGERY

ISBN 978-93-5270-363-0

9 789352 703630