Manual of
Hysteroscopy

Editors
SN Tripathy
KC Mahapatra
SK Giri
Sunita Tandulwadkar
Sujata Swain

61st AICOG 2018 BHUBANESWAR

61st All India Congress of
Obstetrics & Gynaecology
17–21 January 2018

Organized by:
The Odisha Obstetric
and Gynaecological Society
Under the Aegis of FOGSI

Contents

1.	**Operation Theater Setup and Instruments Used in Hysteroscopy** *HP Patnaik*	**1**
2.	**Ideal Anesthesia for Hysteroscopy** *Nibedita Pani, Srimanta Haldar*	**13**
3.	**Basic Principles in Operative Hysteroscopy** *S Krishnakumar, Rohan Krishnakumar*	**18**
4.	**Microhysteroscopy, Contact Hysteroscopy and Office Hysteroscopy** *Sujata Swain*	**29**
5.	**Hysteroscopic Evaluation of Infertile Couple** *PC Mahapatra*	**37**
6.	**Hysteroscopy in Abnormal Uterine Bleeding** *Nahata VS, Bhardwaj F, Mittal M*	**47**
7.	**Hysteroscopic Removal of Intrauterine Contraceptive Devices and Foreign Bodies** *Abhishek Chandavarkar, Priyanka Suhag, Madhura Chandavarkar*	**54**
8.	**Role of Hysteroscopy in Müllerian Anomaly** *Rabi Narayan Satpathy*	**57**
9.	**Hysteroscopic Myomectomy** *Malvika Sabharwal*	**64**
10.	**Transcervical Resection of Uterine Septum** *Parul Kotdawala*	**71**
11.	**Complications of Hysteroscopic Surgery** *Sujata Kar*	**78**
12.	**Hysteroscopic Contraception** *Polly Chatterjee*	**86**

Chapter 2

Ideal Anesthesia for Hysteroscopy

Nibedita Pani, Srimanta Haldar

BACKGROUND

Use of the hysteroscope in modern gynecological practice continues to develop as a diagnostic and management tool for intrauterine disease. Operative hysteroscopy (OH) is now an accepted alternative to hysterectomy for women with menorrhagia. The advantages of OH are associated with its short operating time, rapid postoperative recovery and low morbidity. However, there are concerns about the potential serious complications which can occur during and following OH, and it is important that both surgeons and anesthetists are aware of these—especially as many procedures take place as day-cases.

ANESTHETIC CONSIDERATIONS

- Fluid overload leading to hyponatremia and hypo-osmolality
- Glycine toxicity
- Hemorrhage
- Hypothermia
- Uterine perforation
- Gas or air embolism
- Patient positioning to prevent peripheral neuropathy
- Prevention of sepsis.

CHOICE OF ANESTHESIA

The type of anesthesia used depends on the procedure, the patient's level of anxiety, the surgeon and anesthesiologist's expertise. Simple diagnostic procedures can be completed with monitored anesthesia care with paracervical block or intrauterine local anesthesia. But for extensive procedures or for patients with a low pain tolerance or electrosurgery, general anesthesia (GA) or regional anesthesia is indicated to ensure that the patient does not move with uterine stimulation to avoid the risk uterine perforation and intraperitoneal injury.

JAYPEE BROTHERS

PREANESTHETIC ASSESSMENT

History and Examination

Cardiovascular: Hypertension, ischemic heart disease (IHD) and arrhythmias (particularly atrial fibrillation) are common. Patients with recent onset or poorly controlled heart failure have the highest perioperative mortality.

Respiratory: Marked decrease in functional ability (e.g. inability to climb one flight of stairs) suggests severe disease. Inability to lie flat because of dyspnea from cardiac or respiratory causes will make awake regional anesthesia poorly tolerated.

Neurological: Confused patients may be not lie still during spinal anesthesia.

Musculoskeletal: Degenerative changes in the vertebral column may make subarachnoid block (SAB) technically difficult. Arthritic joints or joint replacements are susceptible to damage or dislocation when the patient's legs are placed in the lithotomy position for the procedure.

Renal impairment if present may deteriorate due to fluid overload.

Airway: Even if SAB is planned perform a full anesthetic assessment (e.g. anticipated airway difficulties) in case the regional technique fails or is inadequate.

Investigations: Full blood count or hemoglobin level, blood glucose, electrolytes and creatinine and electrocardiogram (ECG). Chest X-ray (CXR) if indicated.

GENERAL ANESTHESIA

Advantages

The advantages of GA are:

- Patients with chest disease may not tolerate lying flat or be able to suppress their cough
- No time constraints. Suitable for lengthy procedures
- May be less hemodynamically challenging than SAB in patients with cardiac problems such as aortic stenosis (and other fixed output states) and IHD
- Allows better control of CO_2, which may reduce bleeding from the uterine bed
- Preferred for patients with low pain tolerance and anxiety
- Preferred for extensive surgeries and when concurrent laparoscopy is to be performed.

Risks

Lithotomy, head-down reduces tidal volume (Vt) and functional residual capacity (FRC). Position also increases the risk of aspiration. Under light planes of GA, uterine stimulation can interfere with surgery—this can be managed by deepening anesthesia. Postoperative analgesia will be needed.

JAYPEE BROTHERS

REGIONAL ANESTHESIA

The advantages of the regional technique include:

- Early detection of complications such as fluid overload and uterine perforation
- Possible reduced blood loss, requiring fewer transfusions
- Avoids effects of GA on pulmonary pathology
- Good early postoperative analgesia
- Reduced incidence of postoperative deep venous thrombosis (DVT)/ pulmonary embolism (PE)
- Lower cost.

SPINAL ANESTHESIA

Low spinal anesthesia (with or without intrathecal opioid) achieving a block up to T10 level for the management of patients undergoing OH may offer, in addition to a reliable block and stable hemodynamics, less operative cognitive impairment, a low incidence of side effects, good intraoperative and postoperative analgesia, and acceptable patient satisfaction without prolonging recovery room discharge.

PARACERVICAL BLOCK

Innervation of the uterus and cervix is complex. Major autonomic nerves arise from the S2 to S4 roots and travel to the uterus in the lower portion of the broad ligament as the Frankenhäuser plexus. Interruption of this plexus is the basis of the paracervical block. However, the uterus is richly innervated with nerves that originate at other points as well. Alternative methods of local anesthesia targeting other nerve plexuses may improve pain management in procedures.

Common anesthetic agents are 1% lidocaine, mepivacaine, prilocaine, ropivacaine, bupivacaine, and etidocaine. Of these, bupivacaine and etidocaine have longer durations and can last upward of 2–3 hours.

A recent study suggests that paracervical ropivacaine controls intraoperative pain slightly better than lidocaine during surgical abortions. In most cases, 10 mL of bupivacaine 0.25%, mepivacaine 1%, or lidocaine 1–2% is an adequate volume for paracervical anesthesia.

Risks

Bradycardia and hypotension.

INTRAUTERINE ANESTHESIA

The effectiveness of intrauterine anesthetic is related to the origin and pathways of uterine innervation. While the Frankenhäuser plexus in the lower broad ligament is the most well-known nervous pathway, the uterus, cervix and

JAYPEE BROTHERS

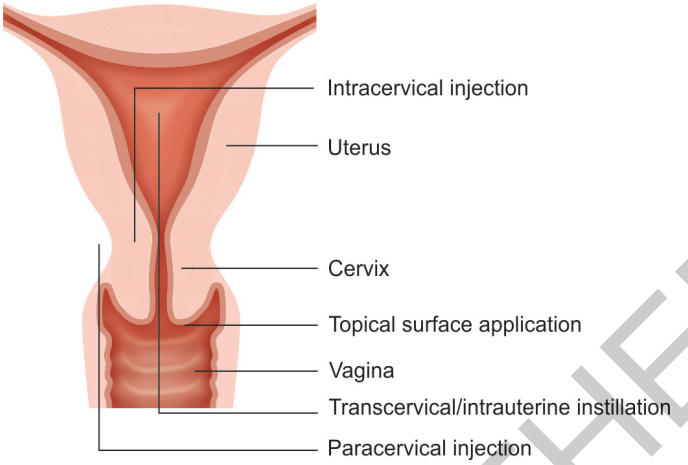

Fig. 1: Different methods of administration of local anesthetic for outpatient hysteroscopy.

fallopian tubes receive nerve supply from other sources as well. Sympathetic innervations from the T10 to L1 roots enter the uterus with the utero-ovarian vessels and follow a variable course, with branches following the anastomoses of the uterine artery. Well-defined nerve plexuses lie in the endometrium and along the mucosal surface of the cervix, and are fed by both the ascending and descending roots; the precise pattern of innervation varies with pathologic processes such as endometriosis and adenomyosis. The limited efficacy of the paracervical block in many gynecologic procedures is likely due to its inability to block these nerves of other origins. Intrauterine anesthesia may reach these nerves more effectively and, alone or in conjunction with paracervical block, provide more global uterine anesthesia (Fig. 1).

Advantages

Administering intrauterine anesthesia prior to an office procedure is an effective, low-cost, and low-risk intervention. Administration is generally simple, and seems less painful for patients than injection of a paracervical block. Good effect on pain is most consistently seen with doses at or equivalent to 100–200 mg of lidocaine.

Risks

Inadequate anesthesia and local anesthesia toxicity.

POSTOPERATIVE COMPLICATIONS

Hypothermia, hypotension, hemorrhage, septicemia and signs and symptoms of fluid overload can all present in the recovery room. Patients may become acutely hypotensive after lowering their legs from the lithotomy position

JAYPEE BROTHERS

because the reduction in venous return. Severe, persistent or unexpected pelvic/abdominal pain, heavy vaginal bleeding and hypotension indicate uterine perforation. The symptoms of this may be masked by residual SAB.

CONCLUSION

Today, the ideal anesthesia for outpatient hysteroscopy is still being sought. However, it appears that the use of combined local intracervical and direct intrauterine anesthesia is effective for office hysteroscopy while GA/regional anesthesia is still the preferred technique for extensive hysteroscopic procedures.

BIBLIOGRAPHY

1. Agdi M, Tulandi T. Outpatient hysteroscopy with combined local intracervical and intrauterine anesthesia. Gynecol Obstet Invest. 2010;69:30-2.
2. Mercier RJ, Zerden ML. Intrauterine anesthesia for gynecologic procedures: a systematic review. Obstet Gynecol. 2012;120(3):669-77.
3. Murdoch JA, Gan TJ. Anesthesia for hysteroscopy. Anesthesiol Clin North America. 2001;19(1):125-40.
4. Mushambi MC, Williamson K. Anaesthetic considerations for hysteroscopic surgery. Best Pract Res Clin Anaesthesiol. 2002;16(1):35-52.

JAYPEE BROTHERS

Available at all medical bookstores
or buy online at www.jaypeebrothers.com

JAYPEE BROTHERS
Medical Publishers (P) Ltd.
www.jaypeebrothers.com

Join us on facebook.com/JaypeeMedicalPublishers

Shelving Recommendation
OBSTETRICS & GYNECOLOGY

ISBN 978-93-5270-369-2