Manual of
Infertility

Editors
SN Tripathy
KC Mahapatra
SK Giri
Nandita Palshetkar
Babita Panda



61st All India Congress of
Obstetrics & Gynaecology
17–21 January 2018

Organized by:
The Odisha Obstetric
and Gynaecological Society
Under the Aegis of FOGSI

Contents

1.	**Approach to Infertile Couple: Basic Evaluation Protocol** *Sujata Pradhan*	1
2.	**Methods of Tubal Evaluation in Infertility** *Saubhagya Kumar Jena, Subhashree Rout*	4
3.	**Evaluation of Female Infertility** *Supriya Pani*	10
4.	**Ovarian Hyperstimulation Syndrome and it's Management** *Anuradha Tibrewal*	14
5.	**Role of Tubal Reconstructive Surgery in the Era of ART** *Babita Panda*	17
6.	**Role of Pre-IVF Hysteroscopy** *Raju Nair*	20
7.	**Sperm Function Tests and Its Implications** *Lilavati Guru*	23
8.	**Optimizing Outcome in IUI Cycles** *Sujata Pradhan*	27
9.	**Genetic Testing of Male Factor Infertility** *Kanchana Devi*	30
10.	**Social and Cultural Consequences of Being Childless** *Taswin Kaur, Kamini Rao*	33
11.	**Stress in Infertility** *Siddhartha Chatterjee*	37

Chapter 2

Methods of Tubal Evaluation in Infertility

Saubhagya Kumar Jena, Subhashree Rout

INTRODUCTION

Evaluation of the Fallopian tubes is an essential part of a fertility workup, as tubal pathology is the cause of subfertility in 25–35% of subfertile couples.[1] Fallopian tubes are not just tubular portals, but are motile structures and have peristalsis. The tubo-ovarian relationship, tubal function in the form of tubal peristalsis, and fimbrial function are as important as patency of the Fallopian tubes for preservation of fertility. Thus, it is required to evaluate both tubal patency and potency.

Several investigations have been used since decades to evaluate the tubal patency. Only few of them can detect tubal potency. In most of the infertility evaluation guidelines, tubal evaluation is the last step. The guidelines are not in agreement on the most effective diagnostic scenario for tubal evaluation. There is no consensus on which test should initially be used and sequence of tests.[2-5]

METHODS

Various nonsurgical and surgical investigative modalities have been reported to assess Fallopian tubes. An ideal test should correctly identify all women with tubal disease with minimal false-negative test results. Further, the tests should be cost-effective, well tolerated by the patient, and should not have any complications. However, such an ideal investigation is yet to be found. Therefore, various tests have been tried to assess the tubal status. While nonsurgical techniques such as hysterosalpingography (HSG) and ultrasound-based techniques like saline-infusion sonography (SIS) and hysterocontrast sonosalpingography (HyCoSy) are less invasive and associated with less serious risks than surgical technique such as laparoscopy and dye test (Chromopertubation). Though, the latter is considered the gold standard for

JAYPEE BROTHERS

Flowchart 1: Decision making pathway for choice of tubal evaluation.

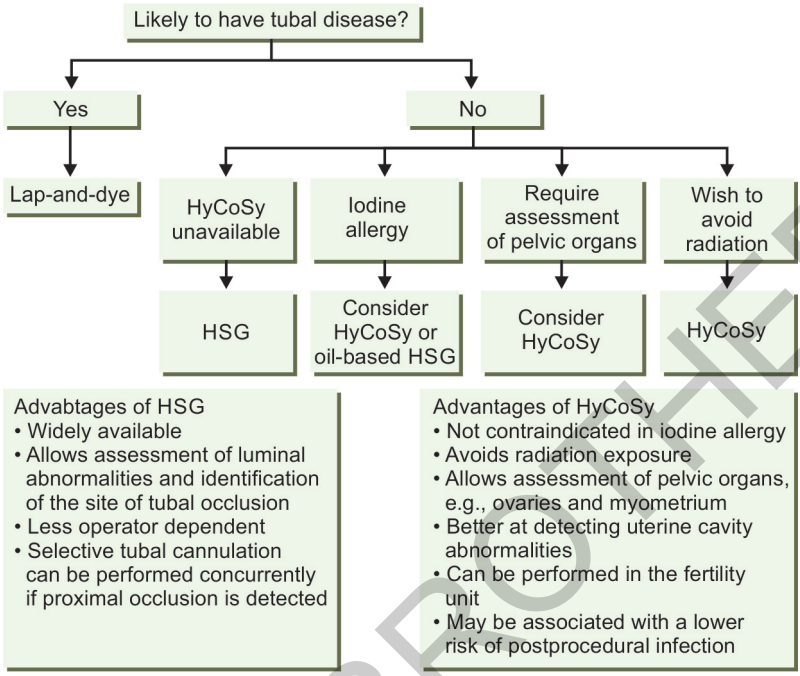

(HSG: hysterosalpingogram; HyCoSy: hysterocontrast sonosalpingography)

assessment of tubal patency and pathology. The decision making for choice of tubal evaluation is described in Flowchart 1.

Hysterosalpingogram

It is safe, less expensive, widely available, and fairly accurate in detecting proximal tubal disease. Due to the longevity of its use, it has the largest evidence base to rule out unilateral or bilateral tubal block. The test may potentially be associated with increased pregnancy rates. Though HSG has been used for several years for tubal assessment and it has been shown in meta-analysis based on three studies gave pooled estimates of sensitivity and specificity for HSG as a test for tubal obstruction of 0.65 [95% confidence interval (CI): 0.50–0.78) and 0.83 (95% CI: 0.77–0.88), respectively. Tubal block seen on HSG will be confirmed by laparoscopy in only 38% of the women.[6] When HSG suggests that the tubes are patent, this will be confirmed at laparoscopy in 94% of the women and thus, HSG is a reliable indicator of tubal patency. These findings imply that after abnormal HSG, even in cases of bilateral pathology such as obstruction, it is still worth performing laparoscopy because, in a considerable number of these patients, the laparoscopic diagnosis allows intrauterine insemination (IUI) treatment to remain an option.[7] Due to widespread availability, it is a good screening test to rule out unilateral or bilateral tubal block. Limitations include failed catheterization or instrumentation and/or

JAYPEE BROTHERS

incomplete seal around the cervix, false positive due to tubal spasm or debris and reporting errors. The ideal time for the test is menstrual cycle day 7–12 (i.e. after the end of menstruation but before ovulation). Radiation exposure from this is significantly higher than that of a standard chest X-ray and there is a 1–3% risk of pelvic infection.[8]

Sonosalpingography

In ultrasound, the Fallopian tubes can be identified only when there is fluid in the tubal lumen or outside the tubes. Fluid can be introduced using a catheter through cervix to visualize and assess the Fallopian tubes by transvaginal ultrasound. The various methods are SIS, HyCoSy and hysterosalpingo-foam sonography (HyFoSy). In HyFoSy, a nonembryotoxic gel containing hydroxyethyl cellulose and glycerol is instilled.[9] HyFoSy allows a more accurate diagnosis of tubal patency compared with HyCoSy.[10] Several modifications have been made to the basic procedure of SIS to improve its diagnostic accuracy as an investigative modality for tubal assessment. The reported modifications are using pulse Doppler and color Doppler, combining air and saline, and three-dimensional (3D) saline SSG.[1]

The accuracy of SIS compared to chromopertubation varies from 81.82% to 100% respectively.[1] The agreement of transvaginal salpingosonography compared with X-ray HSG was 94%, the sensitivity 50%, the specificity 97%, the positive predictive value (PPV) 50%, and the negative predictive value (NPV) 97%.[11] Results of SSG correlated positively with laparoscopy is 97%. SSG and HSG showed 93% correlation.[12] HyCoSy is accurate in determining tubal patency and evaluating the uterine cavity and can supplant HSG as the first-line diagnostic test in an infertility workup.[13] The shortcoming of the procedure is that even when patency of individual tube can be confirmed, it does not give any information about the site of the block, condition of the lumen, and tubo-ovarian relationship.[14]

Laparoscopy

Currently, laparoscopy is the gold standard method. Common indications are abnormal HSG, history or symptoms suggestive of pelvic disease, previous tubal surgery, long-term infertility (>5 years), and age more than 30 years. It has certain advantages like visualization of all pelvic organs with detection and potential concurrent treatment of—(1) intramural/subserosal fibroids, (2) peritubal/periovarian adhesions, (3) endometriosis, (4) tubal constructive surgery, and (5) can be combined with salpingoscopy and/or hysteroscopy.[15-16] However, it requires general anesthesia in most cases and is associated with a 0.13% risk of bowel, urological, or vascular complications.[17]

JAYPEE BROTHERS

Salpingoscopy

Endoscopic visualization of distal tube and ampullary mucosa through distal end. It assesses internal tubal anatomy like—(1) adhesions, (2) loss of mucosal folds, (3) debris, (4) foreign bodies, and (5) abnormal vessels. Classification of salpingoscopic findings by *Brosens and Putteman*:

- *Class-I*: Normal mucosal folds
- *Class-II*: Distended fold pattern
- *Class-III*: Focal lesions like (adhesions, polyp, and strictures)
- *Class-IV*: Extensive lesions like (adhesions, polyp, and strictures)
- *Class-IVa*: With preservation of mucosal folds
- *Class-IVb*: With partial destruction of mucosa
- *Class-V*: Complete loss of pattern.

Falloposcopy

It uses hysteroscopy to introduce flexible scope through tubal ostia to assess proximal Fallopian tube. It is therapeutic with 50% recanalization of blocked proximal tubes.

Transvaginal Hydrolaparoscopy

This procedure involves insufflation of the pelvis with 0.4–0.6 liters of a fluid medium through an insufflating needle inserted into the posterior fornix, followed by the introduction of a small diameter rigid angled endoscope to visualize the pouch of Douglas (POD), pelvic side-walls, adnexa, and tubal patency (the dye injected transcervically). The test is performed in an outpatient setting under local anesthetic and minor operative procedures such as ovarian drilling, adhesiolysis, diathermy to endometriosis, and salpingostomy can be performed through the operative channel.[18] The single biggest risk is bowel injury, either at the time of insufflation or introduction of the endoscope. Pooled data from large case series (n = 4,232) report a rectosigmoid injury rate of 0.61%, all of which were managed either by primary repair or conservatively with no long-term sequelae.[19] The complication rate is much higher than that observed with laparoscopy and the test is not suitable for women with significant obliteration of POD due to pelvic inflammatory disease (PID), endometriosis, and fibroids.

Fertiloscopy

It is an outpatient technique that combines hysteroscopy, transvaginal hydrolaparoscopy (TVHL), and salpingoscopy.[20] A prospective multicenter study (n = 92) reported a high degree of concordance between fertiloscopy

JAYPEE BROTHERS

and laparoscopy.[21] Fertiloscopy was performed first, followed by laparoscopy, by two separate operators chosen by random allocation. Videotape findings of the procedures were reviewed by two other central independent observers to resolve differences. Only 20% of women had normal findings, whereas the remainder (80%) had minor abnormalities.

Chlamydia Antibody Test

Chlamydia trachomatis is the single largest cause of acquired tubal pathology and evidence of both current and past infection can be easily measured using *Chlamydia trachomatis* antibody test (CAT). The sensitivity (21–90%) and specificity (29–100%) vary depending on the cut-off value used to define a positive result.[22] A recent meta-analysis is evaluating the accuracy of three different CAT assays, reported a significantly better performance of MIF (microimmunofluorescence) compared to ELISA (enzyme-linked immunosorbent assay) or IF (immunofluorescence) assays.[23] The negative predictive value of the CAT is 92%, from which can be concluded that the CAT is a good test to rule out tubal pathology.[24]

CONCLUSION

Tubal evaluation is essential in subfertile patients. Due to lack of consistency on the reported accuracy and predictive capacity of tubal patency tests, the clinical application of these tests varies widely between different centers. HSG has been used for a long time for assessment of tubal patency and is considered as the traditional standard for outpatient tubal patency testing in patients who are at low risk for tubal disease. SIS has been proved to be reliable technique for tubal evaluation. Its diagnostic accuracy can be improved using pulse Doppler and color Doppler. Introduction of ultrasound contrast media and HyCoSy have improved the visibility of the tubal lumen. HyCoSy is accurate in determining tubal patency and evaluating the uterine cavity, suggesting it could supplant HSG not only as the first-line diagnostic test in an infertility workup. HyFoSy allows a more accurate diagnosis of tubal patency compared with HyCoSy. But laparoscopy and dye test remain the gold standard among tubal patency tests until a suitable noninvasive test is available.

REFERENCES

1. Rajesh H, Lim SL, Yu SL. Hysterosalpingo-foam sonography: patient selection and perspectives. Int J Womens Health. 2017;9:23-32.
2. ASRM Practice Committee Reports. Optimal evaluation of the infertile female. Fertil Steril. 2006;86 (5 Suppl 1):S264-7.
3. National Institute for Clinical Excellence. (2004). Fertility: assessment and treatment for people with fertility problems. [online] Available from https://www.nice.org.uk/guidance/cg11. [Accessed December, 2017].
4. Bosteels J, Van HB, Weyers S, et al. The position of diagnostic laparoscopy in current fertility practice. Hum Reprod Update. 2007;13:477-85.

JAYPEE BROTHERS

5. den Hartog JE, Lardenoije CM, Severens JL, et al. Screening strategies for tubal factor subfertility. Hum Reprod. 2008;23:1840-8.
6. Panchal S, Nagori C. Imaging techniques for assessment of tubal status. J Hum Reprod Sci. 2014;7(1):2-12.
7. Watrelot A, Dreyfus JM, Andine JP. Evaluation of the performance of fertiloscopy in 160 consecutive infertile patients with no obvious pathology. Hum Reprod. 1999;14:707-11.
8. Steures P, van der Steeg JW, Hompes PG, et al. Intrauterine insemination with controlled ovarian hyperstimulation versus expectant management for couples with unexplained subfertility and an intermediate prognosis: a randomised clinical trial. Lancet. 2006;368:216-21.
9. Emanuel MH, Exalto N. Hysterosalpingo-foam sonography (HyFoSy): a new technique to visualize tubal patency. Ultrasound Obstet Gynecol. 2011;37(4):498-9.
10. Piccioni MG, Riganelli L, Filippi V, et al. Sonohysterosalpingography: Comparison of foam and saline solution. J Clin Ultrasound. 2017;45:67-71.
11. Spalding H, Martikainen H, Tekay A, et al. Transvaginal salpingosonography for assessing tubal patency in women previously treated for pelvic inflammatory disease and benign ovarian tumors. Ultrasound Obstet Gynecol. 1999;14:205-9.
12. Kore S, Hegde A, Nair S. Sonography for assessment of tubal patency: Our experience. J Obstet Gynecol India. 2000;50:63-6.
13. Lucaino DE, Exacoustos C, Johns DA. Transabdominal saline contrast sonohysterography: Can it replace hysterosalpingography in low resource countries? Am J Obstet Gynecol. 2011;204:79.
14. Seal SL, Ghosh D, Saha D. Comparative evaluation of sonosalpingography, hysterosalpingography and laparoscopy for determination of tubal patency. J Obstet Gynecol India. 2007;57:158-61.
15. Perquin DA, Dorr PJ, de Craen AJ, et al. Routine use of hysterosalpingography prior to laparoscopy in the fertility workup: a multicentre randomized controlled trial. Hum Reprod. 2006;21:1227-31.
16. Lijmer JG, Mol BW, Heisterkamp S, et al. Empirical evidence of design-related bias in studies of diagnostic tests. JAMA. 1999;282:1061-6.
17. Whiting P, Rutjes AW, Dinnes J, et al. Development and validation of methods for assessing the quality of diagnostic accuracy studies. Health Technol Assess. 2004;8:iii1-iii234.
18. Andersen AN, Goossens V, Gianaroli L, et al. Assisted reproductive technology in Europe, 2003. Results generated from European registers by ESHRE. Hum Reprod. 2007;22:1513-25.
19. Merkus JM. Fertility treatments: possibilities for fewer multiple births and lower costs–the "Umbrella" study. Ned Tijdschr Geneeskd. 2006;150:1162-4.
20. The Dutch Healthcare Authority. (2009). Diagnosis treatment combinations. [online] Available from http://ctg.bit-ic.nl/Nzatarieven/top.do. [Accessed December, 2017].
21. Jacobson TZ, Duffy JM, Barlow D, et al. Laparoscopic surgery for subfertility associated with endometriosis. Cochrane Database Syst Rev. 2010;1:CD001398.
22. Council for Public Health and Healthcare (Raad voor de Volksgezondheid en zorg). (2006). Sensible and Sustainable Care (Zinnige en duurzame zorg). [online] Available from http://rvz.net/uploads/docs/Advies_-_Zinnige_en_duurzame_zorg.pdf. [Accessed December, 2009].
23. van der Steeg JW, Steures P, Eijkemans MJ, et al. Pregnancy is predictable: a large-scale prospective external validation of the prediction of spontaneous pregnancy in subfertile couples. Hum Reprod. 2007;22:536-42.
24. Lardenoije CM, Land JA. Chlamydia antibody testing for tubal factor subfertility. Ned Tijdschr Geneeskd. 2007;151(36):1981-5.

JAYPEE BROTHERS

Available at all medical bookstores
or buy online at www.jaypeebrothers.com

JAYPEE BROTHERS
Medical Publishers (P) Ltd.
www.jaypeebrothers.com

Join us on facebook.com/JaypeeMedicalPublishers

Shelving Recommendation
OBSTETRICS & GYNECOLOGY

ISBN 978-93-5270-371-5