Manual of
Urogynecology

Editors
SN Tripathy
KC Mahapatra
SK Giri
Vineet Mishra
Ajit Nayak

61st All India Congress of
Obstetrics & Gynaecology
17–21 January 2018

Organized by:
The Odisha Obstetric
and Gynaecological Society
Under the Aegis of FOGSI

Contents

1. **Surgical Anatomy of the Pelvic Floor** 1
   Dilgir S, Ajay Rane and Jay Iyer
2. **Clinical Evaluation of Pelvic Organ Prolapse** 10
   N Rajamaheswari
3. **Surgical Procedures for Pelvic Organ Prolapse** 13
   Uma Rani Swain
4. **Surgical Management of Vesicovaginal Fistula** 16
   Mangesh Narwadkar
5. **Urinary Tract Injury in Urogynecological Surgery** 19
   Subhash Chandra Biswas
6. **Role of Cystoscopy in Urogynecological Surgery** 23
   Suguna Kumar Veera
7. **Update in Pharmacotherapy for Female Urinary Incontinence** 27
   Harsha Ananthram, Jay Iyer, Ajay Rane
8. **The use of Botox in the Management of Overactive Bladder** 32
   Jagdish Gandhi
9. **Pelvic Organ Prolapse** 38
   A Tamilselvi
10. **Role of Urodynamic Study in Stress Urinary Incontinence** 41
    Anju Soni
11. **Urinary Tract Injury During Urogynecological Surgery: Prevention and Management** 44
    Vineet Mishra

Chapter 2

Clinical Evaluation of Pelvic Organ Prolapse

N Rajamaheswari

Pelvic organ prolapse (POP) is a frequently encountered problem which compromises quality of life of women. Ensuring successful outcome with no future recurrence or complications is unquestionably a challenge. Emergence of newer concepts on supports of pelvic organs and better understanding of the anatomy of the pelvic floor has enhanced our knowledge.

Meticulous evaluation leads to an accurate diagnosis which is essential to plan appropriate management. Clinical evaluation defines the degree of prolapse objectively and ensures subjective assessment of integrity of connective tissue and muscular support of pelvic organs. Evaluation may be performed in sitting or standing position. Examination in dorsal lithotomy is simpler and preferred by clinicians even though it may mask the severity of prolapse. Evaluation is done by way of inspection and palpation with the help of simple instruments like speculum and retractors at rest and straining position. Digital examination includes vaginal, bimanual, rectal, and rectovaginal examination.

Bimanual examination identifies tenderness, location, size, mobility of uterus, cervix, bladder, and adnexa. Recognizing coexisting mass is crucial. Bimanual and rectovaginal examination enables assessment of connective tissue and muscular support of pelvic organs. Evaluation starts with anterior vagina followed by posterior vagina and apex and assessment of support at all levels should be performed.

Examination of anterior vagina with the speculum facilitates assessing urethra, urethrovaginal junction, and bladder. Inspection of vagina, cervix, uterus, and perineum is necessary. Assessment of descent and its extent, vaginal epithelium (color effect of estrogen), vaginal rugosity, obliteration of sulci, and perineal concavity should be done in order. Pink and supple vagina indicates well-estrogenized status and presence of rugosity certifies intact underlying visceral connective tissue. A persistent bulge in anterior vaginal wall (with support) but without rugosity suggest a central defect in pubocervical fascia. However, a bulge with rugosity with loss of anterolateral sulci suggests a paravaginal defect. Such bulge disappears if support provided to the lateral fornices by an instrument (support test).

JAYPEE BROTHERS

Transverse tear of pubocervical fascia from anterior margin of pericervical ring results in bulge in anterior fornix (without rugosity). Transverse separation of pericervical ring from uterosacral ligament with intact pubocervical fascia causes descent of cervix/vault. Examination of posterior vaginal wall may reveal transverse rugosity or bulging rectum against vaginal epithelium when the support is defective.

Separation of rectovaginal fascia from uterosacral ligament results in bulge in posterior fornix. Intact uterosacral ligament with separation of fascia may result in elongation of cervix. A rectovaginal examination may differentiate a low from high rectocele. Enterocele is diagnosed by rectovaginal examination if a loop of bowel felt. Anterior and posterior wall descent mostly coexists. Apical defect manifesting as uterine descent or as vault prolapse are not difficult to diagnose. Assessing the side-to-side and vertical mobility of the prolapse should be done. Separation of cervix from cardinal ligaments causes wide lateral mobility of cervix. Separation of cervix from uterosacral ligament causes vertical mobility.

It is essential to identify associated decubitus ulcer, premalignant, or malignant lesions over the vaginal wall. Irreducibility of prolapse secondary to uterine tumor, big bladder stone, or impacted mass in polycystic ovarian disease (POD) should be recognized. Examination of perineum by inspection and palpation is vital. Presence of perineal concavity is normal.

Visualizing and palpating the pelvic floor during a voluntary contraction recognizing muscle body insertion, its strength, duration of contraction, and anterior lift during contraction are essential. Normal location of perineum is at ischial tuberosities or within 2 cm below it. Location of perineum beyond 2 cm at rest or straining is referred perineal descent. Vaginal, rectal-and rectovaginal examination should identify the integrity of rectovaginal septum, enterocele, and laxity of anal sphincter.

Describing and comparing POP to a known volume is imprecise and inconsistent. Hence, pelvic organ prolapse quantification (POP-Q), a universally accepted system, is adopted to describe the anatomic position of pelvic organs. Hymen is used as reference point and nine measurements made to plot the POP-Q grid. POP-Q quantifies and aids in understanding POP. It describes the degree of compromise of supporting tissue; however, it does not identify the underlying defect.

It is essential to diagnose and address coexisting uterine tumor, bladder stone, cystic and solid mass in the vagina, rectal prolapse, urethral mucosal prolapse, and sphincter incompetence in order to obtain successful outcome. Imaging modalities like X-rays, computed tomography (CT), and magnetic resonance imaging (MRI) are rarely required though ultrasound imaging is frequently used as an adjunct. Transperineal imaging is valuable in diagnosing enterocele. Clinicians need to be aware of mixed defects in different levels in order to plan the appropriate management and to optimize the success. Identifying coexisting dysfunctions and addressing the pelvic floor as a complete entity will enable us to achieve the goals of reconstructive pelvic floor surgery. Adopting the POP-Q will enable objective assessment of outcome after surgery.

JAYPEE BROTHERS

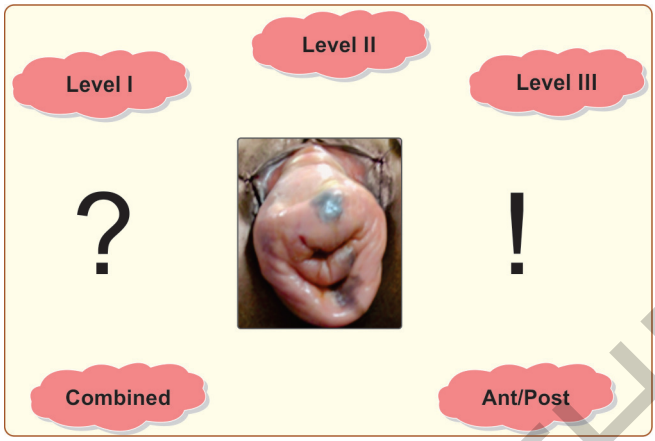

Fig. 1

BIBLIOGRAPHY

1. Brubaker L, Glazener C, Jacquetin B, et al. Surgery for Pelvic Organ Prolapse: Incontinence. 4th edition. 4th International Consultation on Incontinence: Health publications limited; 2009. pp. 1275-310.
2. Haessler AL, Lin LL, Ho MH, et al. Reevaluating occult incontinence. Curr Opin Obstet Gynecol. 2005;17(5):535-40.
3. Maher C, Baessler K, Glazener CM, et al. Surgical management of pelvic organ prolapse in women. Cochrane Database Syst Rev. 2007;(3):CD004014.
4. Maher C, Feiner B, Baessler K, et al. Surgical management of pelvic organ prolapse in women. Cochrane Database Syst Rev. 2004;(4):CD004014.
5. Shull BL, Capen CV, Riggs MW, et al. Preoperative and postoperative analysis of site-specific pelvic support defects in 81 women treated with sacrospinous ligament suspension and pelvic reconstruction. AM J Obstet Gynecol. 1992;166(6 Pt 1):1764-8.
6. Wertz RW, Wertz DC. Lying-in: A history of childbirth in America. New Haven, CT: Yale University Press; 1989.

JAYPEE BROTHERS

Available at all medical bookstores
or buy online at www.jaypeebrothers.com

JAYPEE BROTHERS
Medical Publishers (P) Ltd.
www.jaypeebrothers.com

Join us on facebook.com/JaypeeMedicalPublishers

Shelving Recommendation
OBSTETRICS & GYNECOLOGY

ISBN 978-93-5270-372-2