rs.com, for detailed information on dermatology books, visit our website www.jaypeebrothers.com, for detailed information on dermatology bo

Celebrating 50 YEARS
Passion, Quality and Innovation in Healthcare Publishing

DERMOSCOPY

Text and Atlas

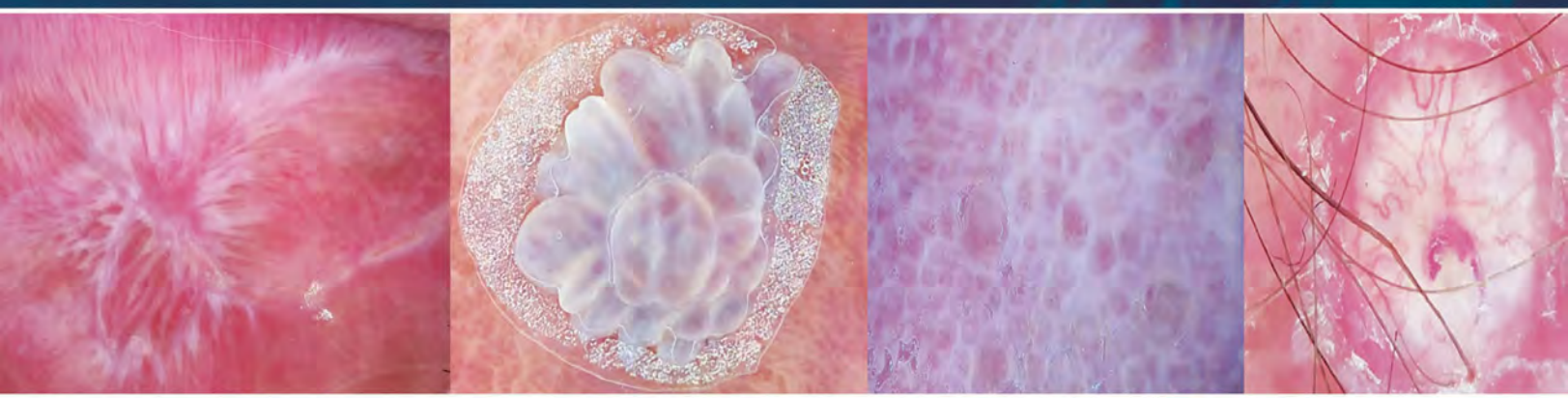

Subrata Malakar

JAYPEE

Contents

1. **Dermoscopy: A Window into Epidermis and Dermis** 1
   Purva Mehta, Subrata Malakar

2. **Dermoscopy: A Missing Link between Clinical Dermatology and Histopathology** 2
   Samipa S Mukherjee, Subrata Malakar

3. **The Dermoscope** 4
   Samipa S Mukherjee

4. **Recognition of Patterns** 11
   Sushrut Save, Purva Mehta, Subrata Malakar

5. **Dermoscopic Dialogues** 37
   Subrata Malakar, Shruti Kulkarni

6. **Color Concept through Dermoscopy** 70
   Subrata Malakar, Samipa S Mukherjee, Surit Malakar

7. **Papulosquamous Disorders** 95
   Subrata Malakar

8. **Infectious Dermatoses** 148
   Subrata Malakar, Anjali Pal

9. **Skin Tumors** 182
   Subrata Malakar

10. **Autoimmune Dermatoses** 260
    Subrata Malakar

11. **Granulomatous Dermatoses** 302
    Subrata Malakar, Jayasree Puravoor

12. **Pigmentary Disorders** 321
    Balachandra S Ankad, Balakrishna Nikam, Niti Khunger

13. **Disorders of Keratinization** 359
    Subrata Malakar, Priya Diwaker, Surit Malakar

14. Vascular Lesions **380**
Subrata Malakar

15. Dermoscopic Surprises **411**
Subrata Malakar, Purva Mehta

16. Miscellaneous Dermatoses **419**
Subrata Malakar, Samipa S Mukherjee, Priya Diwaker, Surit Malakar

17. Dysplastic Nevi **447**
Sushrut Save

18. Dermoscopy in Diagnostic Dilemmas **450**
Subrata Malakar, Samipa S Mukherjee

19. Dermoscopy in Therapeutic Monitoring and Follow-up **465**
Subrata Malakar, Samipa S Mukherjee

20. Algorithms **473**
Samipa S Mukherjee

Index *477*

CHAPTER 3

The Dermoscope

Samipa S Mukherjee

INTRODUCTION

A dermoscope (dermatoscope) is a noninvasive, diagnostic tool which visualizes subtle clinical patterns of skin lesions and subsurface skin structures not normally visible to the naked eye. It has also been called a skin surface microscope, epiluminescence microscope or episcope. Basically, a dermoscope is functionally similar to a magnifying lens but with the added features of an inbuilt illuminating system, a higher magnification which can be adjusted, the ability to assess structures as deep as in the reticular dermis, and the ability to record images.[1] The most commonly used term "dermoscopy" was proposed by Friedman et al. in 1991.[2] In comparison to the hand lens that has been used over the decades, the dermoscope has the ability not just for magnification but also to look at the subsurface structures defining the patterns.

WORKING PRINCIPLE OF THE DERMOSCOPE

The basic principle of dermoscopy is transillumination of a lesion and studying it with a high magnification to visualize subtle features. Light incident on skin undergoes reflection, refraction, diffraction, and absorption. Most of the light incident on dry, scaly skin is reflected, but smooth, oily skin allows most of the light to pass through it, reaching the deeper dermis. Thus, the application of linkage fluids over the lesions to be studied improves the translucency of the skin. The scattering of light is overcome by polarized light in polarized dermoscopes and contact fluid in nonpolarized dermoscopes, allowing visualization of subsurface structures like those in the lower layers of epidermis, dermoepidermal junction, and upper dermis. Various linkage fluids used are oils (immersion oil, olive oil, and mineral oil), water, an antiseptic solution, and glycerin. Water or antiseptic solutions evaporate quickly and hence are less preferred than oils.

COMPONENTS OF A DERMOSCOPE

- *Achromatic lens*: Most handheld instruments provide 10X–20X magnification, but higher magnifications can be achieved with special lenses and advanced machines like Fotofinder, where a magnification of up to 180X can be reached.
- *Inbuilt illuminating system*: Light emitting diodes (LEDs) (Delta 20Ó, DermLiteÓ) provide high intensity white light and consume 70% less power than halogen lamps. Illumination can be altered by turning off a set of LEDs. They are also designed to emit lights of different colors for better visualization of the skin, as penetration of the skin by light is proportional to the wavelength of light (DermLite MSÓ). An orange light helps in enhancing the contrast between the natural skin color and the pigmented lesions which may be found in the newer equipment (DermLite DL3 and DL4).
- *Power supply*: Handheld instruments are usually powered by batteries, e.g. lithium ion battery (DermLite DL100Ó, DermLite platinumÓ), rechargeable lithium battery (DermLite MSÓ, DermLite Pro DP-RÓ), AA battery (mini 2000

JAYPEE BROTHERS

dermatoscopeÓ), and rechargeable handles (DELTA 20Ó). Video dermoscopes are powered directly via the USB cable attached.

Additional facilities in some dermoscopes are an inbuilt photography system, trichoanalysis, body mapping and imaging, softwares for calculating area of involvement and severity scoring.

TYPES OF DEVICES

Nonpolarized Devices

These devices require a contact fluid with a refractive index equal to that of the skin, which optically links the skin surface with the face plate of the dermoscopes.

Polarized Devices

Polarized devices have two filters in a process called cross polarization, one filter is placed between the light source and skin and the second one is placed between the skin and light detector. This cross polarization enables excellent visibility by absorbing all the scattered light allowing light only in a single plane to pass through. They can be used without the contact fluid.

Hybrid Devices

These devices incorporate both polarized and nonpolarized light. The need for both the modes in a single device arises from the fact that nonpolarized mode helps in clearly demonstrating structures on the surface whereas polarized mode demonstrates pigmentary and vascular changes better. The latest in the series include DermLite DL3, DL4, and Fotofinder.

DERMATOSCOPY IMAGE CHARACTERISTICS AND DIFFERENCES AMONG COMMONLY USED STANDARD DERMATOSCOPES

We have compared the four commonly used standard dermatoscopes, viz. Heine Delta 20 (Heine optotechnik, Herrsching, Germany), Heine Delta 20 plus (Heine optotechnik, Herrsching, Germany), DermLite DL3 (3Gen Inc, USA) and Fotofinder (Fotofinder® Dermoscope studio). Heine Delta 20 plus, DermLite DL3, and Fotofinder have both polarized and nonpolarized modes. Heine Delta 20 has only nonpolarized mode, which requires a contact fluid. Nonpolarized dermatoscope helps in the detection of superficial structures in the skin, whereas a polarized dermatoscope allows deeper visualization. Though polarized dermatoscopes do not require contact fluid, images captured by them are sharper in the presence of interface fluid.[3]

Images taken with nonpolarized mode offer better visualization of dermatoscopic findings in lesions with surface abnormalities. Also, most of the studies in the earlier period of dermatoscopy were done on dermoscopes with nonpolarizing mode.

Vascular lesions are better characterized under the polarized mode as the light in this mode penetrates deeper. Visualization of regular red dots in psoriasis is superior with earlier devices, viz. Heine Delta 20, where images are less bright and have a relatively white tone. However, these devices are less efficient in picking up the background erythema as compared to Heine Delta 20 plus and DermLite DL3.[4]

The warmer tone in images of Heine Delta 20 plus dermatoscope and Fotofinder is attributed to higher color rendering index values of the device.

The magnification of images using the Fotofinder is up to 180X whereas with the other instruments is up to 20X which can be further accentuated by the zoom in facility of the digital and smart phone cameras. Fotofinder is an excellent research tool that can be used to document the details of the lesion/hair as the case may be. It can be used for calculating psoriasis area severity index (PASI) in psoriasis, melasma area severity index (MASI) in melasma and so on.

JAYPEE BROTHERS

DIGITAL IMAGING AND DERMOSCOPY

Dermoscopy is the art and science of viewing surface and subsurface structures of the skin thereby aiding in diagnosis. The device was evolved primarily to detect melanomas and prior to biopsy of suspicious lesions. Recently it has found application in diagnosis of papulosquamous disorders, pigmentary disorders other than melanoma, and other benign conditions.

The upper layers of the skin have a reflective property whereas the lower layers have a refractive and absorptive property. Dermoscopes make use of the two most important color giving molecules in the skin, hemoglobin, and melanin. When we look at a skin lesion with a magnifying loupe with lighting, most of the light is scattered due to the reflective property of the stratum corneum. There are two ways to overcome this problem so as to allow more light to pass through the stratum corneum, enabling us to look deeper into the skin to visualize the pigment and vascular patterns among other things. One is by using a fluid medium as an interface and a transparent glass contact plate and the other is by using a cross polarized light.[5]

CHOICE OF THE INSTRUMENT

A number of factors need to be taken into account, namely, quality, budget, need for documentation, and even the major types of cases that one encounters. The most commonly used dermoscopes are the independent handheld units (Figs. 1 to 3) (these do not need to be connected to a monitor to visualize skin lesions), which usually have a magnification of around 10X–20X. Photographs in these devices can be recorded via smart phone cameras, point and shoot as well as digital SLRs, (Figs. 4A and B) using adapters. The image thus captured can be further cropped and magnified to view the minor details.

The other category of dermoscopes is one that needs to be connected to a viewing monitor (Fig. 5), usually with a USB connection. A larger view is obtained which can also be shared with the patients, if needed, for counseling purposes and images can be stored easily along with printed reports that can be given to the patients to carry home. Advanced versions of the video dermoscopes also incorporates whole body imaging and mapping systems, inbuilt trichoanalysis software and serial dermoscopic image recording facilities, however their use is restricted by cost factors.

POINTS TO BE BORNE IN MIND WHILE PRACTICING DERMOSCOPY IN VIVO[6]

- *The choice between wet and dry dermoscopy*: It is always a good idea to start with dry dermoscopy first to visualize the scales followed by wet dermoscopy to visualize the subsurface structures. Wet dermoscopy is more useful for the demonstration of vasculature and pathology in the upper dermis. The choice of linkage fluid in wet dermoscopy could range from immersion oil to water to ultrasound gel based on availability, cost, and feasibility. Dry dermoscopy is especially useful in scaly conditions, for viewing nail anomalies and to see the surface structures like in seborrheic keratosis.
- It must be borne in mind that the investigator must familiarize himself with the normal skin of the affected individual and proceed toward the diseased skin or scalp. This helps in picking up the abnormalities specific to the affected individual.
- The area to be examined must be stabilized to avoid out of focus images and findings.
- In practice, contact dermoscopy can be avoided for infected/infective lesions. The use of disposable contact caps, food wraps, adhesive tapes, and using 70% ethanol as the interface fluid help to avoid cross infection in contact dermoscopy.[7]
- While practicing contact dermoscopy, it is important to avoid excess pressure over the lesion, so as to avoid blanching effect.
- The use of polarized and nonpolarized mode will depend on whether the investigator wishes to demonstrate the surface (nonpolarized mode) or subsurface structures (polarized mode).
- The use of additional facilities like pigment boost could be explored while dealing with hyper/hypopigmentary disorders.

JAYPEE BROTHERS



Figs. 1A and B: DermLite DL3.

- Few devices also have UV light as an additional feature, which facilitates in monitoring conditions like vitiligo.
- Special imaging techniques are required while doing dermoscopy on mucosal surface in order to avoid soiling of instrument and transmission of disease and maintain hygiene. Using of cellophane tape or glass slide as the interface medium in mucosal dermoscopy are widely used methods. However, usage of glass slide has clear advantages over cellophane. Glass slide helps in dispersing the collected smegma/fluid/discharge on the mucosal area thus providing a clear field of vision. Also the number of artifacts due to reflectance is lesser with glass slide as compared to the cellophane sheets.

TAKING A GOOD QUALITY IMAGE

While documenting dermoscopic image, do not forget to take a good quality clinical image. Clinical image is of vital importance for a clinic dermoscopic correlation and future reference like in monitoring of treatment or before and after therapy. Also, using the inbuilt measuring scale available in most units give an idea of the size of the lesion. For clinical image capture, one must select the right lesion, decide on whether or not to use the facility of flash in the camera,

JAYPEE BROTHERS



Fig. 2: DermLite DL4.



Fig. 3: DermLite with smart phone attachment.

JAYPEE BROTHERS



Figs. 4A and B: DermLite Photo II Pro.

eliminate background chaos to focus on the lesion in question and thereby frame the lesion while capturing image. Stability of hand taking the photograph is of immense importance to avoid shaky or blurred images.

Capturing good quality dermoscopic images may be a matter of practice and expertise with time. It may be a good idea to have an assistant at hand who can help to stabilize the lesion, add linkage fluid, stretch the skin, and assist in capturing the image. While practicing contact dermoscopy and capturing the image special importance should be given to avoid excess pressure since that leads to blanching of the lesion. In the author's view, it is a good idea to use both hands while capturing images through a handheld dermoscope in the smart phone cameras. The non-dominant hand is used for stabilizing the camera while the dominant hand may be used to manipulate and maneuver the dermoscope for focusing on the lesion of interest.

STORAGE OF DIGITAL IMAGES

Digital images can be store in the smart phones, computers, tablets or on cloud after appropriate labeling with patient details, clinical image, and related dermoscopic findings. It may be a good idea to clearly label the relevant dermoscopic findings using arrows or circles with a color that has sufficient contrast compared to the background.

JAYPEE BROTHERS



Fig. 5: Fotofinder.

REFERENCES

1. Nischal KC, Khopkar U. Dermoscope. Indian J Dermatol Venereol Leprol. 2005;71:300-3.
2. Friedman RJ, Rigel DS, Silverman MK, et al. Malignant melanoma in the 1990s: the continued importance of early detection and the role of physician examination and self-examination of the skin. CA Cancer J Clin. 1991;41:201-26.
3. Pan Y, Gareau DS, Scope A, et al. Polarized and nonpolarized dermoscopy: the explanation for the observed differences. Arch Dermatol. 2008;144:828-9.
4. Nirmal B. Dermatoscopy image characteristics and differences among commonly used standard dermatoscopes. Indian Dermatol Online J. 2017;8:233-4.
5. Kaliyadan F. The scope of the dermoscope. Indian Dermatol Online J. 2016;7:359-63.
6. Mukherjee SS, Malakar S. Taking the dermoscope from bench to practice. Int J Dermoscop. 2017;1(2):4-6.
7. Kaliyadan F, Kuruvilla J. Using transparent adhesive tape to prevent cross infection during contact dermoscopy. Indian J Dermatol Venereol Leprol. 2016;82:744.

JAYPEE BROTHERS

or detailed information on dermatology books, visit our website **www.jaypeebrothers.com,** for detailed information on dermatology books, visit our

DERMOSCOPY
Text and Atlas

Salient Features

- The only comprehensive book to explain and discuss the language of dermoscopy through dermoscopic dialogue
- Establishing the foundation of dermoscopy through chapters like color concept in dermoscopy and melanin module
- Methodological and extensive description of dermoscopic findings in dermatological disorders aids in the understanding
- Description of multiple new dermoscopic findings and dermoscopic description of multiple rare diseases keeps the reader engrossed
- Dermoscopy in diagnostic dilemmas serves as an indispensable and important tool to improvise the understanding and depth in the subject.



Subrata Malakar MBBS MD (Dermatology) DCH is an accomplished clinician and astute academician par excellence, heading Rita Skin Foundation, one of the premier dermatology centers in India. Having passed Dermatology in 1985, he has also completed diploma in child health from one of the top institutes in Kolkata. His passion for dermatology, vision in innovation and commitment to the subject have rendered him the status of a teacher and doctor par excellence. He has authored one book "Trichoscopy—A Text and Atlas", over 90 papers in various international and national journals, many chapters in various textbooks and over 76 presentations in international and national conferences. Dr Malakar has received several prestigious honors and awards in his career. He is known amongst his peers as a visionary, always striving for excellence and his passion for innovation distinguishes him in the field of dermatology.

Available at all medical bookstores
or buy online at www.jaypeebrothers.com

JAYPEE
JAYPEE BROTHERS
Medical Publishers (P) Ltd.
www.jaypeebrothers.com
Join us on facebook.com/JaypeeMedicalPublishers

Shelving Recommendation
DERMATOLOGY

ISBN 978-93-5270-394-4
9 789352 703944