our website www.jaypeebrothers.com, for detailed information on ophthalmology books, visit our website www.jaypeebrothers.com

Gems of Ophthalmology

RETINA

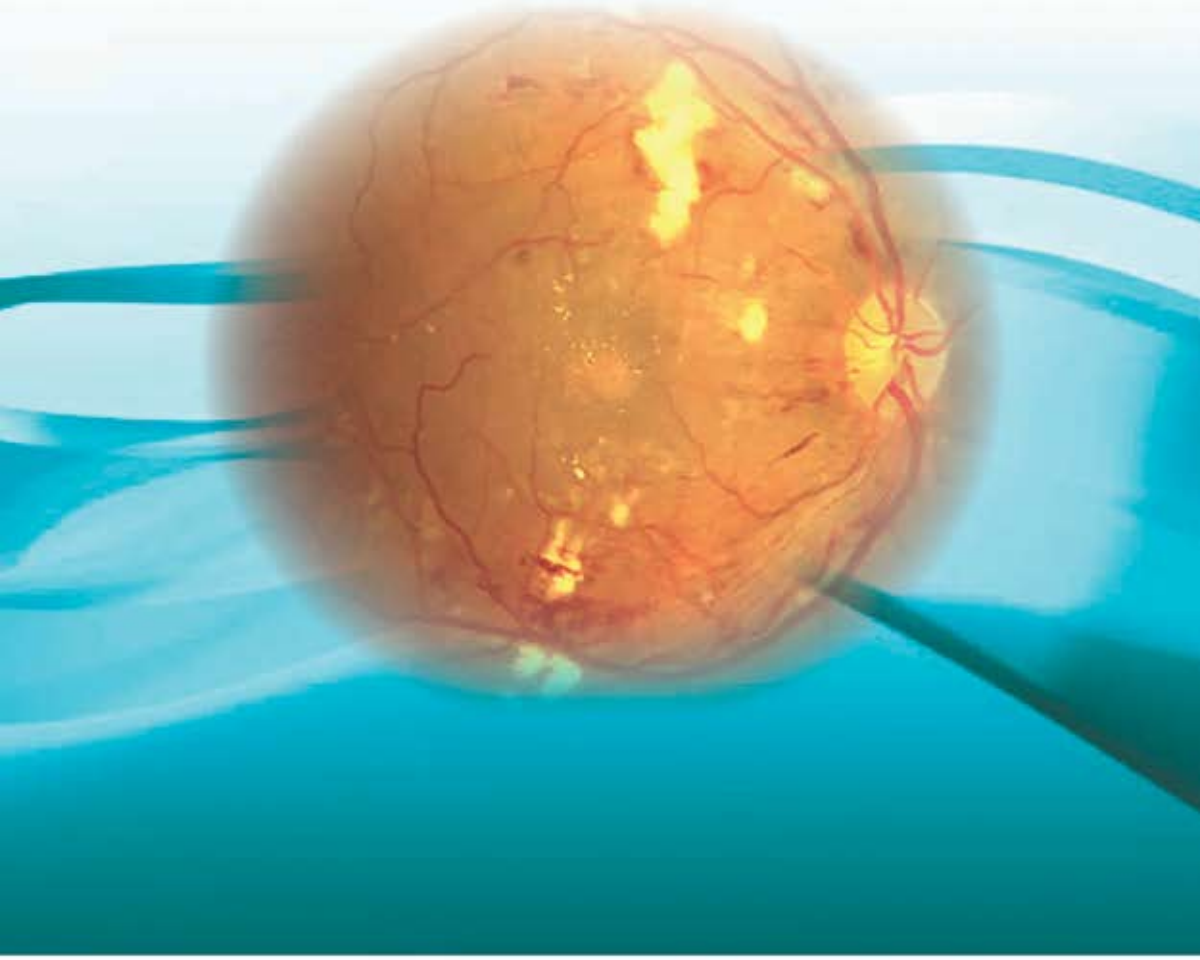

HV Nema
Nitin Nema

JAYPEE

Contents

1. Ophthalmoscopy **1**
Pukhraj Rishi, Tarun Sharma
- Principles of Ophthalmoscopy 1
- Method of Examination 3
- Fundus Drawing Color Code (Peter Morse) 7
- Indirect Ophthalmoscopy in Operating Room 10
- Direct Ophthalmoscopy 14
- Wide Angle Viewing System 17

2. Fundus Fluorescein Angiography **23**
Pradeep Venkatesh
- Procedure of Fundus Fluorescein Angiography 25
- Indications 26
- Phases of Fundus Fluorescein Angiography 26
- Interpretation of Fundus Fluorescein Angiography 27

3. Indocyanine Green Angiography **33**
Rajesh Ramanjulu, Mahesh Shanmugam, Pradeep Sagar BK
- History 33
- Phases of Indocyanine Green Angiography 34
- Adverse Reactions 35
- Applications in Ophthalmology 36
- Diagnostics Applications 36
- Polypoidal Choroidal Vasculopathy 39
- Central Serous Chorioretinopathy 50
- Inflammatory Lesions of the Choroid 54
- Tumors 54
- Therapeutic Application 55

4. Fundus Autofluorescence: Overview and Applications in Retinal Practice **57**
Anand Rajendran, Vinay PG, Vishal MY
- Demonstration of Fundus Autofluorescence 57
- Fundus Autofluorescence Imaging Modalities 58
- Assessing the Fundus Autofluorescence Image 59
- Clinical Applications of Autofluorescence 61
- Classification of Fundus Autofluorescence Patterns in Early AMD 64
- Retinal Pigment Epithelium Tears 67
- Idiopathic Macular Telangiectasia 67
- Chorioretinal Inflammatory Disorders 69
- Acute Posterior Multifocal Placoid Pigment Epitheliopathy 69
- Acute Syphilitic Posterior Placoid Chorioretinitis 70

JAYPEE BROTHERS

- Multifocal Choroiditis and Panuveitis 70
- Acute Zonal Occult Outer Retinopathy 70
- Birdshot Chorioretinopathy 70
- Perspectives in Imaging Technologies 71

5. Choroidal Imaging with Enhanced Depth Imaging and Swept-source Optical Coherence Tomography 73

James A Eadie, Suresh R Chandra

- Imaging of the Normal Choroid 74
- EDI and SS-OCT Imaging in Glaucoma 76
- Choroidal Imaging in Central Serous Chorioretinopathy 76
- Choroidal Imaging in Uveitis 78
- Choroidal Imaging in Age-related Macular Degeneration 79
- Choroidal Changes in Retinal Vein Occlusions 80
- Choroidal Imaging in Myopic Eyes 80
- Choroidal Changes in Inherited Retinal Degenerations 81
- Retinal and Choroidal Tumors Imaged with OCT 82

6. Diabetic Retinopathy: An Update 89

Dhananjay Shukla

- Diabetes Pandemic: Repeatedly Revising Estimates 89
- Pathogenesis 89
- Clinical Features of Diabetic Retinopathy 94
- Natural Course and Grading of Diabetic Retinopathy 97
- Differential Diagnosis of Diabetic Retinopathy 98
- Imaging in Diabetic Retinopathy 102
- Screening for Diabetic Retinopathy 106
- Medical Management of Diabetic Retinopathy 107
- Vitrectomy 110
- Summary and Future Directions 114

7. Diabetic Macular Edema 119

Peter N Youssef, Suresh R Chandra

- Pathogenesis 123
- Treatment 125

8. Diabetic Papillopathy 140

Michael M Altaweel, Richard E Appen, Suresh R Chandra

- Case Presentation 140
- Demographics 146
- Symptoms 146
- Examination 146
- Investigation 147
- Pathophysiology 149
- Differential Diagnosis 149
- Prognosis 151
- Management 152

JAYPEE BROTHERS

9. Hypertensive Retinopathy **154**
Shreyas Temkar, Bhavya G, Pradeep Venkatesh
- Ocular Manifestations 154

10. Recent Advances in the Management of Retinal Vein Occlusions **160**
Deependra Vikram Singh, Yog Raj Sharma
- Pathogenesis 160
- Recent Advances in the Management of Retinal Vein Occlusion 162
- Epidemiology 162
- Diagnosis 163
- Systemic Work-up 166
- Interventions for Retinal Vein Occlusion 169

11. Current Concepts in Central Serous Chorioretinopathy **184**
Neha Sinha, Sandeep Saxena
- Pathophysiology 184
- Epidemiology 186
- Signs and Symptoms 187
- Pathogenesis 188
- Laboratory Studies 188
- Treatment 196
- Complications 199
- Prognosis 199

12. Proliferative Vitreoretinopathy **203**
Ajit Majjhi
- Pathogenesis 203
- Terminology and Classification 204
- Risk Factors 206
- Clinical Features 207
- Investigations 207
- Management 209

13. Diagnostic Procedures in Retinopathy of Prematurity **219**
Yog Raj Sharma, Parijat Chandra, Rajni Sharma, Rajvardhan Azad
- Retinopathy of Prematurity Classification 219
- Retinopathy of Prematurity Screening and Treatment 224

14. Macular Dystrophies **235**
Nidhi Relhan, Subhadra Jalali
- Definition of Hereditary Macular Dystrophies 235
- Classification 237
- Autosomal Dominant Macular Dystrophies 237
- Autosomal Recessive Macular Dystrophies 245
- X-linked Recessive Diseases 248
- Management of Heredomacular Dystrophy 252

JAYPEE BROTHERS

15. Management of Age-related Macular Degeneration 256
Nazimul Hussain, Supriya Dabir, Anjali Hussain
- Demographic Factors 256
- Management of Dry Age-related Macular Degeneration 258
- Management of Active Wet Age-related Macular Degeneration 264

16. Polypoidal Choroidal Vasculopathy 279
Lingam Gopal, Mayuri Bhargava, Su Xinyi
- Demographics 279
- Clinical Presentation 279
- Symptomatology 280
- Types 280
- Investigations 281
- Diagnosis 283
- Age-related Macular Degeneration and Polypoidal Choroidal Vasculopathy 284
- Management 284
- End Point of Treatment 290
- Results 291
- Prognosticating Factors 292
- Genetics 292
- Challenges and Future Direction 293

17. Macular Phototoxicity 297
Dhananjay Shukla
- Photochemical Injuries: Pathogenetic Mechanism 298
- Agents of Phototoxicity 298
- Factors Affecting Vulnerability to Phototoxicity 301
- Diagnosis of Acute and Chronic Macular Phototoxicity 302

18. Chloroquine Retinopathy: Diagnosis 306
Aljoscha Steffen Neubauer
- Premaculopathy 306
- Early Maculopathy 306
- Established Maculopathy 307
- Advanced Maculopathy 307
- Final-stage Maculopathy 307
- Mechanism of Chloroquine Toxicity 308
- Corneal Deposits 309
- Visual Field Testing 310
- Color Vision 310
- Electrooculogram 312
- Electroretinogram and Multifocal Electroretinogram 313

19. Macular Hole 318
Meena Chakrabarti, Arup Chakrabarti, Sonia S John
- Pathogenesis of Macular Holes 319
- Staging of Macular Holes 320
- Etiology of Macular Holes 324
- Investigations 325

JAYPEE BROTHERS

20. Macular Hole Surgery **340**
Abhinav Dhami, Dhanashree Ratra, Tarun Sharma
- Epidemiology 340
- Pathophysiology 341
- Classification of Idiopathic Macular Hole 342
- Ocular Manifestations 344
- Clinical Evaluation 344
- Differential Diagnosis 347
- Natural Course 347
- Treatment Options 347
- Complications 351
- Prognosis 352

21. Giant Retinal Tears **356**
Lingam Gopal
- Etiology 356
- Giant Retinal Tear versus Giant Dialysis 357
- Variables in Clinical Presentation 357
- Management 357
- Results 361

22. Management of Rhegmatogenous Retinal Detachment by Vitreoretinal Surgical Techniques **364**
Yog Raj Sharma, Soman Nair
- Technique of Vitreoretinal Surgery 364

23. Microincisional Vitrectomy Surgery **373**
Lingam Gopal, Mohammed Naseer, Tengku Ain Kamalden
- Relevant Anatomy 373
- History of Evolution of Vitreous Instrumentation 374
- Instrumentation and Fluidics in Microincisional Vitrectomy Surgery 374
- Procedures 377
- Advantages of Microincisional Vitrectomy Surgery 378
- Limitations of Microincisional Vitrectomy Surgery 379
- Problems with Small Gauge Vitrectomy 380

24. Retinal Cyst: Management **384**
Yog Raj Sharma, Soman Nair
- Classification of Retinal Cysts 384
- Congenital Retinal Cysts 385
- Acquired Retinal Cysts 385
- Pseudocystic Vitelliform Macular Degeneration 390

25. Retinoblastoma **392**
Fairooz P Manjandavida, Santosh G Honavar
- Genetics 393
- Classification and Staging 393
- Clinical Features 394
- Diagnosis 396
- Management 396

JAYPEE BROTHERS

26. Radiation Retinopathy **406**
Karobi Lahiri Coutinho
- Etiology 406
- Radiation Therapy 406
- Risk Factors 407
- Comorbidities 407
- Pathogenesis 408
- Diagnosis 408
- Differential Diagnosis 410
- Management 411

Index *415*

JAYPEE BROTHERS

CHAPTER 4

Fundus Autofluorescence: Overview and Applications in Retinal Practice

Anand Rajendran, Vinay PG, Vishal MY

JAYPEE BROTHERS

INTRODUCTION

The phenomenon of autofluorescence, emanating from the lipofuscin-laden retinal pigment epithelium (RPE) cells has been known and studied for a few decades now. In the RPE, lipofuscin originates chiefly from phagocytosed photoreceptor outer segments (OS), whereas in many other cell types, it originates internally through autodigestion.[1,2] Phagocytosis of the tips of the photoreceptor outer segments, and their subsequent lysosomal digestion is one of the key functions of the RPE.[1–3] Although, the digestion of these outer segments is nearly complete, a miniscule portion remains undigested—the lipofuscin. The aggregation of fluorescent material in the RPE reflects the level of metabolic activity, which is largely determined by the quantity of photoreceptor OS renewal. Above the age of 70, about 20–33% of the cytoplasmic volume may be constituted by lipofuscin and melanofuscin granules.

The AF imaging is, essentially, a topographic "metabolic mapping" of the lipofuscin in the RPE and other fluorophores in the outer retina and subretinal space. This retinal autofluorescence is understood to reflect a balance between the accumulation and removal of lipofuscin in the RPE. The lipofuscin in the RPE cells is extraordinary, as this is largely formed as a result of the light energy trapping function of the retina. The lipofuscin is most concentrated in the RPE of the central retina, the area having the largest concentration of visual pigment as well as receiving the highest amount of light. These retinoid-derived fluorophores have an exhaustive system of conjugated double bonds which explains the long wavelength fluorescence emission from the lipofuscin.[4]

DEMONSTRATION OF FUNDUS AUTOFLUORESCENCE

Vitreous fluorophotometry gave us the first *in vivo* evidence of fundus autofluorescence (FAF). A distinct "retinal" peak was noted in the preinjection

scans, whose magnitude increased with age, in keeping with the known properties of lipofuscin fluorescence.[5,6] These studies led to the development of a fundus spectrofluorometer,[7,8] created to evaluate, specifically, the excitation and emission spectra of the autofluorescence from small retinal foci (2° diameter) of the fundus and to permit absolute measurements of the emanated fluorescence.

FUNDUS AUTOFLUORESCENCE IMAGING MODALITIES

The Confocal Scanning Laser Ophthalmoscope

Although originally developed by Webb et al., it was in 1995 that von Ruckmann et al. first described FAF imaging with the confocal scanning laser ophthalmoscope (cSLO).[9,10]

The FAF signal has, compared to fundus reflectance or fluorescence angiography, a very low intensity. In order to enhance image contrast and reduce background noise, several single FAF images are recorded in series.[9,11-14] The mean image (of 4–16 frames) is then calculated, and the pixel values are normalized. The high rate of up to 16 frames per second and the high sensitivity of the cSLO allows FAF imaging to be recorded in rapidly and at minimal excitation energies.[15]

Three different cSLO systems have thus far been developed for creating FAF images: Heidelberg Retina Angiograph (HRA classic, HRA 2, and Spectralis HRA, Heidelberg Engineering, Heidelberg, Germany], Rodenstock cSLO (RcSLO; Rodenstock, Weco, Dusseldorf, Germany), and Zeiss prototype SM 30 4024 (ZcSLO; Zeiss, Oberkochen, Germany). Only the former is commercially available. These instruments use an excitation wavelength of 488 nm generated by an argon or solid-state laser for FAF imaging.

An additional development of the cSLO [Spectralis HRA + optical coherence tomography (OCT), Heidelberg Engineering, Heidelberg, Germany] is combination with spectral-domain OCT in the same instrument. This permits simultaneous cSLO and OCT recordings. With the cSLO system, any lateral eye movement can be detected in real time and input into the scanning system of the OCT modality, facilitating a very accurate registration of the OCT A-scans.

Another key feature is that, with the use of any of the cSLO imaging modes (reflectance, FAF, or angiography) as the reference image, retinal locations on the fundus image can be mapped to cross-sectional OCT findings with precision. The extremely high resolution of these images is like "optical biopsies" of the retina.

The Fundus Camera

The lipofuscin can be stimulated, by direct illumination, to fluoresce and has a wide emission band ranging from about 500 nm to 750 nm.[16] However, other structures in the eye in front of the retina also fluoresce, the crystalline lens being one of the foremost. In order to obtain clear and good quality

JAYPEE BROTHERS

autofluorescence images, the instrument has to be able to either reject or circumvent the fluorescence from the lens.

Scanning laser ophthalmoscopes have a confocal capability in which only the conjugate points on the fundus are imaged. Points not lying on the conjugate planes are rejected. This allows cSLOs to use excitation and barrier wavelengths similar to those used in fluorescein angiography to obtain autofluorescence photographs.

While the initial camera-based systems were restricted by lower contrast and narrower fields of view, the next generations involved shifting the excitation and emission wavelengths towards the red end of the spectrum to preclude autofluorescence from lens.[17,18] Image quality was enhanced using a new set of filters. A band-pass filter centered at about 580 nm for excitation and another centered at about 695 nm as a barrier filter were used. The nuclear sclerosis of the lens does not attenuate these. Additionally, as the lens fluorescence occurs with wavelengths shorter than the upper cutoff of the barrier filter, lens autofluorescence rarely is a problem with moderate degrees of nuclear sclerosis. The limitations of this system for autofluorescence include all those associated with a typical fundus camera especially, for patients with small pupils.

Differences between the Autofluorescence Images Taken with a cSLO and a Fundus Camera

The wavelengths used with the commercially available cSLO are absorbed more by blood as compared to the wavelengths in the modified fundus camera. This makes the contrast between the vessels and background higher in cSLO images than in images from the fundus camera. This possibly is the reason why the optic nerve often shows more fluorescence with a fundus camera system than with the cSLO. Light scattering affects fundus camera systems more than cSLO systems. All these factors may lead to a lower ability of the fundus camera system to discern smaller retinal vessels as compared to the cSLO. Macular pigments or fluorescein do not absorb the wavelengths used in the fundus camera. Fundus cameras utilize a cone of light entering the eye, hence small pupillary apertures reduce the intensity of autofluorescence. Fundus camera images need manual removal of the excess lens autofluorescence in patients with advanced degrees of nuclear sclerosis.

ASSESSING THE FUNDUS AUTOFLUORESCENCE IMAGE

When an FAF image is being evaluated, any abnormal recording should be discerned, and a plausible cause should be investigated for. The characteristics of a normal FAF image, which need to be understood first, are as follows:

- The *optic nerve head* is devoid of the RPE and the autofluorescent lipofuscin and is hence characteristically dark. The *retinal vessels* are also dark because of absorption from blood constituents. The *macular area* has the FAF signal most markedly reduced at the fovea. Beginning from the foveal center, a

JAYPEE BROTHERS

faint yet discernable increase in the signal can be observed at about the margin of the fovea, with a further steady increment toward the outer macula. Beyond these areas with decrements in FAF intensity, the FAF signal appears evenly distributed (Figs. 4.1A and B).

- The quality of the recorded image determines the accuracy with which abnormalities in the FAF image are depicted. Any opacity in the cornea, vitreous, the lens, or the anterior chamber may affect the detection of pathologies at the level of the RPE and the neurosensory retina.

Causes for a Reduced Fundus Autofluorescence Signal

- Reduction in RPE lipofuscin density
  - Retinal pigment epithelium atrophy [such as geographic atrophy (GA)]
  - Hereditary retinal dystrophies (such as RPE65 mutations).
- Increased RPE melanin content
  - Retinal pigment epithelium hypertrophy.
- Absorption from extracellular material/cells/fluid anterior to the RPE
  - Intraretinal fluid (such as macular edema)
  - Migrated melanin-containing cells
  - Crystalline drusen or other crystal-like deposits
  - Fresh intraretinal and subretinal hemorrhages
  - Fibrosis, scar tissue, borders of laser scars
  - Retinal vessels
  - Luteal pigment (lutein and zeaxanthin)
  - Media opacities (vitreous, lens, anterior chamber, cornea).

Causes for an Increased Fundus Autofluorescence Signal

- Excessive RPE lipofuscin accumulation
  - Lipofuscinopathies, including Stargardt disease, best disease, pattern dystrophy, and adult vitelliform macular dystrophy

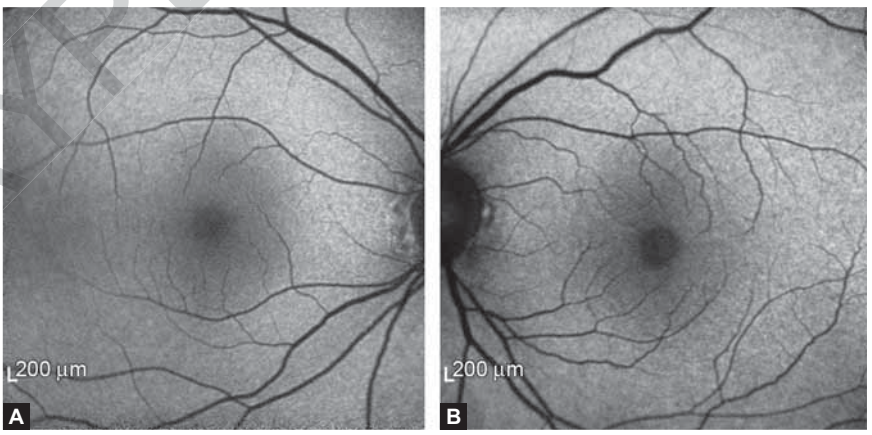

Figs. 4.1A and B: The normal fundus autofluorescence patterns. (A) The right eye. (B) The left eye of a patient.

JAYPEE BROTHERS

  - Age-related macular degeneration (AMD), such as RPE in the junctional zone preceding enlargement of the occurrence of GA.
- Occurrence of fluorophores anterior or posterior to the RPE cell monolayer
  - Intraretinal fluid (such as macular edema)
  - Subpigment epithelial fluid in pigment epithelial detachments
  - Drusen in the subpigment epithelial space
  - Migrated RPE cells or macrophages containing lipofuscin or melanolipofuscin (seen as pigment clumping or hyperpigmentation on funduscopy)
  - Older intraretinal and subretinal hemorrhages
  - Choroidal vessel in the presence of RPE and choriocapillaris atrophy, such as in the center of laser scars or within patches of RPE atrophy
  - Choroidal nevi and melanoma.
- Lack of absorbing material
  - Depletion of the luteal pigment, such as in idiopathic macular telangiectasia (IMT) type 2
  - Displacement of the luteal pigment, such as in cystoid macular edema.
- Optic nerve head drusen
  - Artifacts.

CLINICAL APPLICATIONS OF AUTOFLUORESCENCE

Macular and Retinal Dystrophies

In several macular and retinal dystrophies, autofluorescent material does aggregate in the RPE and the extracellular deposits in the neurosensory space may also be fluorescent. FAF imaging enables detection of the abnormal phenotype in some disorders when it is not otherwise evident (Figs. 4.2A to D).

Clinically discernable pale yellowish deposits at the level of the RPE/Bruch's membrane in Best's disease (Figs. 4.3A to D), adult vitelliform macular dystrophy, fundus albipunctatus (Figs. 4.4A to D), and Stargardt's macular dystrophy or fundus flavimaculatus are associated with markedly increased FAF intensities.[16,19] The focal flecks in Stargardt's disease are much more clearly highlighted on FAF images in comparison to fundus photographs. They show a bright FAF signal that may weaken as atrophy develops.

Age-related Macular Degeneration

Early Manifestation

Age-related macular degeneration, a complex disease with both genetic and environmental factors, has become the most common cause of legal blindness in industrialized countries.[20-23] A hallmark of ageing is the accumulation of lipofuscin (LF) granules in the cytoplasm of RPE cells (Figs. 4.5A and B).

Fundus autofluorescence as an imaging modality was used to map metabolic changes of RPE and LF accumulation *in vivo* and has been studied recently in patients with AMD. These help us to know the spatial correlation

JAYPEE BROTHERS

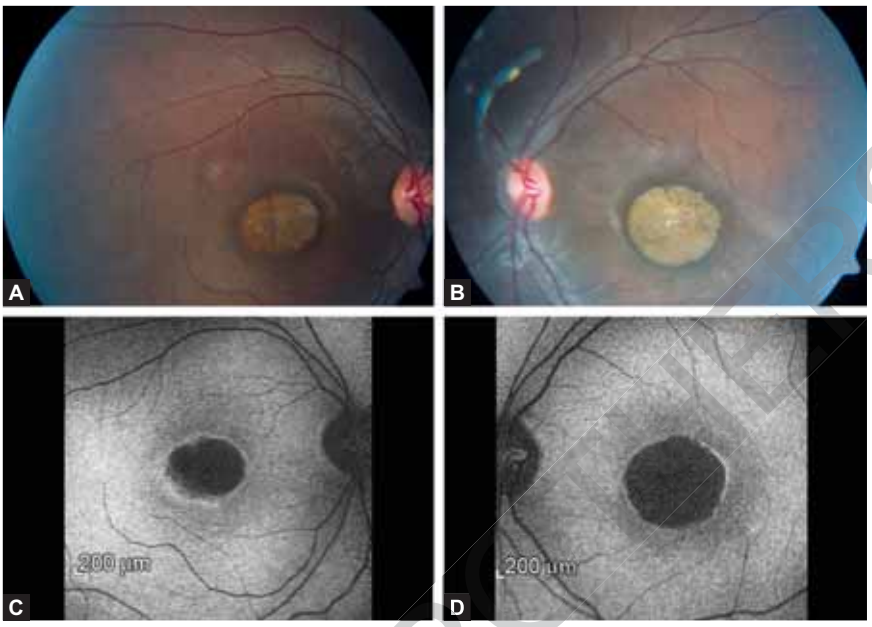

Figs. 4.2A to D: (A and B) A patient diagnosed with Stargardt's disease with the fundus photographs. (C and D) Fundus autofluorescence (FAF) images revealing central hypoautofluorescence reflecting the retinal pigment epithelium (RPE) atrophic pathology surrounded by the hyperautofluorescent ring.

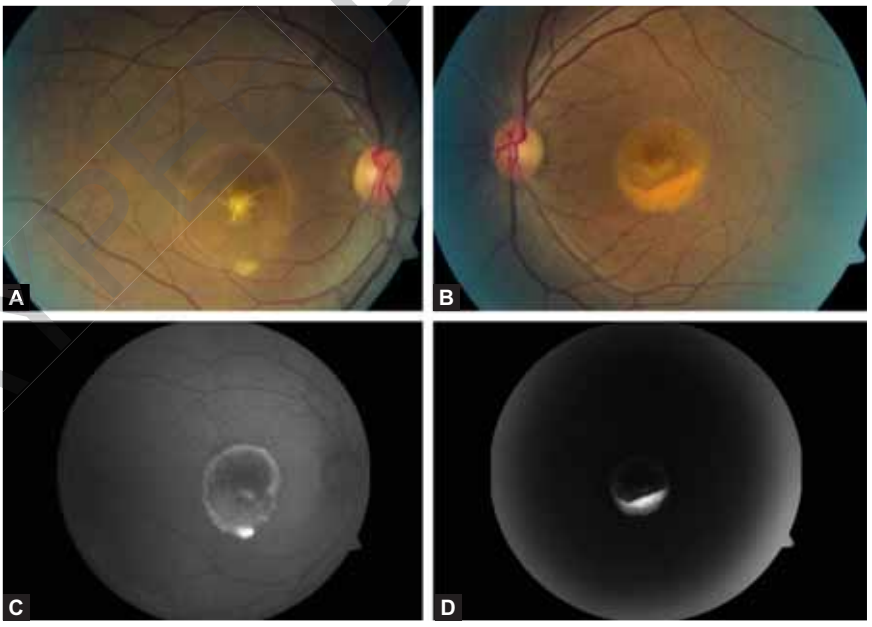

Figs. 4.3A to D: (A and B) The fundus pictures and (C and D) corresponding fundus autofluorescence (FAF) pictures of a patient with Best's disease demonstrating the hyperautofluorescence emanating from the accumulated lipofuscin-laden deposit in the neurosensory space.

JAYPEE BROTHERS

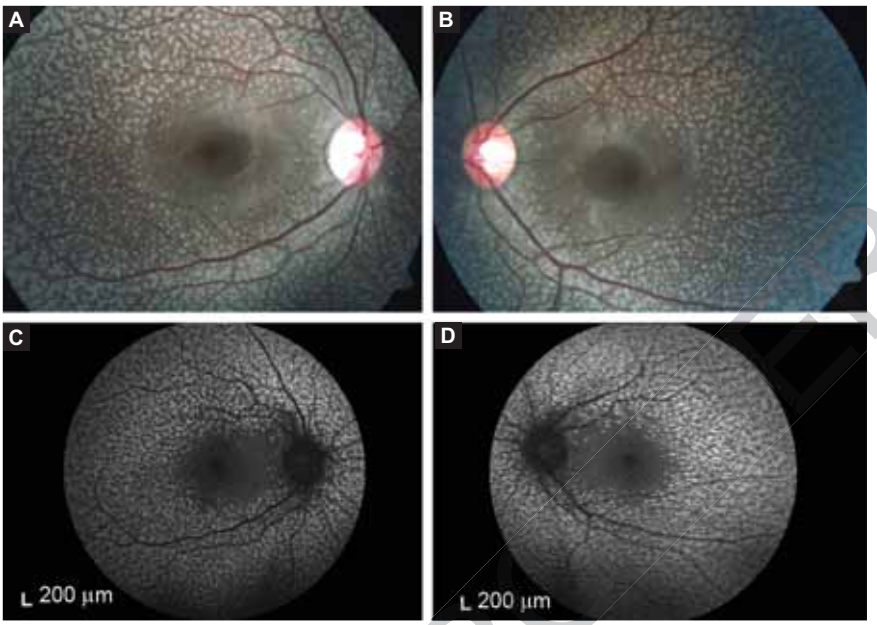

Figs. 4.4A to D: (A and B) A patient with fundus albipunctatus with fundus pictures. (C and D) Corresponding autofluorescence images showing the hyperautofluorescent specks.



Figs. 4.5A and B: (A) The fundus picture autofluorescence image; (B) Highlighting the copious autofluorescence from the drusenoid material.

of FAF findings with established early AMD changes such as focal hypo- and hyperpigmentation and drusen.

One important observation in patients with early AMD is that alterations in the FAF signal are not necessarily associated with corresponding funduscopically or angiographically visible changes such as drusen and

JAYPEE BROTHERS

irregular hyper- or hypopigmentations.[18,23,24] This indicates that FAF findings may represent an independent measure of disease stage and activity.

CLASSIFICATION OF FUNDUS AUTOFLUORESCENCE PATTERNS IN EARLY AMD

Fundus autofluorescence findings in patients with early AMD were recently published by an international workshop on FAF phenotyping in early AMD.[3] Pooling data from several retinal centers developed a classification system with eight different FAF patterns.

It demonstrates the relatively poor correlation between visible alterations on fundus photography and notable FAF changes. Based on these results, it was speculated that FAF findings in early AMD may indicate more widespread abnormalities and diseased areas. These changes in FAF imaging at the RPE cell-level may precede the occurrence of visible lesions as the disease progresses.

Reticular Drusen

Reticular drusen can be identified as a peculiar pattern on FAF images, with multiple relatively uniform roundish or elongated spots with decreased intensities, and surrounded by an interlacing network of normal-appearing FAF signals.[23]

These are readily identified on FAF images and more easily detected than on funduscopy or fundus photographs. The exact anatomic location (i.e. sub-RPE, Bruch's membrane, choriocapillaris) and morphological pattern is not clearly understood.

Age-related Macular Degeneration—Geographic Atrophy

Geographic atrophy represents the atrophic late-stage manifestation of "dry" AMD, characterized by the development of atrophic patches that may initially occur in the parafoveal area.[25-27] During the natural course of the disease, the atrophy slowly enlarges over time, and there is foveal sparing until later. Due to the distinct changes in the topographic distribution of RPE lipofuscin, which is the dominant fluorophore for FAF imaging, the signal is markedly reduced over atrophic areas, while high-intensity FAF levels can be observed in the junctional zone surrounding the atrophic patches. FFA and fundus photography do not show any morphological changes at this stage.

Detection and Quantification of Atrophy

As FAF signal intensity is markedly reduced, areas of atrophy can be readily visualized on FAF images. In contrast to fluorescein angiography, FAF imaging represents a noninvasive imaging method and is less time consuming.

The advantages of FAF imaging in general atrophy have been used to detect and precisely quantify atrophic areas on FAF images using customized

JAYPEE BROTHERS

image analysis software.[28,29] This software allows the automated segmentation of atrophic areas by a region algorithm. Interfering retinal blood vessels that have a similar FAF intensity compared with atrophic areas are recognized by the software and can be excluded from the measurements.

Further developments include the alignment of FAF images at different examinations using retinal landmarks in order to correct for different scan angles and magnifications. This allows the accurate assessment of atrophy progression over time and can be used in longitudinal observations, including interventional trials.

Age-related Macular Degeneration—Pigment Epithelial Detachment

Retinal pigment epithelial detachments (PEDs) are a common feature of advanced AMD. Conventional imaging techniques such as fundus photography, fluorescein, or indocyanine green angiography cannot detect the variations in the area of PED which can be seen by FAF signal in that area.

Changes in FAF intensities in patients with PED secondary to AMD can be classified into four groups. Other dominant fluorophores with similar excitation and emission spectra inside the PED, such as extracellular fluid or degraded photoreceptors, may be present and contribute to typical patterns with abnormal FAF intensity (Figs. 4.6A and B). FAF phenotypes may reflect not only different stages in the evolution of a PED but also the heterogeneity on a cellular and molecular level in the disease process, and may thus be relevant for future molecular genetic analyses.

Age-related Macular Degeneration—Choroidal Neovascularization

Choroidal neovascularization (CNV) is a common cause of visual loss in patients with AMD and represents the growth of new subretinal vessels in the macular region.

Fundus Autofluorescence Findings in Early Choroidal Neovascularization

Eyes with "recent-onset" CNV were found to have patches of "continuous" or "normal" autofluorescence corresponding to areas of hyperfluorescence on the comparative fluorescein angiograms. This implied that RPE viability was preserved at least initially in CNV development. FAF imaging was able to delineate the edge of CNV lesions better than FFA and it was statistically larger.[31]

Fundus Autofluorescence Findings in Late-stage Choroidal Neovascularization

In eyes with long-standing CNV, decreased areas of AF were seen, implying nonviable RPE and lack of photoreceptor outer segment renewal. These

JAYPEE BROTHERS

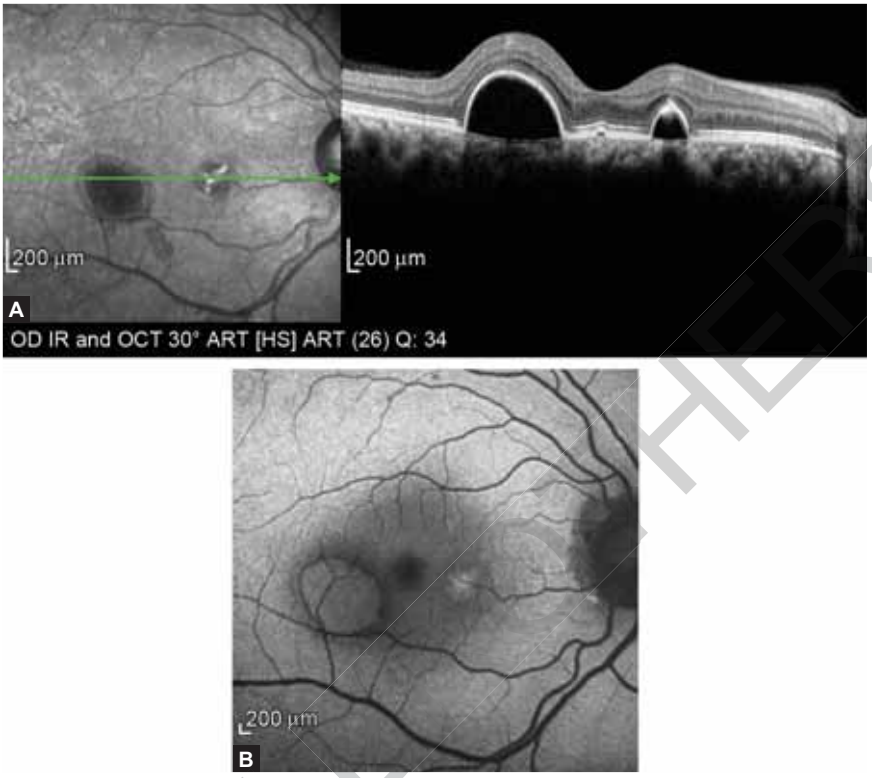

Figs. 4.6A and B: (A) The optical coherence tomography (OCT) picture and (B) Corresponding fundus autofluorescence image showing a large detachment of the retinal pigment epithelium with intermediate fundus autofluorescence (FAF) signal with surrounding well-defined less-autofluorescent halo delineating the entire border of the lesion.

represent areas of RPE atrophy beneath the CNV scars in the late stages of disease,[30] whereas areas of increased FAF seen inferior to lesions were thought to be due to a gravitational effect of fluid tracking under the retina, similar to that seen in central serous retinopathy.[31] Increased FAF signal has also been described around the edge of lesions that are thought to represent proliferation of RPE cells around the CNV.[30-32]

Classic Choroidal Neovascularization

Purely classic lesions showed low or decreased FAF signal at the site of the CNV, with a ring of increased FAF around some lesions (Figs. 4.7A and B).

Occult Choroidal Neovascularization

According to McBain et al. foci of decreased FAF were seen scattered within the lesion. These were felt to be due to small areas of RPE loss or damage caused

JAYPEE BROTHERS

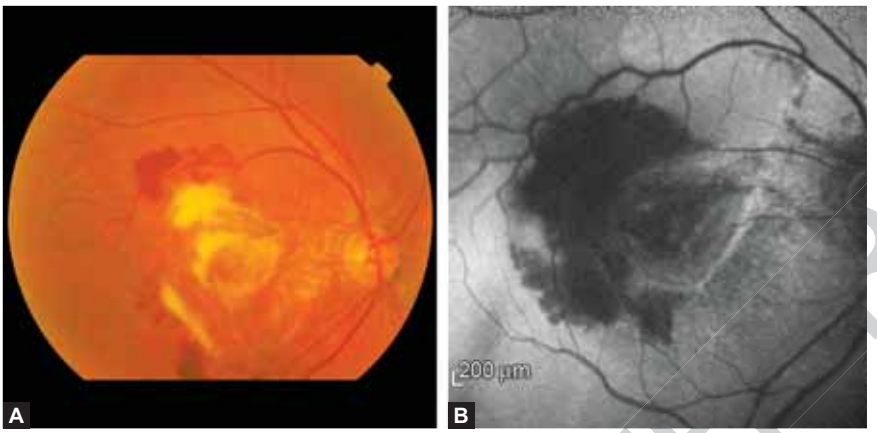

Figs. 4.7A and B: (A) Fundus picture and (B) Autofluorescence image showing the choroidal neovascular membrane (CNVM).

by the chronic, more indolent lesions growing underneath the RPE. Areas of increased FAF were less frequently associated with the edge of occult lesions compared with predominantly classic lesions.

RETINAL PIGMENT EPITHELIUM TEARS

Areas with RPE loss are characterized by a very low signal and intense hypo-autofluorescence because of a complete lack of RPE and loss of lipofuscin. They are sharply demarcated. The adjacent area with rolled-up RPE is characterized by the heterogeneous signal of distinct increased FAF. Thus, the exact location of the tear can be delineated in most cases (Figs. 4.8A and B).

IDIOPATHIC MACULAR TELANGIECTASIA

Idiopathic macular telangiectasia (or idiopathic parafoveal telangiectasis) is a descriptive term for different disease entities presenting with telangiectatic alterations of the juxtafoveolar capillary network with a predominant location temporal to the fovea (Figs. 4.9A and B).[32,33] It is usually classified as type I and type II.

Fundus Autofluorescence in Type 1 Idiopathic Macular Telangiectasia

Fundus autofluorescence imaging may show an increased signal that may be explained by a reduced macular pigment optical density (MPOD) due to retinal tissue defects in the area with cystoid changes. However, overall the distribution is normal, with the highest MPOD in the fovea and attenuation towards the periphery.

JAYPEE BROTHERS

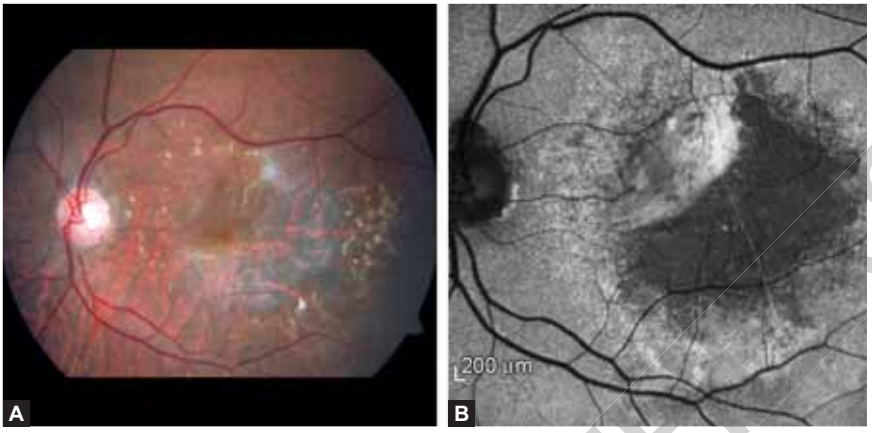

Figs. 4.8A and B: (A) Fundus picture and (B) Autofluorescence image showing a retinal pigment epithelium tear following the development of choroidal neovascularization secondary to age-related macular degeneration.

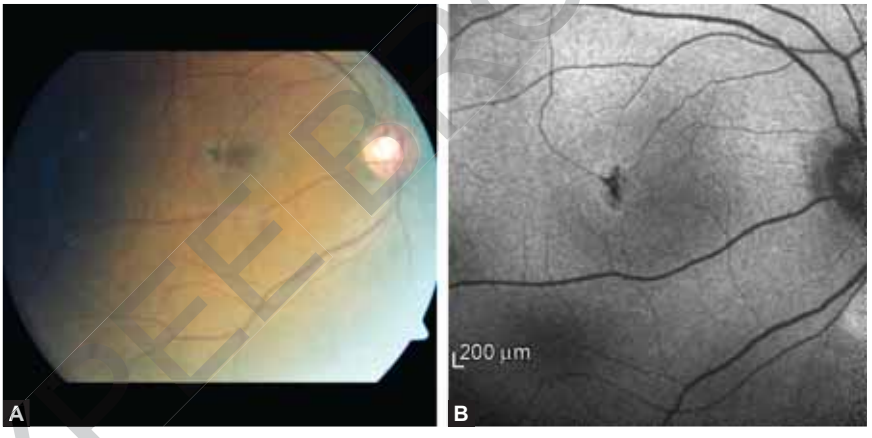

Figs. 4.9A and B: (A) Clinical picture of a patient with idiopathic juxtafoveal telangiectasia (IJT) and the (B) Fundus autofluorescence (FAF) image showing the intense hypoautofluorescence of the pigment deposits.

Fundus Autofluorescence in Type 2 Macular Telangiectasia

Macular pigment optical density is typically reduced in the macular area and the area of depletion largely corresponds to angiographic late-phase hyperfluorescence and increased confocal blue reflectance. In early stages, FAF shows minimal alteration whereas in late stages, it may be grossly abnormal. When intraretinal pigment clumping has occurred, FAF may show a reduced signal due to a blockade phenomenon.

JAYPEE BROTHERS

CHORIORETINAL INFLAMMATORY DISORDERS

Autofluorescence photography complements other methods of imaging the ocular fundus. The amount of autofluorescence is governed by the amount of fluorophores in any given area in the fundus.

Choroidal neovascularization associated with intraocular inflammation is a common complication, and this secondary CNV produces characteristic autofluorescence findings. By observing autofluorescence characteristics, we can estimate the extent of damage, diagnose sequelae such as secondary CNV, learn more about the inflammatory process in question, and possibly anticipate future problems caused by the disease (Figs. 4.10A to D).

ACUTE POSTERIOR MULTIFOCAL PLACOID PIGMENT EPITHELIOPATHY

In the acute phases of acute posterior multifocal placoid pigment epitheliopathy (APMPPE), more lesions are visible by fluorescein angiography and ophthalmoscopy than those that are seen by autofluorescence photography.[34] The areas of decreased pigmentation with increased fluorescence and decreased autofluorescence suggest an atrophy or absence of functional RPE cells. Given the finding of increased pigmentation and autofluorescence

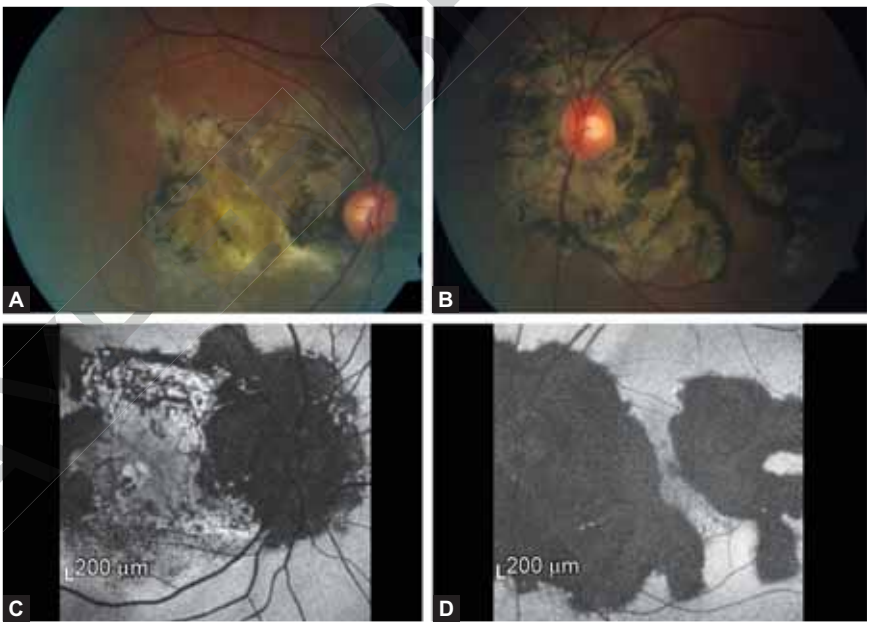

Figs. 4.10A to D: (A and B) Clinical picture of a case of healed geographic helicoid peripapillary choroidopathy (GHPC) with the fundus autofluorescence (FAF) images; (C and D) Images demonstrate the deep hypoautofluorescence of the scarred area and the neighboring mottled hyperautofluorescence.

JAYPEE BROTHERS

centrally with a depigmented hypoautofluorescent surround, it is possible that with the healing of the lesions, there was a centripetal contraction of each placoid lesion with a retraction of the edges inward. The implication of these findings is that the RPE is affected secondarily to the choroidal changes.

ACUTE SYPHILITIC POSTERIOR PLACOID CHORIORETINITIS

Acute syphilitic posterior placoid chorioretinitis (ASPPC) shares similarities to APMPPE, as both conditions can cause yellowish plaque-like changes in the posterior pole.[35] There are important differences in appearance, and probably in pathophysiology. ASPPC usually causes a solitary yellow placoid lesion that has a more prominent color and opacification at its outer borders. The autofluorescence abnormalities are confined only to the placoid region.

MULTIFOCAL CHOROIDITIS AND PANUVEITIS

Autofluorescence photography of multifocal choroiditis and panuveitis (MCP) demonstrates clinically visible hypoautofluorescent chorioretinal scars.[36] However, autofluorescence photography often shows many more times the number of hypoautofluorescent spots than the number of chorioretinal scars. Subsequent development of visible chorioretinal spots has occurred in areas occupied by the hypoautofluorescent spots seen by autofluorescence imaging. Thus, autofluorescence appears to show areas of RPE damage from MCP that are more numerous and extensive than what the choroidal scars would indicate.

Secondary CNV is visible as a butterfly-shaped area of hyperautofluorescence. The borders of the autofluorescence show prominent attachments to hypoautofluorescent MCP scars. The hyperautofluorescence of past CNV persists despite subsequent treatment. Of interest is the finding of small hyperautofluorescent spots or rings in the vicinity of MCP scars.

ACUTE ZONAL OCCULT OUTER RETINOPATHY

The autofluorescent findings in acute zonal occult outer retinopathy (AZOOR) are limited largely because it is a rare disease. Autofluorescence photography showed that the outer border was intensely autofluorescent, consistent with the presence of lipofuscin, and that the central area of the lesion was hypoautofluorescent, consistent with atrophy of the RPE. The patient had visual field abnormalities consistent with the location and size of the autofluorescence abnormality.

BIRDSHOT CHORIORETINOPATHY

Autofluorescent abnormalities are usually associated with the depigmented lesions, while the early lesions do not necessarily cause autofluorescent abnormalities.

JAYPEE BROTHERS

PERSPECTIVES IN IMAGING TECHNOLOGIES

After more than one decade of the first visualization of the topographic distribution of lipofuscin accumulation in the retinal areas using confocal scanning laser ophthalmoscopy (cSLO), FAF imaging is increasingly being used in research and in the clinical setting.[9] FAF findings also serve to identify high-risk features and rapid progress in an ongoing large interventional trial of patients with GA secondary to AMD. There are limitations to the currently used FAF imaging devices; these include resolution and quantification issues as well as the distinction of different underlying fluorophores according to spectral characteristics. Novel emerging imaging techniques offer new perspectives.

REFERENCES

1. Cuervo AM, Dice JR. When lysosomes get old. Exp Gerontol. 2000;35:119-31.
2. Sparrow JR, Boulton M. RPE lipofuscin and its role in retinal photobiology. Exp Eye Res. 2005;80:595-606.
3. Yin D. Biochemical basis of lipofuscin, ceroid, and age pigment-like fluorophores. Free Rad Biol Med. 1996;21:871-88.
4. Feeney-Burns L, Hilderbrand ES, Eldridge S. Aging human RPE: morphometric analysis of macular, equatorial, and peripheral cells. Invest Ophthalmol Vis Sci. 1984;25:195-200.
5. Delori, FC, Bursell, SE, Yoshida, A, et al. Vitreous fluorophotometry in diabetics: study of artifactual contributions. Graefe's Arch Clin Exp Ophthalmol. 1985;222:215-8.
6. Kitagawa, K, Nishida, S, Ogura, Y. In vivo quantification of autofluorescence in human retinal pigment epithelium. Ophthalmologica. 1989;199:116-21.
7. Delori FC. Fluorophotometer for noninvasive measurement of RPE lipofuscin. Noninvasive assessment of the visual system. OSA Technical Digest. 1992;1:164-7.
8. Delori FC. Spectrophotometer for noninvasive measurement of intrinsic fluorescence and reflectance of the ocular fundus. Appl Opt. 1994;33:7439-52.
9. von Ruckmann A, Fitzke FW, Bird AC. Distribution of fundus autofluorescence with a scanning laser ophthalmoscope. Br J Ophthalmol. 1995;79:407-12.
10. Webb RH, Hughes GW, Delori FC. Confocal scanning laser ophthalmoscope. Appl Opt. 1987;26:1492-9
11. Bellmann C, Holz FG, Schapp O, et al. Topography of fundus autofluorescence with a new confocal scanning laser ophthalmoscope. Ophthalmologe. 1997;94:385-91.
12. Bindewald A, Jorzik JJ, Roth F, et al. cSLO digital fundus autofluorescence imaging. Ophthalmologe. 2005;102:259-64.
13. Jorzik JJ, Bindewald A, Dithmar S, et al. Digital simultaneous fluorescein and indocyanine green angiography, autofluorescence, and red-free imaging with a solid-state laser-based confocal scanning laser ophthalmoscope. Retina. 2005;25:405-16.
14. Solbach U, Keilhauer C, Knabben H, et al. Imaging of retinal autofluorescence in patients with age-related macular degeneration. Retina. 1997;17:385-9.
15. American National Standards Institute. American national standard for the safe use of lasers: ANSI Z136.1. Orlando, FL: Laser Institute of America; 2000.
16. Delori FC, Dorey CK, Staurenghi G, et al. In vivo fluorescence of the ocular fundus exhibits retinal pigment epithelium lipofuscin characteristics. Invest Ophthalmol Vis Sci. 1995;36:718-29.

JAYPEE BROTHERS

for detailed information on ophthalmology books, visit our website www.jaypeebrothers.com, for detailed information on ophthalmolo

Gems of Ophthalmology
RETINA

Salient Features

- Describes the basic diagnostic procedures for retinal diseases—ophthalmoscopy, fundus fluorescein angiography (FFA), indocyanine green angiography (ICGA), and optical coherence tomography (OCT)
- Highlights the clinical features and management of diabetic retinopathy, hypertensive retinopathy, central retinal vein occlusion, etc.
- Diagnostic procedures of retinopathy of prematurity
- Presents a detail account of macular dystrophy and age-related macular degeneration
- Macular hole and giant retinal tears and their management
- Management of rhegmatogenous retinal detachment by vitreoretinal surgery
- Diagnosis and treatment of retinoblastoma.



HV Nema MS has a distinguished academic career and is well-known for teaching, research and publications. He has served as a Consultant Editor/Advisory Editor to Indian Journal of Ophthalmology, Afro–Asian Journal of Ophthalmology and Indian Journal of Optometry. He has published more than 6 dozen papers in the national and international journals. He is an established author in the field of ophthalmology. *Ophthalmic Syndromes* (Butterworth, London, UK, 1973) and *Textbook of Ophthalmology* (6th edition, 2012, Jaypee Brothers Medical Publishers, New Delhi, India) are some of his popular books. He has edited 13 volumes of *Recent Advances in Ophthalmology*, 3 editions of *Diagnostic Procedures in Ophthalmology* and *Eye in Systemic Disorders* (Wiley India) which were well-received by readers and favorably reviewed in Indian and international journals. He has delivered guest-lectures in many universities.



Nitin Nema MS DNB is a Professor of Ophthalmology at Sri Aurobindo Medical College and PG Institute, Indore, Madhya Pradesh, India. He is an experienced Vitreoretinal Surgeon. He did his Fellowship from Aravind Eye Hospital and PG Institute, Madurai, Tamil Nadu. He gained clinical and research experience from the University of Illinois at Chicago, and the University of Wisconsin at Madison in the USA. He was awarded a Fellowship by the All India Ophthalmological Society to work on a Project on Uveitis at Sankara Nethralaya, Chennai, Tamil Nadu. He was awarded Dr Mohan Lal Gold Medal for the best paper by UP State Ophthalmological Society. He had authored (in collaboration with Dr HV Nema) 2 textbooks: *Anatomy of the Eye and Adnexa* (3rd edition) and *Textbook of Ophthalmology* (6th edition), and edited 12 volumes of *Recent Advances in Ophthalmology*, and 3 editions of *Diagnostic Procedures in Ophthalmology*.

Available at all medical bookstores
or buy online at www.jaypeebrothers.com

JAYPEE BROTHERS
Medical Publishers (P) Ltd.
www.jaypeebrothers.com

Join us on facebook.com/JaypeeMedicalPublishers

Shelving Recommendation
OPHTHALMOLOGY

ISBN 978-93-5270-402-6