PGMEE books, visit our website **www.jaypeebrothers.com,** for detailed information on PGMEE books

# Review of NEET PG Pattern 2018

## Model Questions with Solved Explanatory Answers

Includes full color Image-based questions

**Mukesh Bhatia**
**Reetu Dogra**

**For suggestions and comments**
e-mail to us: contactdrbhatia@gmail.com, drreetudogra@dbmi.edu.in
Follow us on f: https://www.facebook.com/dbmci/?ref=bookmarks

*Contribution by*
**Rajat Jain**

*Edited by*
**DBMI Premiere Faculty**

JAYPEE

# Contents

*Image-Based Questions*

1. **Anatomy** 1
2. **Physiology** 8
3. **Biochemistry** 25
4. **Pathology** 35
5. **Pharmacology** 68
6. **Microbiology** 89
7. **Forensic Medicine and Toxicology** 97
8. **Orthopedics** 103
9. **Ophthalmology** 117
10. **ENT** 129
11. **Preventive and Social Medicine** 137
12. **Medicine** 155
13. **Surgery** 194
14. **Pediatrics** 217
15. **Gynecology and Obstetrics** 226
16. **Skin** 250
17. **Anesthesia** 262
18. **Radiology** 267
19. **Psychiatry** 279

# 1 Anatomy

**1. Nasopharyngeal chordoma arises from:**

A. Notochord
B. Endoderm
C. Mesoderm
D. Rathke's pouch

**2. Pain referred to ear in tonsillitis is due to:**

A. Facial nerve
B. Trigeminal nerve
C. Glossopharyngeal nerve
D. Vagus nerve

**3. About Sibson's fascia all are true except:**

A. Attached to the inner border of 2nd rib
B. Subclavian vein runs over it
C. Formed by scalenus anterior muscle
D. Covers apex of the lung

**4. Structure not passing through aortic opening:**

A. Thoracic duct
B. IVC
C. Aorta
D. Azygos vein

**5. What is the action of this Muscle (pointed) at metacarpophalangeal joint?**

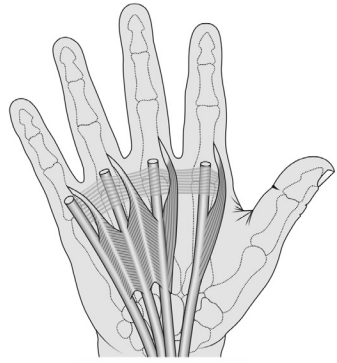

A. Abduction
B. Adduction
C. Flexion
D. Extension

JAYPEE BROTHERS

**6. Special visceral efferent fiber is not seen in:**

A. Trigeminal nerve
B. Facial nerve
C. Nucleus ambigus
D. Vagus nerve

**7. Nerves supplying pharyngeal arches are developed from:**

A. Mesoderm
B. Neural crest
C. Endoderm
D. Notochord

**8. Broca's area is situated in:**

A. Inferior frontal gyrus
B. Superior temporal gyrus
C. Inferior temporal gyrus
D. Angular gyrus

**9. Ureteric bud develops from?**

A. Metanephros
B. Mesonephric duct
C. Mesonephros
D. Genital sinus

**10. What is the feature of the muscle shown in the image below:**

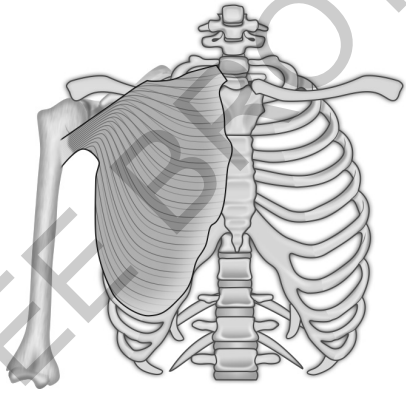

A. Cruciate
B. Multipennate
C. Spiral
D. Unipennate

**11. Which of the following statements is not true about iliolumbar ligament?**

A. Upper fibers attached to the iliac crest
B. Lower fibers attached to the base of sacrum
C. Help in maintaining the lumbosacral joint stability
D. Upper attachment to transverse process of T12

**12. Which of the following structure develops from dorsal mesentery?**

A. Greater omentum
B. Lesser omentum
C. Liver
D. Diaphragm

JAYPEE BROTHERS

## Answers with Explanations

**1. Ans. (A) Notochord**

- Chordoma is a rare slowgrowing neoplasm thought to arise from cellular remnants of the notochord.
- There are three histological variants of chordoma: Classical (or "conventional"), chondroid and dedifferentiated.
- The histological appearance of classical chordoma is of a lobulated tumor composed of groups of cells separated by fibrous septa. The cells have small round nuclei and abundant vacuolated cytoplasm, sometimes described as physaliferous (having bubbles or vacuoles).
- Chondroid chordomas histologically show features of both chordoma and chondrosarcoma.
- Chordomas can arise from bone in the skull base and anywhere along the spine. The two most common locations are cranially at the clivus and in the sacrum at the bottom of the spine.
- A possible association with tuberous sclerosis complex (TSC1 or TSC2) has been suggested.
- In most cases, complete surgical resection followed by radiation therapy offers the best chance of long-term control.
- Chordomas are relatively radioresistant, requiring high doses of radiation to be controlled. The proximity of chordomas to vital neurological structures such as the brainstem and nerves, limits the dose of radiation that can safely be delivered. Therefore, highly focused radiation such as proton therapy and carbon ion therapy are more effective than conventional X-ray radiation.
- The PDGFR inhibitor Imatinib and sirolimus can be used but only modest response.

**2. Ans. (C) Glossopharyngeal nerve**

**Referred (secondary) pain in ear causes are:**

- Via Trigeminal nerve [cranial nerve V]: Oral cavity carcinoma can also cause referred ear pain via this pathway.
- Via Facial nerve [cranial nerve VII]: This can come from the teeth, temporomandibular joint (due to its close relation to the ear canal), or the parotid gland.

JAYPEE BROTHERS

- Via Glossopharyngeal nerve [cranial nerve IX]: This comes from the oropharynx, and can be due to pharyngitis, pharyngeal ulceration, tonsillitis, or to carcinoma of the oropharynx (base of tongue, soft palate, pharyngeal wall, tonsils).
- Via Vagus nerve [cranial nerve X]: This can arise from the laryngopharynx in carcinoma of this area, or from the esophagus in GERD.
- Via the second and third spinal segments, C2 and C3.

**3. Ans. (A) Attached to the inner border of 2nd rib**

The **suprapleural membrane** is also known as **Sibson's fascia. Suprapleural membrane is:**

- Dome-shaped musculo – fascial expansion
- Muscular part – scalenus minimus muscle
- Fascial part – endothoracic fascia.

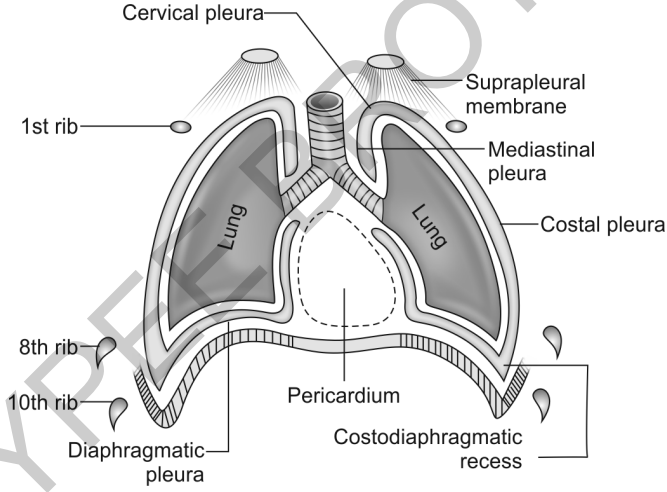


- Attachments:
  - In front—Inner border of the 1st rib
  - Behind—Tip of the transverse process of the 7th cervical vertebra
  - Medially—Continuous with the pretracheal fascia by the side of the trachea.
- Protects the apex of the lung and cervical pleura from the structures of the root of the neck.

JAYPEE BROTHERS

**4. Ans. (B) IVC**

| *Opening* | *Vertebral level* | *Location* | *Structures passing through* |
|---|---|---|---|
| Vena caval hiatus | T8 | Central tendon of diaphragm | • Inferior vena cava<br>• Right phrenic nerve |
| Esophageal hiatus | T10 | Muscular part at the right crus of the diaphragm | • Esophagus<br>• Vagus nerve<br>• Left inferior phrenic vessels |
| Aortic hiatus | T12 | Between the diaphragm and vertebral column | • Aorta<br>• Azygos vein<br>• Thoracic duct |

**5. Ans. C. Flexion**

- The lumbricals perform movements of the second to fifth finger. Their contraction leads to flexion at the metacarpophalangeal joints (MCP) and extension at both proximal (PIP) and distal interphalangeal joints (DIP).
- The reason for the opposite actions is that the tendons cross the MCP on the palmar side, but distally insert at the dorsal side of the finger.
- These combined movements support a strong hand grip (e.g. holding a pen).
- The muscle pointed is the first lumbrical which will flex the second MCP joint and extend the PIP and DIP joints of the index finger.

**6. Ans. (C) Nucleus ambigus**

- Special visceral efferent (SVE) fibers are the efferent nerve fibers that provide motor innervation to the muscles of the pharyngeal arches in humans.
- The only nerves containing SVE fibers are: Trigeminal nerve (V), facial nerve (VII), glossopharyngeal nerve (IX), vagus nerve (X) and accessory nerve (XI).
- Nucleus ambiguus contains the cell bodies of nerves that innervate the muscles of the soft palate, pharynx, and larynx which are strongly associated with speech and swallowing.
- The axons of these cell bodies will form the tract and run in the ninth, tenth and eleventh cranial nerves.

**7. Ans. (B) Neural crest**

Nerves supplying pharyngeal arches are developed from the cranial neural crest. The cranial neural crest arises in the cranial part of the

JAYPEE BROTHERS

embryo and populates the face and the pharyngeal arches giving rise to bones, cartilage, nerves and connective tissue. The endocranium and facial bones of the skull are ultimately derived from crest cells.
*Other places of Migration of cranial neural crest are:*

- Into the pharyngeal arches and play an inductive role in thymus development.
- Into the pharyngeal arches and form the parafollicular cell or ultimobranchial bodies of the thyroid gland.
- Into the pharyngeal arches and play an inductive role in the parathyroid gland development.
- Facial ectomesenchyme of the pharyngeal arches forming skeletal muscle, bone, and cartilage in the face.
- Odontoblasts (dentin-producing cells) of the teeth.
- Around the optic vesicle and the developing eye and contributes to many eye elements such as choroid, sclera, iris, and ciliary body. It also contributes to the attaching skeletal muscles of the eye.
- Into the otic placode and participates in the inner ear development.
- Sensory ganglia of the fifth, seventh, ninth and tenth cranial nerves.
- Schwann cells

**8. Ans. (A) Inferior frontal gyrus**

The inferior frontal gyrus includes the following areas:

- Brodmann area 44
- Brodmann area 45
- Brodmann area 47

Brodmann area 44 corresponds to Broca's area (sometimes Broca's area is taken to encompass Brodmann's areas 44 and 45) — for the dominant hemisphere of the brain.

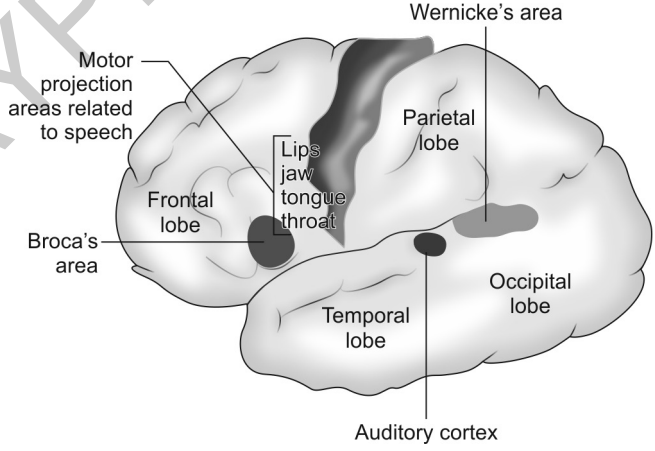


JAYPEE BROTHERS

**9. Ans. (B) Mesonephric duct**

The ureteric bud also known as the metanephrogenic diverticulum is a protrusion from the mesonephric duct. It later develops into a conduit for urine drainage from the kidneys which in contrast originate from the metanephric blastema.

**10. Ans. (C) Spiral**

- The muscle in the image is pectoralis major, which has spiral/twisted fascicular arrangement.
- Spiral or twisted fibers are also found in trapezius, latissimus dorsi and supinator.
- Pectoralis major may also be called as a convergent muscle (the fascicles extend from a broad, fan-shape area and converge on single attachment site where the muscle interacts with a tendon).
- In certain muscles the fasciculi are crossed. These are called cruciate muscles, e.g. sternocleidomastoid, masseter and adductor magnus.

**11. Ans. (D) Upper attachment to transverse process of T12**

- The iliolumbar ligament is a strong ligament passing from the tip of the transverse process of the fifth lumbar vertebra to the posterior part of the inner lip of the iliac crest (upper margin of ilium).
- It radiates as it passes laterally and is attached by two main bands to the pelvis.
- The lower bands/fibers run to the base of the sacrum; the upper band is attached to the crest of the ilium immediately in the front of the sacroiliac articulation, and is continuous above with the lumbodorsal fascia.
- In front, it is in relation with the Psoas major; behind with the muscles occupying the vertebral groove; above with the quadratus lumborum.
- The ililumbar ligament strengthens the lumbosacral joint.

**12. Ans. (A) Greater omentum**

- The derivatives of ventral mesentery are lesser omentum, falciform ligament, coronary ligament of liver and triangular ligament of liver.
- The derivatives of dorsal mesentery are greater omentum, gastrosplenic ligament, gastrocolic ligament, lienorenal ligament, mesentery of small intestine, mesoappendix, transverse mesocolon and sigmoid mesocolon.

JAYPEE BROTHERS

for detailed information on PGMEE books, visit our website **www.jaypeebrothers.com,** for detailed inf

# Review of NEET PG Pattern 2018

***Salient Features***

- Completely updated from Harrison 19th Edition, Robbins Pathology 9th Edition, Bailey and Love 26th Edition, Park 24th Edition, Ganong 25th Edition, Gray's Anatomy 41st Edition, Goodman and Gilman 12th Edition, with recent changes and updated tables
- First and only book in the market for the Latest NEET PG Exam Pattern
- Includes full color Image-based Questions
- Cover the topics asked in the exam completely so that students will answer any question about that topic easily if that comes in future exam
- Explanations are pointwise, so that students can remember them easily and follow as per their convenience
- All the questions are solved with authentic and verified answers, with relevant references given by the subject faculty of DBMCI
- High yielding MCQs are provided for last minute revision
- Schematic diagrams, tables, illustrations, bulleted key points and references are highlights will make reading and understanding of the material easier and effective
- Includes all type of latest NEET Pattern Questions with Image-based Questions as well
- A complete book in all the aspects
- Different books that are followed are:
  Anatomy—BD Chaurasia, Gray's Atlas; Biochemistry—Harper's Illustrated Biochemistry; Physiology—Ganong; Pathology—Robbins; Pharmacology—KD Tripathi, CMDT; Microbiology—Ananthanarayan, KD Chatterjee; Preventive and Social Medicine—Park; ENT—Dhingra; Ophthalmology—Parson, Khurana; Medicine—Harrison's Internal Medicine; Surgery—Bailey and Love, SRB Manual; Gyne/Obs—DC Dutta, Shaws; Pediatrics—Nelson, OP Ghai; Dermatology—Neena Khanna; Anesthesia-Morgan and Mikhail; Psychiatry-Niraj Ahuja



**Mukesh Bhatia** has done MBBS from MAMC, New Delhi, India. He is the first person in the entire India who gave the idea of PG Entrance Exams. He is the founder of these courses and the pioneer in the field. He is a Senior Consultant Physician, Fortis Hospital, Delhi. He is an Eminent Educationist, Excellent Teacher, Author of bestselling books, Orator and Guide to students in choosing their career (branch and college). He has been teaching PG aspirants for more than 20 years. Till date he has taught entire Medicine to more than 1.25 lacs students all over India, Nepal and China. He has an unique, crisp and concise style of teaching Medicine. He summarizes the entire subject of Medicine in such a way that after attending his classes, students can revise the whole Medicine in just 3 hours. He is considered as 'God of Medicine' by the students. For his services to Education, he has been blessed by the former Prime Minister Dr Manmohan Singh and the former President Mr Pranab Mukherjee. His book was released by Chief Justice of India, honorable former Justice TS Thakur.



**Reetu Dogra** has done MBBS from Government Medical College, Jammu, Jammu and Kashmir, India. Being a meritorious student and topper in her school and among the toppers in the college exams, she was awarded DBT Scholarship by Government of India, Department of Biotechnology under Ministry of Science and Technology, New Delhi for her excellent achievements in her academic carrier in 2008. She has cleared AIIMS, PGI, JIPMER, NEET, JK PG CET Exams many times but being inclined towards the academic side, she decided to be academician and helping the PG aspirants in achieving their dream branch. She has previously worked in the PGI Chandigarh and in AIIMS Pathology department. She is currently working as Academic Director in Dr Bhatia Medical Coaching Institute (DBMCI), New Delhi. She has immense knowledge of various exam patterns and various counseling being conducted by the different authorities thus helping students in counseling process as well. She has contributed a lot to the latest edition of DBMCI books particularly Dr Bhatia's Medicine Books.

**Available at all medical bookstores**
**or buy online at www.jaypeebrothers.com**

JAYPEE BROTHERS
Medical Publishers (P) Ltd.
www.jaypeebrothers.com
Join us on facebook.com/JaypeeMedicalPublishers

ISBN 978-93-5270-510-8
9 789352 705108