visit our website **www.jaypeebrothers.com,** for detailed information on obstetrics & gynecology books, visit our website **www.jaypeebrothers.com**

Celebrating 50 YEARS
Passion, Quality and Innovation in Healthcare Publishing

Fibroids

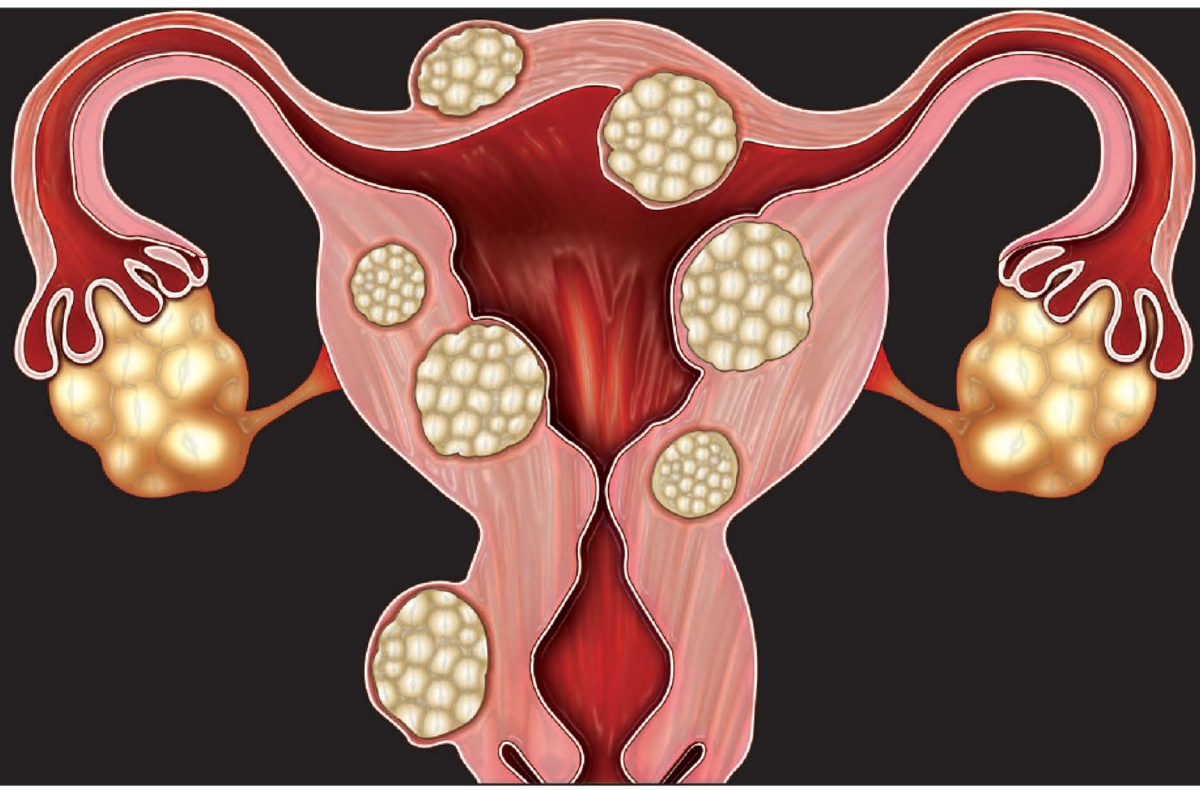

Editors
Narendra Malhotra
Poonam Goyal

Co-Editors
Jaideep Malhotra
Bhavana Mittal

Foreword
Alka Kriplani (Padma Shri)

JAYPEE

Contents

1. **Understanding Fibroids** 1
   Arti Luthra, Narendra Malhotra, Jaideep Malhotra
2. **Diagnosis of Fibroids** 13
   Ankesh R Sahetya, Divya Sahetya
3. **Clinical Rainbow of Fibroids** 24
   Poonam Goyal
4. **Management of Fibroids in Adolescent Girl** 31
   Vimee Bindra, Shaik Meera Esha
5. **Fibroids and Infertility** 36
   Bhavana Mittal
6. **Fibroids in Pregnancy** 41
   Dhaval A Baxi, Sonam D Baxi
7. **Management of AUB with Fibroid** 49
   Kundan Ingale, Ashish Kale
8. **Management of Fibroids in Perimenopausal Women** 61
   Esha Sharma
9. **Management of Fibroids in a Menopausal Woman** 69
   Selvapriya Saravanan
10. **Can We Leave Fibroids Alone?** 74
    Anuradha Khar
11. **Surgical Management of Fibroids** 79
    Rajalaxmi Walavalkar, Garima Sharma, Vimee Bindra
12. **Controversies Regarding Fibroid Morcellation** 96
    Prakash Trivedi, Soumil Trivedi, Sandeep Patil
13. **Medical Management of Fibroids** 106
    Poonam Loomba, Poonam Goyal
14. **Newer Nonsurgical Treatment Options for Fibroids** 117
    Shalu Gupta, Meenu Handa
15. **Fibroids and Malignancy** 126
    Reeta Mahey, Venus Dalal
16. **Recurrence and Treatment Outcomes in Fibroids** 130
    Kavitha Gautham
17. **Fibroids and Sexual Dysfunction** 139
    Mohit Rajendra Saraogi

18. Fibroids and Gastrointestinal Symptoms....143
Sunita Chandra, Poonam Goyal

19. Genitourinary Dysfunction in Uterine Fibroids....146
Rutvij Dalal

20. Infrequent or Atypical Fibroid Syndrome....152
Neha Priyadarshini

21. What's New in the World of Fibroids?....161
Apoorva Pallam Reddy

22. How Much Should She Worry? Reassuring Patients with Fibroids....172
Rakhi Singh, Seema Pandey

23. Holistic Approach to Fibroids....179
Gunjan Gupta

24. Uterine Fibroid in a Nutshell....185
Ruchika Garg

25. Case Scenarios....191
Diksha Goswami Sharma, Anita Kant

26. Perplexing Situations with Fibroids....207
Poonam Goyal

27. Counseling in a Patient of Fibroid....209
Poonam Goyal

28. Emerging and Hopeful Strategies toward Nonsurgical Management of Fibroids....211
Narendra Malhotra, Manpreet Sharma, Shemi Bansal, Poonam Goyal, Jaideep Malhotra

29. Ulipristal: Experience in Few Cases....216
Poonam Goyal

30. Fibroid Management Guidelines....222
Kavita Agarwal

Index....227

4

Management of Fibroids in Adolescent Girl

Vimee Bindra, Shaik Meera Esha

INTRODUCTION

- Uterine myomas are the most common tumors of the female pelvis.
- Approximately one-third of women are diagnosed with fibroids.
- Myomas are rarely present in pediatric and adolescent age group but if suspected, on clinical history or examination, evaluation should be done properly to rule out adnexal pathologies in this age group.
- Biologic behavior of these tumors is unknown in this age group as well as there is a dilemma for appropriate management.
- Etiology of these tumors in this age group is not well-known; it has been suggested that there may be some intrinsic abnormalities in the myometrium due to elevated sex steroid levels or due to myometrial insult or injury during menstruation.

CLINICAL PRESENTATION

Symptomatic

- Most common complaints are irregular or heavy uterine bleeding
- Compression symptoms due to pelvic mass such as urgency and frequency of urine, and constipation
- Pelvic pain
- Symptoms in adolescent population usually are same as general population suffering from fibroids.

Incidental Findings

- Fifty percent of fibroids are asymptomatic which is not always correct because of under-reporting of cases.
- In adolescent population, approximately 87% of fibroids are symptomatic and rest is detected on routine ultrasound and examination.

DIAGNOSIS

Clinical Examination

Fibroids can be detected on clinical examination by determining the size and shape of uterus but in case of adolescent girls, bimanual examination is not possible so small fibroids may

JAYPEE BROTHERS

be missed. Clinically significant fibroids can be identified on abdominal examination in young girls. For big fibroids to differentiate from adnexal mass, we have to go for sonography or magnetic resonance imaging (MRI).

Ultrasound

Ultrasound uses the high frequency sound waves to create a picture of pelvic organs. Sonographic appearance of fibroids may widely vary but usually they appear as hypoechoic, well-defined heterogeneous masses. Sonography may not be accurate in determining the exact position and number of fibroids. Once the fibroids are diagnosed, it is also important to confirm the diagnosis in adolescent girls by doing MRI as it is very common to find an adnexal mass in this age group.

Magnetic Resonance Imaging

Magnetic resonance imaging by the use of magnetic field forms the images and once we diagnose the fibroids, it is important to know the exact location and number of fibroids which guides us in further management and decide the type of surgery as well. There are advantages of MRI that it is operator-independent and also low interobserver variations and does not use ionizing radiation. MRI has a sensitivity of 88–93% and a specificity of 66–91%. In some cases, it may be difficult to differentiate a large exophytic subserosal fibroid from an adnexal mass such as ovarian neoplasm which is a very common finding in adolescent age group. Differentiation is very imperative as it helps in deciding the treatment and also important for prognostic implications. MRI has a great advantage in making this distinction and it helps us in avoiding unnecessary laparoscopy or exploratory laparotomy. An important feature to identify uterine masses on MRI is "Bridging Vascular Sign" and in cases of exophytic fibroid away from the uterus, this sign helps in identifying it to be uterine in origin.

DIFFERENTIAL DIAGNOSIS

- Differential diagnosis of these tumors in adolescents is important. An increase in the abdominal volume due to pelvic mass should always alert the attending gynecologist to rule out the adnexal mass which is very common in this age group.
- Müllerian adenosarcomas are low-grade tumors which can affect teenagers and must be remembered.
- When leiomyoma protrudes through the cervical canal, it must be differentiated from sarcoma botryoides, a rare tumor originating from the vaginal mucosa which mainly affects adolescents.

MANAGEMENT (FLOWCHART 4.1)

There is no proved consensus on the type of treatment in adolescent population and treatment is usually extrapolated from general population suffering from fibroids.

Medical

Medical treatment is only used for short-term symptomatic relief because of risks associated with long-term treatment or the benefits with long-term treatment have not been proved till date. These are the following indications for medical treatment:

- For short-term symptomatic relief from pain or bleeding.
- As a preoperative adjunct to either reduce the size of fibroid before surgery or raise the hemoglobin level in case of concomitant anemia. Usually gonadotropin-releasing hormone (GnRH) analogs are currently used for this purpose.

JAYPEE BROTHERS

Flowchart 4.1: Management.

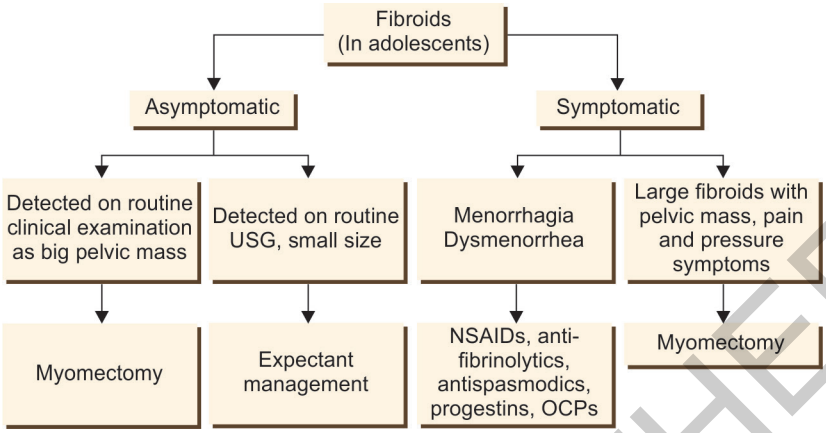

(USG: Ultrasonography; NSAIDs: Nonsteroidal anti-inflammatory drugs; OCPs: Oral contraceptive pills)

- As a part of research for newer drugs.
  - *Tranexamic acid (antifibrinolytic agents)*: It is used only during menstrual cycle to reduce the amount of blood loss. It has been shown to reduce bleeding by 60%.
  - *Progestins alone and medroxyprogesterone acetate can be given to reduce the bleeding.*
  - *Combined oral contraceptives* are widely used in cases of fibroids for reducing the amount of bleeding, but they also provide short-term relief.
  - *GnRH analogs* in adolescent girls for fibroids are only used as preoperative adjunct to reduce the size of fibroid and to raise the hemoglobin level in case of anemia. A Cochrane systematic review has shown that preoperative GnRH analog prior to myomectomy or hysterectomy has improved hemoglobin and hematocrit significantly. It also reduces the tumor volume, size, and pelvic symptoms significantly.
  - *Ormeloxifene*: It can be used if symptoms are of abnormal uterine bleeding. It does not have effect on size of fibroid. It is more patient- friendly drug.

Surgical

- Myomectomy is the best surgical treatment as it:
  - Preserves fertility
  - Most durable owing to low recurrence rate of fibroids
  - Does not interfere with the reproductive development of adolescent girl
  - Preferably if possible and surgical expertise is available, laparoscopic myomectomy should be preferred over abdominal myomectomy because of its well-known advantages of early recovery, less blood loss, less adhesions which will take care of her reproductive performance later in life.
  - Hysteroscopic myomectomy can be considered if the fibroid is completely submucous and she presents with bleeding problems and anemia. Proper counseling should be done prior to doing hysteroscopic myomectomy in an adolescent girl.
- Remote possibility of hysterectomy should always be discussed when planning myomectomy of adolescent patients.

JAYPEE BROTHERS

Newer Conservative Methods

Newer conservative treatments are available, but still not sufficient evidence to determine their efficacy in adolescent population.

- Ulipristal acetate is a selective progesterone receptor modulator (SPRM); has been used in adult population and has given a success rate of reaching amenorrhea of 70–80% and also a faster onset of 4 median days to achieve it and also the adverse effects are much lesser as compared to GnRH analogs. But this drug has not been used in girls below 18 years of age.
- Aromatase inhibitors are very much similar to GnRH analogs, but have not been tested on younger population in trials.
- *Uterine artery embolization (UAE)*: It is a percutaneous image-guided procedure performed by highly trained interventional radiologist. No case series in young population but has shown very good results in women over 18 years of age. One case has been reported where UAE was successfully used for a 12-year-old girl and she was saved from life-threatening hemorrhage.
- High-intensity focused ultrasound (HIFU) or magnetic resonance-guided focused ultrasound surgery (MRgFUS) has also shown promising results in women more than 18 years of age but no studies in young women or adolescent girls. It is a new method of thermal ablation which uses high-intensity focused ultrasound through the anterior abdominal wall to a certain focused point to induce the coagulative necrosis of the fibroid. Use of MRI helps in targeting the right tissue and also helps in thermal control.

RISK OF MALIGNANCY

One must think of malignancy in older age group especially with a rapidly growing tumor. Chance of malignancy in adolescent age group is practically nil as uterine sarcomas are nonexistent in this age group. But in case of rapidly increasing tumor or sudden appearance of tumor, potential of malignancy or cellular leiomyoma must be kept in mind. There is a case report of cellular leiomyoma by Morad and El Said in 15-year-old girl.

IMPLICATIONS ON FUTURE FERTILITY

Fertility outcomes and pregnancy outcomes are similar across all types of surgical procedures, be it abdominal, laparoscopic or robotic myomectomy. As far as possible, minimally invasive approach is chosen over abdominal approach for better outcomes. Fibroids per se do not cause infertility; they are mostly associated with subfertility and rarely are a sole cause of infertility. If infertility is an issue in a patient with fibroids, she and her partner should be evaluated thoroughly to find out the associated causes of infertility as well.

COUNSELING

- Counseling, counseling, and counseling. It is very important whenever a decision to operate the patient is undertaken especially in adolescent age group. Appropriate preoperative counseling and discussion is very important also to decide the type of surgery and diagnosis as in most of these cases the diagnosis may be changed for adnexal mass in case of uterine fibroid and vice versa in case of adnexal mass and this should be properly informed to parents and they should be counseled in detail regarding the best course of action in either case.
- If uterine mass is suspected then preservation of fertility should be discussed in detail and also the need for hysterectomy if needed to save the patient.
- In case adnexal mass is suspected, counseling would center around the ovarian or tubal procedure and discussion about future fertility.

JAYPEE BROTHERS

Flowchart 4.2: Follow-up.

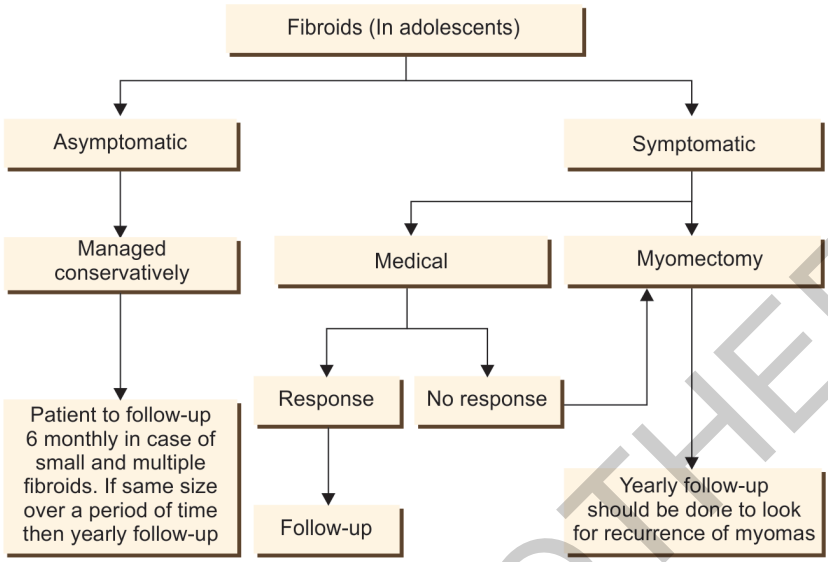

FOLLOW-UP (FLOWCHART 4.2)

- In young adolescent girl, if fibroids are detected incidentally and small in size, they should be called for 6 monthly follow-up to monitor the size and growth of fibroids and if it remains same over a period of time, they can be called for yearly follow-up.
- Multiple myomas and big myomas are a risk factor for recurrence and patient should be followed up after myomectomy regularly to look for its recurrence. Once a year follow-up is considered good to see for its recurrence.

CONCLUSION

- It is certain that the biologic behavior of fibroids in adolescents is different from other population.
- Ultrasound is usually sufficient for differentiating between the adnexal mass and myoma, but MRI is superior to ultrasound in case of doubt about the diagnosis.
- Best treatment is still not defined, but myomectomy for big fibroids is a preferable option to preserve their fertility.
- Myomas should always be kept in differential diagnosis in adolescents when dealing the pelvic masses.

BIBLIOGRAPHY

1. Bowkley C, Dubel G, Haas R, et al. Uterine artery embolisation for control of life threatening hemorrhage at menarche: brief report. J Vasc Interv Radiol. 2007;18:127-31.
2. Donnez J, Vazquez F, Tomaszewski J, et al. Long term treatment uterine fibroids with ulipristal acetate. Long term treatment of uterine fibroids with ulipristal acetate. Fertil Steril. 2014;101(6):1565-73.
3. Fields KR, Neinstein LS. Uterine myomas in adolescents: Case reports and review of literature. J Pediatr Adolesc Gynecol. 1996;9:195-8.
4. Lethaby A, Vollenhoven B, Sowter M. Preoperative GnRH analogue therapy before hysterectomy or myomectomy for uterine fibroids. Cochrane Database Syst Rev. 2000;(2):CD000547.
5. Livermore JA, Adusumilli S. MRI of benign uterine conditions. Appl Radiol. 2007;36(9):8-18.
6. Morad NA, El-Said MM. Cellular uterine myoma causing vaginal bleeding in a 15 year old girl. Aust NZ J Obstet Gynaecol. 1993:33;211-3.
7. Parker W. Etiology, symptomatology and diagnosis of uterine myomas. Fertil Steril. 2007;87:725-36.

JAYPEE BROTHERS

or detailed information on obstetrics & gynecology books, visit our website **www.jaypeebrothers.com,** for detailed information on obstetrics & gy

Fibroids

Fibroids has been dedicatedly written for the practicing gynecologists keeping in mind that fibroids are a common occurrence resulting in abnormal uterine bleeding (AUB), infertility and poor obstetric outcome causing a tremendous health burden on society. It aims to provide clinical guidelines on effective patient care. It stresses upon when it is not wise to touch the fibroids and also covers experiment with newer medical and nonsurgical treatments.

Narendra Malhotra is the Management Director, Global Rainbow Healthcare, Agra, Uttar Pradesh, India and Vice President at the World Association of Prenatal Medicine. He is the current President of the Indian Society for Prenatal Diagnosis and Therapy (ISPAT) and Past President of the Federation of Obstetric and Gynaecological Societies of India (FOGSI). He is Member and Fellow of different Indian and international organizations. He has published 65 papers and presented approximately 300 papers. Along with this, he had given 300 guest lectures and edited 25 books such as the revision of the Jeffcoate's Principles of Gynaecology. He has been awarded different awards like the Corion Award, the Man of the Year Award, and the Best Citizens of India Award.

Poonam Goyal is an ART Specialist and Ultrasonologist, Department of IVF and Infertility, Max Superspecialty Hospital, New Delhi, India. She is a graduate from the Government Medical College, Patiala, Punjab, India and MD from Lala Lajpat Rai Memorial Medical College, Meerut, Uttar Pradesh, India. She was a brilliant student throughout her studies. She was invited as a Faculty in the International Conference on Endometriosis and also in World Perioncology Conference. She has presented papers in various national conferences. She has authored and edited a book on Endometriosis and Fibroids.

Jaideep Malhotra is the Management Director, Rainbow IVF, Agra, Uttar Pradesh, India and President, FOGSI. She is President Elect of ISAR, ISPAT, SAFOG. She is a leading IVF specialist in India and managing several centres such as the Rainbow IVF in Agra. She is a Member of several Indian and international organizations such as the Reproductive Endocrinology and Infertility of the International Federation of Gynaecology and Obstetrics. She was the editor of several publications such as the Managing Infertility in Low Resource. She has been credited for 300 test tube babies of Nepal.

Bhavana Mittal is the Director of Shivam IVF Centre in Delhi, India, and Consultant at Max IVF in Vaishali, Ghaziabad, Uttar Pradesh, India. She is an Executive Member of Delhi Indian Society For Assisted Reproduction (ISAR), Delhi. She has also been an active speaker and organizer at various National Level Conferences. She has provided infertility trainings to many doctors from India and abroad. She has authored many books on IUI, fibroid and endometriosis.

Available at all medical bookstores
or buy online at www.jaypeebrothers.com



JAYPEE BROTHERS
Medical Publishers (P) Ltd.
www.jaypeebrothers.com

Join us on facebook.com/JaypeeMedicalPublishers

Shelving Recommendation
OBSTETRICS & GYNECOLOGY

