e www.jaypeebrothers.com, for detailed information on dental books, visit our website www.jaypeebrothers.com

Celebrating 50 Years
Passion, Quality and Innovation in Healthcare Publishing

Clinical Diagnosis in Oral Medicine

A Case-based Approach

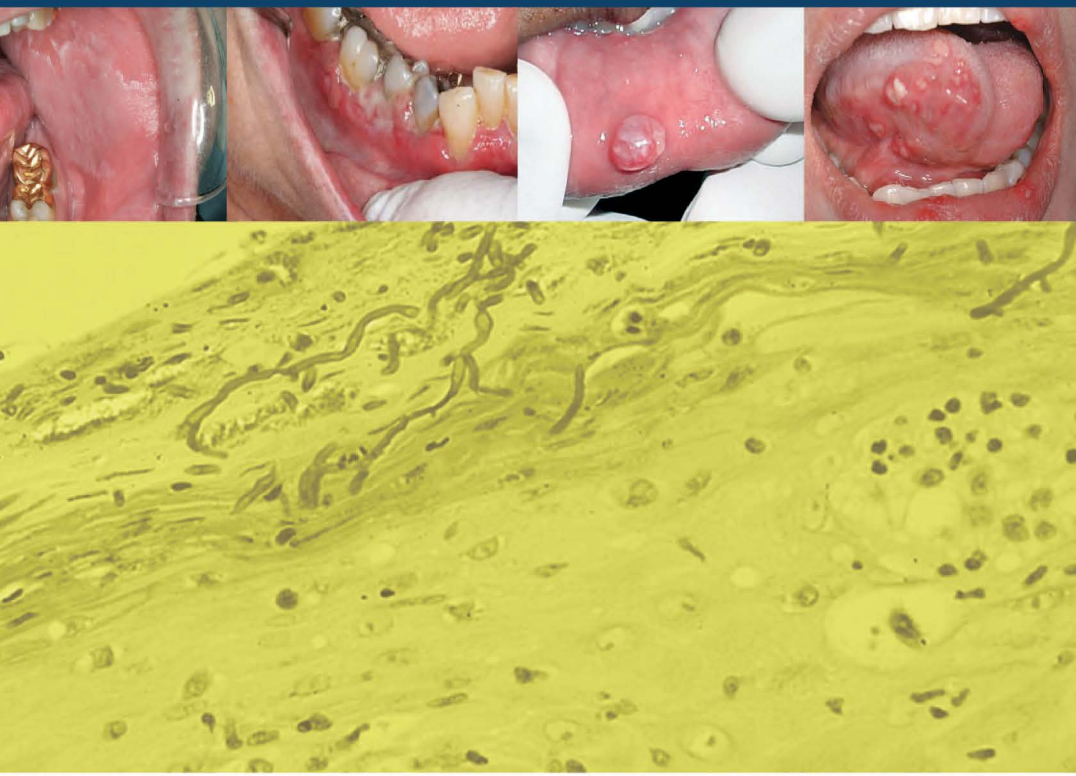

SR Prabhu

Foreword
Pauline Ford

JAYPEE

Contents

Chapter 1. Benign Mucosal White Lesions **1**

Diagnostic Approaches to Mucosal White Lesions: Some basic facts

- **Case 1A:** An adult male reports for a routine dental check-up. Examination reveals a linear white lesion on the buccal mucosa *10*
- **Case 1B:** An adult male complains of a rough white patch on the left buccal mucosa *10*
- **Case 1C:** A young adult male seeks routine dental consultation. Examination reveals a white patch on the left buccal mucosa *11*
- **Case 2:** An adult male reports for a routine dental examination. Examination reveals a cloudy gray colored buccal mucosa *13*
- **Case 3:** An adult male attends an oral cancer screening program. Examination reveals multiple granular white lesions on the right and left buccal mucosae *15*
- **Case 4A:** A middle-aged male reports for routine dental examination. Examination reveals a thick raised white patch involving the hard palate *17*
- **Case 4B:** A 55-year-old male presents with white patch involving the hard palate *18*
- **Case 5:** A young adult male reports for a routine dental examination. Examination reveals corrugated white patches on the lateral surfaces of the tongue *20*
- **Case 6:** An elderly male complains of sore mouth and multiple white patches in the mouth *23*
- **Case 7:** A middle-aged male complains of a white 'wart-like' growth on the hard palate *26*

Chapter 2. Benign Mucosal Red Lesions **29**

Diagnostic Approaches to Mucosal Red Lesions: Some basic facts

- **Case 1:** An elderly male presents for a routine dental check-up. Oral examination reveals multiple red spots on the tongue and lips *35*
- **Case 2:** A 50-year-old female presents with a raised red lesion on the mucosa of the lower lip *37*
- **Case 3:** A 49-year-old female complains of sore red gums *40*
- **Case 4A:** A young boy is brought to the oral medicine clinic with a history of painful oral ulcers *44*

- **Case 4B:** An adult male complains of painful red patches in the mouth and lips *45*
- **Case 5A:** An elderly denture wearer male complains of discomfort and mild burning sensation on the palate *48*
- **Case 5B:** An elderly male complains of ill-fitting maxillary complete denture *49*
- **Case 5C:** A 46-year-old female complains of redness of the mucosal surface covered by the partial denture *49*
- **Case 6:** A young male complains of red margins of the gums *53*
- **Case 7A:** A middle-aged male complains of mild burning sensation on the tongue *55*
- **Case 7B:** A middle-aged male complains of persistent bad breath *56*
- **Case 7C:** A 50-year-old male complains of sensitivity to spicy food on the dorsum of the tongue *56*
- **Case 8:** A middle-aged Indian male complains of a painful red patch on the palate *59*
- **Case 9A:** A young female complains of mild burning sensation on the tongue *61*
- **Case 9B:** A middle-aged male complains of alterations in taste *62*
- **Case 10:** An elderly male complains of painful angles of the mouth *64*

Chapter 3. Mucosal White and Red Lesions and Disorders with Malignant Potential 68

Diagnostic Approaches to Potentially Malignant Mucosal White and Red Lesions and Disorders: Some basic facts

- **Case 1A:** A middle-aged male complains of a white patch on the left buccal mucosa *77*
- **Case 1B:** A 58-year-old male complains of a mixed white and red patch on the right commissure *77*
- **Case 1C:** A middle-aged male complains of a white patch on the hard palate *78*
- **Case 2:** An elderly male reports for repair of a lower partial denture. Examination reveals a white patch in the floor of the mouth *90*
- **Case 3:** A 48-year-old male reports for a routine dental examination. Oral examination reveals a white lesion involving the entire lower labial sulcus *94*
- **Case 4A:** A middle-aged female complains of sore buccal mucosa *98*
- **Case 4B:** A 51-year-old male complains of bilateral white lesions on the buccal mucosae *98*
- **Case 4C:** A middle-aged female complains of sore mouth *99*
- **Case 5:** An elderly male reports with a history of scaly red lesions on the lower lip *104*

- **Case 6:** A 60-year-old male presents with mixed white and red patches at the commissures *107*
- **Case 7A:** A middle-aged male complains of stiffness of the cheek mucosa *112*
- **Case 7B:** An elderly female complains of restricted mouth opening *112*
- **Case 8:** A 49-year-old male complains of a red patch on the hard palate *117*
- **Case 9:** A 47-year-old male with a history of lupus erythematosus complains of a sore red patch on the left cheek mucosa *120*
- **Case 10:** A young female complains of a white patch on the left cheek mucosa following restorative dental procedures carried out a few days previously *124*

Chapter 4. Benign Mucosal Pigmented Lesions and Disorders 131

Diagnostic Approaches to Mucosal Pigmented Lesions: Some basic facts

- **Case 1A:** A young male complains of black patch on the tongue and altered taste *138*
- **Case 1B:** An elderly male complains of brown patch on the tongue *138*
- **Case 2:** A young male presents with multiple pigmented lesions on the vermillion and around the lips *140*
- **Case 3:** A young male of African descent reports for treatment on his maxillary anterior teeth. Examination reveals dark brown patches on the alveolar mucosa and gums *142*
- **Case 4A:** A young male reports for a routine dental check-up. Examination reveals a pigmented lesion on the soft tissues around the crown of the mandibular first molar *144*
- **Case 4B:** An adult male reports for a routine dental examination. Examination reveals a pigmented lesion on the edentulous lower alveolar ridge *144*
- **Case 5:** A young female reports for a routine dental check-up. Examination reveals a raised pigmented lesion on the lower lip *147*
- **Case 6:** A 35-year-old male reports for a routine dental examination. Oral examination reveals a flat pigmented lesion on the lower lip *149*
- **Case 7:** A young male with a history of HIV disease presents for routine oral examination. Examination reveals pigmentation of the buccal mucosa *151*

Chapter 5. Benign Mucosal Blisters, Erosions, and Ulcers 154

Diagnostic Approaches to Blisters, Erosions and Ulcers: Some basic facts

- **Case 1A and B:** A 53-year-old female complains of blisters and sore mouth *164*

- **Case 2:** A 41-year-old male complains of multiple painful ulcers in the mouth *168*
- **Case 3A:** A 13-year-old girl complains of painful ulcers in mouth and lips *172*
- **Case 3B:** A 11-year-old girl complains of painful ulcers on the tongue and gums *173*
- **Case 4:** A 30-year-old female complains of painful blisters on the lower lip *176*
- **Case 5:** An elderly male complains of blood-filled blisters on the palate *178*
- **Case 6:** A 29-year-old female complains of ulcers on the soft palate *180*
- **Case 7A:** A 57-year-old male complains of blisters on the right side of the face, upper lip and the mouth *183*
- **Case 7B:** An adult male complains of painful ulcers on the right side of the tongue and cheek mucosa *183*
- **Case 8:** A 45-year-old male complains of gingival ulcers and oral malodor *187*
- **Case 9A:** A 20-year-old male complains of sore palate *190*
- **Case 9B:** A 45-year-old HIV-positive male complains of a large painful ulcer on the palate *191*
- **Case 9C:** A 38-year-old female complains of painful ulcers on the buccal mucosa *191*
- **Case 10:** An adult male presents with a painless ulcer on the tongue *196*
- **Case 11:** A middle-aged male complains of an ulcer on the right lateral surface of the tongue *198*
- **Case 12:** A 30-year-old male presents with an ulcer at the tip of the tongue *201*

Chapter 6. Benign Mucosal Swellings 205

Diagnostic Approaches to Mucosal Swellings: Some basic facts

- **Case 1A:** A young female presents with a swelling on the gums between maxillary central incisors *210*
- **Case 1B:** A young male complains of a fleshy growth on the anterior part of the palate *210*
- **Case 1C:** A young adult female complains of a swelling on the buccal aspect of the gingiva in relation to the right mandibular second premolar *211*
- **Case 2:** An elderly edentulous denture wearer reports with a history of a lump in the left mandibular vestibule *216*

- **Case 3A:** A middle-aged male on cyclosporin therapy presents with gingival enlargement *218*
- **Case 3B:** A young male presents with mandibular gingival swelling *219*
- **Case 3C:** A young male complains of bleeding from the swollen gingiva *219*
- **Case 4:** A 10-year-old boy is brought to the clinic with a complaint of a persistent swelling of the lower lip and painful cracks at the angle of the mouth *226*
- **Case 5A:** A 21-year-old male presents with a painless soft swelling on the lower lip *230*
- **Case 5B:** A 17-year-old boy complains of a fluctuant swelling on the labial mucosa *230*
- **Case 5C:** A 19-year-old male presents with a swelling on the floor of the mouth *231*
- **Case 6:** A 55-year-old male presents with a painless swelling in the palate *234*
- **Case 7A:** An adult male presents with a painless growth on the cheek mucosa *236*
- **Case 7B:** A 24-year-old male presents with a soft swelling on the dorsum of the tongue *239*

Chapter 7. Oral Cancer (Squamous Cell Carcinoma) and Other Malignancies 243

Diagnostic Approaches to Oral Cancer: Some basic facts

- **Case 1A:** A 58-year-old male reports with a history of a growth on the right buccal mucosa and the labial commissure *244*
- **Case 1B:** A 56-year-old male presents with a history of a white lesion and pain on the left buccal mucosa *244*
- **Case 1C:** An elderly male reports with a history of a painful ulcer on the left buccal mucosa *245*
- **Case 1D:** A middle-aged male presents with a growth on the right border of the tongue *245*
- **Case 1E:** A middle-aged male complains of a white plaque and a growth on the left border of the tongue *246*
- **Case 1F:** A middle-aged male reports with a fungating growth on the left ventral surface of the tongue *246*
- **Case 1G:** An elderly male presents with a swelling in the right submandibular region. Patient also reports of an intraoral growth on the same side *247*
- **Case 2A:** A 57-year-old male complains of a growth involving the left buccal mucosa *257*

- **Case 2B:** A middle-aged male complains of a large growth involving the right side of the tongue *258*
- **Case 3A:** A 51-year-old male presents with a large bluish/black growth on the lower anterior gingivae and the floor of the mouth *261*
- **Case 3B:** A 48-year-old male presents with a blue colored growth on the palate *262*
- **Case 4:** A 42-year-old male complains of a fleshy growth on the palate *265*

Chapter 8. Dental and Orofacial Pain 269

How to Record Pain History

- **Case 1:** An adult male reports with moderate to severe pain in a carious left mandibular molar. Examination points to a diagnosis of acute pulpitis *271*
- **Case 2:** A 57-year-old female complains of severe stabbing intermittent pain on the right side of the face. On examination of the teeth and oral structures no abnormality is detected *274*
- **Case 3:** A female aged 59 years complains of oral mucosal burning sensation of several months duration *278*
- **Case 4:** A female aged 41 years complains of severe facial pain on the left side of the maxilla *281*

Chapter 9. Miscellaneous Disorders 285

- **Case 1A:** A 36-year-old male complains of mild pain and swelling of the left side of the face *286*
- **Case 1B:** A 33-year-old female complains of acute pain and swelling of the left side of the face *286*
- **Case 2:** A young adult complains of inability to move facial muscles on one side and taste alterations *294*
- **Case 3:** A middle-aged male complains of bilateral facial swelling and dry mouth *298*
- **Case 4:** An elderly male complains of severe pain and ulceration in the mouth following radiation therapy for head and neck cancer *305*
- **Case 5A:** A middle-aged male with a history of radiation therapy for oral cancer complains of bone exposure in the lower jaw *309*
- **Case 5B:** An elderly male on medication for osteoporosis complains of bone exposure in the lower jaw *310*

Appendices

1. ***Clinical and histological nomenclature used in oral medicine 319***
2. ***Definitions of mucosal lesions/disorders 323***

3. Clinical differential diagnosis of mucosal lesions and disorders 330

Table A3.1: Clinical differential diagnosis of mucosal benign white lesions 330

Table A3.2: Clinical differential diagnosis of mucosal benign red lesions 335

Table A3.3: Clinical differential diagnosis of mucosal white and red lesions or disorders with malignant potential 340

Table A3.4: Clinical differential diagnosis of mucosal pigmented lesions and disorders 348

Table A3.5: Clinical differential diagnosis of mucosal blisters, erosions and ulcers 355

Table A3.6: Clinical differential diagnosis of mucosal and other oral soft tissue swellings 365

Table A3.7: Clinical differential diagnosis of oral cancer (squamous cell carcinoma) and other less common malignant disorders 374

Table A3.8: Clinical differential diagnosis of dental and orofacial pain disorders 378

Index 387

4

CHAPTER

Benign Mucosal Pigmented Lesions and Disorders

JAYPEE BROTHERS

Chapter Outline

Diagnostic approaches to mucosal pigmented lesions: Some basic facts

- Case 1A: A young male complains of black patch on the tongue and altered taste
- Case 1B: An elderly male complains of brown patch on the tongue
- Case 2: A young male presents with multiple pigmented lesions on the vermillion and around the lips
- Case 3: A young male of African descent reports for treatment on his maxillary anterior teeth. Examination reveals dark brown patches on the alveolar mucosa and gums
- Case 4A: A young male reports for a routine dental check-up. Examination reveals a pigmented lesion on the soft tissues around the crown of the mandibular first molar
- Case 4B: An adult male reports for a routine dental examination. Examination reveals a pigmented lesion on the edentulous lower alveolar ridge
- Case 5: A young female reports for a routine dental check-up. Examination reveals a raised pigmented lesion on the lower lip
- Case 6: A 35-year-old male reports for a routine dental examination. Oral examination reveals a flat pigmented lesion on the lower lip
- Case 7: A young male with a history of HIV disease presents for routine oral examination. Examination reveals pigmentation of the buccal mucosa

DIAGNOSTIC APPROACHES TO MUCOSAL PIGMENTED LESIONS: SOME BASIC FACTS

Accurate diagnosis of mucosal pigmented lesions depends on the history, examination and appropriate investigations.

Definition

A definition of a *pigmented* lesion may include any area of altered coloration of the oral mucosa due to the deposition of endogenous or exogenous pigments or foreign material in the tissues.

Source of the Pigmentation

A broad distinction must be made between lesions caused by endogenous pigment producing or containing cells and those resulting from exogenous materials deposited within the tissues of the oral mucosa.

The Color of the Pigmented Lesions

Patients may present focal or diffuse pigmented lesions that are black, brown, purple or dark blue in color.

Endogenous Pigmented Lesions

Endogenous pigmented lesions are almost exclusively caused by melanin producing cells that are embryonically derived from neural crest cells. In the oral mucosa, pigment producing cells (melanocytes) are normally located in the basal keratinocyte layer of the lining epithelium.

Melanocytes

Melanocytes are dendritic cells that produce packaged pigment granules called melanosomes.

Pigment produced by melanocytes accounts for the normal physiological variations in skin and mucosal color observed in many races. It is important to note that dark skinned people do not have greater numbers of pigment producing cells (melanocytes) within their oral mucosa, but rather these cells are more active in their pigment producing activity.

Nevus Cells

Closely related to the melanocytes are the pigment producing nevus cells. These cells are commonly found in the subepithelial layers of the oral mucosa and the skin. These cells are oval in shape and tend to clump or nest with other cells and retain the ability to synthesize melanin. Whilst melanocytes are responsible for physiological pigmentations, nevus cells are important cells in the formation of

JAYPEE BROTHERS

hamartomatous (e.g. pigmented nevi) and neoplastic pigmented lesions such as malignant melanoma. Unlike in physiological pigmentation, in these conditions the number of pigment containing cells is greatly increased.

Exogenous Pigmented Lesions

Exogenous pigmented material can be deposited on the oral mucosa in many ways. Localized implantation of dental materials such as amalgam during restorative procedures or as a consequence of extraction of amalgam filled teeth can result in amalgam tattoo.

Cases of intentional tattooing of oral tissues (e.g. lips) for cultural reasons may also be observed in some communities. Pigment in these cases is carbon particles implanted in the mucosal connective tissues.

Chronic ingestion of certain heavy metals (bismuth, lead, and arsenic) can also cause oral pigmentation. Antibiotics (tetracycline), antiviral agents (zidovudine used in HIV infection), antimalarials (chloroquine) and oral contraceptive pills are known to cause oral mucosal pigmentation due to an increase in melanin production by melanocytes.

Clinical Presentations of Pigmented Lesions

Clinical presentations of oral pigmented lesions are variable. They may range from:

- A small flat spot or a macule 1–2 mm in diameter
- A large spot or macule larger than 2 mm in diameter
- A more diffuse patch or spreading lesion
- Multiple small pigmented lesions
- Multiple diffuse pigmented patches
- Wide spread gingival pigmentation
- Variously sized raised pigmented nodules.

Classification of the Oral Pigmented Lesions

Pigmented lesions can be classified based on the origin of the pigment and according to their clinical presentation. Both classifications are presented in Table 1.

General Principles of Management of Oral Pigmented Lesions

Recognition

- Clear understanding of the normal topography of the oral structures is essential.

JAYPEE BROTHERS

Table 1: Classification of the oral pigmented lesions.*

Classification based on the source or origin of the pigment	Classification based on clinical presentation*
Caused by the endogenous pigmentation: ❑ Physiological or racial pigmentation (melanoplakia) ❑ Ephelis (Freckles) ❑ Oral melanotic macule ❑ Smoking associated melanosis ❑ Lentigo ❑ Nevus (pigmented nevus) ❑ Melanoma ❑ Neuroectodermal tumor of infancy ❑ Drug-induced pigmentation ❑ Pigmentation associated with systemic disorders (Peutz–Jegher's syndrome, Addison's disease, Albright's syndrome and HIV/AIDS) *Caused by exogenous pigmentation:* ❑ Amalgam tattoo (focal argyrosis) ❑ Heavy metal pigmentation ❑ Tattoos	*Localized:* ❑ Amalgam and other tattoos ❑ Ephelis (Freckle) ❑ Melanotic macule ❑ Nevus ❑ Malignant melanoma *Generalized:* ❑ Genetic: ➢ Racial ➢ Peutz-Jegher's syndrome ❑ Drug related: ➢ Smoking ➢ Heavy metal (arsenic, bismuth and lead) ➢ Antimalarials ➢ Tetracycline ➢ Adrenocorticotropic hormone ➢ Zidovudine ➢ Clofamazine ➢ Methyldopa ➢ Busulphan ➢ Menthol ➢ Contraceptive pill ❑ Endocrine: ➢ Addison' disease ➢ Albright's syndrome ➢ Pregnancy ❑ Other: ➢ Incontinentia pigmenti ➢ Neurofibromatosis (Von Recklinghausen's disease) ➢ Wilson's disease ➢ HIV disease

**Adapted in part from* Scully C. Slide interpretation in oral diseases. Oxford University Press: Oxford; 1999. pp.175-7.

JAYPEE BROTHERS

Investigation

- Detailed history
- Thorough intra- and extraoral examination including radiographic examination (where appropriate).
- Biopsy of lesion(s) if required.

Appropriate Management

- No treatment for some lesions (patient education/reassurance required)
- Regular monitoring for some lesions (with clinical photographs)
- Medical or surgical treatment (by the specialist).

History of Mucosal Pigmented Lesions

Based on the presenting complaint, where relevant, a clinician should seek answers to the following questions:

When did the patient first notice the pigmented lesion?

- *Duration:* Pigmented lesions may be of short or long duration, symptomatic or asymptomatic
- Those of short duration may have a known cause (e.g. colored topical medications). Pigmentations of long duration have either a genetic background or systemic disorders.

Is there a history of oral pigmented lesions among the family members?

- For example, racial pigmentation.

What is the occupation of the patient?

- Workers dealing with bismuth and lead are more likely to develop pigmented lesions.

Did the patient recently use any lozenges or topical medications in the mouth?

- Colored topical medications often are mistaken for true pigmentations.

Did the patient visit a dentist for restorations or extractions?

If amalgam tattoo is suspected this question is of relevance.

Is the patient on systemic medications?

- Antimalarials, antiviral agent (zidovudine) tetracycline, contraceptive pills can cause oral pigmentation.

Does the patient have a history of any endocrine or immune disorder?

- Oral pigmented lesions may occur in patients with Addison's disease and Albright's syndrome. In HIV disease those on zidovudine can present with mucosal pigmentations.

Where in the mouth was the pigmented lesion first noticed?

- Location of the pigmented lesion is an indicator of the nature/cause of its pathology.
  - Fixed band-like pigmented lesion on the gingivae is common in colored people (racial pigmentation).

JAYPEE BROTHERS

- A pigmented lesion on the alveolar mucosa in an extraction or an amalgam restoration site is due to amalgam tattoo.
- A spreading pigmented (dark blue or black) lesion on the alveolar mucosa may be a sign of malignant melanoma.
- Multiple perioral pigmented lesions are typical of Peutz-Jegher's syndrome.

Are there any other body sites where skin lesions exist?

❖ In Albright's syndrome, skin and oral pigmented lesions may coexist.

What drew patient's attention to the oral pigmented lesion?

❖ Ulceration and pain associated with pigmented patches include lesions such as malignant melanoma.

In what way does the pigmented lesion trouble the patient?

❖ Pigmented lesions may be asymptomatic as in pigmented nevus.
❖ If the pigmented lesion is symptomatic, does it interfere with talking, speech, eating, and swallowing?

Has the pigmented lesion changed since it was first noticed?

❖ Rapid and recent increase in size or shape in a fixed pigmented lesion may point to a malignant lesion such as malignant melanoma.

What does patient think caused the pigmented lesion?

❖ Some patients are able to give reasons for the presence of pigmented lesions. Is it smoking? Genetics? Tattoo?

Does the patient use tobacco in any form?

❖ Smoker's melanosis is common among heavy smokers.

Note: Since some questions such as sexual orientation or HIV status are of personal and confidential nature, care must be taken to avoid any embarrassment to the patients. Patients must be informed at the beginning that answers to a host of questions are sought from every patient seeking treatment for mucosal disorders and that interviewing exercise with a wide range of questions is an essential part of a routine diagnostic work-up regardless of the presenting signs or symptoms.

Examination of Pigmented Lesion(s): Inspection and Palpation

Assessment of Size, Shape, Number and Position of Pigmented Lesions

❖ Large mucosal flat pigmented patches predominantly on the gingiva have a genetic background in Afro-Asian populations (racial pigmentation).
❖ Multiple perioral pigmentation is typical of Peutz-Jegher's syndrome.

JAYPEE BROTHERS

- A small pigmented spot may be derived from nevus cells such as pigmented nevus.
- A more diffuse pigmented patch may be due to endogenous causes as in Addison's disease or Albright's syndrome. Pigmented patches may be present on the skin as well.
- A spreading raised pigmented lesion may be due to malignant melanoma.

Other Features

- Association of any redness, erosion or ulceration with the pigmented lesion must be noted.
- All but malignant melanoma listed above are benign lesions. Rarely, pigmented nevi (e.g. junctional nevus) may become malignant.
- A thorough intraoral and extraoral examination including palpation of cervical lymph nodes should be performed. This is of utmost important for those with raised spreading blue or black lesions suspected to be malignant melanoma. Melanoma is discussed in Chapter 7.

JAYPEE BROTHERS

Case 1A

A young male complains of black patch on the tongue and altered taste.

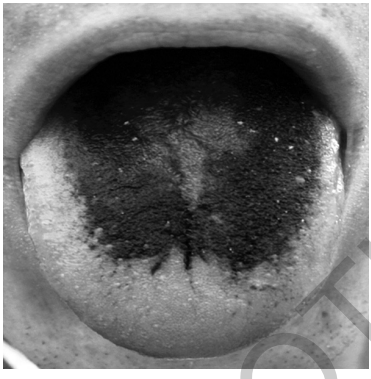

(For color version, see Plate 6)

1. Describe the clinical appearance of the tongue.

- Bilaterally symmetrical black patch with hair-like structures on the dorsum of the tongue.

Case 1B

An elderly male complains of brown patch on the tongue.

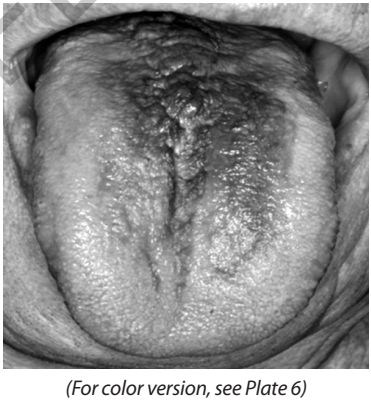

(For color version, see Plate 6)

1. Describe the clinical appearance of the tongue.

- Bilaterally symmetrical dark brown patch with hair-like lingual papillae on the dorsum of the tongue. Posteriorly, the pigmented patch appears lobulated and hairy.

JAYPEE BROTHERS

2. What further information would you seek from this patient?

The following information would be sought:

- Onset and duration of chief complaints.
- Additional symptoms such as irritation, bad taste, gagging and burning sensation, etc.
- Tobacco habits (smoking, chewing, snuff use: their duration frequency and quantity).
- Alcohol abuse
- Use of topical and systemic medications and antiseptic mouth rinses.
- Medical/dental history: Use of antibiotics, iron salts and recent systemic infections.

3. What clinical procedure would you perform to determine the nature of this lesion?

- Thorough clinical examination of the tongue and oral and extraoral structures.
- Gently scrape the pigmented area to determine whether they are wiped away with gentle scraping.

4. Which lesions would you include in the differential diagnosis for this lesion?

- Black/brown hairy tongue
- Furred tongue
- Smoker's melanosis.

5. What is your most likely clinical diagnosis of this lesion?

- Black/brown hairy tongue.

6. What is the basis of your clinical diagnosis?

- *History:*
  - History of the use of tetracycline in Case 1A.
  - History of heavy smoking in Case 1B.
  - History of bad taste and occasional gaging sensation.
  - Noncontributory medical/dental histories.
- *Clinical appearance:*
  - *Color:* Black and brown.
  - Elongated filiform papillae.

7. What is black/brown hairy tongue?

- Black and brown hairy tongue refers to conditions in which the filiform papillae elongate with black (or brown) discoloration.
- Hairy tongue occurs on the dorsum of the tongue, anterior to circumvallate papillae. The condition is asymptomatic. Some individuals may complain of dry mouth, bad taste, oral malodor or gagging sensation.

JAYPEE BROTHERS

8. What is/are the possible cause(s)/risk factors associated with black/brown hairy tongue?

- Causes or predisposing conditions of black hairy tongue include poor oral hygiene, smoking, radiation and xerostomia, use of antibiotics (tetracyclines), antacids, chlorhexidine rinses, iron salts and excessive growth of fungal or bacterial organisms.
- Brown hairy tongue may be due to heavy smoking and poor oral hygiene.
- Formation of excessive keratin can cause elongation of filiform papillae. Keratin may become pigmented by the action of pigment producing microbes or tobacco, mouth rinses, etc.

9. How is black/brown hairy tongue diagnosed?

- On history and clinical grounds.
- Cytology smear helps to rule out *Candida* infection.

10. What is the recommended treatment for black/brown hairy tongue?

- Elimination of predisposing factors.
- Scraping the dorsum of the tongue with tooth brush (patient education).
- Topical antifungal treatment if candidal association is found.

Case 2

A young male presents with multiple pigmented lesions on the vermillion and around the lips.

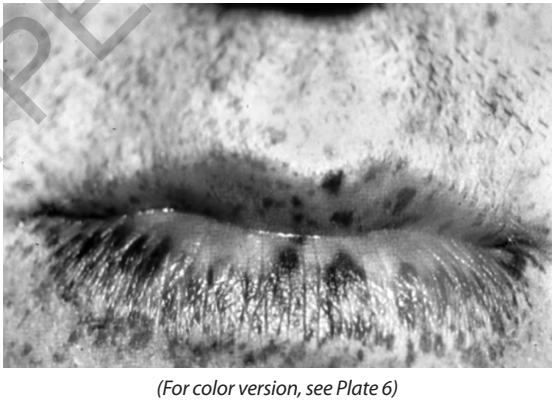

(For color version, see Plate 6)

1. Describe the clinical appearance of the labial and perioral lesions.

JAYPEE BROTHERS

- Multiple circumscribed melanotic spots are seen on the vermillion and the mucocutaneous junction of the lips. Pigmented macules are of varying intensity some with dark brown and others with light brown color. Variation in their sizes is also evident.

2. What further information would you seek from this patient?

The following information would be sought:

- Onset and duration of pigmentations.
- Additional information on symptoms such as irritation, itching, increase in size, etc.
- Tobacco habits (smoking, chewing, snuff use—their duration frequency and quantity).
- Use of recreational drugs: Their duration frequency and quantity.
- Medical/dental history: Gastrointestinal complaints, recent infections, bleeding disorders.
- Family history: Family members with similar condition.

3. What clinical procedure would you perform to determine the nature of these lesions?

- Thorough clinical examination of the lips and oral and extraoral structures.
- Examination of the exposed parts of the skin (hands in particular).

4. Which lesions would you include in the differential diagnosis for this lesion?

- Peutz-Jegher's syndrome
- Melanotic nevi
- Addison's disease
- Freckles

5. What is your most likely clinical diagnosis of this lesion?

- Peutz-Jegher's syndrome.

6. What is the basis of your clinical diagnosis?

- *History:*
  - History of its onset early in childhood.
  - Asymptomatic nature of lesions
  - Occasional complaint of intestinal pain.
- *Clinical appearance:* Multiple brown macules on and around the lips.

7. What is *Peutz-Jegher's syndrome*?

- An inherited autosomal dominant genetic defect characterized by multiple mucocutaneous macules and intestinal polyps.
- Vermillion and perioral skin are always involved.
- Other intraoral sites of involvement include buccal mucosa, tongue and the palate.

JAYPEE BROTHERS

- The skin around the nose, the anus, and of the skin on the palms and soles may also exhibit pigmented lesions in some individuals.
- Pigmented lesions develop during the first decade of life.
- Intestinal polyps involving the small intestine are common.
- Patients are at a higher risk for breast and gynecological cancers.
- Melanotic macules are not potentially malignant.

8. What is/are the possible cause(s)/risk factors of Peutz-Jegher's syndrome?

- An inherited genetic disorder.

9. How is Peutz-Jegher's syndrome diagnosed?

- On history and clinical grounds.

10. What is the recommended treatment plan for Peutz-Jegher's syndrome?

- No treatment is required for oral lesions.
- Referral to the plastic surgeons may be required for some patients who wish to have cosmetic surgery done on their lips.
- The need for cancer screening is necessary as these patients may have an increased risk for GI and other cancers.

Case 3

A young male of African descent reports for treatment on his maxillary anterior teeth. Examination reveals dark brown patches on the alveolar mucosa and gums.

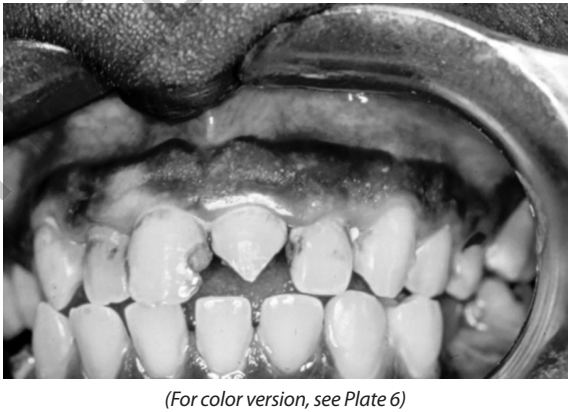

(For color version, see Plate 6)

1. Describe the clinical appearance of the gingival lesion.

- The maxillary alveolar mucosa and gingiva show dark brown colored patch involving the entire arch. In the lower arch, the

JAYPEE BROTHERS

gingival papillae also show evidence of pigmentation. Pigmentation is diffuse and band like in its distribution.

2. What further information would you seek from this patient?

The following information would be sought:

- Is patient aware of the pigmentation? If so, its onset and duration
- Tobacco habits (smoking, chewing, snuff use—their duration frequency and quantity).
- Use of recreational drugs: Their duration frequency and quantity.
- Medical/dental history: Gastrointestinal complaints, endocrine disorders, recent infections and bleeding disorders
- Family history: Family members with similar condition.

3. What clinical procedure would you perform to determine the nature of these lesions?

- Thorough clinical examination of the gingivae and alveolar mucosa.
- Examination of oral and extraoral structures.

4. Which lesions would you include in the differential diagnosis?

- Physiologic pigmentation (racial pigmentation)
- Smoker's melanosis
- Addison's disease
- Albright syndrome
- Malignant melanoma
- Kaposi's sarcoma.

5. What is your most likely clinical diagnosis of this condition?

- Physiologic pigmentation (racial pigmentation).

6. What is the basis of your clinical diagnosis?

- *History:*
  - Asymptomatic nature of the brown patch on the gums
  - Long duration of its presence
  - Family members with similar patches on their gingival tissues
  - African descent of the individual
  - No history of medications, smoking or systemic disorders.
- *Clinical appearance:*
  - Band-like brown patches involving the gingival tissues
  - No signs of other abnormalities (tenderness, ulceration, etc.).

7. What is physiologic pigmentation?

- Physiologic pigmentation (also called racial pigmentation) commonly involves gingival tissues in dark skinned people.

8. What is/are the possible cause(s)/risk factors for physiologic pigmentation?

JAYPEE BROTHERS

- Physiologic pigmentation is not an abnormality. Pigmentation is caused by the normal amount of melanin in the basal cell layers of the epithelium. Often considered as a variation of the normal.
- Common in dark skinned people (African or Asian in majority of cases).

9. How is physiologic pigmentation diagnosed?

- On history and clinical grounds.

10. What is the recommended treatment plan for physiologic pigmentation?

- No treatment is required.
- Reassurance if the patient is concerned.

Case 4A

A young male reports for a routine dental check-up. Examination reveals pigmented lesion on the soft tissues around the crown of the mandibular first molar.

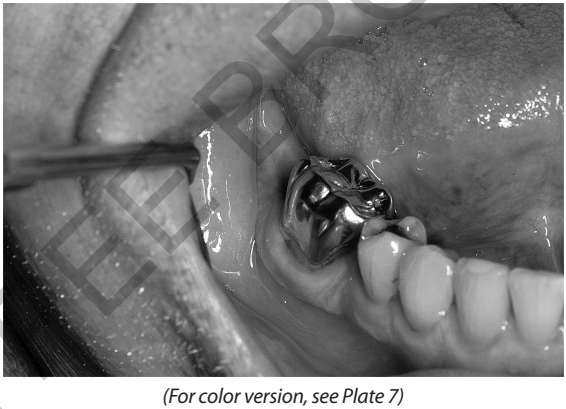

(For color version, see Plate 7)

1. Describe the clinical appearance of the pigmented lesion.

- A gray/black pigmented patch is located on the alveolar mucosa posterior to the crowned mandibular right first molar. A small band of pigmentation is also evident on the buccal aspect of gingival tissue in contact with the crown.

Case 4B

An adult male reports for a routine dental examination. Examination reveals a pigmented lesion on the edentulous lower alveolar ridge.

JAYPEE BROTHERS



(For color version, see Plate 7)

1. Describe the clinical appearance of the lesion on the lower alveolar ridge.

- Edentulous alveolar mucosa shows a bluish slightly raised pigmented lesion of approximately 1.5 cm in diameter. The surrounding mucosa appears normal.

2. What further information would you seek from this patient?

The following information would be sought:

- Is the patient aware of the pigmented lesion? If so, its onset and duration
- Tobacco habits (smoking, chewing, snuff use—their duration frequency and quantity)
- Alcohol abuse
- Use of recreational drugs: Their duration frequency and quantity.
- Medical history: Gastrointestinal complaints, recent infections, bleeding disorders.
  - Dental history: Restorations with amalgam extractions of amalgam filled molars.

3. What clinical procedure would you perform to determine the nature of these lesions?

- Thorough clinical examination of the gingivae and alveolar mucosa.
- Examination of oral and extraoral structures.

4. Which lesions would you include in the differential diagnosis for this lesion?

- Amalgam tattoo
- Pigmented nevi
- Melanotic macule

JAYPEE BROTHERS

- Malignant melanoma
- Smoker's melanosis.

5. What is your most likely clinical diagnosis of this lesion?

- Amalgam tattoo.

6. What is the basis of your clinical diagnosis?

- *History:*
  - Asymptomatic nature of the pigmented patches in both patients.
  - History of extraction of amalgam restored teeth in both patients.
  - No history of medications or systemic disorders.
- *Clinical appearance:*
  - Blue/black patch involving the alveolar mucosal tissues.
  - No signs of other abnormalities (tenderness, ulceration, etc.)

7. What is *amalgam tattoo*?

- Amalgam tattoos (formerly called focal argyria) is one of the most common causes of exogenous pigmentation in the oral mucosa.
- Amalgam tattoos are iatrogenic usually caused by amalgam inadvertently implanted into the mucosa during dental restorations but may also be caused by diffusion through the teeth. This results in a gray to black/blue non-elevated symptomless pigmented patch. Asymptomatic in most cases and overlying mucosa is always intact. Amalgam tattoos are common in the gingiva or alveolar mucosa.

8. What is/are the possible cause(s)/risk factors for physiologic pigmentation?

- Amalgam fragments are embedded in the pre-existing wound (such as tooth socket during the removal of amalgam filled tooth) or oral soft tissues. This can also occur secondary to dental restorative treatment or apical surgery.

9. How is amalgam tattoo diagnosed?

- On history and clinical grounds.
- If the tattoo is dense, deposits of amalgam can be detected in the radiographs.
- If clinical diagnosis is doubtful, biopsy of the lesion is recommended.

10. What is the recommended treatment plan for physiologic pigmentation?

- No treatment is required.
- Excision biopsy may be required for clinically uncertain pigmented lesions.

JAYPEE BROTHERS

Case 5

A young female reports for a routine dental check-up. Examination reveals a raised pigmented lesion on the lower lip.

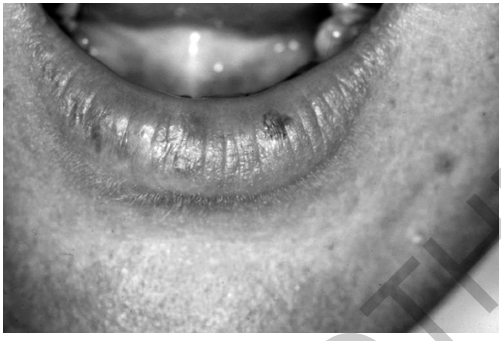

(For color version, see Plate 7)

1. Describe the clinical appearance of the pigmented lesion on the lip.

- A brown papule measuring about 0.6 cm in diameter is seen on the mucosa of the lower lip. The lesion appears to be slightly raised with irregular borders.

2. What further information would you seek from this patient?

The following information would be sought:

- Is patient aware of the pigmentation, if so, its onset and duration
- Tobacco habits (smoking, chewing, snuff use: Their duration frequency and quantity)
- Use of recreational drugs: Their duration frequency and quantity
- Medical history: Systemic complaints.

3. What clinical procedure would you perform to determine the nature of these lesions?

- Thorough clinical examination of the lip lesion.
- Clinical examination of the oral structures.

4. Which lesions would you include in the differential diagnosis for this lesion?

- Pigmented (melanotic) nevus
- Oral melanotic macule
- Malignant melanoma
- Peutz-Jegher's syndrome

5. What is your most likely clinical diagnosis of this lesion?

- Pigmented (melanotic) nevus.

JAYPEE BROTHERS

6. What is the basis of your clinical diagnosis?

- *History:* Asymptomatic nature of the pigmented lesion.
- *Clinical appearance:*
  - Brown colored slightly raised solitary round lesion.
  - No signs of other abnormalities (tenderness, ulceration, etc.).

7. What is *pigmented (melanotic) nevus*?

- Nevi are hamartomatous lesions made up of focal collections of normally pigmented nevus cells in the connective tissues beneath the epithelium. The common name for a nevus is 'mole'. These are common on the skin. Oral nevi are rare.
- Oral nevus presents as a painless, single, small (usually less than 5 mm in diameter) well circumscribed dome-shaped papule or flat macule. Its color may range from blue to brown to dark black.
- Most common intraoral sites for nevus are hard palate and buccal mucosa. They may occur at any age.
- Rarely junctional activity may be seen in pigmented nevi. Excisional biopsy is recommended to assess the junctional activity or to rule out melanomas.

8. How is pigmented nevus diagnosed?

- On history and clinical grounds.
- Biopsy and microscopic evaluation is confirmatory. In adults nodular nevus can sometimes clinically mimic malignant melanoma.

9. What are the histological features of oral nevi?

- Four main histological types have been reported:
  - *Junctional nevus:* Pigmented nevus cells confined to basal epithelium.
  - *Intradermal or intramucosal nevus:* Nevus cells located within the lamina propria.
  - *Compound nevus:* Combination of junctional and intradermal/intramucosal nevi.
  - *Blue nevus:* Spindle-shaped nevus cells within lamina propria.

10. Are nevi potentially malignant?

- Flat small macular lesions are benign. On the skin, examples of chronically sun exposed 'moles' have been reported to turn malignant. Oral nevi have rarely been reported to transform into malignant melanoma. Immunohistochemical staining with p53 may have a prognostic significance.

11. What is your recommended treatment plan for physiologic pigmentation?

JAYPEE BROTHERS

- No treatment is required.
- If clinical diagnosis is doubtful, biopsy of the lesion is recommended.

Case 6

A 35-year-old male reports for a routine dental examination. Oral examination reveals a fat pigmented lesion on the lower lip.

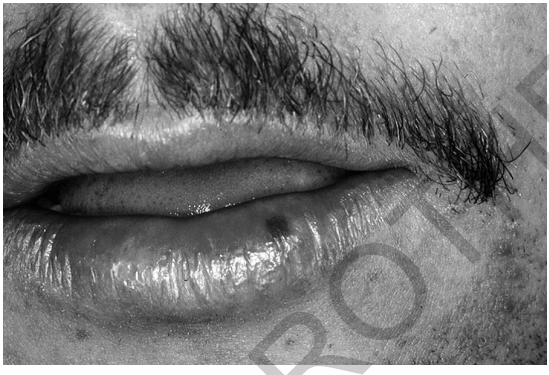

(For color version, see Plate 7)

1. Describe the mucosal lesion on the lower lip.

- A well-circumscribed round solitary brown macular lesion on the labial mucosa of the lower lip.

2. What further information would you require from this patient?

The following information will be sought:

- Duration of the lip lesion and whether the lesion has changed its color, size and shape in recent times?
- History of trauma to the lip.
- Any additional symptoms: Systemic or local.
- Tobacco and alcohol habits
- Medical history: Systemic health.

3. What clinical procedure would you perform to determine the nature of this lesion?

- Clinical examination of the lip and oral structures.
- Palpation of the lip lesion for its consistency and texture.
- Diascopy of the lesion to determine blanchability.

4. Which lesions would you include in the differential diagnosis for this lesion?

- Labial melanotic macule
- Melanocytic nevus

JAYPEE BROTHERS

- Freckles
- Amalgam tattoo
- Hemangioma
- Addison's disease
- Peutz-Jegher's syndrome
- Malignant melanoma.

5. What is your most likely clinical diagnosis of this lesion?

- Labial melanotic macule.

6. What is melanotic macule?

- Melanotic macule is a circumscribed brown colored symptomless lesion covered with intact mucosa.
- Melanotic macule is usually less than half a centimeter in size. Oral sites of melanotic macule include lower lip (labial melanotic macule), gingiva, palate and buccal mucosa.
- Once developed the lesion usually remains unchanged in size and color. It can occasionally have an irregular edge and there may be a history of color change which can cause confusion with other pigmented lesions.
- Patients are usually adults.
- This is a benign lesion with no malignant potential.

7. What is/are the possible cause(s)/risk factors for this lesion?

- Developmental etiology.

8. What confirmatory test(s) would you recommend for this lesion?

- If lesion shows signs of changing its shape, size and color, biopsy is recommended.
- The histologic features of melanotic macule shows benign features such as:
  - Increased melanin in the melanocytes and keratinocytes of the basal layer.
  - Melanophages in the lamina propria.
  - Mild acanthosis without elongation of the rete ridges.

9. Is melanotic macule a potentially malignant lesion?

- Melanotic macules are benign lesions. If the diagnosis is uncertain (with a history of change in its size and shape), biopsy is indicated to rule out malignant melanoma.

10. What is the recommended treatment plan including the advice to the patient?

- If decided to leave the lesion, it should be measured, photographed and followed up.

JAYPEE BROTHERS

- If biopsied, no further treatment is necessary once the lesion has been removed for microscopy. Follow-up is necessary.
- Advise the patient to avoid trauma (e.g. habitual lip biting).

Case 7

A young male with a history of HIV disease presents for routine oral examination. Examination reveals pigmentation of the buccal mucosa.



(For color version, see Plate 7)

1. Describe the clinical appearance of the buccal lesions.

- Left buccal mucosa shows multiple pigmented patches. Patches are dark brown and flat lesions with irregular borders. Surrounding mucosa appears normal.

2. What further information would you require from this patient?

The following information will be sought:

- Is the patient aware of the pigmented patches in the mouth? If yes, for how long?
- Have the patches changed its color, size and shape in recent times?
- Any additional symptoms: Systemic or local
- Tobacco and alcohol habits
- Medical history: HIV and medication history.

3. What clinical procedure would you perform to determine the nature of this lesion?

- Clinical examination of the oral structures.
- Palpation of the buccal lesion for its consistency and texture.
- Diascopy of the lesion to determine blanchability.

4. Which lesions would you include in the differential diagnosis for this lesion?

JAYPEE BROTHERS

- Drug-induced mucosal pigmentation (oral melanotic macule associated with HIV disease)
- Melanocytic nevus
- Hemangioma
- Addison's disease
- Peutz-Jegher's syndrome
- Malignant melanoma.

5. What is your most likely clinical diagnosis of this lesion?

- Drug-induced mucosal pigmentation (oral melanotic macule associated with HIV disease).

6. What is drug-induced mucosal pigmentation?

- Drug-induced mucosal pigmentation refers to pigmentation of the oral mucosa due to the stimulation of melanin production by melanocytes caused by certain drugs.
- Drugs known to cause mucosal pigmentation include chloroquine, cyclophosphamide, zidovudine {also called azidothymidine (AZT)} and amiodarone.
- The most common mucosal sites for drug-induced pigmentation include buccal mucosa, palate and the gingivae.
- Tetracycline (minocycline) and chloroquine cause bluish pigmentation in the middle of the palate whereas zidovudine causes brown pigmentation.
- The pathogenesis underlying drug-induced pigmentation can be categorized as:
  - Drug or drug metabolite deposition in the epithelial or subepithelial tissues.
  - Enhanced melanin deposition with or without increase in melanocytes.
  - Drug-induced postinflammatory changes to the mucosa especially if the drugs induce an oral lichenoid reaction.
  - Bacterial metabolism.

7. What is/are the possible cause(s)/risk factors for this lesion?

- Prolonged use of antiviral drug zidovudine for HIV disease.

8. What confirmatory test(s) would you recommend for this lesion?

- Clinical diagnosis is adequate. If lesion shows signs of changing its shape, biopsy is recommended.

JAYPEE BROTHERS

9. Is drug-induced pigmented lesion potentially malignant?

❖ Drug-induced pigmented lesions are benign. If the diagnosis is uncertain (with a history of change in its size and shape), biopsy is indicated to rule out malignant melanoma.

10. What is the recommended treatment for the mucosal pigmentation?

❖ No treatment is necessary. Medication may be changed by the HIV physician. With time there may be resolution of the pigmented patch. Follow-up is necessary.

❖ Advise the patient to avoid trauma (e.g. habitual cheek biting).

ACKNOWLEDGMENTS

Case 1A. *Source:* ©Wikimedia.org. Available from: http://upload.wikimedia.org/wikipedia/commons/1/16/Black_tongue.jpg.)
Cases 1B, 4A and 4B. *Courtesy:* Dr Nagamani Narayana UNMC Nebraska, USA.
Cases 2 and 6. *Courtesy:* David Wilson, CSU, Orange, Australia.
Case 7. *Courtesy:* David Reznik, AIDS Org. USA.

RECOMMENDED READING

1. Cawson RA, Odell EW. Oral pigmented lesions. In: Cawson's essentials of oral pathology and oral medicine, 9th edition. Churchill Livingstone: Edinburgh; 2017. pp. 383-8.
2. Lewis Michael AO, Jordan Richard CK. Pigmentation. Oral medicine, 2nd edition. Mansion Publishing: London; 2012. pp. 147-65.
3. Wilson DF, Moore SR, Logan RM. Pigmented lesions of the oral mucosa. In: Prabhu SR (Ed). Textbook of oral medicine. Oxford University Press: New Delhi; 2004. pp. 107-16.

JAYPEE BROTHERS

For detailed information on dental books, visit our website www.jaypeebrothers.com, for detailed information on de

Clinical Diagnosis in

Oral Medicine

A Case-based Approach

Salient Features

- Comprehensive resource for the development of diagnostic skills in oral medicine
- Most useful and user-friendly book with case-based questions that challenge the clinician to think through clinical problems and arrive at a differential or final diagnosis based on patient history, symptoms and clinical findings
- Highly illustrated handy reference book with over 100 clinical scenarios
- Useful appendices for quick revision with definitions of common clinical and histological nomenclature and mucosal disorders and tables providing clinical differential diagnosis of mucosal diseases
- Targeted at dental students and practitioners who are often faced with challenges of clinical decision-making.

SR Prabhu BDS MDS (Oral Path) FFDRCS (Oral Med, Ire) FDSRCS (Edin) FDSRCS (Eng) FDSRCPS (Glasgow) FFGDPRCS (UK) MOMedRCS (Edin) FICD is an Associate Professor, Discipline of Oral Medicine, The University of Queensland School of Dentistry, Brisbane, Australia. With extensive experience in India, Africa, Australasia, Middle East and the Caribbean, he has published several scientific papers and authored/edited books in the field of oral diseases. He is a Fellow of the Dental Faculties of the Royal College of Surgeons in the UK and Ireland.

Available at all medical bookstores
or buy online at www.jaypeebrothers.com



JAYPEE BROTHERS
Medical Publishers (P) Ltd.
www.jaypeebrothers.com

Join us on facebook.com/JaypeeMedicalPublishers

Shelving Recommendation
DENTISTRY

