t our website **www.jaypeebrothers.com,** for detailed information on ophthalmology books, visit our website **www.jaypeebrothers.com**

Celebrating 50 YEARS
Passion, Quality and Innovation in Healthcare Publishing

Ophthalmology Review

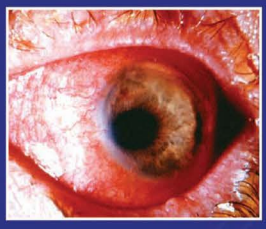

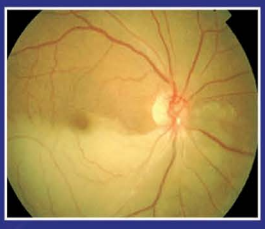

Editor-in-Chief
Myron Yanoff

Editors
Uriel Schechter
Vincent B Lam
Kelly A Williamson
Weiye Li
An Vo
Nancy Crawford
Stephanie J Weiss

THIRD EDITION

JAYPEE

Contents

1. **Optics and Refraction** 1
   Uriel Schechter, Clifford Goodrich
2. **Genetics and Ocular Embryology** 13
   Kelly A Williamson
3. **Uveitis and Other Intraocular Inflammations** 20
   Kelly A Williamson
4. **Cornea and External Disease** 49
   An Vo
5. **Refractive Surgery** 82
   An Vo
6. **Lens** 93
   Myron Yanoff, Nicole Pumariega
7. **Orbit and Oculoplastics** 123
   Vincent B Lam, Ryan McGuire, Nida Khan
8. **Retina and Vitreous** 149
   Weiye Li, Stephanie J Weiss
9. **Glaucoma** 207
   Nancy Crawford, Prashanth Iyer
10. **Intraocular Tumors** 229
    Myron Yanoff, Nicole Pumariega
11. **Neuro-ophthalmology** 257
    Stephanie J Weiss, Robert T Spector
12. **Strabismus** 287
    Stephanie J Weiss, Robert T Spector

CHAPTER

4

Cornea and External Disease

An Vo

QUESTIONS

Identify the correct answer for all questions (unless instructed otherwise).

1. A choristoma is a tumor composed of:

A. Cartilage and ectodermal tissue.
B. Fat and endodermal tissue.
C. Tissue not normally found in the area of involvement.
D. Tissue normally found in the area of involvement.
E. Tissue from each of the three germ layers.

2. Goldenhar's syndrome contains all the following, *except*:

A. Preauricular skin tags.
B. Blind-ended preauricular fistulas.
C. Bilateral limbal dermoids.
D. Hypoplasia of the facial bones.
E. Polydactylism.

3. Secondary conjunctival localized amyloidosis may occur in all the following, *except*:

A. Stromal corneal dystrophies.
B. Trachoma.
C. Trichiasis.
D. Epithelial corneal dystrophies.
E. Chronic keratitis.

4. The most common cause of acute bacterial conjunctivitis worldwide is:

A. *Staphylococcus aureus.*
B. *Streptococcus pneumoniae.*
C. *Corynebacterium diphtheriae.*
D. *Staphylococcus albus.*
E. *Haemophilus influenzae*.

5. The most common cause of chronic bacterial conjunctivitis especially angular blepharoconjunctivitis is:

A. *Proteus mirabilis.*
B. *Moraxella lacunata.*
C. *Escherichia coli.*
D. *Klebsiella pneumoniae.*
E. *Serratia marcescens.*

6. Viral conjunctivitis:

A. Cannot be differentiated from bacterial conjunctivitis without culture.
B. Usually appears as a bilateral conjunctivitis.
C. Typically has a purulent discharge.
D. Unlike bacterial conjunctivitis is almost never accompanied by preauricular lymphadenopathy.
E. Can usually be diagnosed clinically.

7. Pharyngoconjunctival fever is characterized by all the following, *except*:

A. It is caused by adenovirus serotypes 3, 4, and 7.
B. It is the most common ocular adenoviral infection.
C. It has a short incubation period (<5 days).
D. It causes a predominantly follicular reaction.
E. It has an associated preauricular lymphadenopathy in about 90% of cases.

8. Epidemic keratoconjunctivitis is characterized by all the following *except*:

A. It is associated with membrane formation in about one-third of cases.
B. Corneal involvement occurs in most cases.
C. It causes a mixed follicular and papillary reaction.
D. It is caused by adenovirus serotypes 3, 4, and 7.
E. It causes a more severe form of conjunctivitis than does pharyngo-conjunctival fever.

9. Chlamydial infections cause all the following, *except*:

A. Trachoma.
B. Chronic follicular conjunctivitis.
C. Adult inclusion conjunctivitis.
D. Middle to deep stromal corneal infiltrates.
E. Neonatal conjunctivitis.

10. All the following contribute to the cause of neonatal conjunctivitis, *except*:

A. Inadequate treatment of maternal infection during pregnancy.
B. Organisms harbored in the mother's birth canal.
C. 0.10% buffered silver nitrate ocular prophylaxis.
D. Susceptibility of the infant's eye to infection.
E. Ocular trauma during delivery.

11. Allergic conjunctivitis is characterized by all the following, *except*:

A. Not occurring as part of a generalized allergic reaction.
B. Type I allergic response.
C. Mediation by immunoglobulin E.
D. Bilateral itchy, burning, hyperemic eyes.
E. Often a family history of atopy.

12. Which of the following statements is true regarding the condition depicted in this figure?

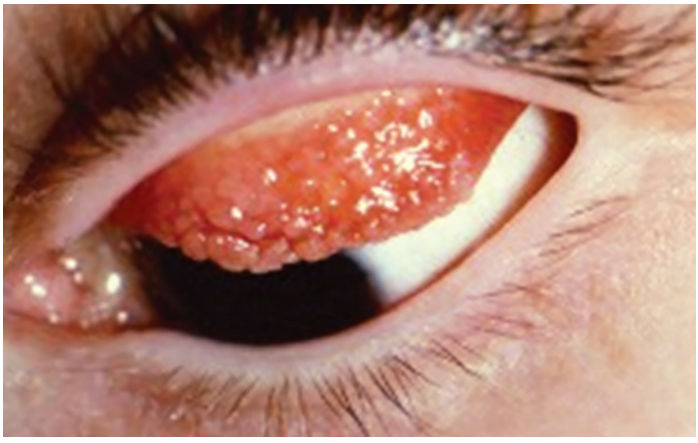

A. It tends to be unilateral.
B. It most commonly occurs in the fall and winter.
C. It usually occurs in young boys (<10 years).
D. Generally is not self-limiting in children and needs aggressive therapy to cause a remission.
E. It occurs in palpebral, limbal, and mixed forms.

13. Giant papillary conjunctivitis is seen in all the following, *except*:

A. Soft contact lens wearers.
B. Acrylic lens implants.
C. Hard contact lens wearers.
D. Ocular prostheses.
E. Protruding ocular sutures.

14. On examination, a 72-year-old woman has subepithelial conjunctival fibrosis, symblepharon, and fibrotic conjunctival bands. The most likely diagnosis is:

A. Ligneous conjunctivitis.
B. Cicatricial pemphigoid.
C. Toxic follicular conjunctivitis.
D. Microbiallergic conjunctivitis.
E. Vernal conjunctivitis.

15. Erythema multiforme major (Stevens–Johnson syndrome) is characterized by all of the following, *except*:

A. It usually occurs in the fifth and sixth decades of life.
B. It can cause an acute, bilateral, mucopurulent conjunctivitis, chemosis, and conjunctival vesicles.
C. Its most severe variant is toxic epidermal necrolysis.
D. Systemic toxicity includes fever, malaise, headache, and fluid imbalance.
E. It may be precipitated by bacteria and sulfonamides.

16. Primary acquired melanosis is characterized by all the following, *except*:

A. Unilaterality.
B. Brown pigmentation.
C. Melanocytes in the junctional and subepithelial locations.
D. The tendency toward progression.
E. Potential to become a malignant melanoma.

17. All the following characterize a conjunctival intraepithelial neoplasm, *except*:

A. Conjunctival dysplasia.
B. Carcinoma in situ.
C. Squamous cell carcinoma with minimal invasion.
D. Squamous cell carcinoma with deep invasion.
E. Sessile squamous papilloma.

18. The corneal epithelium contains all the following, *except*:

A. Langerhans cells.
B. Wing epithelial cells.
C. Basal epithelial cells.
D. Dendritic melanocytic nevus cells.
E. Superficial epithelial cells.

19. All the following occur within the first few hours after small corneal epithelial injury, *except*:

A. Cell spreading.
B. Cell migration.
C. Disappearance of anchoring hemidesmosomes.
D. Cell proliferation.
E. Contraction of actin fibers.

20. Recurrent erosion may occur in which of the following conditions:

A. Post-traumatic corneal abrasion.
B. Map-dot-fingerprint (Cogan's microcystic) dystrophy.
C. Reis-Bückler's dystrophy.
D. Meesmann's dystrophy.
E. All of the above.
F. None of the above.

21. Typically, the onset of symptoms of recurrent erosion:

A. Occurs in midafternoon.
B. Occurs on awakening in the morning.

C. Is worse in the evening.
D. Is variable throughout the course of the day.
E. Does not seem to occur during the sleeping hours.

22. Treatment of recurrent erosion includes all the following, *except*:

A. Sharp instrument debridement when large, loose sheets of devitalized cells are present.
B. Ocular surface lubricants.
C. Topical hypertonic solutions.
D. Extended-wear bandage, soft contact lenses.
E. Anterior stromal micropunctures.

23. The corneal endothelium shows all the following characteristics, *except*:

A. A monolayer of cells.
B. Lateral interdigitations of adjacent cells with both gap and tight junctions.
C. Being devoid of surface villi on the aqueous side.
D. On specular microscopy, presence of light, well-defined cell borders and dark centers.
E. Continuous secretion of Descemet's membrane throughout life.

24. Fluid regulation by corneal endothelium is enhanced by all the following, *except*:

A. Hexagonal arrangement of individual cells.
B. The barrier portion of the endothelium which is permeable to the extent that it allows enough ion flux to establish the osmotic gradient.
C. Ca^{+} channel enhancer function.
D. Membrane·bound Na^{+}/K^{+}-ATPase sites.
E. Intracellular carbonic anhydrase pathway.

25. Fuchs' dystrophy:

A. Is the most common corneal dystrophy to require keratoplasty.
B. Shows peripheral cornea guttata of Descemet's membrane.
C. Has as its primary defect an epithelial abnormality.
D. Is most common in men.
E. Is not associated with glaucoma.

26. Which of the following symptoms are associated with Fuchs' dystrophy?

A. Blurred vision.
B. Recurrent erosions.
C. Glare.
D. Pain.
E. All of the above.

27. Congenital hereditary endothelial dystrophy has all the following attributes, *except*:

A. Autosomal dominant inheritance pattern.
B. Onset usually at 3 months in a term infant.

C. Autosomal recessive inheritance pattern.
D. Accumulation of functionally abnormal and structurally exaggerated posterior non-banded Descemet's membrane.
E. Bilateral, symmetric, edematous, and cloudy corneas.

28. Posterior polymorphous dystrophy has all the following attributes, *except*:

A. An autosomal dominant inheritance pattern.
B. Vesicular, curvilinear, and placoid abnormalities on specular microscopy.
C. Epithelial-like transformation of corneal endothelium.
D. An association with glaucoma.
E. An autosomal recessive inheritance pattern.

29. Megalocornea:

A. Shows a corneal horizontal size more than or equal to 11.5 mm after 2 years of age.
B. May be autosomal recessive.
C. May be X-linked recessive.
D. Shows a decreased endothelial density on specular microscopy.
E. Often shows a lens dislocated into the vitreous.

30. All of the following characteristics are associated with Axenfeld–Rieger syndrome, *except*:

A. About 50% of the cases are associated with glaucoma.
B. Results from retention of surface ectodermal tissue.
C. Iris atrophy, corectopia and polycoria are present.
D. Dental abnormalities can be present.
E. Defects in the *PAX2* gene on chromosome 4q25.

31. Peters' anomaly:

A. Does not involve Descemet's membrane.
B. Does not involve Bowman's membrane.
C. Is a paracentral, midcorneal stromal defect.
D. May occur as part of fetal alcohol syndrome.
E. Is associated with dental and vertebral anomalies.

32. A 2-year-old child has painful recurrent corneal erosions. Testing shows abnormalities of chromosome 5q. The most likely diagnosis is:

A. Superficial granular dystrophy.
B. Fuchs' combined dystrophy.
C. Meesmann's dystrophy.
D. Gelatinous drop-like dystrophy.
E. Reis-Bückler's dystrophy.

33. Recurrent corneal erosions are a dominant feature of all of the following, *except*:

A. Reis-Bückler's dystrophy.
B. Honeycomb (Thiel-Behnke dystrophy).
C. Superficial granular dystrophy.

D. Lattice dystrophy.
E. Macular dystrophy.

34. Lattice type I (Biber-Haab-Dimmer) dystrophy:
A. Is associated with familial amyloidosis.
B. Shows dichroic, Congo red-positive material in the stroma.
C. Is associated with development of linear, often branching, stromal opacities in the fifth and sixth decades.
D. Involves stromal opacities that are most dense just anterior to Descemet's membrane.
E. Shows abnormalities of chromosome 11p.

35. A 48-year-old patient presents with mildly decreased vision. Examination shows discrete corneal stromal opacities. The stroma between the opacities is clear. The most likely diagnosis is:
A. Granular (Groenouw type I) corneal dystrophy.
B. Macular corneal dystrophy.
C. Lattice dystrophy type III.
D. Gelatinous drop-like dystrophy.
E. Central cloudy dystrophy.

36. A 36-year-old patient has decreased vision. Examination demonstrates anterior corneal stromal discrete opacities and posterior stromal linear, often branching, opacities. The most likely diagnosis is:
A. Granular (Groenouw type I) corneal dystrophy.
B. Central cloudy dystrophy.
C. Lattice dystrophy type III.
D. Avellino dystrophy.
E. Posterior amorphous dystrophy.

37. All the following corneal dystrophies have been mapped to chromosome 5q, *except*:
A. Granular (Groenouw type I) corneal dystrophy.
B. Reis-Bückler's dystrophy.
C. Lattice dystrophy type II (Meretoja).
D. Avellino dystrophy.
E. Lattice dystrophy type I.

38. All the following statements about the attributes of macular corneal dystrophies are true, *except*:
A. These dystrophies show an autosomal recessive pattern.
B. In type I, typical sulfated keratan sulfate is not present in the cornea or serum.
C. In type II, antigenic sulfated keratin sulfate is present in the cornea and serum.
D. Discrete corneal stromal opacities are shown; the stroma between the opacities is cloudy.
E. Penetrating keratoplasty frequently is followed by recurrence in the graft.

39. On clinical examination, all the following may be seen in the condition depicted by the slit-lamp photo, *except*:

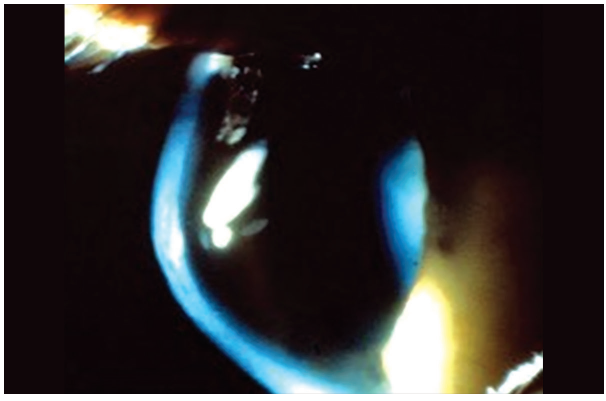

Fig. 4.2: Slit-lamp image.

A. Corneal epithelium iron deposition in a ring form (Fleischer ring).
B. Ruptures in Bowman's membrane leading to acute keratoconus.
C. Protrusion of the lower lid on downgaze (Munson's sign).
D. Presence of keratometry >47.2 diopters, steepening of the inferior cornea >1.2 diopters (compared with the superior cornea), and skewing of the radial axis of astigmatism more than 21°.
E. Thinning of the corneal apex.

40. A pterygium is similar to a pinguecula in all the following ways, *except*:

A. It has an association with ultraviolet light.
B. It demonstrates elastotic degeneration of the conjunctival substantia propria.
C. It starts in the region of the limbus.
D. It shows fibrovascular invasion of Bowman's membrane.
E. It is a degenerative (as opposed to dysplastic) process.

41. Histologically, arcus senilis shows:

A. Stromal deposition of lipid.
B. Peripheral Descemet's membrane deposition of lipid.
C. Peripheral Bowman's membrane deposition of lipid.
D. All of the above.
E. None of the above.

42. Terrien's marginal corneal degeneration:

A. Occurs most frequently in women in the third to fourth decades.
B. Has a fairly steep central edge and sloping peripheral edge.
C. Is unrelated to pellucid marginal corneal degeneration.
D. Contains a lipid deposit along its peripheral edge.
E. Involves pain as a prominent symptom.

43. Calcific band keratopathy typically develops in all the following, *except*:

A. Chronic topical epinephrine therapy for glaucoma.
B. Uveitis.
C. Juvenile rheumatoid arthritis.
D. Hyperparathyroidism.
E. Vitamin D toxicity.

44. A 78-year-old patient shows white-to-gray and light-blue superficial corneal stromal nodules elevating the corneal epithelium. All the following have a likely predisposing association, *except*:

A. Male gender.
B. Phlyctenular keratitis.
C. Vernal keratitis.
D. Trachoma.
E. Thygeson's superficial punctate keratitis.

45. Amyloid corneal stromal deposition can be seen in all the following, *except*:

A. Lattice dystrophy type II (Meretoja).
B. Gelatinous drop-like dystrophy.
C. Granular (Groenouw type I) corneal dystrophy.
D. Climatic proteoglycan stromal keratopathy.
E. Lattice dystrophy type I.

46. General principles of therapy for noninfectious keratitis include all the following, *except*:

A. Determining the specific cause.
B. Using a broad-spectrum antibiotic.
C. Promoting epithelial healing.
D. Limiting ulceration and stromal loss.
E. Supporting repair.

47. All the following are typical of Thygeson's superficial pupctate keratopathy, *except*:

A. Long duration of exacerbations and remissions.
B. In some patients an increase in HLA-Dw3 and HLA-DR3 expression.
C. Central cornea opacities that are small, round, or oval and granular, white-gray, intraepithelial, and dot-like and are often accompanied by subepithelial opacities.
D. Usual absence of conjunctival inflammation.
E. Suggestion of male preponderance.

48. A 41-year-old patient has a history of bilateral recurrent inflammation of the superior limbus and conjunctiva. Involvement of the superior tarsal and bulbar conjunctiva is noted. The probable diagnosis is:

A. Thygeson's superficial punctate keratopathy.
B. Moren's ulcer.
C. Superior limbic keratoconjunctivitis (SLK) of Theodore.
D. Terrien's marginal degeneration.
E. Neurotrophic keratitis.

49. Mooren's ulcer is characterized by all the following, *except*:

A. Circumferential and central spread of the ulcer.
B. Peripheral ulcer with undetermined central edge of the ulcer (overhanging edge).
C. Chronicity.
D. Pain.
E. Association with collagen vascular disease.

50. The differential diagnosis of nonsyphilitic interstitial keratitis (Cogan's dystrophy) includes all the following, *except*:

A. Lyme disease.
B. Avellino dystrophy.
C. Congenital syphilis.
D. Sarcoidosis.
E. Viral keratitis.

51. As a description of the characteristics of neurotrophic keratitis, which of the following statements is not true?

A. A quiet white eye is usually seen.
B. The condition results from lesions of the fifth cranial nerve.
C. Varicella-zoster and herpes simplex keratitis are the most common causes.
D. Punctate keratitis is seen.
E. Loss of corneal sensation is noted.

52. The therapy for mild neurotrophic keratitis is:

A. Punctal occlusion.
B. Soft contact lens wear.
C. Lateral tarsorrhaphy.
D. Ocular lubrication.
E. Penetrating keratoplasty.

53. Rheumatoid-associated ocular involvement includes all the following characteristics, *except*:

A. Central ulcerative keratitis.
B. Peripheral limbal gutter.
C. Acute corneal stromal keratitis.
D. Keratolysis.
E. Sclerosing keratitis.

54. The pathologic characteristics of paracentral rheumatoid melt include all the following, *except*:

A. Infiltration by monocytes, macrophages, and T-lymphocytes.
B. Strong HLA-DR expression by stromal keratocytes and epithelium.
C. Presence of CD 11 (macrophages) in epithelium and subepithelium at the ulcer edge.
D. Immunoglobulin deposition in corneal epithelium.
E. Stromal infiltration exclusively by neutrophils and eosinophils.

55. Bacterial keratitis:

A. Is not an important cause of monocular blindness in the developing world.
B. Is caused by *Streptococcus pneumoniae* and *Serratia marcescens* in the majority of cases.
C. Occurs in 0.0001–0.0003% of contact lens wearers (10–30 in 100,000).
D. In patients who have debilitated diseases is caused mainly by *Staphylococcus epidermidis*.
E. In the eastern and northeastern United States is most commonly caused by pseudomonal infection.

56. The corneal surface normally is protected by all the following, *except*:

A. An intact corneal epithelium.
B. Stromal antimicrobial substances.
C. Eyelid blinking which regularly sweeps away debris trapped in the mucin layer.
D. Tears which contain lysozyme, lactoferrin, 13-lysin, tear-specific albumin, and immunoglobulin.
E. Immune mediators present in the conjunctiva.

57. The cardinal sign(s) of bacterial keratitis is (are):

A. "dry" satellite stromal lesions.
B. Satellite lesions plus hypopyon.
C. Peripheral corneal infiltration and conjunctival injection.
D. Localized or diffuse central infiltration of the corneal epithelium or stroma.
E. Ciliary injection and chemosis.

58. A corneal ulcer is cultured. The organism ferments mannitol. The most probable bacterium present is:

A. *Staphylococcus epidermidis.*
B. *Pseudomonas aeruginosa*.
C. *Staphylococcus aureus.*
D. *Neisseria gonorrhoeae.*
E. *Streptococcus pneumoniae.*

59. All the following organisms have been associated with infectious crystalline keratopathy. Which is the most common cause?

A. *Streptococcus viridans.*
B. *Streptococcus pneumoniae.*
C. *Pseudomonas aeruginosa*.
D. *Haemophilus aphrophilus*.
E. *Peptostreptococcus*.

60. Of the following culture media, which is the best for *Neisseria* organisms?

A. Blood agar.
B. Brain heart infusion.
C. Chocolate agar.

D. Sabouraud dextrose agar.
E. Enriched thioglycollate broth.

61. Of the following culture media, which is the best for anaerobic bacteria?

A. Brain heart infusion.
B. Blood agar.
C. Chocolate agar.
D. Sabouraud dextrose agar.
E. Enriched thioglycollate broth.

62. Which of the following is best for the identification of bacteria?

A. Giemsa stain.
B. Grocott–Gomori's methenamine silver stain.
C. Periodic acid-Schiff stain.
D. Calcofluor white stain.
E. Gram-stain.

63. Definitive diagnosis of bacterial keratitis can be made by:

A. Clinical history.
B. Clinical history and physical examination.
C. Gram staining of scrapings.
D. Culture of scrapings.
E. Giemsa staining of scrapings.

64. All the following are active in the treatment of gram-negative bacteria and some gram-positive bacteria, *except*:

A. Amikacin.
B. Vancomycin.
C. Gentamicin.
D. Tobramycin.
E. Ofloxacin.

65. Viruses have all the following attributes, *except*:

A. Presence of an intracellular parasite.
B. Acute sensitivity to treatment with fluoroquinolones.
C. Only one type of nucleic acid within the infectious unit.
D. Inability to replicate by binary fission.
E. Resistance to commonly used topical antibiotics.

66. All the following belong to the Herpesviridae family, *except*:

A. Adenovirus.
B. Herpes simplex virus.
C. Varicella-zoster virus.
D. Epstein–Barr virus.
E. Cytomegalovirus.

67. All of the following about Herpesviridae organisms are true, *except*:

A. Are deoxyribonucleic acid (DNA) viruses.
B. Contain a central core surrounded by a protein capsid.

for detailed information on ophthalmology books, visit our website **www.jaypeebrothers.com,** for detailed information on ophthalmol

Ophthalmology Review

Salient Features

- Completely updated and enlarged with new illustrations
- Reviews in depth the fundamentals of both clinical and basic ophthalmic sciences
- Intended as a general review for practicing clinicians as well as for the students
- Helps the students to prepare for primary and recertifying examinations.

Myron Yanoff MD is Chair Emeritus and Professor, Department of Ophthalmology, Drexel University College of Medicine, Philadelphia, Pennsylvania, USA. A recipient of the prestigious Senior Distinguished US Scientist Award (Humbolt Award), he is active in anterior segment clinical activity and research.

Available at all medical bookstores
or buy online at www.jaypeebrothers.com



JAYPEE BROTHERS
Medical Publishers (P) Ltd.
www.jaypeebrothers.com

Join us on facebook.com/JaypeeMedicalPublishers

Shelving Recommendation
OPHTHALMOLOGY

