ers.com, for detailed information on pathology books, visit our website www.jaypeebrothers.com, for detailed information on pathology books

Celebrating 50 Passion, Quality and Innovation in Healthcare Publishing

# 101 Medical Autopsy Cases Adult & Pediatric

## With Complete Pathological/Clinical Details and Review of Literature

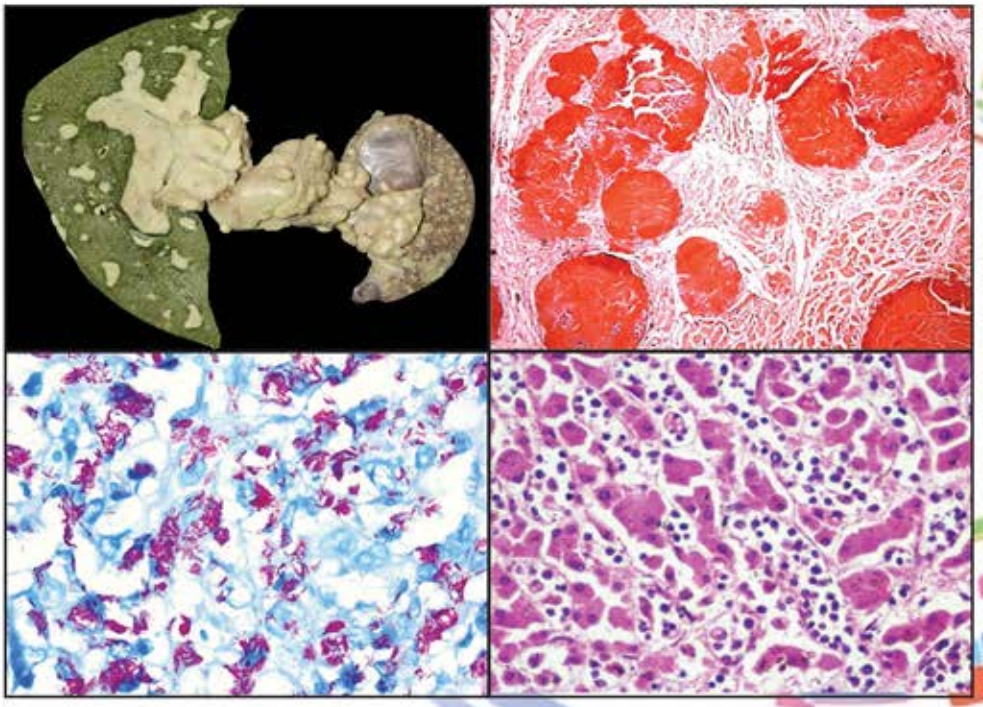

*Editor*
**Nandita Bharadwaj Kakkar**

*Foreword*
**Vinay Kumar**

JAYPEE

# 101 Medical Autopsy Cases Adult and Pediatric

## (With Complete Pathological/Clinical Details and Review of Literature)

*Editor*

**Nandita Bharadwaj Kakkar** MD FICPath
Professor
Department of Histopathology
Post Graduate Institute of Medical Education and Research
Chandigarh, India

*Foreword*

**Vinay Kumar** MBBS MD FRCPath

**JAYPEE BROTHERS MEDICAL PUBLISHERS**
*The Health Sciences Publisher*
New Delhi | London | Panama

JAYPEE BROTHERS

# Contents


## Introduction

Medical Autopsy: The Strongest Teaching Tool in Medicine xxvii

## Section 1: Hematological Disorders—Adult Cases

Case 1: Mantle Cell Lymphoma, Presenting with Florid Cutaneous Lesions, with Common Variant Morphology in the Nodal/Extranodal Sites and Blastoid Morphology in the Peripheral Blood: PM 25983 3
*Nandita Bharadwaj Kakkar*

Case 2: Primary Myelofibrosis, Cellular Phase with Formation of Sclerosing Extramedullary Hematopoietic Tumors: PM 27873 13
*Nandita Bharadwaj Kakkar*

Case 3: Primary Myelofibrosis, Cellular Phase with Extensive Extramedullary Hematopoiesis and Transformation into Acute Leukemia: PM 23618 23
*Nandita Bharadwaj Kakkar*

Case 4: Hepatosplenic T-cell Lymphoma: PM 23096 31
*Nandita Bharadwaj Kakkar*

Case 5: Acute Promyelocytic Leukemia with Early Death due to Disseminated Intravascular Coagulation and Right Temporal Lobe Hemorrhage: PM 26880 38
*Nandita Bharadwaj Kakkar*

Case 6: Acute Promyelocytic Leukemia with Differentiation Syndrome: PM 17959 47
*Nandita Bharadwaj Kakkar*

Case 7: Chronic Lymphatic Leukemia, Post-Bone Marrow Transplantation with Recurrence, Massive Lymphadenopathy and Hemophagocytosis: PM 21710 53
*Nandita Bharadwaj Kakkar*

Case 8: Symptomatic Plasma Cell Myeloma with Primary Systemic Amyloidosis Showing a Predominant Involvement of the Heart and Gastrointestinal Tract: PM 19667 61
*Nandita Bharadwaj Kakkar*

## Section 2: Malignancy—Adult Cases

Case 9: Microscopic/Occult Testicular Seminoma with Germ Cell Neoplasia in situ and Widespread Nonseminomatous Metastasis in a Young Male: PM 14170 71
*Nandita Bharadwaj Kakkar*

Case 10: Malignant Teratoma, Primary Pulmonary, Containing Yolk Sac tumor, Associated with Hematologic Neoplasia: PM 13633 80
*Nandita Bharadwaj Kakkar*

Case 11: Young Male with Metastasis: Do not Waste Time—Look for the Primary in the Testes: PM 19388 88
*Nandita Bharadwaj Kakkar*


JAYPEE BROTHERS

Case 12: Occult, Peripheral, Mucin-secreting Adenocarcinoma of Lung with Florid Meningeal Carcinomatosis along with Thrombotic Microangiopathy and Disseminated Intravascular Coagulation, Leading to Bilateral Renal Infarction: PM 26226 96
*Nandita Bharadwaj Kakkar*

Case 13: Young Male with Occult, Diffuse Type, Mucin-secreting Adenocarcinoma of the Stomach with Extensive Lymphangitic Carcinomatosis, Presenting with Deep Vein Thrombosis and Pulmonary Embolism: PM 21829 107
*Nandita Bharadwaj Kakkar*

## Section 3: Infections—Adult Cases

Case 14: Amebic Ileocolitis, Perforation and Liver Abscess: PM 18836 119
*Nandita Bharadwaj Kakkar*

Case 15: Cerebral Toxoplasmosis in a Human Immunodeficiency Virus Positive Patient: PM 19210 126
*Nandita Bharadwaj Kakkar*

Case 16: Pulmonary Hyalinizing Granuloma with Recent Onset Cryptococcal Meningoencephalitis in an Immunocompetent Male: PM 21122 133
*Nandita Bharadwaj Kakkar*

Case 17: Leptospirosis with Multiorgan Involvement: PM 22793 142
*Nandita Bharadwaj Kakkar*

Case 18: Silicotuberculosis: PM 26075 149
*Nandita Bharadwaj Kakkar*

Case 19: Rabies Meningoencephalitis, Post-Pet Dog Bite: PM 27786 157
*Nandita Bharadwaj Kakkar*

## Section 4: Hepatobiliary and Pancreatic Disorders—Adult Cases

Case 20: Extrahepatic Portal Venous Obstruction due to Cavernomatous Transformation of Portal Vein and Portal Cavernoma Cholangiopathy: PM 22260 167
*Nandita Bharadwaj Kakkar*

Case 21: Chronic Budd-Chiari Syndrome with Mesoatrial Shunt, Venocentric Cirrhosis, Hepatocellular Carcinoma Infiltrating into the Hepatic Duct Causing Obstruction and Hemobilia: PM 27800 175
*Nandita Bharadwaj Kakkar*

Case 22: Acute on Chronic Pancreatitis Leading to Portal Vein Pyemia, with Multiple Liver Abscesses and Life-threatening Sepsis Shock: PM 25975 184
*Nandita Bharadwaj Kakkar*

Case 23: Lipomatous Pseudohypertrophy of the Pancreas with Polyglandular Autoimmune Syndrome Type II and Inflammatory Myopathy: PM 22590 193
*Nandita Bharadwaj Kakkar*

Case 24: Young Male with Early Onset Micronodular Cirrhosis due to Synergistic Hepatotoxic Effect of Alcohol and Hepatitis C Virus Infection along with Cryoglobulinemic Vasculitis: PM 27791 201
*Nandita Bharadwaj Kakkar*

Case 25: Diffuse Hepatocellular Carcinoma Arising in a Setting of Mixed Nodular Cirrhosis, Hepatitis C Virus and Alcohol Related: PM 26695 212
*Nandita Bharadwaj Kakkar*

JAYPEE BROTHERS

Case 26: Acute Liver Failure and Encephalopathy in a Case of Dengue Shock Syndrome: PM 25035 220
*Nandita Bharadwaj Kakkar*

Case 27: Postpartum, Hyperacute, Fulminant Hepatic Failure due to Hepatitis E Virus: PM 26595 225
*Nandita Bharadwaj Kakkar*

Case 28: Sporadic, Hepatitis E-related Massive Hepatic Necrosis in a Young Female: PM 26254 231
*Nandita Bharadwaj Kakkar*

Case 29: A Classical Case of Wilson's Disease with Hepatic and Neuropsychiatric Manifestations: PM 26195 235
*Nandita Bharadwaj Kakkar*

**Section 5: Cardiovascular System—Adult Cases**

Case 30: Silent Healed Myocardial Infarction and its Complications—Infarct Expansion, Mural Thrombosis, Aneurysm Formation, Extensive Arterial Embolization, Deep Vein Thrombosis and Subsequent Fatal Venous Thromboembolism: PM 21817 245
*Nandita Bharadwaj Kakkar*

Case 31: Coexistence of Acute-on-Chronic Rheumatic Heart Disease and Acute Poststreptococcal Glomerulonephritis: PM 21119 255
*Nandita Bharadwaj Kakkar*

Case 32: A Classical Case of Marfan Syndrome with Aortic Root Dilatation, Aneurysm of the Ascending Aorta and Acute Aortic Dissection: PM 22554 264
*Nandita Bharadwaj Kakkar*

Case 33: Adult Tetralogy of Fallot with Tricuspid Valve Infective Endocarditis and Thromboembolic Botryomycotic Cerebral Abscess: PM 26941 272
*Nandita Bharadwaj Kakkar*

Case 34: Cocaine-induced Vasculopathy Leading to Cardiomyopathy, Renal Infarcts, Gangrene of Digits with Autoamputation: PM 23445 281
*Nandita Bharadwaj Kakkar*

Case 35: Aftermath of Hypertension in a Middle-aged Male—Intraparenchymal Brain Hemorrhage, Pontine and Thalamic: PM 26485 288
*Nandita Bharadwaj Kakkar*

**Section 6: Systemic Vasculitides—Adult and Pediatric Cases**

Systemic Vasculitides—Introduction 297
*Nandita Bharadwaj Kakkar*

Small Vessel Vasculitides 299
*Nandita Bharadwaj Kakkar*

Case 36: Renal Limited Microscopic Polyangiitis: PM 13127 307
*Nandita Bharadwaj Kakkar*

Case 37: Microscopic Polyangiitis, ANCA Negative, with Florid Glomerulitis and Granulomatous Glomerulonephritis: PM 15649 312
*Nandita Bharadwaj Kakkar*

Case 38: Microscopic Polyangiitis in a Child: PM 16450 318
*Nandita Bharadwaj Kakkar*

JAYPEE BROTHERS

Case 39: Microscopic Polyangiitis, ANCA Negative, Clinically Mimicking Granulomatosis with Polyangiitis (Wegener's Granulomatosis) and Presenting with a Breast Mass: PM 18473 323
*Nandita Bharadwaj Kakkar*

Case 40: Microscopic Polyangiitis—Chronic Phase: PM 18987 331
*Nandita Bharadwaj Kakkar*

Case 41: Microscopic Polyangiitis with Acute Vasculitis of Small, Medium and Large-sized Arteries: PM 20415 338
*Nandita Bharadwaj Kakkar*

Case 42: p-ANCA Positive Classic Polyarteritis Nodosa: PM 24277 347
*Nandita Bharadwaj Kakkar*

Case 43: Takayasu's Aortoarteritis, Pulmonary Hypertension, and Pulmonary Capillary Hemangiomatosis: PM 14993 356
*Nandita Bharadwaj Kakkar*

Case 44: Takayasu Aortoarteritis, Presenting with Pulmonary Arterial Hypertension Secondary to Extensive Involvement of Right Pulmonary Artery: PM 25988 363
*Nandita Bharadwaj Kakkar*

Case 45: Granulomatosis with Polyangiitis (Wegener's Granulomatosis) with Left Foot Gangrene and Right Hemiplegia: PM 14106 374
*Nandita Bharadwaj Kakkar*

Case 46: Granulomatosis with Polyangiitis—Wegener's Granulomatosis, Presenting as an Anterior Mediastinal Mass: PM 18613 380
*Nandita Bharadwaj Kakkar*

Case 47: Granulomatosis with Polyangiitis, i.e Wegener's with Multiple Pulmonary Nodules and Total Splenic Necrosis: PM 21594 388
*Nandita Bharadwaj Kakkar*

Case 48: c-ANCA Positive, Nonreactive, Disseminated Tuberculosis with Pulmonary and Mesenteric Vasculitis: PM 14513 394
*Nandita Bharadwaj Kakkar*

**Section 7: Primary Renal Mucormycosis—Adult and Pediatric Cases**

Case 49: Isolated Bilateral Renal Mucormycosis with Contiguous Spread to the Adrenals, Mesentery, Pancreas and Colon in an Apparently Immunocompetent Adult: PM 27250 405
*Nandita Bharadwaj Kakkar*

Case 50: Primary Bilateral Renal Mucormycosis in an Apparently Immunocompetent Child: PM 22863 412
*Nandita Bharadwaj Kakkar*

**Section 8: Histiocytosis—Pediatric and Adult Cases**

Case 51: Primary/Familial Hemophagocytic Lymphohistiocytosis with Extensive Involvement of the Brain: PM 20788 423
*Nandita Bharadwaj Kakkar*

Case 52: Langerhans Cell Histiocytosis Presenting as an Anterior Mediastinal Mass: PM 21476 432
*Nandita Bharadwaj Kakkar*

JAYPEE BROTHERS

Case 53: Macrophage Activation Syndrome—A Fatal Complication of Systemic Onset Juvenile Idiopathic Arthritis: PM 26202 440
*Nandita Bharadwaj Kakkar*

Case 54: Epstein–Barr Virus-associated Secondary Hemophagocytic Lymphohistiocytosis—A Rare Complication: PM 21703 446
*Nandita Bharadwaj Kakkar*

**Section 9: Primary Immunodeficiency—Pediatric Cases**

Case 55: Disseminated Bacillus Calmette–Guérin Infection in a Case of Severe Combined Immunodeficiency: PM 22931 457
*Nandita Bharadwaj Kakkar*

Case 56: Chronic Granulomatous Disease of Childhood: PM 24170 468
*Nandita Bharadwaj Kakkar*

Case 57: Disseminated Nonreactive Tuberculosis, PCR-Proven Dual Positivity for *Mycobacterium Tuberculosis* and *Abscessus* ? Mendelian Susceptibility to Mycobacterial Disease: PM 25174 478
*Nandita Bharadwaj Kakkar*

**Section 10: Infantile Nephrotic Syndrome**

Case 58: Congenital Nephrotic Syndrome of the Finnish Type: PM 23777 489
*Nandita Bharadwaj Kakkar*

Case 59: Infantile Nephrotic Syndrome—Diffuse Mesangial Sclerosis in a 10-Month-Old Male Child: PM 26462 496
*Nandita Bharadwaj Kakkar*

**Section 11: Infections—Pediatric Cases**

Case 60: Disseminated Congenital Cytomegalovirus Infection with Islet Cell Hyperplasia as the Cause of Persistent Hypoglycemia in a Neonate: PM 23822 507
*Nandita Bharadwaj Kakkar*

Case 61: Congenital Tuberculosis: An Underdiagnosed Entity: PM 24753 514
*Nandita Bharadwaj Kakkar*

Case 62: Disseminated Cryptococcomas Mimicking Disseminated Malignancy, with Hepatic Dysfunction as the Initial Manifestation, in an Immunocompetent Child: PM 25744 523
*Nandita Bharadwaj Kakkar*

Introduction to Tubercular Meningitis 534
*Nandita Bharadwaj Kakkar*

Case 63: Catastrophic Posterior Circulation Tubercular Arteritis with Infarcts and Cortical Venous Thrombosis—A Rare Co-existence: PM 26344 538
*Nandita Bharadwaj Kakkar*

Case 64: Child with Disseminated Miliary Tuberculosis, Tubercular Meningitis with Extensive Arteritis, Infarction and Ischemic Hepatitis: PM 25901 544
*Nandita Bharadwaj Kakkar*

JAYPEE BROTHERS

Case 65: Disseminated Cryptococcal Infection in an HIV-positive Child: PM 23563 553
*Nandita Bharadwaj Kakkar*

## Section 12: Cardiovascular System—Pediatric Case

Case 66: Transposition of Great Arteries: PM 24027 563
*Nandita Bharadwaj Kakkar*

## Section 13: Hematological Disorders—Pediatric Cases

Case 67: Child with Acute Lymphoblastic Leukemia on Induction Therapy with Febrile Neutropenia and Disseminated *Aspergillus* Infection: PM 25927 569
*Nandita Bharadwaj Kakkar*

Case 68: Myeloid Sarcoma of Lacrimal Sac as the First Manifestation of AML-M1 with Acute Diffuse Colorectal Neutropenic Colitis in a Child: PM 23395 576
*Nandita Bharadwaj Kakkar*

## Section 14: Storage Disorder

Case 69: Niemann–Pick Type B Presenting with Massive Splenohepatomegaly and Hypertensive Crisis in a 12-year-old Child: PM 27096 587
*Nandita Bharadwaj Kakkar*

## Section 15: Pediatric Renal Cystic Disease (Developmental/Genetic/Syndromes)

Pediatric Cystic Disease (Developmental/Genetic) of Kidney—Introduction 601
*Nandita Bharadwaj Kakkar*

**Section 15A: Renal Dysplasia**

Case 70: Recurrent Bilateral Multicystic Dysplastic Kidneys, Consistent with Hereditary Renal Adysplasia: PM 20505 609
*Nandita Bharadwaj Kakkar*

Case 71: Symmetrically Enlarged, Solid Dysplastic Kidneys with Intrauterine Growth Retardation: PM 24340 612
*Nandita Bharadwaj Kakkar*

Case 72: Multicystic Dysplastic Kidneys with Dilated Ureters and Hypertrophied Urinary Bladder Leading to Obstructed Labor and Uterine Rupture: PM 26207 615
*Nandita Bharadwaj Kakkar*

Case 73-74: Renal Hypodysplasia: PM 19521, PM 25711 619
*Nandita Bharadwaj Kakkar*

Case 75: Bilateral Renal Agenesis: PM 24019 623
*Nandita Bharadwaj Kakkar*

Case 76-80: Unilateral Renal Malformation: PM 22428, PM 22393, PM 26428, PM 26291, PM 26824 626
*Nandita Bharadwaj Kakkar*

Case 81: Segmental Renal Dysplasia with Duplex Kidney and Ureterocele: PM 19965 633
*Nandita Bharadwaj Kakkar*

JAYPEE BROTHERS

**Section 15B: Posterior Urethral Valve**

Case 82-83: Posterior Urethral Valve Leading to Congenital Hydroureteronephrosis and Hypertrophied Urinary Bladder: PM 18485, PM 26118 636
*Nandita Bharadwaj Kakkar*

**Section 15C: Renal Hypoplasia**

Case 84: Neonate with Bilateral Simple Renal Hypoplasia, Lung Hypoplasia and Hydrocephalous: PM 27245 642
*Nandita Bharadwaj Kakkar*

Case 85: Bilateral Simple Renal Hypoplasia, Cystic Periventricular Leukomalacia with Hydrocephalus ex vacuo in Surviving Twin, after death of Monochorionic Co-twin: PM 25677 646
*Nandita Bharadwaj Kakkar*

Case 86: Segmental Hypoplasia (Ask-Upmark Kidney): S-14525/2008 655
*Nandita Bharadwaj Kakkar*

**Section 15D: Genetic Disorders**

Case 87: A Classical Case of Autosomal Recessive Polycystic Kidney Disease: PM 22879 657
*Nandita Bharadwaj Kakkar*

Case 88: Autosomal Dominant Polycystic Kidney Disease with Cyst Infection: PM 22828 662
*Nandita Bharadwaj Kakkar*

**Section 15E: Glomerulocystic Kidney Disease**

Case 89: Co-existing Glomerulocystic Kidney Disease and Renal Tubular Dysgenesis with Late Onset Oligohydramnios and Renal Failure at D2 of Life: PM 28154 669
*Nandita Bharadwaj Kakkar*

Case 90: Glomerulocystic Kidney Associated with Posterior Urethral Valve—A Rare Association: PM 28255 678
*Nandita Bharadwaj Kakkar*

**Section 15F: Syndromes**

Case 91-92: Meckel–Gruber Syndrome: PM 20070, PM 26190 683
*Nandita Bharadwaj Kakkar*

Case 93-94: Prune Belly Syndrome Leading to a Markedly Distended Urinary Bladder and Hydroureteronephrosis: PM 23424, PM 25509 689
*Nandita Bharadwaj Kakkar*

Case 95: Sirenomelia with Bilateral Renal Agenesis and Multiple Other Malformations: PM 27025 698
*Nandita Bharadwaj Kakkar*

**Section 16: Liver Disorders—Pediatric Cases**

Case 96: Coexistence of Duarte 2 Variant of Galactosemia with Niemann–Pick Disease Type B, in an Infant: PM 23108 703
*Nandita Bharadwaj Kakkar*

Case 97: A Classical Case of Galactosemia: PM 23869 710
*Nandita Bharadwaj Kakkar*

Case 98: Galactosemia, Double Heterozygous for N314D and Q188R Mutations, with Micronodular Cirrhosis and Absence of Steatosis: PM 25342 716
*Nandita Bharadwaj Kakkar*

JAYPEE BROTHERS

Case 99: A Case of Galactosemia, Double Heterozygous for Q188R and E308K Mutations with Early Neonatal Acute Liver Failure: PM 25552 722
*Nandita Bharadwaj Kakkar*

Case 100: Neonate with Hemolytic Disease of Newborn (Due to Rh Isoimmunization—for both Rh-D Antigen and Rh-C Antigen), Conjugated Hyperbilirubinemia, and Associated Nonsyndromic Paucity of Intrahepatic Bile Ducts: PM 27937 728
*Nandita Bharadwaj Kakkar*

Case 101: Indian Childhood Cirrhosis: PM 24527 737
*Nandita Bharadwaj Kakkar*

*Abbreviations* *743*

*Index* *745*

JAYPEE BROTHERS

# Introduction

# Medical Autopsy: The Strongest Teaching Tool in Medicine

*Nandita Bharadwaj Kakkar*

Autopsy is the dissection of a dead human body and is performed to find the cause of death. The Greek word "autopsy" means "to see with one's own eyes". Autopsy pathology is the best method of learning pathology and medicine. "Pathology" was actually born at the autopsy table. The history of autopsy dates back to 3000 BC when the ancient Egyptians used to practice the removal and examination of the internal organs of dead humans in their religious practice of "mummification". The word autopsy comes from the Greek, meaning "to see with one's own eyes." Synonymous terms are *"necropsy/postmortem"* but the term *"autopsy"* is more popular and hence widely used.

**Autopsies are of two kinds**:

- ***Forensic/Medicolegal/Coroner's autopsy:*** This is ordered by law, when death occurs under suspicious circumstances, sudden death or accidental death.
- ***Medical/Clinical/Pathological autopsy*:** They are performed to find the cause of death and for research purposes. In this book, I have used the term "Medical Autopsy". For a medical autopsy, mandatory prerequisite is to get the consent from the "next of kin", after explaining the procedure in clear words along with the benefits. No force should be applied. The job of the clinician is to only recommend but "cannot order" a medical autopsy. The next of kin are generally recognized in the following order—spouse, children of legal age, parents, siblings of legal age and legal guardians/custodians.

## MEDICAL AUTOPSY TECHNIQUES

- ***Rudolf Virchow***, in the 19th century, established and published specific autopsy protocols which till date bear his name. It is known as the "Technique of R Virchow" wherein the organs are removed one by one.
- ***C Rokitansky*** established a technique characterized by in situ dissection combined with en-block removal of the organ blocks.
- ***Ghon's technique*** is characterized by "en bloc" removal of thoracic/cervical organs, abdominal organs and urogenital system. Thus, in this technique there are multiple organ blocks.
- ***M Letulle*** established the technique of "en masse" removal where in the thoracic, cervical, abdominal and pelvic organs are removed as one organ block and then subsequently dissected into individual organ blocks. This technique is cumbersome and needs more experience. This is a quick method and the body can be returned to the relatives in a shorter time. The dissection can then be done subsequently with ease.

## TYPES OF MEDICAL AUTOPSIES

- Abdominal with/without brain
- Abdominothoracic with/without brain
- Brain only
- Brain with spinal cord
- Any special instruction
- Multiple biopsy autopsies (In PGIMER, this if done is done by the clinicians)

JAYPEE BROTHERS

We generally use the term partial autopsy for abdominothoracic without removal of the brain and complete autopsy for abdominothoracic with brain.

## BENEFITS OF MEDICAL AUTOPSY

- ***To Find the "Cause of Death"***
  - In the adult medical autopsies, the relatives get to know the exact cause of death and this satisfies their mind. Any infectious disease like tuberculosis (which is rampant in India) can be diagnosed and the relatives can be given adequate treatment.
  - In the pediatric age group, the benefits are many. Death of a child, infant, neonate and still births (early and late) is the most devastating event for parents. Due to advancements in radiology, a new group has come up for medical autopsies, i.e. the fetuses (Previable fetuses <20 weeks gestation) who undergo medical termination for various malformations.
    - Medical autopsy establishes the exact cause of death and this satisfies the parents to some extent in bearing with the loss of their child.
    - Valuable information about congenital malformations, genetic or inherited diseases is obtained and this helps in planning the next pregnancy.
- ***Audit***
  Autopsy gives you the complete pathology of the disease process occurring in every organ of the body and hence it teaches the clinicians, where they went wrong in their diagnosis and treatment and how to rectify it. This is the best audit available in the field of medicine.
- ***Final Autopsy Diagnosis***
  Pathologist gives the final answer. This helps in bringing revolution in treatments, better techniques and makes a remarkable difference in patient care.
- ***Unraveling New Entities in a Particular Part of the World***
  New pathological entities are diagnosed, which had never been seen in the area. This changes the mindset of the clinicians and if they see such a case again, it helps them in making an early and correct diagnosis. Examples from PGIMER—(1) Familial hemophagocytic lymphohistiocytosis with severe involvement of the central nervous system was first diagnosed at autopsy in 1996. This awareness led the clinicians to diagnose and treat subsequent patients. (2) Hepatosplenic γδ T cell lymphoma was first diagnosed at autopsy when it was a provisional entity in the WHO classification and this awareness was very fruitful. (3) The presence of "Leptospirosis" was first proven at autopsy in PGIMER, for which the serological confirmation was done on the postmortem sample from Lal Path Laboratory, New Delhi. Thereafter a strong laboratory support was established in our institute for leptospirosis and more such cases are being diagnosed and treated ever since.
- ***Pediatric Autopsies—Special Benefits***
  - Medical autopsy is the best audit for neonatal deaths, stillbirths (early and late) and terminated fetuses. All autopsied cases are discussed in the neonatal/stillbirth mortality rounds held once in a month in our institute.
  - The "Final Autopsy Diagnosis" of all terminated fetuses (with various congenital malformations) is correlated with the radiological diagnosis for which the pregnancy was terminated. This gives immense relief to the parents that their decision for MTP was correct. They are then sent to the "Genetic clinic" for further management and planning a subsequent pregnancy.

## PROCEDURE FOR MEDICAL AUTOPSY AT PGIMER, CHANDIGARH, INDIA

We are more or less following the Letulle's technique as most of our incision permissions are abdominothoracic and we remove the entire organs "en masse" and later dissect them out meticulously.

- The organs are dissected and kept flat in a tray as follows for 7–10 days in 10% formalin.
  - ***As complexes***—(1) Organ complex comprising of both the lungs (adequately sliced) and the tracheobronchial tree. (2) Organ complex comprising of slice of liver, c loop of duodenum, pancreas, gallbladder with the dissected biliary tract and slice of spleen. (3) Organ complex comprising of both kidneys, ureters, urinary bladder, abdominal aorta, para-aortic lymph nodes and part of inferior vena cava. (4) Testes with their respective spermatic cords. (5) Uterus with cervix, fallopian tubes and both ovaries. (6) Heart with its arch and part of descending aorta, dissected along the flow of blood from right to the left side.
  - ***As individual organs***—Remaining slices of liver and spleen, adrenals, thymus, lymph nodes, stomach with esophagus, small and large intestine, mesentery, bone piece from the vertebrae, skin, psoas muscle, thyroid/parathyroids.
- *The brain* is kept intact with the brain stem floating in a bucket of 20% formalin hanging from a thread passing

JAYPEE BROTHERS

via the Circle of Villus, the thread tied on either side to the handles of the bucket. The meninges and the pituitary gland are also kept. After fixing for 10–12 days, the brain is cut.

- *Postmortem samples*: Blood sample is kept and fresh tissues if needed (i.e. kidney etc.) are kept at –80° (for immunofluorescence and molecular techniques if needed later on) and in glutaraldehyde for electron microscopy.
- *Organ review conference*: This is done after 7–10 days of fixing the organs. Gross autopsy diagnosis is made and adequate sections (minimum 30–35 in an adult autopsy) are taken and sent for processing. Gross photographs are taken.
- *Brain review conference*: The brain cutting is done 10–12 days after fixation. Five standard sections and additional sections if needed are taken and sent for processing.
- *Pediatric autopsies*: Anthropometric measurements, weight of the body and external gross photographs are taken at the time of autopsy. External congenital malformations are meticulously enumerated and photographed. Infantogram is taken if needed. The heart–lung complex is kept together. For Arnold Chiari malformation, the incision is given on the nape of the neck and the displacement of the brainstem into the foramen magnum is documented.
- *Review of slides*: Hematoxylin and eosin stained slides are examined. Special stains, electron microscopy, immunohistochemistry and other special tests, i.e. PCR confirmation of infections etc. are done if needed. Clinical details are sought for, correlations are done and a "Final Autopsy Diagnosis" is made. Gross and photomicrographs are taken and a 20-minute PowerPoint presentation is made.

## CLINICOPATHOLOGIC CORRELATION CONFERENCE—CPCC

Three CPCCs are done every week in the main lecture theater of the institute and this is attended by the entire medical fraternity of PGIMER and doctors/students from the local Medical college and other hospitals of Chandigarh. This CPCC is relayed "live" by the Telemedicine department to 14 medical institutes and medical schools across India. In the one hour session, the clinician presents the case along with the relevant investigating team, i.e. the radiologists, hematopathologists, cytologists, microbiologists, etc. The clinician thus gives his clinical diagnosis which is followed by open house discussion for 5–8 minutes. The pathologist then takes 20 minutes to explain the entire case organ wise, to reach to the "Final Autopsy Diagnosis" which is then followed by open house discussion. CPCC is the strongest teaching tool in medicine and this is the pride of PGIMER, Chandigarh, India.

## SUGGESTED READING

1. Connolly AJ, Finkbeiner WI, Ursell PC, et al. Autopsy Pathology: A Manual and Atlas, 3rd edition. US: Elseviers; 2016.
2. Enid GB, Spicer DE, et al. Handbook of Pediatric Autopsy Pathology, 2nd edition. New York: Springer; 2014.
3. Lanjerwar D, Vaideeswar P. Autopsy Practices, 1st edition. New Delhi: Jaypee Brothers Medical Publishers (P) Ltd; 2017.
4. Ludwig J. Handbook of Autopsy Practice, 3rd edition. Totowa New Jersey: Humana Press; 2002.

JAYPEE BROTHERS

# CASE 18

# Silicotuberculosis: PM 26075

*Nandita Bharadwaj Kakkar*

JAYPEE BROTHERS

## HIGHLIGHTS OF THE CASE

An 83-year-old male, stone cutter by profession, with no previous comorbidities, presented with on and off fever and cough for 4 months with intermittent episodes of hemoptysis and altered sensorium for 12 days. On examination he had hypotension, tachycardia and neck rigidity. Cerebrospinal fluid (CSF) analysis was exudative with elevated proteins, low sugars and 300 cells, predominantly polymorphs. Noncontrast computed tomography (NCCT) and contrast-enhanced computed tomography (CECT) head were within normal limits. Chest X-ray showed fine nodular opacities in both the lungs. A clinical diagnosis of pulmonary tuberculosis with tubercular meningitis was made. Autopsy revealed chronic silicosis (lung and hilar lymph nodes), disseminated miliary tuberculosis (AFB + +) involving the lungs (silico-tuberculosis), lymph nodes (hilar, mediastinal), liver, spleen, kidneys and bone marrow, tubercular meningitis with borderzone encephalitis, choroid plexitis and tuberculoma (AFB + + +), superadded bronchopneumonia, crossed fused renal ectopia, prostate hyperplasia and complicated atherosclerosis.

*Keywords:* Silicotuberculosis, tubercular meningitis, miliary tuberculosis, crossed fused renal ectopia, autopsy.

## CLINICAL DETAILS

**Date of Admission: 22.5.2014, Date of Death: 24.5.2014, Duration of Hospital Stay: 2 Days**

An 83-year-old male with no previous comorbidities presented with fever (on and off) and persistent cough of 4 months duration along with altered sensorium since 12 days. The fever was not associated with any rigors and chills. The cough was associated with mild expectoration with intermittent blood streaking. There was no diurnal variation. There was altered sensorium in the form of decreased responsiveness. However, no neurological deficits were seen. There was no history of seizure, jaundice, petechiae, diabetes, hypertension and pulmonary tuberculosis. He was a nonsmoker and did not consume alcohol. On physical examination, blood pressure was 90/50 mm Hg, pulse 150/min, respiratory rate 24/min and $SpO_2$—90% on room air. There was no pallor, icterus, cyanosis or lymphadenopathy. The abdomen was soft and nontender. There was no hepatomegaly. Respiratory and cardiovascular systems were within normal limits. Central nervous system (CNS) examination revealed E1VTM3, neck rigidity was present, pupils were both equal and reacting to light, deep tendon reflexes were +1 and plantars were mute. NCCT and CECT head were within normal limits. Features of raised intracranial tension were present. Chest X-ray showed fine nodular opacities in both the lungs.

### Investigations and Course of Management

Investigations revealed—Hb 11.3 g/dL, TLC 19300/μL and platelets 1,30,000/uL. Blood biochemistry revealed normal electrolytes, renal and liver function tests. CSF analysis was exudative with elevated proteins and low sugars and 300 cells, predominantly polymorphs (300 cells/with P80 L20, RBCs + and protein/sugar: 260/37 mg/dL). Arterial blood gas (ABG) showing hypoxia, $CO_2$ retention. Occupational history was found out after the autopsy and it came out that this man was a laborer and had worked for many years as a stone cutter. He was started on antibiotics and intravenous fluids after which his hypotension and tachycardia improved. But the next day he had bradycardia followed by sudden cardiac arrest and could not be revived. Units final diagnosis was pulmonary tuberculosis with tubercular

meningitis. Cause of death being refractory septic shock, type II respiratory failure and pulmonary thromboembolism.

## AUTOPSY FINDINGS: PM 26075

**Date of Admission: 22.05.2014, Date of Death: 24.05.2014, Duration of Hospital Stay: 2 Days**

A complete autopsy was performed. All serous cavities were within normal limits. The *lungs* (Fig 1A) were voluminous and together weighed 1,026 g. The pleural surface was dull with fibrinous tags and focal pleural thickening. The cut surface was blackish and subcrepitant to feel. No thrombus was identified. Numerous intimately admixed, blackish and yellowish nodules ranging in size from 0.2 cm to 0.5 cm were identified (Fig 1B). On microscopic examination, the black nodules were composed of acellular concentric lamellar bundles of collagen in the center, with numerous black pigment laden macrophages at the periphery (Figs 2A–D). On polarizing, these nodules showed brightly birefringent, needle-shaped crystals, indicating these to be silicate crystals (Fig 2E). Many of these silicotic nodules were present in the subpleural location leading to pleural thickening. The white millet sized nodules were composed of central area of caseation necrosis bordered by epithelioid cells, lymphocytes and Langhans type of giant cells (Figs 3A–C). The Ziehl–Neelsen stain showed strong positivity for acid-fast bacilli (AFB) (Fig 3D). Many of these small tubercular millet sized nodules were coalescing to form larger nodules. Few of the silicotic nodules showed signs of necrosis in the center. The adjacent lung parenchyma shows emphysematous change and superadded bronchopneumonia. The hilar and mediastinal *lymph nodes* also revealed typical silicotic nodules (Fig 4A) along with tubercular granulomas (Fig 4B) which were positive for AFB. Overall features were suggestive of chronic silicosis with miliary tuberculosis. The *brain* weighed 1,130 g. The external surface showed a thin meningeal exudate over the ventral aspect of temporal lobe (Fig 5A). In addition, basal exudates were also present. Bilateral tonsilar herniation was noted, supporting the presence of raised intracranial tension. On coronal slicing, a small tuberculoma was identified in the parahippocampal gyrus (Fig 5B). Lateral ventricles were mildly dilated. Microscopy revealed multiple epithelioid cell granulomas in the subarachnoid space (Fig 5C), many of which were surrounding the meningeal vessels causing fibrinoid necrosis and endarteritic changes (Figs 6A and B). This infiltrate was extending into the adjacent brain parenchyma leading to borderzone encephalitis (Fig 6B). The tuberculoma was sampled and showed extensive caseation necrosis surrounded by epithelioid cells, lymphocytes and

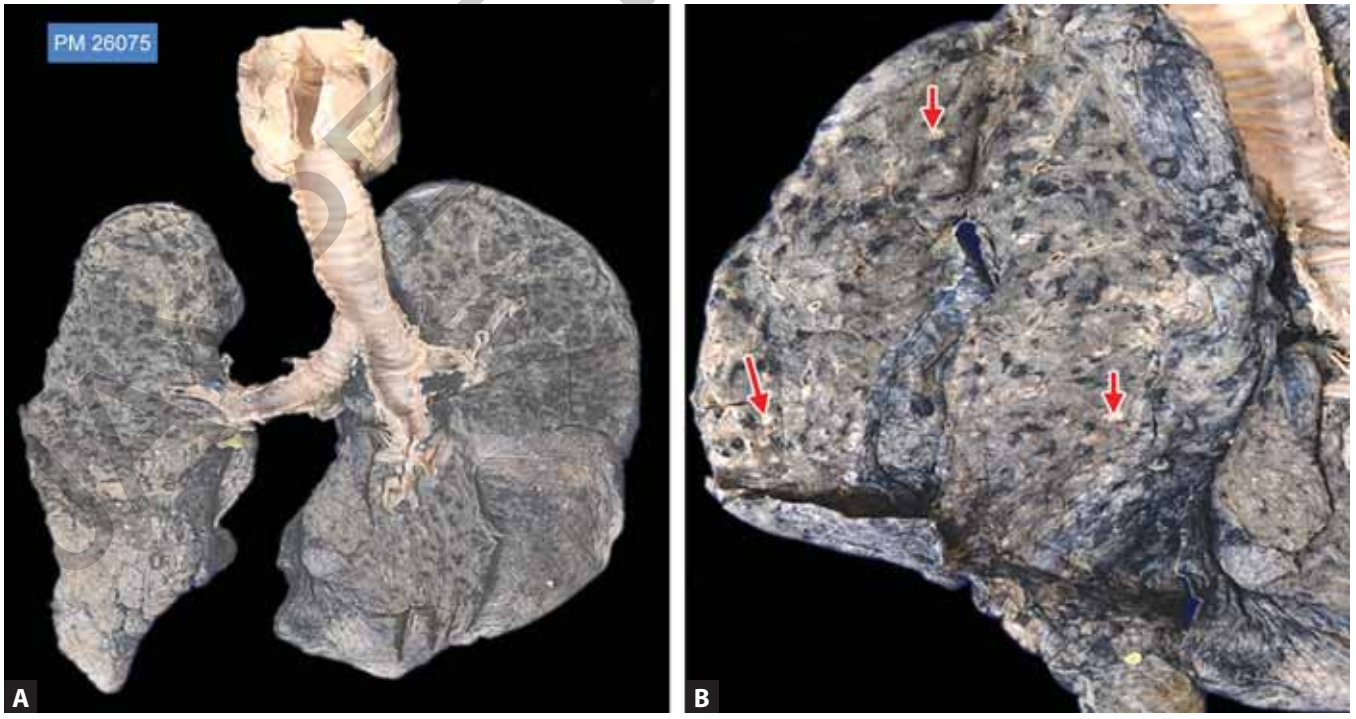


**Figs 1A and B:** (A) Gross picture of the voluminous lungs with the tracheobronchial tree; and (B) Close up of the cut section of the lung showing small white (red arrows) and black nodules.

JAYPEE BROTHERS

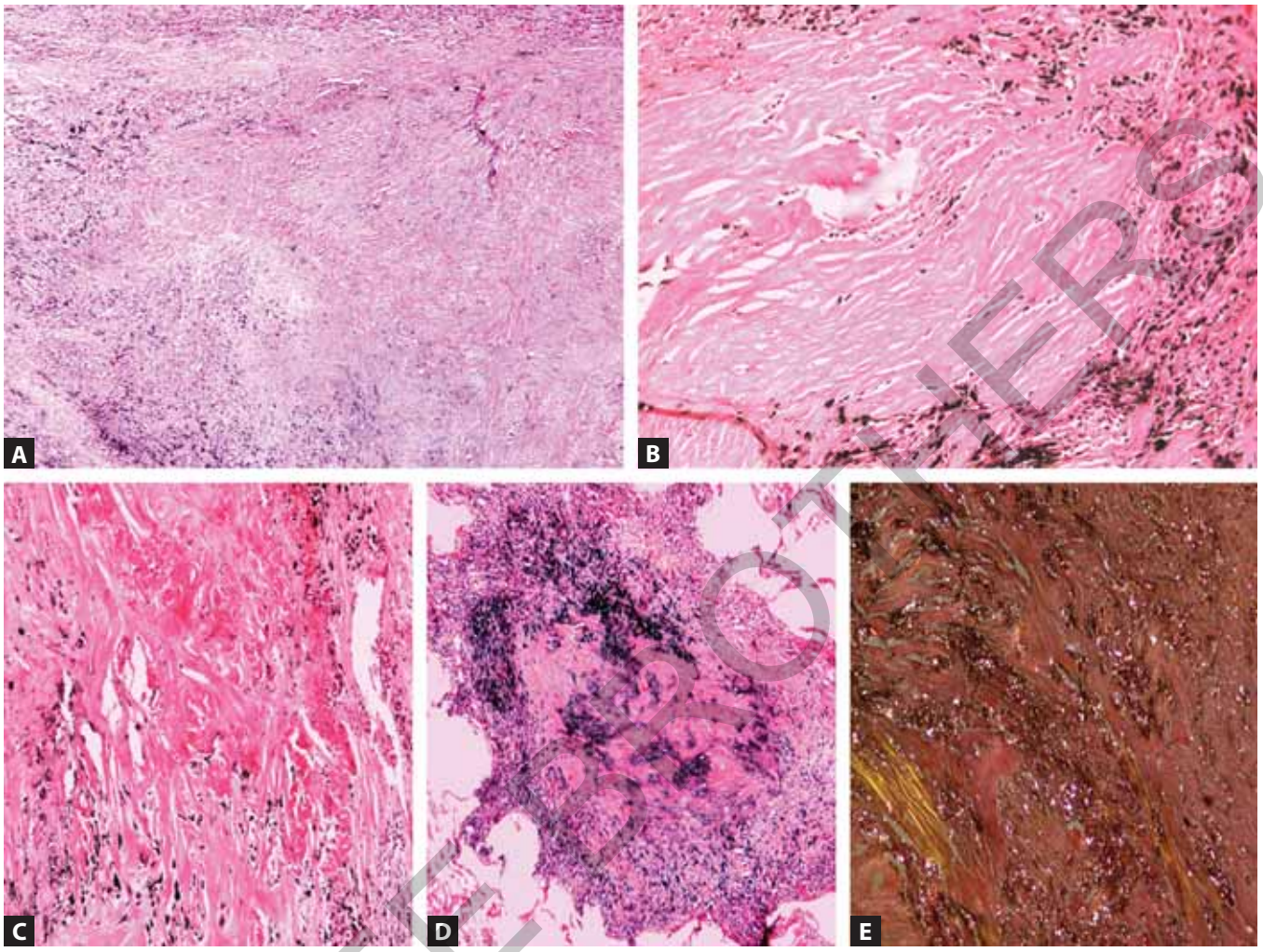


**Figs 2A–E:** (A to C) Low and high power of a large silicotic nodule with acellular concentric lamellar bundles of collagen in the center with numerous black pigment laden macrophages at the periphery; (D) A smaller silicotic nodule; and (E) Polarized light showing birefringent, needle-shaped crystals of silica.

JAYPEE BROTHERS

Langhans giant cells. Choroid plexitis was noted in the form of inflammation and multiple granulomas (Fig 6C). Stain for AFB was very strongly positive in the meningeal exudate (Fig 6D). Features were those of tubercular meningitis with borderzone encephalitis, choroid plexitis and tuberculoma. Multiple epithelioid cell granulomas were noted in the *liver* (portal tracts and lobules) (Fig 7A), *spleen* and the *bone marrow* (Fig 7B). Both the *kidneys* (weighed 290 g) were fused and were placed on right side of the aorta, consistent with the diagnosis of crossed fused renal ectopia (Figs 7C and D). They showed vascular splaying with three different branches arising from the abdominal aorta and supplying one each at both the poles of kidney and third one was entering the middle portion of the kidney. There were two separate venous draining channels one from each pelvis and two ureters. On microscopic examination, multiple epithelioid cell granulomas were noted in the cortex and medulla (Fig 7E). The *heart* weighed 338 g and was unremarkable. The coronaries revealed atherosclerosis and calcification of the vessel wall, with 30–40% occlusion. The arch and descending thoracic aorta revealed complicated atherosclerosis. There was adenoleiomyomatous hyperplasia seen in the *prostate* and adrenals showed hemorrhage. Other organs were within normal limits. Occupational history was found after the autopsy diagnosis was made. The fact came to light that this man was a laborer, who had worked for many years as a stone cutter.

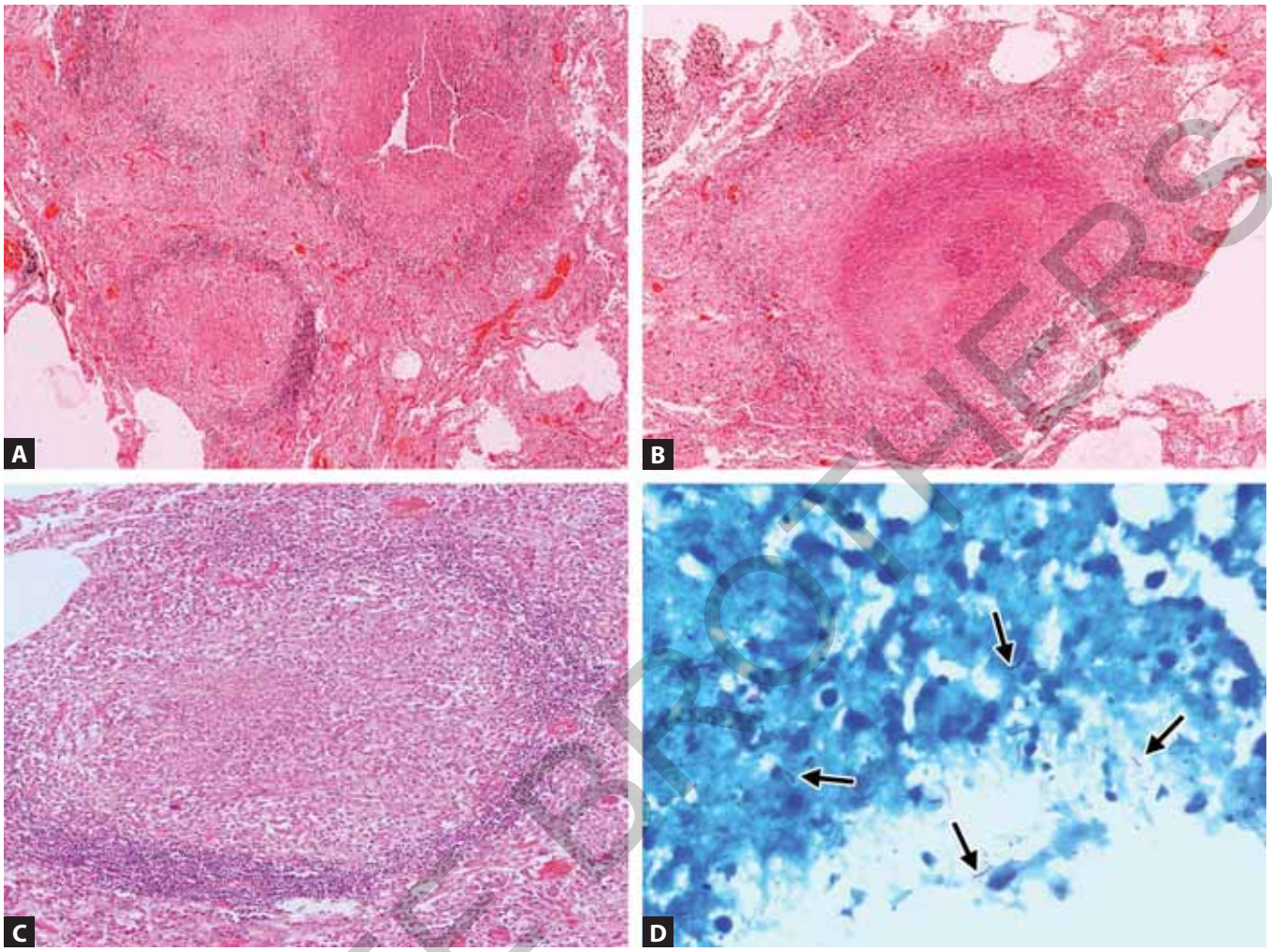


**Figs 3A–D:** (A to C) Photomicrographs of the lung showing granulomas with central area of caseation necrosis bordered by epithelioid cells, lymphocytes and few Langhans type of giant cells; and (D) Ziehl–Neelsen stain showing plenty of acid fast bacilli (arrows).

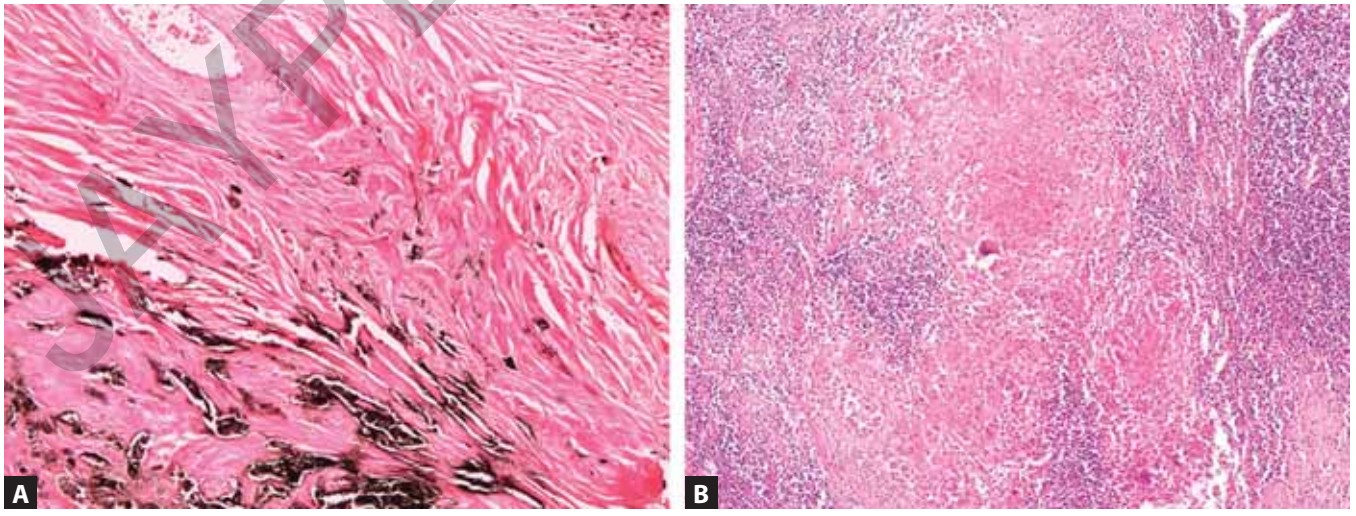


**Figs 4A and B:** (A) Silicotic nodule in the mediastinal lymph node; and (B) Epithelioid cell granulomas in the lymph node.

JAYPEE BROTHERS

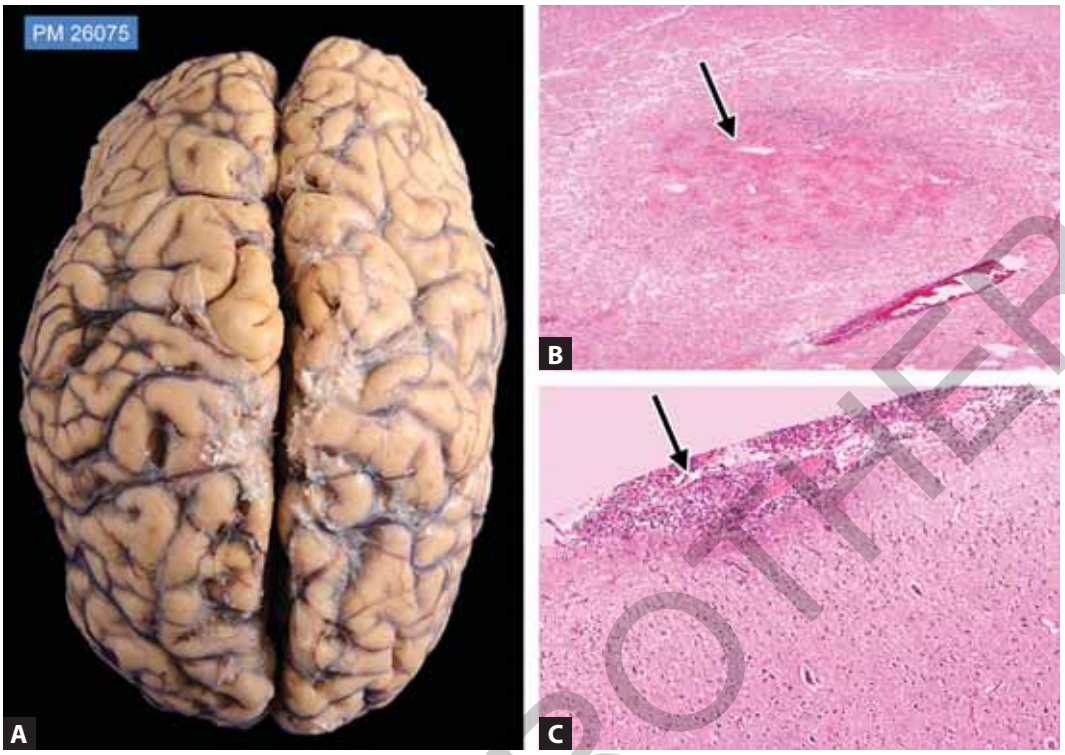


**Figs 5A–C:** (A) Superolateral surface of the brain showing a mild meningeal exudate; (B) Tuberculoma (arrow) in the parahippocampal gyrus; and (C) Granulomatous inflammation in the subarachnoid space (arrow).

## FINAL AUTOPSY DIAGNOSIS: PM 26075

**83 Years Old Male**

- Chronic silicosis—lung and hilar lymph nodes
- Disseminated miliary tuberculosis (AFB + +) involving the lungs (silicotuberculosis), lymph nodes (hilar, mediastinal), liver, spleen, kidneys and bone marrow
- Tubercular meningitis with borderzone encephalitis, choroid plexitis and tuberculoma (AFB + + +)
- Superadded bronchopneumonia
- Crossed fused renal ectopia
- Adenoleiomyomatous hyperplasia—prostate
- Complicated atherosclerosis—arch and descending thoracic aorta.

## SILICOSIS AND ITS SEQUELAE

Silicosis is the most prevalent chronic occupational lung disease that occurs due to inhalation of free crystalline silicon-dioxide also known as silica. Silica, i.e. $SiO_2$ is the oxidized form of silicon and it occurs either in an amorphous noncrystalline form or as a crystalline form. The histopathologic changes commonly occur postexposure, after a latent period of 25–30 years. It leads to respiratory impairment due to the occurrence of a slowly growing nodular fibrosing pneumoconiosis. This further predisposes the lung to various infections which can be catastrophic. The principal sources of industrial exposure to free silica are hard rock mining, quarrying, tunneling, metal casting work, stone cutting, polishing and cleaning monumental masonry. The crystalline form of silica is more fibrogenic and it includes quartz (most commonly implicated form in silicosis), cristobalite and tridymite. After inhalation the particles interact with epithelial cells and are phagocytosed by the macrophages. Ingested silica particles cause activation and release of mediators by pulmonary macrophages and these include interleukin-1 (IL-1), IL-18, TNF, fibronectin, lipid mediators, oxygen-derived free radicals and fibrogenic cytokines. However, when mixed with other minerals, quartz has been thought to reduce the fibrogenic effect. Pulmonary fibrosis due to silica exposure is dose-dependent and occurs after many years of exposure.

There are two main types of silicosis–(1) Acute silicosis occurs after heavy exposure to high concentrations of silica. The symptoms can develop within a few weeks or as long as 5 years after the exposure. This is characterized by the accumulation of lipoproteinaceous material within the alveo-

JAYPEE BROTHERS

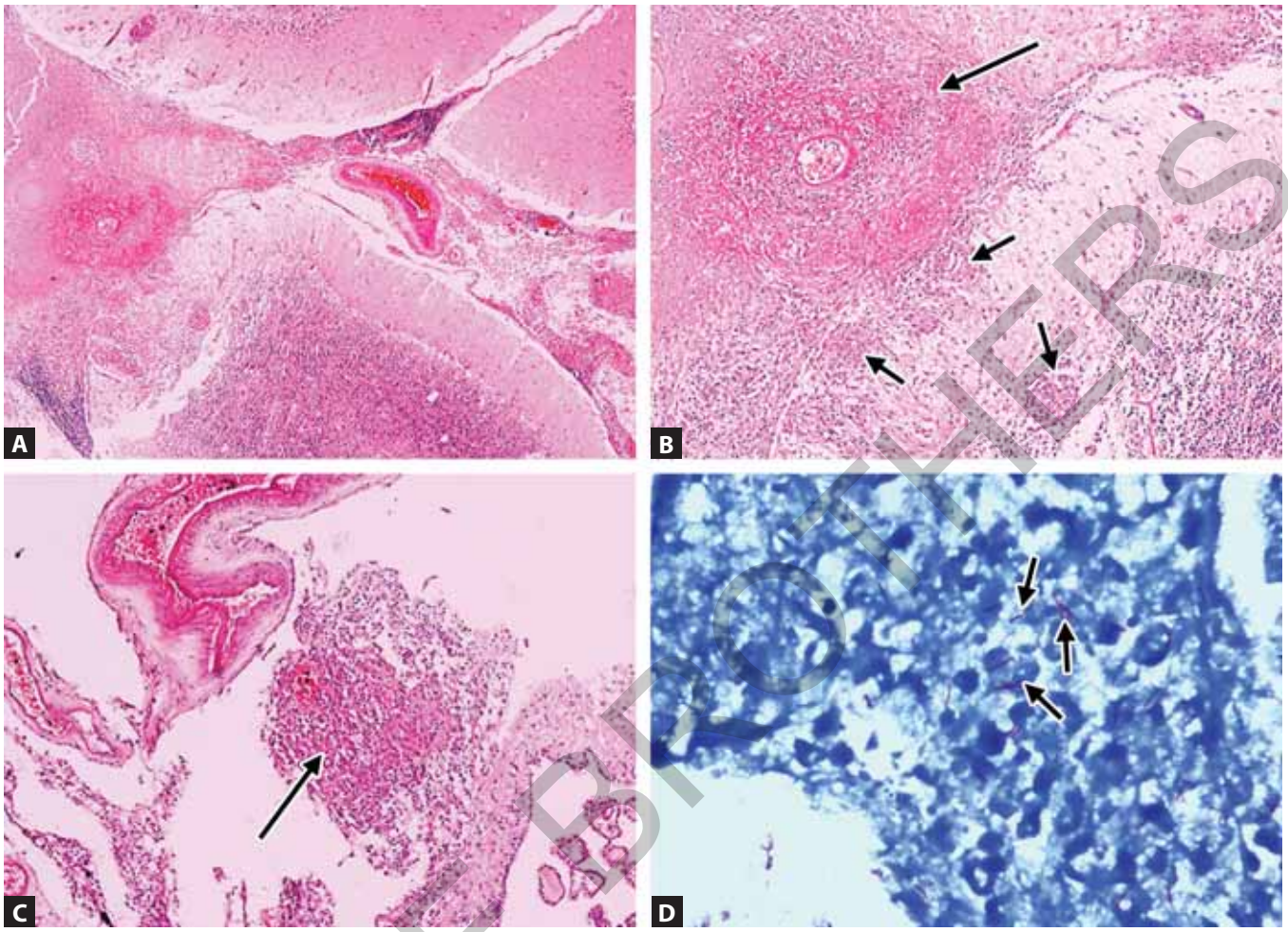


**Figs 6A–D:** (A) Florid granulomatous inflammation over the cerebellar folia; (B) Caught up vessel in the exudate showing endarteritic changes (long arrow) with granulomas in the molecular layer (small arrows); (C) Granuloma in the choroid plexus (arrow); and (D) Meningeal exudate replete with acid fast bacilli (Ziehl–Neelsen stain) (arrows).

JAYPEE BROTHERS

lar spaces, morphologically similar to alveolar proteinosis. (2) Chronic silicosis occurs after a long-term exposure of low concentrations of silica dust. This is the most common form of the disease and is often undetected after many years. A chest X-ray does not reveal the disease for as long as 20 years after exposure. This type of the disease severely hinders the ability of the lung to fight infections, making the person more susceptible to lung infections, including tuberculosis. A third hyperacute variety of silicosis, which is rare, occurs very rapidly within weeks or months after intense exposure to fine dust, high in silica. Extrathoracic silicotic lesions (in spleen, liver, bone marrow and abdominal nodes) may also be found, especially in cases with heavy and prolonged exposures. Plain chest X-rays or CT may show fine nodular infiltrates in upper zones of the lungs along with hilar/mediastinal lymphadenopathy. Five to 15% have eggshell calcification outlining the peripheral margin of mediastinal lymph nodes.

Typical microscopic picture of silicotic nodules shows dense, concentric, acellular, whorled collagen with a peripheral zone of black, dust laden macrophages. Under polarized light, fine birefringent particles are seen throughout the nodule. No giant cells or necrosis is seen. These nodules may be confused with fibrotic/collagenized healed granulomas. Examination of sections with polarized light is of limited use in this regard, because silica particles are weakly birefringent and small particles in tissue sections may be difficult or impossible to visualize. In simple silicosis, the lung parenchyma between nodules is normal or near normal. Giant cells are uncommon. With disease progression, the

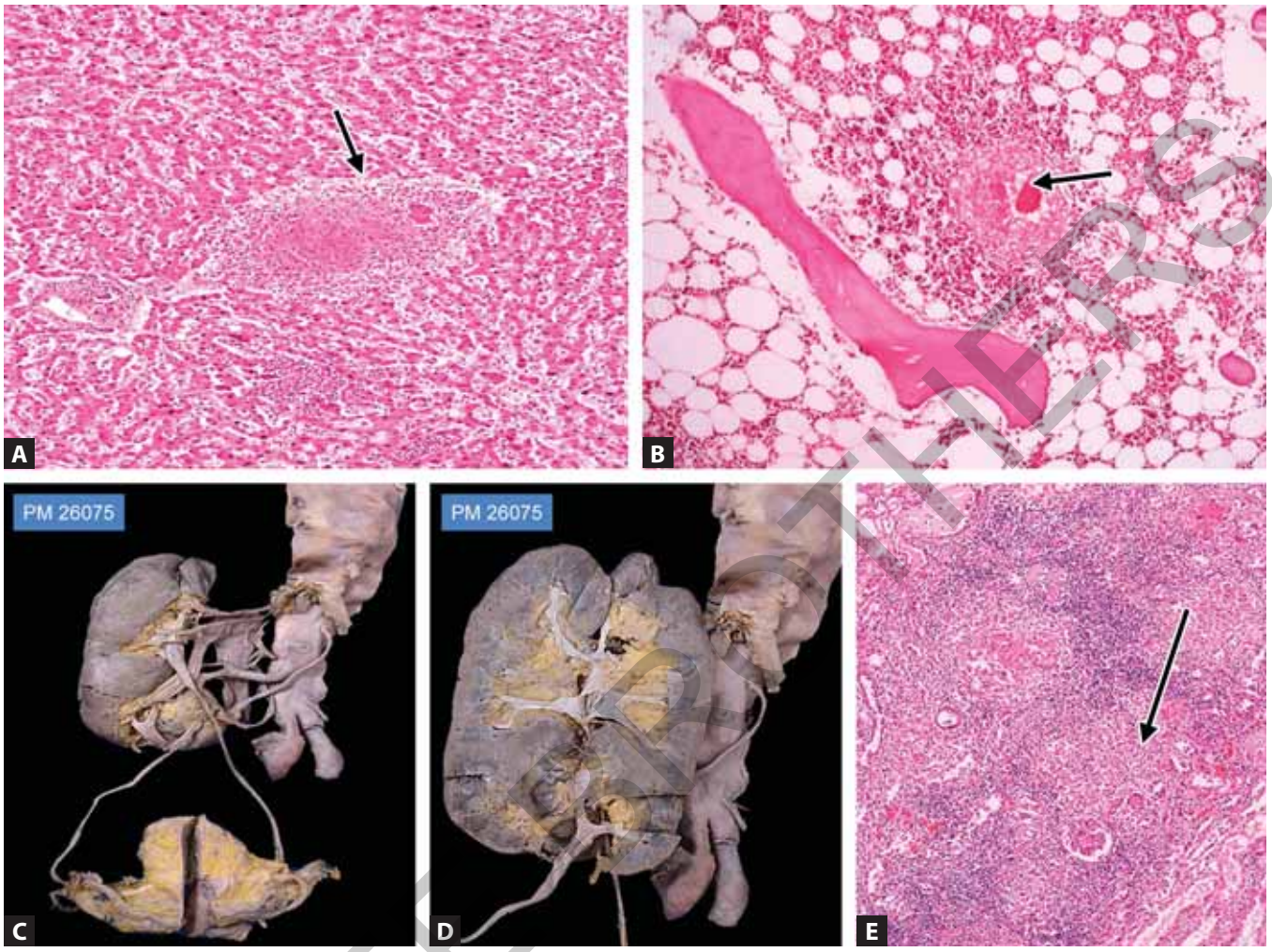


**Figs 7A–E:** (A and B) Epithelioid cell granuloma in the liver and bone marrow (arrows); (C and D) Kidneys showing crossed fused renal ectopia; and (E) Multiple epithelioid cell granulomas in the kidney (arrow).

individual nodules may coalesce into hard, collagenous scars, eventually leading to progressive fibrosis. The intervening lung parenchyma may be compressed or over expanded and a honeycomb pattern may develop. The coalescent lesions are referred to as conglomerate silicosis. Such masses may cavitate centrally as a result of ischemia, although when this occurs, superinfection chiefly caused by *Mycobacterium tuberculosis* should be suspected.

Silicosis predisposes to tubercular infection by lowering the cell-mediated immunity. The silica particles contribute by disabling the pulmonary macrophages to kill the ingested mycobacteria. Silicotuberculous nodules show central caseation necrosis. Under polarizer, brightly birefringent needle-shaped crystals about 7–15 μm are observed.

## COMMENTARY—INDEX CASE: PM 26075

An 83-year-old male, stone cutter by profession, with no previous comorbidities, presented with on and off fever and cough for 4 months with intermittent episodes of hemoptysis and altered sensorium. There was hypotension and neck rigidity. CSF analysis was suggestive of tubercular meningitis. The NCCT and CECT head were within normal limits. Chest X-ray showed fine nodular opacities in both the lungs. A clinical diagnosis of pulmonary tuberculosis with tubercular meningitis was made. In this 83-year-old male, occupational history did reveal a history of stone cutting and at autopsy there was chronic silicosis in the lungs and lymph nodes, which is the most common form of this disease. The chronic silicosis had predisposed the lung to tuberculosis,

JAYPEE BROTHERS

which showed wide spread miliary dissemination with a heavy bacillary load. The brain involvement eventually led to his demise due to tonsillar herniation. Crossed fused renal ectopia was an incidental finding.

## TAKE HOME MESSAGE

- Silicosis is the most common chronic occupational lung disease that occurs due to inhalation of proinflammatory, crystalline, silicon-dioxide also known as silica.
- Silica occurs, either in an amorphous noncrystalline form or as a crystalline form. The latter is more fibrogenic and it includes quartz (most commonly implicated in silicosis), cristobalite and tridymite.
- Ingested silica particles cause activation and release of inflammatory mediators by pulmonary macrophages particularly IL-1 and IL-18.
- Silicosis predisposes to tubercular infection by lowering the cell-mediated immunity.

## SUGGESTED READING


1. Diseases associated with exposure to silica and nonfibrous silicate minerals. Silicosis and Silicate Disease Committee. Arch Pathol Lab Med. 1988;112:673-720.
2. Gibbs AR, Wagner Jc. Diseases due to silica. In: Churg A, Green FHY (Eds). Pathology of Occupational Lung Disease, 2nd edition. Baltimore: Williams and Wilkins, 1998.
3. Heppleston AG. Pulmonary repair and fibrosis. In: Glynn LE (Ed). Tissue Repair and Regeneration. Amsterdam: Elsevier/North Holland, 1981. pp. 393-456.
4. Kleinerman J, Green F, Laquer WM, et al. Pathology standards for coal workers pneumoconiosis. Arch Pathol Lab Med. 1979;103:375-432.
5. Kleinerman J. The pathology of some familiar pneumoconiosis. Semin Roentgenol. 1967;2:244-64.
6. McDonald JW, Roggli VL. Detection of silica particles in lung tissue by polarized light microscopy. Arch Pathol Lab Med. 1995;119:242-6.
7. Slavin RE, Swedo JL, Brandes D, et al. Extrapulmonary silicosis: A clinical, morphologic and ultrastructural study. Hum Pathol. 1985;16:393-412.
8. Travis WD, Colby TV, Koss MN, Rosado-de-Christenson ML, Muller NL, King TE Jr. Non-neoplastic disorders of the lower respiratory tract. Occupational lung diseases and pneumoconioses. In: King DW (Ed). Atlas of Nontumor Pathology, First Series, Fascicle 2. Washington, DC: American Registry of Pathology, 2002.
9. Watanabe S, Shirakami A, Takeichi T, et al. Alterations in lymphocyte subsets and serum immunoglobulins in patients with silicosis. J Clin Lab Immunol. 1987;23:45-51.


## CONTRIBUTIONS BY:


1. Dr Pavithra HN, Junior Resident, Department of Pathology (In taking gross photographs)
2. Dr Sumita Bhogal, Junior Resident, Department of Internal Medicine (Compilation of Clinical Details)
3. Dr Ashish Bhalla, Professor, Department of Internal Medicine (Clinician In-Charge)

Post Graduate Institute of Medical Education and Research, Chandigarh, India.


JAYPEE BROTHERS

for detailed information on pathology books, visit our website **www.jaypeebrothers.com,** for detailed information on pathology books, visit ou

# 101 Medical Autopsy Cases
# Adult & Pediatric

In this book, the author has given a comprehensive description of 101 Medical Autopsy Cases (48 Adults and 53 Pediatrics) with their complete clinical and pathological details. Medical Autopsy is the strongest teaching tool in medicine, but unfortunately its practice has declined worldwide. In Post Graduate Institute of Medical Education and Research (PGIMER), Chandigarh, India, the Department of Histopathology performs 500–600 Medical Autopsies per year. These 101 cases have been presented in the routine Clinico-Pathologic Correlation Conferences (CPCs)/Pediatric Rounds. This book is a collection of the authors' 27 years of service in this institute. Each case is unique and has been discussed in a simple, practical, straightforward, but comprehensive manner under the following headings—Highlights, Clinical Details, Complete Histopathological Findings with a Gallery (over 3000) of Gross and Microscopic Photographs, Final Autopsy Diagnosis, Review of Literature, Discussion of Index Case with its Peculiarities, Take Home Message and Suggested Reading. The author says that this was a 'CALL BEYOND HER DUTY', to compile this immensely valuable learning material, which probably would have got deleted from her computer, once she would retire. For knowledge to live, its propagation is a must.

**Nandita Bharadwaj Kakkar** MD FICPath is Professor, Department of Histopathology, Post Graduate Institute of Medical Education and Research, Chandigarh, India. She is an eminent Surgical Pathologist and is actively engaged in postgraduate teaching. Her special interest lies in Pediatric Pathology and she is the Course Director of the countries first 'Post Doctoral certified course in Pediatric Pathology'. She has more than 180 publications in national and international journals along with chapters in books. She is the proud daughter of an Indian Army Hero, Col RK Bharadwaj, recipient of battle honor 'Sehjra'.

**Available at all medical bookstores**
**or buy online at www.jaypeebrothers.com**




**JAYPEE BROTHERS**
**Medical Publishers (P) Ltd.**
**www.jaypeebrothers.com**

Join us on facebook.com/JaypeeMedicalPublishers

Shelving Recommendation
**PATHOLOGY**

ISBN 978-93-5270-612-9

