it our website **www.jaypeebrothers.com,** for detailed information on obstetrics & gynecology books, visit our website **www.jaypeebrothers.com**

Celebrating 50 YEARS
Passion, Quality and Innovation in Healthcare Publishing

Principles and Practices of Premalignant and Malignant Disorders of Vulva

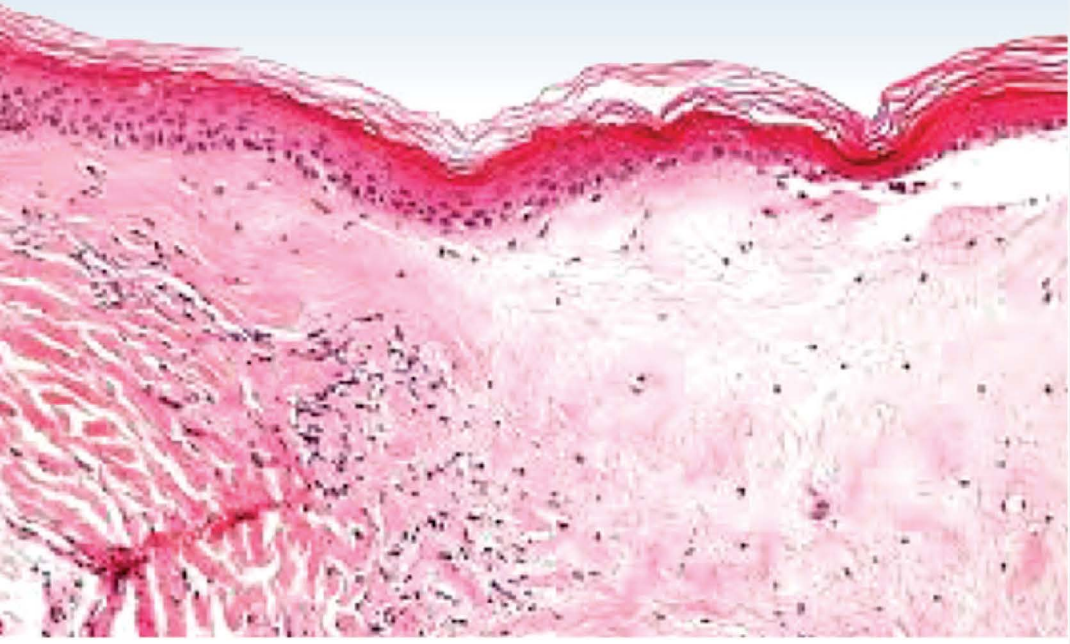

Sabera Khatun

Foreword
TA Chowdhury

JAYPEE

Contents

1. Anatomy **1**
- Mons Pubis *2*
- Labia Majora *2*
- Nerve Supply of External Genitalia *8*
- Labia Minora *9*
- Clitoris *11*
- Vestibule 13
- Bartholin's Glands *15*
- Female Urethra *16*

2. Vulvar Dystrophies **18**
- Types of Vulvar Dystrophy *18*
- Lichen Sclerosus *19*
- Squamous Cell Hyperplasia *27*
- Lichen Planus *30*

3. Non-neoplastic Inflammatory and Ulcerative Vulvar Disease **33**
- Vulvar Vestibulitis *33*
- Vulvar Psoriasis *34*
- Fox–Fordyce Disease *34*
- Crohn's Disease *34*
- Behcet Syndrome *36*
- Systemic Disease *38*

4. Vulvar Intraepithelial Neoplasia **40**
- Incidence and Etiology *40*
- Relation between Vulvar Dystrophy, VIN and Invasive Squamous Cell Carcinoma Vulva *41*
- Classification of Vulvar Intraepithelial Neoplasia 43
- Natural History of Vulvar Intraepithelial Neoplasia *44*
- Terminology for Squamous Vulvar Intraepithelial Neoplasia *45*
- Clinical Profile of Vulvar Squamous Intraepithelial Neoplasia *46*
- Paget's Disease *58*

5. Vulvar Cancer (Squamous Type) 64
- Composition of Vulva *64*
- Classification of Vulvar Cancer According to Histopathology *64*
- Incidence and Epidemiology *65*
- Etiology *65*
- Diagnostic Dilemmas *66*
- Types of Squamous Cell Carcinoma of Vulva *67*
- Staging System *72*
- Predicting Lymph Node Metastasis *72*
- Treatment *75*
- Advanced Stage Disease *87*
- Role of Radiation Therapy in Vulvar Cancer *94*
- Recurrent Vulvar Cancer 98
- Verrucous Carcinoma *101*

6. Nonsquamous Type of Vulvar Cancer 105
- Vulvar Malignant Melanoma *105*
- Bartholin's Gland Carcinoma *110*
- Basal Cell Carcinoma *112*
- Paget's Disease and Other Vulvar Adenocarcinomas *113*
- Unusual Varieties of Vulvar Malignancy *115*
- Metastatic Tumors of the Vulva *116*

Index *119*

CHAPTER 4

Vulvar Intraepithelial Neoplasia

JAYPEE BROTHERS

INTRODUCTION

Vulvar intraepithelial neoplasia (VIN) is an increasingly common problem, particularly among women in their 40s. Like cervical intraepithelial neoplasia (CIN), premalignant condition of vulva is called vulvar intraepithelial neoplasia.

Vulvar skin is one of the components of anogenital epithelium. The lower genital tract epithelium is of common cloacogenic origin. Neoplasia of vulvar skin is often associated with multiple foci of dysplasia in the lower genital tract.

Vulvar intraepithelial neoplasia is defined as dysplastic changes in the vulvar squamous epithelium characterized by the presence of immature cells, cellular disorganization and increased mitotic activity as in CIN changes of the cervix and vaginal intraepithelial neoplasia (VAIN) changes of the vagina.

INCIDENCE AND ETIOLOGY

Since 1970s, marked increase in incidence of high-grade VIN and a decrease in modal age of diagnosis has been observed. Surveillance, Epidemiology and End Results (SEER) data from the United States have shown a four-fold increase in diagnosis of VIN between 1973 and 2000.[1] However, the incidence of vulvar carcinoma has remained relatively constant presumably because the preinvasive disease is actively treated.

Although 85% of high grade VIN lesions are human papilloma virus associated, human papillomavirus (HPV) DNA is detected only in approximately 40% of vulvar cancers. Many of the HPV negative cancers, particularly in older women are associated with lichen sclerosus.[2] HPV type 16 is commonly associated with VIN. 50% VIN is associated with CIN or VAIN and 20–30% is associated with invasive squamous cell carcinoma of vulva. The risk of malignant transformation of VIN is 3–12%. It takes less than 8 years to change to invasive cancer.

A strong association exists between sexually transmitted disease and high grade of VIN particularly VIN-3. Primarily HPV, but also gonorrhea, syphilis, gardnerella vaginalis, trichomoniasis are associated with VIN which rates varying from 20% to 60%. Other risk factors include smoking, immunosuppressive disease, radiation therapy, pregnancy and other genital precancers and cancers. VIN can be viral or nonviral etiology. Young women are more commonly affected by viral VIN than older women and also are more likely to exhibit multifocal disease. In older women, the lesion is usually unifocal and arises de novo.

RELATION BETWEEN VULVAR DYSTROPHY, VIN AND INVASIVE SQUAMOUS CELL CARCINOMA VULVA

Vulvar intraepithelial neoplasia has traditionally been considered to be premalignant condition, and to be one disease, but in 2004, the International Society for the Study of Vulvovaginal Disease (ISSVD) officially divided VIN in to two types: (1) usual type VIN, which is related to HPV infection, and (2) differentiated type VIN, which is unrelated to HPV infection (Box 4.1).[3] The term VIN I is no longer used, and VIN 2 and VIN 3 are simply called VIN.

The older classification of VIN 1, 2, and 3 was based on the degree of histologic abnormality, but there is no evidence that the VIN 1 to 3 morphologic spectrum reflects a biologic continuum, or that VIN 1 is a cancer precursor.[3]

It is now generally accepted that there are two different etiologic types of vulvar cancer. One type is seen mainly in younger patients, is related to HPV infection and smoking, and is commonly associated

JAYPEE BROTHERS

BOX 4.1: Squamous vulvar intraepithelial neoplasia (VIN) [2004 International Society for the Study of Vulvar Disease (ISSVD) Terminology].

I. VIN, usual type
   a. VIN, warty type
   b. VIN, basaloid type
   c. VIN, mixed (warty/basaloid) type
II. VIN, differentiated type

Source: Reproduced with permission from Sideri M, Jones RW, Wilkinson EJ, et al. Squamous vulvar intraepithelial neoplasia: 2004 modified terminology, ISSVD Vulvar Oncology Subcommittee. J Reprod Med. 2005;50:807-10.

with basaloid or warty VIN. The more common type is seen mainly in elderly patients, is unrelated to smoking or HPV infection, and concurrent VIN is uncommon. There is, however, a high incidence of dystrophic lesions, including lichen sclerosus and squamous hyperplasia, adjacent to the tumor. If VIN is present, it is of the differentiated type.

Using data on 2,685 patients with invasive vulvar cancer from the National Cancer Institute's Surveillance Epidemiology and End Results program (SEER), Sturgeon et al. reported the increased risk of a subsequent cancer to be 1.3-fold. Most of the second cancers were related to smoking (i.e. cancers of the lung, buccal cavity, pharynx, nasal cavity, or larynx) or to infection with human papillomavirus (e.g. cervix vagina, or anus).[4]

In a study designed to investigate the malignant potential of the vulvar premalignant conditions, Eva et al. identified 580 women from Birmingham, England, who had vulvar biopsies showing VIN, lichen sclerosus, or squamous hyperplasia over a 5-year period.[5] These women were studied for the presence of a synchronous of metachronous vulvar cancer. The authors reported that differentiated VIN had a higher risk of malignancy (85.7%) than usual VIN (25.8%), lichen sclerosus (27.7%) or squamous hyperplasia (31.7%).

Dutch workers between 1992 and 2005 in their prospective study, found that the malignant potential of premalignant conditions to be much lower 5.7% for usual VIN, 32% for differential VIN, and 2–6% for lichen sclerous.[6]

Patients with lichen sclerosus and concomitant hyperplasia may be at risk for malignant transformation. Rodke et al. reported

JAYPEE BROTHERS

development of vulvar carcinoma in 3 of 18 such cases (17%), postulating that areas of hyperplasia were superimposed on a background of lichen sclerosus because of chronic irritation and trauma.[7]

Carli et al. from the vulvar clinic at the University of Florence, Italy, reported an association with lichen sclerosus in 32% of their cases of vulvar cancer that were not HPV related.[8] They felt that the existence of accessory conditions necessary to promote the progression from lichen sclerosus to cancer remained to be established. Scurry believes lichen sclerosus contributes to a vicious cycle of itching and scratching, which leads to superimposed lichen simplex chronicus, squamous cell hyperplasia, and ultimately carcinoma.[9]

CLASSIFICATION OF VULVAR INTRAEPITHELIAL NEOPLASIA

Traditionally, squamous vulvar intraepithelial neoplasia was classified into three grades, analogous to the three-grade CIN classification. Preinvasive neoplasia of the vulva has been recognized for more than 75 years, but the descriptive terminology has been confusing. The degree of loss of epithelial cellular maturation in a given lesion defines the grade of VIN. Histologically VIN has been graded as:

- VIN I or mild dysplasia where dysplastic changes are found in lower one-third of the vulvar epithelium.
- VIN II or moderate dysplasia where dysplastic cells are found in lower two-thirds of the vulvar epithelium.
- VIN III or severe dysplasia where dysplastic cells are found in more than lower two-thirds of the vulvar epithelium.

When whole thickness epithelium is involved by dysplastic changes it is called vulvar carcinoma in situ (CIS). Microscopically essential features of vulvar CIS is the absence of penetration of basement membrane. Vulvar CIS has been described as Bowen's disease, erythroplasia of Queyrat, CIS simplex, Bowenoid papulosis or kraurosis vulvae and leukoplakia. Bowen's disease is applied to some cases of VIN when large Bowen's cells, sometimes corp rords appear in the malignant cell. Bowen's cells are large cells with perinuclear vacuolation and nuclear fragmentation. It is usually found in association with HPV infection.

JAYPEE BROTHERS

Current Classification of VIN

Subsequent studies determined that VIN 1 reflects usually a self-limited infection caused by human papillomavirus (HPV). In 2004, the ISSVD replaced the previous three-grade classification system with the current single-grade system, in which only high-grade disease is classified as VIN.[10] In the current system, VIN is subdivided into usual-type VIN (including warty, basaloid, and mixed VIN) and differentiated VIN. Usual-type VIN is commonly associated with carcinogenic genotypes of HPV and other HPV persistence risk factors, such as cigarette smoking and immunocompromised status, whereas differentiated VIN usually is not associated with HPV and is more often associated with vulvar dermatologic conditions, such as lichen sclerosus. However, differentiated VIN associated with lichen sclerosus is more likely to be associated with a squamous cell carcinoma of the vulva than usual-type VIN.

Flat lesions associated with basal atypia and koilocytic changes (formerly termed VIN 1) are considered condylomas in the current ISSVD classification system and can be treated as such.[10] Other intraepithelial vulvar neoplasms, such as Paget's disease and melanoma in situ, are rare.

NATURAL HISTORY OF VULVAR INTRAEPITHELIAL NEOPLASIA

There is some basis for establishing a biological continuum from CIN I to CIN III. But the neoplastic biologic continuum from VIN I through VIN III to invasive cancer had not been established.

Although the progression rate of VIN III to invasive cancer remains controversial, the malignant potential has been established. By contrast, there is no direct evidence that VIN I has any malignant potential.

There is compelling argument for excluding low-grade VIN from the "intraepithelial neoplasia" category.[11] When mild squamous atypia is seen in vulvar skin, usually limited to lower epidermis, the lesion is more likely to be non-neoplastic reactive atypia. Considerable interobserver and intraobserver variation occurs with the VIN I diagnosis and this diagnostic category is not reproducible.[10]

JAYPEE BROTHERS

Most histologic VIN lesions are categorized as VIN 2–3 and good histologic agreement is obtained when VIN-II and VIN-III are combined as a single high-grade VIN diagnose.[10] Only 10–15% of VIN is not associated with any coexistent disease. It coexists with invasive lesion in 30–50% of cases. Lichen sclerosus and hypertrophic type vulvar dystrophy occurs in 50% of the specimen. One report made by Jones and Rowan from New Zealand in 1994 on follow-up of 113 women with VIN III diagnosed between 1961 and 1993. Among eight untreated cases of VIN III, there was progression to invasive cancer in seven patients (87%) within 8 years. This risk may be as high as 100% for women over 40. Another recent study from New Zealand reported spontaneous regression of VIN II-III.[12] These women were young (medical age 24 years) with sexually transmitted disease. Most had multifocal pigmented lesion and median time to regression was 9.5 months.

TERMINOLOGY FOR SQUAMOUS VULVAR INTRAEPITHELIAL NEOPLASIA

In 2004, the ISSVD recommended the following modifications to the terminology for squamous vulvar intraepithelial neoplasia.[10]

1. The VIN I should no longer be used, being replaced with the terms flat condyloma acuminatum or HPV effect. The term "atypia" in this context is discouraged.
2. The term VIN should apply to histologic high-grade squamous intraepithelial lesions (VIN 2–3).
3. Two categories of VIN were described:
   a. The more common VIN, usual type, which enocompasses VIN 2, VIN 3, and the older clinical and histologic terms: Bowen's disease, bowenoid papulosis, dysplasia, and CIS. These lesions are associated with high-risk HPV types, particularly HPV 16. VIN, usual type, has been subcategorized histologically as warty (condylomatous), basaloid, or mixed.
   b. The less-common VIN, differentiated type. These lesions are not associated with HPV, but frequently occur against a background of a dermatosus, particularly lichen sclerosus.
4. The occasional VIN lesion that cannot be classified as VIN, usual or differentiated types is termed VIN, unclassified type (or VIN, NOS). (This includes the rare pagetoid VIN).

JAYPEE BROTHERS

BOX 4.2: International Society for the Study of Vulvar Disease (ISSVD) classification of vulvar diseases.

1. *Non-neoplastic epithelial disorders of skin and mucosa of vulva*
   - Lichen sclerosus (formerly lichen sclerosus et atrophicus)
   - Squmous hyperplasia (formerly hyperplastic dystrophy)
   - Other dermatoses (e.g. psoriasis)
2. *Intraepithelial neoplasia*
   - Squamous intraepithelial neoplasia
     - VIN, usual type
       - VIN, warty type
       - VIN, basaloid type
       - VIN, mixes (warty/basaloid) type
     - VIN, differentiated type
   - Nonsquamous intraepithelial neoplasia
     - Paget's disease
     - Tumors of the melanocytes, noninvasive (melanoma in situ)
3. Mixed non-neoplastic and neoplastic epithelial disorders
4. Invasive tumors

(VIN: Vulvar intraepithelial neoplasia)
Source: International Society for the Study of Vulvar Disease (Committee on Terminology, 2004).

5. Classification is on the basis of histologic morphology only, and clinical appearance or HPV type. The 2004 ISSVD classification of VIN is shown in Box 4.2.

CLINICAL PROFILE OF VULVAR SQUAMOUS INTRAEPITHELIAL NEOPLASIA

The increasing incidence of VIN 3 in recent decades reflects increased clinical awareness, improved diagnostic accuracy and an absolute increase in disease incidence. Symptom distribution of VIN lesion in younger and older women is variable. The lesion is commonly localized and unifocal in older patients, which is usually not associated with HPV infection. Malignant potential in these women are higher, because invasive vulvar cancer occurs in older age group.

In younger, the lesion tends to be multifocal and extensive. The size of the lesion varies from several mm to large confluent lesion involving the whole vulva. It may remain as small discrete lesion or multiple lesion coalesce to develop a large lesion.

Common sites involved are non-hair bearing areas of the vulva extending laterally from labia majora to the hair-bearing skin of the

JAYPEE BROTHERS

labia majora and anteroposteriorly from mons pubis to posterior fourchette, perineum and perianal skin.

Appearance of the VIN lesions vary in color from white to black, red, gray or brown depending on the age, race and complexion of the patient.

White Lesion

The lesion may be raised, papular or flat macular type. Usually papular lesion occurs at the keratinized skin and flat macular lesion occurs at the mucosal surface. Macular lesions are subclinical and are detected on colposcopic examination after application of 5% acetic acid solution.

White lesions occur as a result of hyperkeratosis or dehydration of the outer keratinized layer. Red lesion results from increased vascularity, secondary to inflammatory response or due to angiogenetic factors of neoplasia. Brown or pigmented lesion result from pigmented melanin deposition (Figs. 4.1 to 4.3).

Symptoms

Majority are asymptomatic, only 30% with VIN III experience some vulvar symptoms, mostly pruritus, vulvar irritation and burning, pain and dysuria. The symptoms are exacerbated by voiding. Other complains may be:

- Localized lump or swelling
- Thickening of vulvar skin
- Area of altered pigmentation

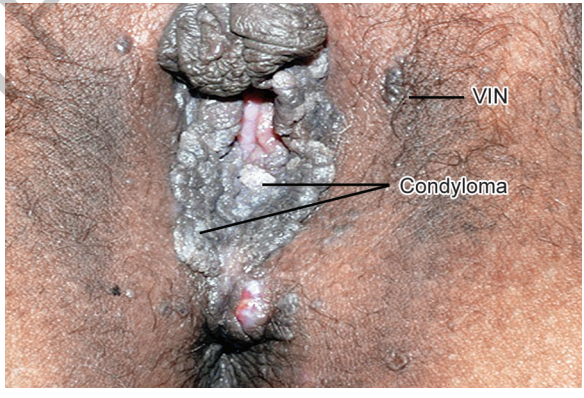

Fig. 4.1: Patient with multiple condyloma and vulvar intraepithelial neoplasia (VIN).

JAYPEE BROTHERS



Fig. 4.2: Hyperpigmented vulvar intraepithelial neoplasia (VIN)—usual type.

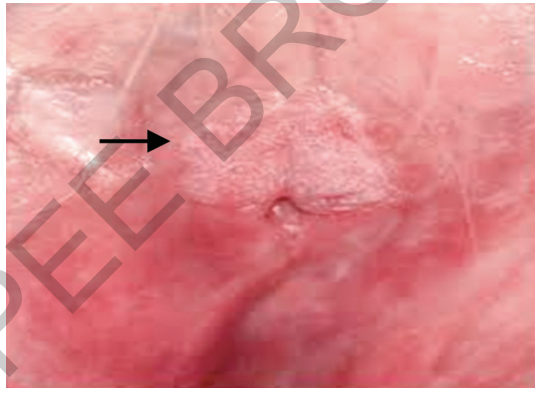

Fig. 4.3: Vulvar intraepithelial neoplasia showing warty growth.

- Change in color
- Dyspareunia
- Difficulty in voiding stool.

Microscopic Appearance

The microscopic appearance of vulvar squamous intraepithelial lesion is characterized by:

- Cellular disorganization
- Loss of stratification

JAYPEE BROTHERS

- Increased cellular density
- Great variation in cell size
- Presence of giant multinucleated cell
- Hypercromatism
- HPV-related cytopathy such as perinuclear halos with displacement of nucleus are also common. Essential feature is the absence of penetration of basement membrane (Fig. 4.4).

Diagnosis

Vulvar intraepithelial neoplasia is a multifocal disease, especially in young women, when it is caused by HPV infection. Possibly 1–2% of young women with cervical dysplasia will be found to have involve the upper third of the vagina and the vulva, perineum and perianal area as these surfaces arise from a common cloacogenic origin. A spectrum of diseases ranging from mild dysplasia to carcinoma in situ may be found in the same lesion.

No screening strategies have been developed for the prevention of vulvar cancer through early detection of VIN. Vulvar cytological testing is complicated by the keratinization of vulvar skin, making performance and interpretation of test results problematic. Diagnosis is limited to visual assessment. Clinically VIN lesion is quite variable. Most women have visible lesions that are elevated, but flat lesions occur. Color can vary from white to gray or from red to brown to black. So, carefully naked eye inspection of the lesion is mandatory.

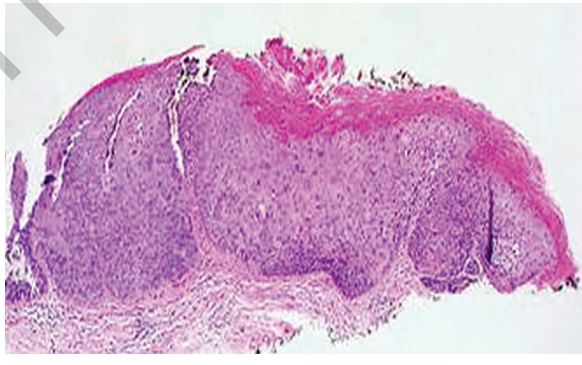

Fig. 4.4: Microscopic appearance of vulvar squamous intraepithelial lesion—absence of penetration of basement membrane.

JAYPEE BROTHERS

Biopsy is indicated for any pigmented vulvar lesion. Expert opinion is derived regarding the need for biopsy of all warty lesions, but biopsy should be performed in postmenopausal women with apparent genital warts and in women in whom topical therapies have failed.

Colposcopic evaluation in higher magnification (6–7 times) with or without green filter may be helpful. An abnormal vascular pattern is most frequently associated with a severe degree of dysplasia, carcinoma in situ or early invasive disease. Nowadays colposcopy is an accepted standard procedure in the diagnostic assessment of VIN. Colposcopic examination, diagnosis of abnormal area and biopsy of any suspicious lesion is the gold standard for diagnosis of VIN. Although toluidine blue testing is often cited for use in the assessment of VIN, this method is infrequently used and rarely beneficial in the diagnosis of VIN.

Colposcopic Procedure

After application of 5% acetic acid solution and colposcopic assessment, lesions appear as clearly demarcated, dense acetowhite areas. The multifocal distribution is usually evident. The acetic acid reaction is seen in lesions that are nonpigmented or red. Pigmented lesions often develop an acetowhite hue or a rim of acetowhitening. Initial clinical examination may identify clinically apparent lesions. Colposcopy may permit identification of previously unidentified, subclinical lesions and better define the distribution of clinically evident disease.

In high-grade vulvar preinvasive lesions, vascular patterns are often inconspicuous or absent, particularly in the presence of hyperkeratosis. Macular lesions on the mucous membranes may reveal a capillary punctuation pattern, and a fine punctuation is sometimes observed in papular lesions. Marked vascular abnormalities characterized by a varicose, widely spaced punctuation and rarely, mosaicism represent a definite warning sign of invasive cancer and the lesion must be excised. Colposcopic warning signs of vulvar cancer occur late in the neoplastic process. Histologic evidence of VIN may be seen outside colposcopically identified margins of disease, particularly laterally in the hair-bearing areas.

JAYPEE BROTHERS

Diagnosis ultimately depends on liberal use of directed biopsy. This is particularly the case if ablative treatment is being considered either alone or in combination with excisional procedures. *Biopsies are best taken with a Keyes biopsy instrument* under local anesthesia in the office setting.

Prevention

Immunization with the quadrivalent HPV vaccine, which is effective against HPV genotypes 6, 11, 16, and 18, has been shown to decrease the risk of VIN and should be recommended for women in target populations. The bivalent HPV vaccine is not approved for this indication, because this endpoint was not assessed in clinical trials. Cigarette smoking is strongly associated with usual-type VIN, and cessation should be encouraged, although no studies have shown a reduction in VIN incidence or post-treatment recurrence after smoking-cessation efforts. Differentiated VIN may be associated with vulvar dermatoses, and treatment of vulvar dermatologic disorders may reduce VIN and cancer risk.

Treatment

Treatment is recommended for all women with VIN. But in younger patients spontaneous regression may occur. So, there are some indications for observation for 6–12 months. Indications for observation are:

- When the patient is young with mild dysplasia and good compliance,
- Patients who have recently completed a course of corticosteroid therapy,
- Patients who were recently pregnant or were temporarily immunocompromised. These patients should be reviewed at every 3–6 months and if the disease is persistent or worse, then her treatment is indicated.

Aim of treatment of VIN:

- To give symptomatic relief.
- To rule out associated CIN, VAIN and invasive cancer of vulva.
- To rule out associated sexually transmitted disease.

JAYPEE BROTHERS

for detailed information on obstetrics & gynecology books, visit our website **www.jaypeebrothers.com,** for detailed information on obstetrics & gyn

Principles and Practices of Premalignant and Malignant Disorders of Vulva

Salient Features

- Overview of entire theoretical and practical aspects of vulvar disorders
- Contains all essential topics in 6 chapters. First chapter contains anatomy of vulva; Second and third chapters describe vulvar dystrophies and non-neoplastic and ulcerative disorders of vulva; Fourth chapter explains premalignant conditions of vulva; Fifth and sixth chapters contain malignant conditions of vulva
- Every disease is described according to the protocol of introduction followed by clinical features, complications, diagnosis, and treatment
- Describes all premalignant and malignant disorders of vulva elaborately
- Supplemented with relevant figures, tables, and boxes
- Useful for undergraduate students, postgraduate students, practicing general gynecologists, and gynecological oncologists and also helpful for pathologists and venereologists.

Sabera Khatun MBBS FCPS (Obs & Gynae) Fellow (Gynecologic Oncology) is the Chairman, Department of Gynecological Oncology, Bangabandhu Sheikh Mujib Medical University, Dhaka, Bangladesh. She completed her MBBS in 1979, and obtained her postgraduation (FCPS) degree (1992) in Obstetrics and Gynecology from the Bangladesh College of Physicians and Surgeons (BCPS). After the completion of her postgraduation, she worked as the Senior Consultant, Khulna Medical College Hospital, Khulna for 2 years. Then she joined as the Assistant Professor (Obstetrics and Gynecology), Bangabandhu Sheikh Mujib Medical University. She has been promoted to Associate Professor in 2001 and Professor of Gynecological Oncology in 2006. She has introduced FCPS course in Gynecological Oncology (2013) and MS Residency in this subject since 2015.

She has obtained Young Gynecologist's Award (1998) by the Asia & Oceania Federation of Obstetrics and Gynaecology (AOFOG), FIGO Gynaecological Oncology Fellowship Award (2009), and IGCS Traveling Scholarship (2002). She has written a book on *Practice Guidebook for Prevention and Management of Preinvasive Cervical Cancer*. She has attended more than 100 conferences, workshop, and training at home and abroad. She has founded a Society of Gynaecological Oncologists of Bangladesh named Gynaecological Oncology Society of Bangladesh (GOSB). She is the Secretary General of GOSB. She has introduced "CERVARIX" in Bangladesh (2008). She has written more than 40 research papers in different national and international journals.

Available at all medical bookstores
or buy online at www.jaypeebrothers.com



JAYPEE BROTHERS
Medical Publishers (P) Ltd.
www.jaypeebrothers.com

Join us on facebook.com/JaypeeMedicalPublishers

Shelving Recommendation
OBSTETRICS & GYNECOLOGY

ISBN 978-93-5270-613-6

