ypeebrothers.com, for detailed information on cardiology books, visit our website www.jaypeebrothers.com, for detailed information on cardiology books, visit our website www.jaypeebrothers.com

Get Full Access
with added features at
emedicine360.com

Celebrating 50
Passion, Quality and Innovation in Healthcare Publishing

Advances in Clinical Cardiovascular Imaging Echocardiography & Interventions (ACCI-EI)

A Textbook of Cardiology

Editors-in-Chief

HK Chopra (India) • Navin C Nanda (USA) • Jagat Narula (USA)



JAYPEE

Contents

SECTION 1: BASICS

1. **Basics of Cardiac Computed Tomography** 3
   Priya Jagia, Kartik Ganga, Arun Sharma
2. **Basics of Cardiac Magnetic Resonance Imaging** 10
   Johann Christopher
3. **New Cardiac Cameras: Single-photon Emission Computed Tomography and Positron Emission Tomography** 17
   PS Soni

SECTION 2: HYPERTENSION

4. **Left Ventricular Hypertrophy Evaluation by Echocardiography in Hypertension** 27
   Atul Karande, Manish Bansal, R Hotchandani
5. **Left Atrial Volume Index Evaluation by Echocardiography in Hypertension** 35
   Rohit Tandon, Gurpreet Singh Wander, HK Chopra
6. **Advances in Diastology by Echocardiography in Hypertension** 40
   Aniruddha De
7. **Advances in Left Atrial Strain Evaluation by Echocardiography in Hypertension** 49
   KK Kapur, Naveen Garg
8. **Sequential ABPM Navigation Imaging in Hypertension** 58
   AK Pancholia, HK Chopra
9. **Echocardiographic Evaluation in Hypertension: Diagnostic, Prognostic, and Therapeutic Implications** 63
   Manish Bansal, HK Chopra, C Venkata S Ram, Anil Pareek
10. **Beta-blocker Effect and Outcome Evaluation by Echocardiography in Hypertension** 72
    Jamshed J Dalal, Vijay Katekhaye
11. **Statin Effect and Outcome Evaluation by Echocardiography** 78
    Rahul Mehrotra, Bharat Bansal
12. **ARNIs Effect and Outcome Evaluation by Echocardiography in Hypertension** 81
    Sandeep Bansal, Preeti Gupta, Ankit Singh
13. **Left Ventricular Hypertrophy and Left Ventricular Mass Index Evaluation by 3D Echocardiography in Hypertension** 89
    Mohamed Faher Almahmoud, Masood Ahmad
14. **Validation of Chlorthalidone Efficacy and Outcome by Echocardiographic Variables** 98
    Harsh Wardhan, Nitin Aggarwal
15. **Secondary Hypertension Evaluation: Multimodality Imaging** 105
    Simran Kaur, Rohin Vinayak, Ravina Sharma, Gurpreet Singh Wander

SECTION 3: HEART FAILURE

16. **Biomarkers Imaging in Heart Failure** 113
    Bhargava Mohan, Abhinav Jain, Bhargava Prachal
17. **Advances in Systolic Heart Failure Evaluation by Echocardiography** 120
    Rohit Tandon, Mridul Mahanta, Gulshan Rai
18. **Cardiac Magnetic Resonance Imaging in Ischemic Heart Failure** 127
    Mona Bhatia, Khemendra Kumar

19. **Role of Cardiovascular Magnetic Resonance Imaging in Nonischemic Cardiomyopathy** 135
Mona Bhatia, Amit Garg, Rahul Nijhara, Shashank Jain

20. **Echocardiography-guided β-blocker Therapy in Heart Failure** 144
Kushagra Mahansaria, Manish Bansal, Ravi R Kasliwal, HK Chopra

21. **Diuretics Effect and Outcome Evaluation in Heart Failure by Echocardiography** 154
Saumitra Ray, Rajat Subhra Ghose

22. **Device Intervention in Heart Failure** 161
Raghav Bansal, Viveka Kumar

23. **Radionuclide Imaging of Cardiac Autonomic Innervation: MIBG** 167
Pawan K Sharma, HK Chopra, AK Bali

24. **Cardiac Radionuclide Imaging to Assess Patients with Heart Failure** 174
GN Mahapatra

SECTION 4: ST-ELEVATION MYOCARDIAL INFARCTION AND CORONARY ARTERY DISEASE

25. **Biomarkers Imaging in ST-elevation Myocardial Infarction** 187
Ajay Kumar Sinha, Sanjeev Kumar, Vikas Singh

26. **Electrocardiography Imaging in ST-elevation Myocardial Infarction** 194
Apoorv Mittal, HK Chopra, V Anand, Manish Gaba

27. **Advances in Echocardiographic Navigation of STEMI Complications** 203
Santanu Guha, Somnath Mukhopadhyay, Avik Karak

28. **Coronary Artery Disease and Advances in Intravascular Ultrasound Imaging** 208
Satyavan Sharma, Nikhil Raut

29. **Vulnerable Plaque Imaging in Acute Coronary Syndrome: When to Intervene?** 215
Sundeep Mishra

30. **ST-elevation Myocardial Infarction and Advances in Optical Coherence Tomography** 223
Raghav Bansal, Viveka Kumar

31. **Role of OCT in the Subset of CAD Postpercutaneous Coronary Intervention and Postcoronary Artery Bypass Graft** 229
Binoy John

32. **Acute Coronary Syndrome: Bifurcation Lesion, Imaging, and Intervention Advances** 235
Ravi Prakash, Viveka Kumar, Sunil Aggarwal

33. **Quantitative Assessment of Myocardial Blood Flow and Fractional Flow Reserve and their Clinical Applications** 240
Ashwani Sood, Tinu T Lukose, Bhagwant R Mittal

34. **ACS Coronary Intervention and Imaging: Recent Advances—Optical Coherence Tomography** 247
Rony Mathew, Jo Joseph, Jabir A, Jimmy George

35. **Advances in CT Coronary Angiography in Evaluation of CAD** 255
Harsh Mahajan, Suman Singhal, Puneet Sethi

36. **TNK Effect and Outcome Evaluation in STEMI by Echocardiography** 264
SS Iyengar, Rajiv Ananthakrishna, Nagaraja Moorthy

37. **Prognosis and Risk Outcome by Echocardiography in AMI Patients Post-thrombolysis** 271
Rohit Tandon, Harshit Gupta, Mohammed Nazir, Devinder Mahal, Bishav Mohan

38. **TNK Effect and Outcome Evaluation in STEMI by Coronary Angiography** 278
KN Srinivasan, I Sathyamurthy

39. **Thrombolytic Therapy Effect/Outcome Evaluation by Intravascular Ultrasound** 283
K Venugopal

40. **Role of Myocardial Perfusion Imaging in Patients of Chronic Stable Angina** 288
E Prabhu, S Santhosh

41. STEMI Intervention: Femoral versus Radial by Conventional Coronary Angiography 296
Brian Pinto, Neeraj A Desai, Ankeet Dedhia

42. ARBs, ACEIs Effect and Outcome Evaluation in STEMI by Echocardiography 300
PB Jayagopal, SKM Sarjun Basha

43. Beta Blockers Effect and Outcome Evaluation in STEMI by Echocardiography 303
Arnab Banerjee, Debabrata Roy

44. Post-PCI Effect and Evaluation in STEMI by Echocardiography 309
Ankush Sachdeva, Sameer Shrivastava

45. Coronary Artery Disease Evaluation by Coronary Doppler Imaging 315
Anjaneyulu V Anne

46. Dobutamine Stress Echocardiography in Assessment of Myocardial Viability 322
CK Ponde, Pranav A Oza

47. Assessment of Myocardial Viability: Advantages and Pitfalls of Various Modalities 328
Mythri Shankar

48. Small Vessel Coronary Artery Disease 332
Sayeed Raheem, Upendra Kaul

SECTION 5: ADVANCES IN ECHOCARDIOGRAPHY: CLINICAL IMPLICATIONS

49. Three-dimensional Echocardiography: Diagnostic, Prognostic, and Therapeutic Implications 343
Aiman M Smer, Navin C Nanda, Ahmed Y Salama, Raziye E Akdogan, Hanan Fadala, HK Chopra

50. TEE: Overview, Diagnostic, Prognostic and Therapeutic Implications 351
Kaustubh Mahamine, CK Ponde

SECTION 6: EMERGENCY IMAGING IN CHEST PAIN

51. Emergency Imaging in Chest Pain: Echocardiographic Evaluation 367
BP Singh, Ravi Vishnu Prasad

52. Chest Pain: Emergency Echocardiographic Evaluation 373
Debika Chatterjee

53. Imaging in Chest Pain: Computed Tomography Coronary Angiography Evaluation 378
Nidhi Goyal, Parveen Gulati, Arif Mirza, Aishwarya Gulati

54. Radionuclide Imaging in Patients with Acute Chest Pain 399
Uma Ravishankar, Arjun Ravishankar

55. Cardiovascular Imaging in Emergency Department in Patients of Chest Pain 407
Satyendra Tewari, Roopali Khanna, Nikunj Kotecha

SECTION: VALVULAR HEART DISEASE

56. Advances in Echocardiographic Evaluation of Mitral Stenosis 417
Rakesh Gupta, N Chidambaram, SKD Bhardwaj, Sunil Mangla

57. Echocardiographic Advances in the Diagnosis of Mitral Regurgitation 420
Rakesh Gupta, N Chidabaram, SKD Bhardwaj, Sunil Mangla

58. Echocardiography in Aortic Stenosis 427
R Alagesan, Satish Govind

59. Advances in Echocardiographic Evaluation of Aortic Regurgitation 439
Simmi Manocha, Kumar Hrishikesh, Prateek Bajaj

60. Transcatheter Aortic Valve Replacement Imaging Evaluation: Status 2018 446
R Keshava, Satish Govind

61. Transcatheter Mitral Valve Interventions Imaging Evaluation: Potentials and Tips 453
S Venkatesh, Satish Govind

62. **Three-dimensional/Four-dimensional Echocardiography: Recent Advances in the Evaluation of Mitral Valve** 463
V Amuthan, RVA Ananth, AB Gopalamurugan

63. **Mitral Clipping Evaluation by Echocardiography** 479
Ahmed K Pasha, Rajesh Janardhanan

64. **Evaluation of Tricuspid Valve Regurgitation and Stenosis: Advances in Echocardiography** 483
Vinay Sharma, Sameer Shrivastava, HK Chopra

65. **Advances in Echocardiographic Assessment of Pulmonary Regurgitation and Stenosis** 490
Rohit Tandon, Rajiv Gupta

66. **Echocardiographic Evaluation of the Prosthetic Valve** 498
Ashok K Omar, Rahul Kumar, Mitu Minocha, Shailendra Bhadoriya

67. **Magnetic Resonance Imaging in Valvular Heart Disease** 522
Kartik Ganga, Arun Sharma, Gurpreet S Gulati

SECTION 8: RHEUMATIC HEART DISEASE

68. **Recent Advances in Echocardiographic Navigation in Acute Rheumatic Fever Evaluation** 535
IB Vijayalakshmi

69. **Balloon Valvotomy in Rheumatic Mitral Stenosis: Echocardiographic Evaluation** 543
CN Manjunath, Ravi S Math

SECTION 9: ATRIAL FIBRILLATION

70. **Echocardiographic Navigation in Atrial Fibrillation—From Irregular Pulse to Slurring of Speech** 561
Shraddha Ranjan, Manish Bansal, Ravi R Kasliwal, HK Chopra

71. **Echocardiographic Evaluation of LV Diastolic Dysfunction and Drugs that Modify Diastolic Dysfunction** 577
Hanumanth K Reddy, Ravi Komatireddy, Thirupathi K Reddy, Raghuveer Kura

72. **Role of Echocardiography in Atrial Fibrillation** 584
Soumitra Kumar

73. **Advances in Echocardiographic Evaluation of Left Atrial Appendage** 588
Krishnam Raju P, Chandramukhi Sunehra

74. **Advances in Echocardiographic Evaluation of Left Atrial Strain in Atrial Fibrillation** 600
Nitin J Burkule

75. **Non-Vitamin-K Oral Anticoagulant Effect and Outcome Evaluation in Echocardiography** 607
Tapan Sinha, Mrinal Kanti Das

76. **Electrophysiology Mapping in Atrial Fibrillation** 616
Shafiq Ahmed Zargar, Aparna Jaswal

77. **Echocardiographic Navigation for Radiofrequency Ablation** 621
Ajit Thachil

SECTION 10: VENTRICULAR TACHYCARDIA STORM

78. **Echocardiographic Imaging in Ventricular Tachycardia Storm** 633
Ashish Nabar, Goutam Vaggar, Varun Deokate

79. **Cryoballoon Ablation for Atrial Fibrillation** 638
Jayakeerthi Yoganarasimha

SECTION 11: DILATED CARDIOMYOPATHY

80. **Advances in Echocardiographic Navigation in Dilated Cardiomyopathy** 645
Vivek Tandon

81. ICD/CRT Evaluation in DCMP by Echocardiography 654
Nitin Burkule

82. Echo-guided Dyssynchrony Evaluation in Dilated Cardiomyopathy 664
Rahul Mehrotra, Raj Kumar

83. Myocardial Perfusion Single-photon Emission Computed Tomography in Assessment of Left Ventricular Dyssynchrony 670
Chetan D Patel, Anirban Mukherjee

84. Left and Right Ventricular and Atrial Strain Evaluation by Two-dimensional Speckle Tracking Echocardiography 676
Sudhir Wahi, Adrian Chong, Tony Stanton, Liza Thomas

85. Echo-guided PPI Evaluation in Dilated Cardiomyopathy by Echocardiography 690
Soumitra Kumar

SECTION 12: HYPERTROPHIC OBSTRUCTIVE CARDIOMYOPATHY

86. Advances in Echocardiographic Navigation in Hypertrophic Cardiomyopathy 695
Rahul Mehrotra, Showkat Hussain Bhat, Raj Kumar, Bharat Bansal

87. Implantable Cardioverter Defibrillator for Sudden Death Prevention in Hypertrophic Cardiomyopathy 701
Surendra Chutani, Arti Shah, Arun Chutani, Bharat Kantharia

SECTION 13: RESTRICTIVE CARDIOMYOPATHY

88. Advances in Echocardiographic Navigation in Restrictive Cardiomyopathies 707
S Sivasankaran, G Vijayaraghavan

89. Restrictive Cardiomyopathies 721
Krishnam Raju P, Chandramukhi Modi

SECTION 14: PERICARDIAL EFFUSION

90. Advances in Echocardiographic Navigation in Pericardial Effusion 751
Sakhalesh Patil, S Sivasankaran, G Vijayaraghavan

91. Echocardiographic Advances in Evaluation of Cardiac Tamponade 760
S Shanmugasundaram, U Ilayaraja, K Rajeswari

92. Multimodality Imaging of Pericardium 776
Vidyut Jain, Avani Jain, Ravi Masand

SECTION 15: CONSTRICTIVE PERICARDITIS

93. Advances in Echocardiographic Evaluation of Constrictive Pericarditis 785
G Vijayaraghavan, S Sivasankaran, Sakhalesh Patil

94. Computed Tomography and Magnetic Resonance Imaging in Pericardial Diseases 797
Tarun Mittal

SECTION 16: INFECTIVE ENDOCARDITIS

95. Advances in Echocardiographic Navigation of Infective Endocarditis 809
Krishnam Raju P, Chandramukhi Sunehra

SECTION 17: PULMONARY EMBOLISM AND DEEP VEIN THROMBOSIS

96. Echocardiographic Navigation in Pulmonary Embolism and Deep Vein Thrombosis 831
Satish K Parashar, HK Chopra, PK Mangla

97. Computed Tomography Angiographic Evaluation in Pulmonary Embolism and Deep Vein Thrombosis 839
Priya Jagia, Niraj Pandey

SECTION 18: PULMONARY HYPERTENSION

98. **Advances in Echocardiographic Navigation in Pulmonary Hypertension** 847
S Shanmugasundaram, U Ilayaraja, K Rajeswari

SECTION 19: AORTIC DISEASE

99. **Echocardiographic Evaluation in Aortic Disease** 867
Anjlee M Mehta, HK Chopra, Navin C Nanda, Ahmed Y Salama, Raziye E Akdogan, Hanan Fadala

100. **CT and MR Angiographic Evaluation of Aortic Diseases** 877
Vineeta Ojha, Sanjeev Kumar

SECTION 20: CAROTID ARTERY DISEASE

101. **Ultrasound Evaluation of the Carotid Artery for Stenosis** 893
Christopher SG Murray, Tamanna Nahar, Navin C Nanda, HK Chopra

SECTION 21: VERTEBRAL ARTERY DISEASE

102. **Color Doppler Evaluation of Vertebral Artery Disease** 907
Naveen Garg, KK Kapur

SECTION 22: PERIPHERAL ARTERIAL AND VENOUS DISEASE

103. **Color Doppler Echocardiographic Evaluation of Peripheral Arterial, Venous, and Carotid Artery Disease** 915
Naveen Garg, KK Kapur, HK Chopra

104. **CT and MR Angiography Evaluation of Peripheral Arterial and Venous Disease** 938
Chandrashekhara SH, Priya Jagia, Mumun Sinha

105. **Conventional Angio Evaluation of Peripheral Arterial Disease** 946
NN Khanna, Dyah W Anggrahini, Suparna Rao, Oladimeji Oluwaseye

106. **Advanced Image-guided Peripheral Vascular Interventions** 953
NN Khanna, Suparna Rao, Oladimeji Oluwaseye, Wulan Anggrahini

107. **Color Doppler Evaluation of Erectile Dysfunction** 963
Naveen Garg, KK Kapur

SECTION 23: SYNCOPE

108. **Electrocardiography in Syncope: Diagnostic, Prognostic, and Therapeutic Implications** 973
Vivek Kumar, Vanita Arora

109. **Cardiac Color Doppler Echo Evaluation in Syncope** 979
Rajan J Manjuran, Sulthan R Salih

SECTION 24: STROKE

110. **Atrial Fibrillation and Stroke** 987
Himashu Agarwal, Chandril Chugh

111. **Computed Tomography and Magnetic Resonance Imaging in Stroke** 993
Vivek Lanka, Ajay Garg

112. **Recent Advances in Neurointervention** 1006
Sanjeev Kumar, Tariq Matin

SECTION 25: CONGENITAL HEART DISEASE

113. **Advances in Echocardiographic Evaluation and Intervention of Cyanotic Congenital Heart Disease** 1017
Sakshi Sachdeva, S Ramakrishnan

114. Echocardiographic Evaluation in Neonatal Heart Failure 1027
Hala El Marsafawy

115. Advanced Echo Imaging in Cardiomyopathies in Children 1037
Sonia A El-Saiedi, Hosam Ibrahim, Wael A Attia

116. Cross-sectional Imaging in Congenital Heart Disease 1044
Richa Kothari, Vimal Raj

117. Role of Cardiac MRI in Evaluation of Congenital Heart Disease 1055
Richa Kothari, Vimal Raj

SECTION 26: ECHO IN EXTRACORPOREAL MEMBRANE OXYGENATION

118. Echo in Extracorporeal Membrane Oxygenation in Critical Care 1069
Poonam Malhotra

SECTION 27: SHOCK

119. Echocardiographic Evaluation of Shock in Intensive Care Unit 1083
Rekha Mishra, Rakesh Bachloo, Shashwat Mishra

SECTION 28: EPIDEMIOLOGICAL

120. Imaging as Tool for Risk Prediction in Cardiovascular Epidemiology 1097
Suman Singhal, Rajeev Gupta

121. Reducing Cardiovascular Risk in Diabetes from Tsunami Warning to Zebra Line 1108
Tiny Nair

122. Metabolic Syndrome and C-Reactive Protein 1112
SN Pathak, Rajesh Meena, HK Chopra

123. Biomarker B-type Natriuretic Peptide Imaging in Heart Failure 1115
Srikant Sharma, HK Chopra, M Srihari Babu, Surabhi Awasthi, Nisarg Patel

124. Neuroimaging in Meditation 1126
Subash Khushu, Richa Trivedi, Kushal Madan, SC Manchanda

125. Multimodality Imaging and Telemedicine in Cardiology 1134
P Krishnam Raju, SG Prasad

126. Echocardiography in Noncardiac Surgery 1147
Yatin Mehta, Dheeraj Arora

SECTION 29: METABOLIC: NUTRITIONAL IMAGING

127. Lipid Evaluation: Diagnostic, Prognostic, and Clinical Therapeutic Implications 1155
JPS Sawhney, Prashant Wankhade, Simran Sawhney

128. Coenzyme Q_{10} Imaging and Coronary Artery Disease 1162
Pawan K Sharma, HK Chopra

129. Myocardial Molecular Imaging of Fatty Acid Metabolism Using BMIPP 1169
Pawan K Sharma, HK Chopra, Srikant Sharma

130. Homocysteine Imaging and Coronary Artery Disease 1176
GS Sainani, Rajesh Sainani

SECTION 30: CARDIAC SPACE-OCCUPYING LESION

131. Cardiac Tumors 1183
George Koshy, Mathew Iype, KM Krishnamoorthy

132. Cardiac Computed Tomography and Magnetic Resonance Evaluation of Cardiac Masses 1191
S Singhal, R Singhal

SECTION 31: INTRAOPERATIVE ECHOCARDIOGRAPHY IN OPERATION THEATER

133. Intraoperative Transesophageal Echocardiography 1203
Prateek Sharma, Ashley Pender, Roshini Malaney, Smadar Kort

134. Echocardiographic Imaging in Operation Theater 1212
Naman Shastri

SECTION 32: SURGERY AND IMAGING

135. Imaging in Heart Transplant 1227
Kewal Krishan, Reena Anand, Rajneesh Malhotra

136. Intraoperative Graft Imaging 1232
OP Yadava

SECTION 33: ECHO ONCOLOGY

137. Echocardiographic Navigation Cardio-oncology 1241
Madhu Mary Minz, Manish Bansal, Ravi R Kasliwal, HK Chopra

SECTION 34: ETHICAL AND LEGAL ISSUES

138. Ethical and Legal Issues in Cardiovascular Imaging 1253
KK Aggarwal

SECTION 35: FUTURE DIRECTIONS

139. Imaging to Plan Transcatheter Aortic Valve Replacement 1269
Anil Dhall, Nagendra Chouhan, Karan Chopra, Prashant Bharadwaj

140. Recent Advances in Strain Echocardiographic Analysis of Coronary Artery Disease 1288
V Amuthan, RVA Ananth

141. Newer Advances in Computed Tomography and Magnetic Resonance Imaging in Cardiac Imaging 1299
Harsh Mahajan, Suman Singhal

142. Current Concepts of Radiotracer Technology and its Future Directions 1307
N Ramamoorthy, Meera Venkatesh

Index 1311

VIDEO LEGENDS

Video 1: A large myxoma in left atrium.
Video 2: A myxoma in left atrium; smaller compared to Video 1, but producing mitral inflow obstruction.
Video 3: Parasternal long axis view of myxoma attached to anterior mitral leaflet and prolapsing to left ventricular outflow tract.
Video 4: Parasternal short axis view of myxoma shown in Video 3.
Video 5: Myxoma in right atrium producing tricuspid inlet obstruction.
Video 6: A sweep of four-chamber view showing multiple rhabdomyomas in the ventricular septum, apex, and lateral wall of ventricle.
Video 7: Myxosarcoma in left atrium prolapsing into left ventricle. Note the bulky, mobile, heterogeneous mass with the areas of echolucency suggestive of necrosis.
Video 8: Lymphoma in right ventricular outflow tract, producing turbulence in outflow tract.
Video 9: Thickening in free wall and septum due to secondaries from an unknown site.
Video 10: A small thrombus in the left atrial appendage.

**The videos (Chapter 131) are available on www.emedince360.com*

SECTION 2

Hypertension

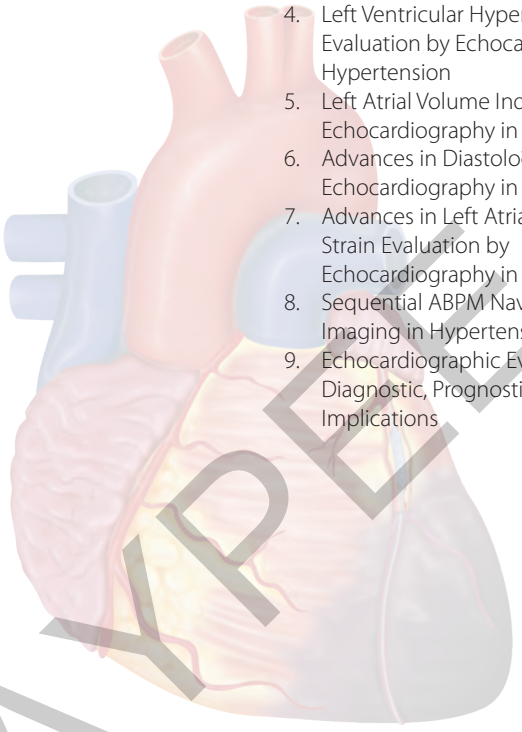

4. Left Ventricular Hypertrophy Evaluation by Echocardiography in Hypertension
5. Left Atrial Volume Index Evaluation by Echocardiography in Hypertension
6. Advances in Diastology by Echocardiography in Hypertension
7. Advances in Left Atrial Strain Evaluation by Echocardiography in Hypertension
8. Sequential ABPM Navigation Imaging in Hypertension
9. Echocardiographic Evaluation in Hypertension: Diagnostic, Prognostic, and Therapeutic Implications
10. Beta-blocker Effect and Outcome Evaluation by Echocardiography in Hypertension
11. Statin Effect and Outcome Evaluation by Echocardiography
12. ARNIs Effect and Outcome Evaluation by Echocardiography in Hypertension
13. Left Ventricular Hypertrophy and Left Ventricular Mass Index Evaluation by 3D Echocardiography in Hypertension
14. Validation of Chlorthalidone Efficacy and Outcome by Echocardiographic Variables
15. Secondary Hypertension Evaluation: Multimodality Imaging

JAYPEE BROTHERS

4

CHAPTER

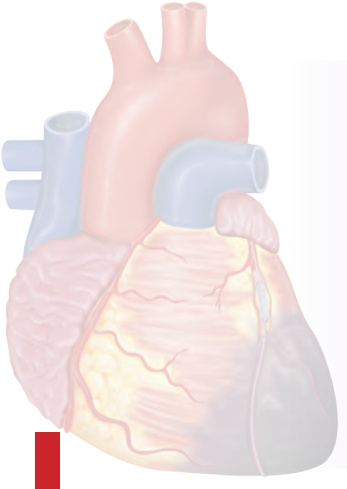

Left Ventricular Hypertrophy Evaluation by Echocardiography in Hypertension

Atul Karande, Manish Bansal, R Hotchandani

INTRODUCTION

Hypertension is currently a major contributor to the global burden of disease. The left ventricle (LV) remains one of the main target organs of hypertension. Echocardiographic measures of structure and function provide prognostic information. Left ventricular mass (LVM) is a well-established measure that can independently predict adverse cardiovascular events and premature death.[1-3] Population-based studies have revealed that increased LVM and left ventricular hypertrophy (LVH), as assessed by two-dimensional (2D) M-mode echocardiography measurements, provide prognostic information beyond traditional cardiovascular disease (CVD) risk factors.[4-6] Left ventricular mass has been stated as a suitable measure for CVD risk stratification and a marker for subclinical disease.[4,7] Moreover, the regression of LVH in patients with hypertension treated with antihypertensive medication has been associated with improved CVD outcomes.[8,9]

DIAGNOSTIC CRITERION

It is essential to have a reliable method for estimation of LVM. Echocardiography offers a reliable, noninvasive, rapidly available, and relatively inexpensive method for estimation of LVM. Regardless of the method used, LVM estimation is derived by converting myocardial volume to mass by multiplying the volume by the myocardial density of 1.05 g/mL.[10] All measurements should be performed at the end of diastole, the frame before mitral valve closure or the frame in the cardiac cycle in which the ventricular dimension is largest.

Linear Method (for Normally Shaped Ventricles)

The linear measurements of LV diastolic dimension (LVDd), septal [interventricular septum (IVS)], and posterior wall (PW) are made from the parasternal long axis or short axis acoustic window with the ultrasound beam directed perpendicular to the LV long axis approximately at the level of the mitral valve leaflet tips (Fig. 1A).[10] M-mode recordings have excellent temporal resolution and may be chosen from 2D images. However, even when directed by 2D guidance, it may not be possible to align the M-mode cursor perpendicular to the long axis of the ventricle.[11] A software has been developed to reconstruct anatomical M-mode images from 2D images (Fig. 1B). This is now available in most of the equipment.

Advantages

- Abundance of published data:
  - Fast and widely used
  - Established prognostic value.
- Fairly accurate in normally shaped ventricles (systemic hypertension, aortic stenosis).

Limitations

Beam orientation frequently off axis

- Based on the assumption that the LV is a prolate ellipsoid with a 2:1 long/short-axis ratio
- Since linear measurements are cubed, small measurement errors in dimensions are also multiplied
- It overestimates LV mass.

JAYPEE BROTHERS

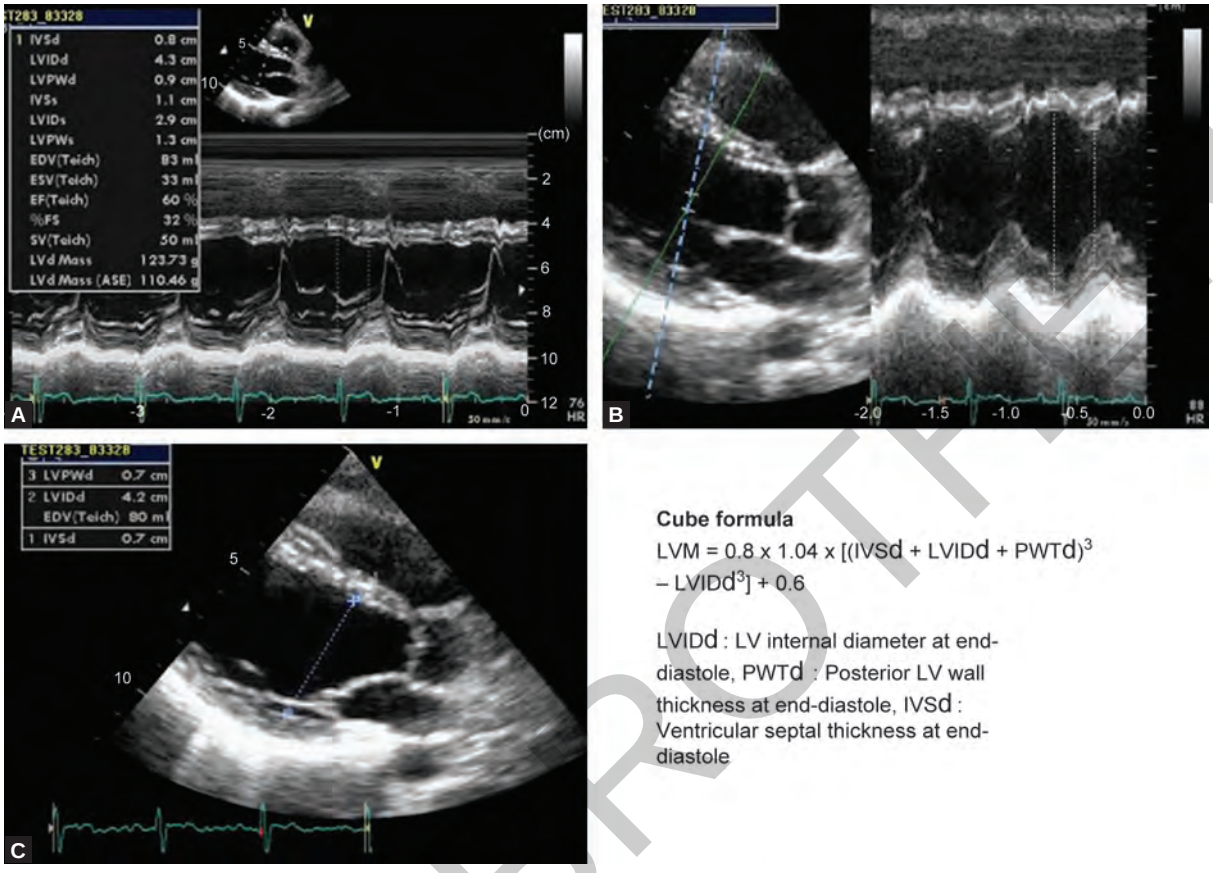

Figs. 1A to C: Linear echocardiographic methods of LVM measurement.

Inaccurate in the Presence of Asymmetric Hypertrophy or Dilated Ventricles

Alternatively, chamber dimension and wall thicknesses can be acquired from the parasternal long-axis view using direct 2D measurements. The use of 2D-derived linear dimensions overcomes the common problem of oblique parasternal images resulting in overestimation of dimensions from M-mode. When 2D measurements are used, the wall thicknesses and linear dimensions should be measured at the level of the LV minor dimension, at the mitral leaflet tips level. Left ventricle internal dimension diastole, IVS diastole, and PW diastole are measured at end-diastole (Fig. 1C).

Advantage

It facilitates orientation perpendicular to the LV long axis.

Limitations

Based on the same geometrical assumptions as M-mode.

- Same limitations as M-mode in patients with abnormal LV geometry
- Impact of harmonic imaging on the mass calculations is not established
- Normal values are less well established.

Normal Values

The upper limits of normal ranges in the American Society of Echocardiography chamber quantification update are more than 95 g/m^2 (>44 g/height 2.7) in women and more than 115 g/m^2 (>48 g/height 2.7) in men.

Two-dimensional Method

The commonly used 2D methods for measuring LVM are based on the area, length formula, and the truncated ellipsoid model (Fig. 2).[12] In the presence of shape distortions, the geometric assumptions in this approach remain problematic. Both methods were validated in the early 1980s in animal models and human autopsies.

Advantages

- Partial correction for shape distortions
- Less dependent on geometrical assumptions than the linear measurements.

JAYPEE BROTHERS

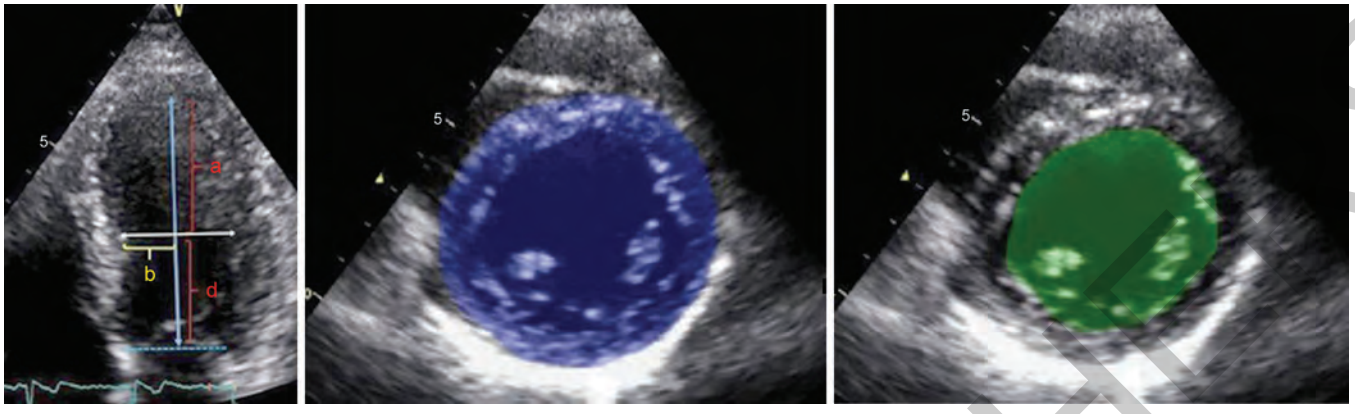

Truncated ellipsoid method:

$$LVM = 1.05 \left\{(b+t)^2\left[\frac{2}{3}(a+t)+d-\frac{d^3}{3(a+t)^2}\right]-b^2\left[\frac{2}{3}a+d-\frac{d^3}{3a^2}\right]\right\}$$

Area-length method:

$$LVM = 1.05\left\{\left[\frac{5}{6}A_2(a+d+t)\right]-\left[\frac{5}{6}A_2(a+d)\right]\right\}$$

A_1: Total LV area obtained by tracing the epicardium, A_2: LV cavity area obtained by tracing the endocardium excluding papillary muscles, a: LV extending rom the widest LV to the apex, b: widest LV radius, d: truncated LV extending from widest short axis to the mitral annulus plane, t (mean LV wall thickness) = $\sqrt{(A_1/\pi)}-b$

Fig. 2: 2D echocardiographic methods of LVM measurement.

Limitations

- Good image quality and properly oriented parasternal views are required with no oblique planes
- Cumbersome methodology
- Good epicardial definition is required
- Higher measurement variability
- Less published normative data.

Normal Values[10,13,14]

- *Left ventricle mass (g)*: Men—96–200, women—66–150
- *Left ventricle mass index (g/m²)*: Men—50–102, women—44–88.

Three-dimensional Method (for Abnormally Shaped Ventricles and Ventricles with Asymmetric or Localized Hypotrophy)

The benefit of three-dimensional echocardiography (3DE) is especially to obviate inaccurate geometric assumptions, inherent to two-dimensional echocardiography (2DE). 3DE is a potentially attractive modality for the measurement of LVM, and normal ranges have been developed.[14] The accuracy of 3DE is reportedly similar to cardiac magnetic resonance (CMR) imaging methods.[15-17] However, there are wide limits of agreement which primarily relate to difficulties in tracing accurately the LV epicardial border, particularly in dilated ventricles.[18] Three-dimensional echocardiography underestimates LVM compared with CMR imaging in patients with cardiac disease, yet is more accurate than alternative ultrasound methods.

Advantages

- Higher accuracy than the linear or 2D measurements
- Higher inter-measurement and test/retest reproducibility
- Direct measurement without geometrical assumptions
- Better discrimination of small changes.

Limitations

- Patient's cooperation is required
- Dependent on image quality
- Normal values less well established.

Normal Values[10,13,14]

Left ventricle mass index (g/m²): Men—57–97, women—58–90.

JAYPEE BROTHERS

BODY SIZE INDEXATION

Normal values for LVM are derived from the studies of the general population without hypertension or obesity.[9,10] For the comparison of LVM among the subjects of different body sizes, different allometric approaches have been suggested. However, there is controversy about the best method for indexing LVM.[10] Body surface area (BSA) was the first anthropometric variable used to index LVM. It has shown a stronger statistical correlation than height with LVM[19] and better identification of hypertension-related LVH.[20] However, indexing by BSA has been noted to minimize the effect of obesity on LVM, and, therefore, it underestimates the prevalence of obesity-related LVH.[21] Indexation of LVM to height raised to an allometric exponent of 2.7 (LVM/height 2.7), in comparison to BSA or height alone, has shown better predictive value for CVD outcomes, better detection of obesity-related LVH, and less variability of LVM among normal individuals.[22,23] Chirinos et al. demonstrated that indexation to LVM/height 1.7 was the best method, in comparison to BSA and height 2.7, to identify obesity-related LVH.[24] In a population with a low prevalence of obesity, there was no significant difference in the risk attributed to LVH, regardless of the method of indexation.[25]

The American Society of Echocardiography and European Association of Cardiovascular Imaging recommend BSA as the preferred method for indexing LVM.[10]

PROGNOSTIC IMPLICATIONS

Left Ventricle Remodeling Patterns and Prognostic Implications

While patients with early hypertensive disease will most likely have normal LV geometry,[26] long-standing or untreated hypertension will result in changes in LV shape, and eventually, a deterioration of systolic function. Broadly, the changes in LV geometry can be classified according to whether LVM is normal or increased and whether ventricular morphology [relative wall thickness (RWT)] is altered (Fig. 3).[13] Relative wall thickness is variably reported as (PW × 2)/LVd or (IVS + PW)/LVd; of which, the former is favored because septal measurements may be confounded by the presence of septal bulge. Relative wall thickness is problematic and not reflective of true LV geometry in patients with asymmetric hypertrophy. The upper limit of normal RWT is 0.42.[10]

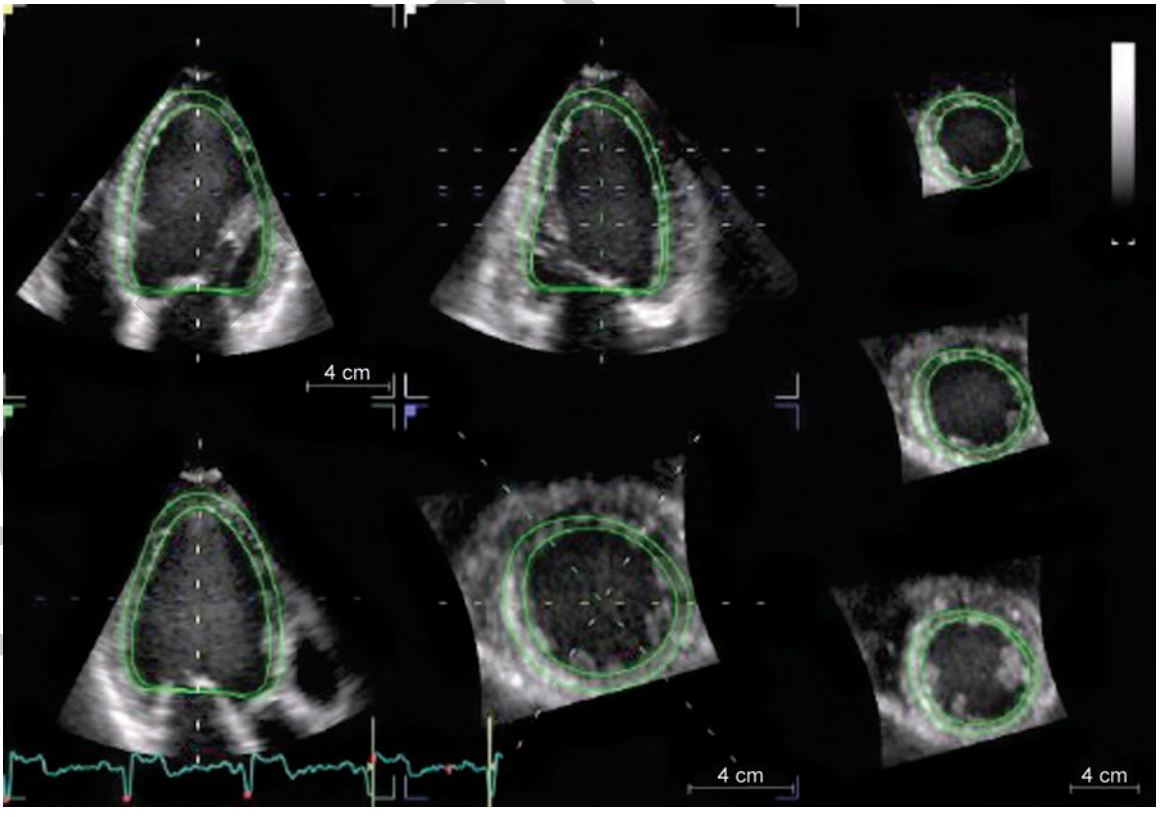

Fig. 3: 3D echocardiographic method of LVM measurement.

JAYPEE BROTHERS

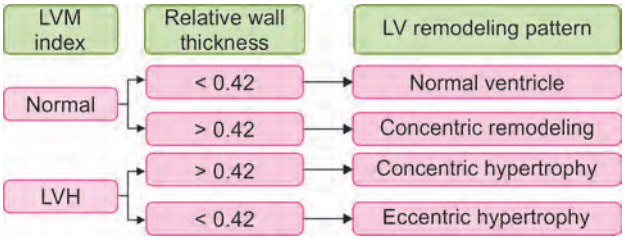

Fig. 4: ASE/EACVI classification of remodeling patterns.

Concentric Left Ventricular Hypertrophy

Concentric LVH, probably most commonly associated with hypertension, is characterized by normal cavity size, uniformly increased LV wall thickness, and increased LVM.[12] Concentric LVH and changes in LV geometry have been shown to affect both men and women, regardless of age,[27] and are also associated with changes in diastolic function, longitudinal and radial myocardial function, and atrial size (Fig. 4).[28-30]

Eccentric Left Ventricular Hypertrophy

In contrast to concentric LVH, eccentric hypertrophy is associated with volume, rather than pressure overload. This is usually due to significant valvular regurgitation or high cardiac index, as is seen in elite athletes. Systemic pressure is normal and peripheral resistance is not increased in patients with eccentric hypertrophy. Echocardiographic findings show increased LV cavity size, normal LV wall thickness, and increased LVM. Patients with eccentric hypertrophy share similar changes in diastolic function and longitudinal and radial function as those with concentric hypertrophy.[27,29,30] Unlike concentric hypertrophy, however, patients with eccentric LVH generally have low normal or mildly impaired systolic function.

Concentric Remodeling

Concentric LV remodeling is a late-stage response of the LV and can be caused by chronic pressure, volume overload, or myocardial infarction. It is most commonly associated with coronary artery disease (CAD), but is also associated with long-standing untreated hypertension.[31] Like eccentric hypertrophy, it is also associated with LV systolic dysfunction. Echocardiographic features show normal or small LV cavity size, usually increased LV wall thickness and normal LVM. Concentric remodeling is also associated with changes in the shape of the LV, which becomes more rounded. This results in dramatic degradation of diastolic function and loss of radial and longitudinal function.[29]

Other Classifications

The limitation of the classical categories is the suboptimal categorization of dilated ventricles.[32] In an attempt to develop a classification that is more inclusive of different physiologic and pathologic remodeling phenotypes, Gaasch and Zile suggested including LV end-diastolic volume as an additional marker to identify LV dilatation.[33] This classification provided incremental prognostic value regarding CVD outcomes in the Cardiovascular Health Study cohort.[34] In another attempt to address the limitations associated with the traditional remodeling classification, Khouri et al. suggested a four-tiered classification of LVH.[32] Dilated LVH and mixed thick and dilated LVH carried the worst prognosis for heart failure or cardiovascular death, and indeterminate hypertrophy had comparable rates to those without LVH.[35]

Prognostic Implication of Left Ventricular Hypertrophy

There is enough evidence indicating association between LVH and increased cardiovascular morbidity and mortality. Levy et al.[36] reported that LVH, quantified by echocardiography, independently predicts cardiovascular morbidity and mortality. The relative risk (RR) for developing CVD was 1.49 in men and 1.57 in women for every 50 g/m^2 increase in the LV mass above normal. This increment was also associated with higher all-cause mortality and cardiovascular mortality. Data from the same cohort also showed that LVH increased the risk of sudden cardiac death, more so in men than women.[37] Hypertensive black adults tend to have higher LV mass and RWT when compared with their Caucasian counterparts.[38] Left ventricular hypertrophy–related cardiovascular risk is higher in black population and women.[39,40] Furthermore, LVH carries more risk than multivessel CAD in this group. Liao et al.[41] showed that among 1,089 African Americans, who had undergone cardiac catheterization and M-mode echocardiography, the attributable RR for all-cause mortality was 2.4 with LVH, 2.0 with reduced ejection fraction, and 1.6 with multivessel CAD. The increase in morbidity and mortality in this group could partly be due to concentric LVH phenotype, which has been independently associated with worse outcomes.[1] Verdecchia et al.[42] showed that for each 29 g/m^2 increase in LV mass, there is a significant independent increase in the risk of stroke in hypertensive patients. In a meta-analysis of 20 studies with 48,545 patients, Vakili et al.[43] found that LVH consistently predicted worse cardiovascular morbidity and all-cause mortality across all groups and population, except end-stage renal disease patients.

JAYPEE BROTHERS

THERAPEUTIC IMPLICATIONS

Left Ventricular Hypertrophy Regression

Current evidence suggests that LVH can be targeted through reducing blood pressure (BP) by pharmacotherapy and lifestyle. Nonpharmacological intervention and lifestyle changes aimed at LVH regression include weight loss, aerobic exercise, and low-salt diet.[44,45] All antihypertensive drugs appear to have some effect on LVH regression. While there is no consensus on the best pharmacologic agent, the current evidence favors the drug-targeting renin–angiotensin–aldosterone system (RAAS).[46] Angiotensin receptor blocker seems to have additional class action on LVH regression, independent of BP control. It is not clear whether dual blockage of RAAS with different pharmacological agents will incur incremental benefit in BP control and LV mass reduction. In a meta-analysis, Klingbeil et al.[47] found a significant difference among different medication classes. Overall, LV mass index was decreased by 13% with angiotensin II receptor antagonists, by 11% with calcium channel antagonists, by 10% with angiotensin-converting-enzyme inhibitors, by 8% with diuretics, and by 6% with β-blockers. Recently, the focus has been shifted to downstream pathways and oxidative stress in the pathogenesis of LVH. Previous studies have shown that allopurinol reduces oxidative stress. In a recent randomized, double-blind, placebo-controlled study, allopurinol 600 mg/day was shown to reduce absolute LV mass and LV mass in patients with type II diabetes mellitus.[48]

Left Ventricular Hypertrophy Regression and Outcome

Regression of LVH is independently associated with improved cardiovascular outcome. This has been reported by Levy et al.,[49] HOPE (Heart Outcomes Prevention Evaluation) trial,[50] and Verdecchia et al.[8] in PIUMA (Progetto Ipertensione Umbria Monitoraggio Ambulatoriale) registry. In a meta-analysis, Verdecchia et al. showed the association between LVH regression and lower CVD events.[51] In the LIFE (Losartan Intervention for Endpoint) Echo Study,[52] composite endpoint of cardiovascular death, fatal and nonfatal myocardial infarction, and fatal or nonfatal stroke occurred in 11% of the patients. There was a parallel independent association between LVH regression and lower cardiovascular mortality, all-cause mortality and myocardial infarction. Interestingly, regression or absence of progression of LV mass has been reported to be associated with lower incidence of diabetes mellitus.[53] In addition, LVH regression has been reported to improve LV systolic performance.[54]

CONCLUSION

Left ventricular mass is prognostically important and should be reported in hypertensive patients. In the normally shaped LV, either M-mode or 2DE formulas can be used to calculate LVM. In laboratories that use 3DE routinely, three-dimensional LVM measurement should be considered especially in abnormally shaped ventricles or in individuals with asymmetric or localized hypertrophy. 3DE is the only echocardiographic technique that measures myocardial volume directly, without geometric assumptions about LV shape and distribution of wall thickening. Description of LV geometry, using at the minimum the four categories of normal geometry, concentric remodeling, and concentric and eccentric hypertrophy, should be a standard component of the echocardiography report.

REFERENCES

1. Koren MJ, Devereux RB, Casale PN, et al. Relation of left ventricular mass and geometry to morbidity and mortality in uncomplicated essential hypertension. Ann Intern Med. 1991;114:345-52.
2. Drazner MH, Rame JE, Marino EK, et al. Increased left ventricular mass is a risk factor for the development of a depressed left ventricular ejection fraction within five years: the Cardiovascular Health Study. J Am Coll Cardiol. 2004;43:2207-15.
3. Verma A, Meris A, Skali H, et al. Prognostic implications of left ventricular mass and geometry following myocardial infarction: the VALIANT (VALsartan In Acute myocardial iNfarcTion) Echocardiographic Study. JACC Cardiovasc Imaging. 2008;1:582-91.
4. Levy D, Garrison RJ, Savage DD, et al. Left ventricular mass and incidence of coronary heart disease in an elderly cohort. The Framingham Heart Study. Ann Intern Med. 1989;110:101-7.
5. Gardin JM, McClelland R, Kitzman D, et al. M-mode echocardiographic predictors of six- to seven-year incidence of coronary heart disease, stroke, congestive heart failure, and mortality in an elderly cohort (the Cardiovascular Health Study). Am J Cardiol. 2001;87:1051-7.
6. Verdecchia P, Carini G, Circo A, et al. Left ventricular mass and cardiovascular morbidity in essential hypertension: the MAVI study. J Am Coll Cardiol. 2001;38:1829-35.
7. Devereux RB, Alderman MH. Role of preclinical cardiovascular disease in the evolution from risk factor exposure to development of morbid events. Circulation. 1993;88:1444-55.
8. Verdecchia P, Schillaci G, Borgioni C, et al. Prognostic significance of serial changes in left ventricular mass in essential hypertension. Circulation. 1998;97:48-54.
9. Hatani T, Kitai T, Murai R, et al. Associations of residual left ventricular and left atrial remodeling with clinical outcomes in patients after aortic valve replacement for severe aortic stenosis. J Cardiol. 2016;68(3):241-7.

JAYPEE BROTHERS

10. Lang RM, Badano LP, Mor-Avi V, et al. Recommendations for cardiac chamber quantification by echocardiography in adults: an update from the American Society of Echocardiography and the European Association of Cardiovascular Imaging. J Am Soc Echocardiogr. 2015;28: 1-39.e14.
11. Marwick TH, Gillebert TC, Aurigemma G, et al. Recommendations on the Use of Echocardiography in Adult Hypertension: A Report from the European Association of Cardiovascular Imaging (EACVI) and the American Society of Echocardiography (ASE). J Am Soc Echocardiogr. 2015;28:727-54.
12. Lang RM, Bierig M, Devereux RB, et al. Recommendations for chamber quantification. Eur J Echocardiogr. 2006;7:79-108.
13. Fukuda S, Watanabe H, Daimon M, et al. Normal values of real-time 3-dimensional echocardiographic parameters in a healthy Japanese population: the JAMP-3D study. Circ J. 2012;76:1177-81.
14. Muraru D, Badano LP, Peluso D, et al. Comprehensive analysis of left ventricular geometry and function by three-dimensional echocardiography in healthy adults. J Am Soc Echocardiogr. 2013;26:618-28.
15. Jenkins C, Bricknell K, Hanekom L, et al. Reproducibility and accuracy of echocardiographic measurements of left ventricular parameters using real-time three-dimensional echocardiography. J Am Coll Cardiol. 2004;44:878-86.
16. Takeuchi M, Nishikage T, Mor-Avi V, et al. Measurement of left ventricular mass by real-time three-dimensional echocardiography: validation against magnetic resonance and comparison with two-dimensional and M-mode measurements. J Am Soc Echocardiogr. 2008;21:1001-5.
17. van den Bosch AE, Robbers-Visser D, Krenning BJ, et al. Comparison of real-time three-dimensional echocardiography to magnetic resonance imaging for assessment of left ventricular mass. Am J Cardiol. 2006;97:113-7.
18. Shimada YJ, Shiota T. Meta-analysis of accuracy of left ventricular mass measurement by three-dimensional echocardiography. Am J Cardiol. 2012;110:445-52.
19. Gardin JM, Arnold A, Gottdiener JS, et al. Left ventricular mass in the elderly. The Cardiovascular Health Study. Hypertension. 1997;29:1095-103.
20. Ferrara LA, Vaccaro O, Cardoni O, et al. Indexation criteria of ventricular mass and predictive role of blood pressure and body composition. Am J Hypertens. 2005;18:1282-7.
21. Cuspidi C, Giudici V, Negri F, et al. Improving cardiovascular risk stratification in essential hypertensive patients by indexing left ventricular mass to height (2.7). J Hypertens. 2009;27:2465-71.
22. de Simone G, Daniels SR, Devereux RB, et al. Left ventricular mass and body size in normotensive children and adults: assessment of allometric relations and impact of overweight. J Am Coll Cardiol. 1992;20:1251-60.
23. de Simone G, Kizer JR, Chinali M, et al. Normalization for body size and population-attributable risk of left ventricular hypertrophy: the Strong Heart Study. Am J Hypertens. 2005;18:191-6.
24. Chirinos JA, Segers P, De Buyzere ML, et al. Left ventricular mass: allometric scaling, normative values, effect of obesity, and prognostic performance. Hypertension. 2010;56:91-8.
25. de Simone G, Devereux RB, Maggioni AP, et al. Different normalizations for body size and population attributable risk of left ventricular hypertrophy: the MAVI study. Am J Hypertens. 2005;18:1288-93.
26. Krishnamoorthy A, Brown T, Ayers CR, et al. Progression from normal to reduced left ventricular ejection fraction in patients with concentric left ventricular hypertrophy after long-term follow-up. Am J Cardiol. 2011;108:997-1001.
27. Masiha S, Sundstrom J, Lind L. Left ventricular geometric patterns and adaptations to hemodynamics are similar in elderly men and women. BMC Cardiovasc Disord. 2011;11:25.
28. Tsioufis C, Taxiarchou E, Syrseloudis D, et al. Left ventricular mass but not geometry determines left atrial size in the early stages of hypertension. J Hum Hypertens. 2009;23:674-9.
29. Mizuguchi Y, Oishi Y, Miyoshi H, et al. Concentric left ventricular hypertrophy brings deterioration of systolic longitudinal, circumferential, and radial myocardial deformation in hypertensive patients with preserved left ventricular pump function. J Cardiol. 2010;55:23-33.
30. Masugata H, Senda S, Inukai M, et al. Differences in left ventricular diastolic dysfunction between eccentric and concentric left ventricular hypertrophy in hypertensive patients with preserved systolic function. J Int Med Res. 2011;39:772-9.
31. Cameli M, Lisi M, Righini FM, et al. Left ventricular remodeling and torsion dynamics in hypertensive patients. Int J Cardiovasc Imaging. 2013;29:79-86.
32. Khouri MG, Peshock RM, Ayers CR, et al. A 4-tiered classification of left ventricular hypertrophy based on left ventricular geometry: the Dallas Heart Study. Circ Cardiovasc Imaging. 2010;3:164-71.
33. Gaasch WH, Zile MR. Left ventricular structural remodeling in health and disease: with special emphasis on volume, mass, and geometry. J Am Coll Cardiol. 2011;58:1733-40.
34. Zile MR, Gaasch WH, Patel K, et al. Adverse left ventricular remodeling in community-dwelling older adults predicts incident heart failure and mortality. JACC Heart Fail. 2014;2:512-22.
35. Garg S, de Lemos JA, Ayers C, et al. Association of a 4-tiered classification of LV hypertrophy with adverse CV outcomes in the general population. JACC Cardiovasc Imaging. 2015;8:1034-41.
36. Levy D, Garrison RJ, Savage DD, et al. Prognostic implications of echocardiographically determined left ventricular mass in the Framingham Heart Study. N Engl J Med. 1990;322(22):1561-6.
37. Haider AW, Larson MG, Benjamin EJ, et al. Increased left ventricular mass and hypertrophy are associated with increased risk for sudden death. J Am Coll Cardiol. 1998;32(5):1454-9.
38. Kizer JR, Arnett DK, Bella JN, et al. Differences in left ventricular structure between Black and White hypertensive adults: the Hypertension Genetic Epidemiology Network Study. Hypertension. 2004;43(6):1182-8.

JAYPEE BROTHERS

39. Havranek EP, Froshaug DB, Emserman CD, et al. Left ventricular hypertrophy and cardiovascular mortality by race and ethnicity. Am J Med. 2008;121(10):870-5.
40. Liao Y, Cooper RS, Mensah GA, et al. Left ventricular hypertrophy has a greater impact on survival in women than in men. Circulation. 1995;92(4):805-10.
41. Liao Y, Cooper RS, McGee DL, et al. The relative effects of left ventricular hypertrophy, coronary artery disease, and ventricular dysfunction on survival among black adults. JAMA. 1995;273(20):1592-7.
42. Verdecchia P, Porcellati C, Reboldi G, et al. Left ventricular hypertrophy as an independent predictor of acute cerebrovascular events in essential hypertension. Circulation. 2001;104(17):2039-44.
43. Vakili BA, Okin PM, Devereux RB. Prognostic implications of left ventricular hypertrophy. Am Heart J. 2001;141(3):334-41.
44. Schmieder RE, Messerli FH, Garavaglia GE, et al. Dietary salt intake. A determinant of cardiac involvement in essential hypertension. Circulation. 1988;78(4):951-6.
45. MacMahon SW, Wilcken DEL, Macdonald GJ. The effect of weight reduction on left ventricular mass. A randomized controlled trial in young, overweight hypertensive patients. N Engl J Med. 1986;314(6):334-9.
46. Sadoshima J, Izumo S. Molecular characterization of angiotensin II-induced hypertrophy of cardiac myocytes and hyperplasia of cardiac fibroblasts. Critical role of the AT1 receptor subtype. Circ Res. 1993;73(3):413-23.
47. Klingbeil AU, Schneider M, Martus P, et al. A meta-analysis of the effects of treatment on left ventricular mass in essential hypertension. Am J Med. 2003;115(1):41-6.
48. Szwejkowski BR, Gandy SJ, Rekhraj S, et al. Allopurinol reduces left ventricular mass in patients with type 2 diabetes and left ventricular hypertrophy. J Am Coll Cardiol. 2013;62(24):2284-93.
49. Levy D, Salomon M, D'Agostino RB, et al. Prognostic implications of baseline electrocardiographic features and their serial changes in subjects with left ventricular hypertrophy. Circulation. 1994;90(4):1786-93.
50. Galzerano D, Tammaro P, Viscovo L, et al. Three-dimensional echocardiographic and magnetic resonance assessment of the effect of telmisartan compared with carvedilol on left ventricular mass: a multicenter, randomized, longitudinal study. Am J Hypertens. 2005;18(12 Pt 1):1563-9.
51. Verdecchia P, Angeli F, Borgioni C, et al. Changes in cardiovascular risk by reduction of left ventricular mass in hypertension: a meta-analysis. Am J Hypertens. 2003;16(11 Pt 1):895-9.
52. Devereux RB, Wachtell K, Gerdts E, et al. Prognostic significance of left ventricular mass change during treatment of hypertension. JAMA. 2004;292(19):2350-6.
53. Okin PM, Devereux RB, Harris KE, et al. In-treatment resolution or absence of electrocardiographic left ventricular hypertrophy is associated with decreased incidence of new-onset diabetes mellitus in hypertensive patients: the Losartan Intervention for Endpoint Reduction in Hypertension (LIFE) Study. Hypertension. 2007;50(5):984-90.
54. Wachtell K, Palmieri V, Olsen MH, et al. Change in systolic left ventricular performance after 3 years of antihypertensive treatment: the Losartan Intervention for Endpoint (LIFE) study. Circulation. 2002;106(2):227-32.

JAYPEE BROTHERS

or detailed information on cardiology books, visit our website www.jaypeebrothers.com, for detailed information on cardiology books, visit our website www.jaypeebrothers.com, for detailed informa

Advances in Clinical Cardiovascular Imaging Echocardiography & Interventions (ACCI-EI)

A Textbook of Cardiology

Salient Features

- It is the first publication in the form of a Textbook of Cardiology
- Over 278 contributors from India and abroad have contributed chapters in this book
- Focuses on every aspect of cardiovascular imaging and intervention, thereby enhancing knowledge and has tremendous innovative and research potential of understanding advances in cardiovascular imaging for the undergraduates, postgraduates, practicing cardiologists, endocrinologists, nephrologists, neurologists, critical care, pulmonologists, pediatricians, pediatric surgeons, physicians, cardiovascular surgeons, dermatologists, gynecologists, imaging experts and nutritionists, etc.
- Includes various sections with chapters on Basics; Hypertension; Heart Failure; ST segment elevation myocardial infarction (STEMI), coronary artery disease (CAD); Advances in Echocardiography: Clinical Implications; Emergency Imaging in Chest Pain; Valvular Hear Disease; Rheumatic heart disease (RHD); Atrial fibrillation, Ventricular Tachycardia Storm; Dilated Cardiomyopathy (DCMP), Hypertrophic Cardiomyopathy (HCM); Restrictive Cardiomyopathy (RCM), Pericardial Effusion, Constrictive Pericarditis, Infective Endocarditis, Pulmonary Embolism and Deep Vein Thrombosis (DVT); Pulmonary Hypertension; Aortic Disease; Carotid Artery Disease; Vertebral Artery Disease; Peripheral Arterial and Venous Disease; Syncope; Stroke; Congenital Heart Disease (CHD); Echo in Extracorporeal Membrane Oxygenation (ECMO); Shock; Epidemiological; Nutritional Imaging; Cardiac Space-occupying Lesions (SOL); Intraoperative Echocardiography in OT, Surgery and Imaging, Echo Oncology, Ethical and Legal Issues, Future Directions, etc. in various sections of the book.



HK Chopra is the Chief Cardiologist, Moolchand Medcity, New Delhi, India, for the last 39 years. He is the Chairman of CME, COP, Moolchand Medcity and is working in Clinical, Preventive Cardiology and Echocardiography. He is the Chairman, World Wellness Foundation. He was the President of the Cardiological Society of India (CSI), 2015 and Indian Academy of Echocardiography, 2017. He has pioneering contribution in thrombolysis in STEMI since 1983 in India, and at Cedar Sinai Hospital, University of California, Los Angeles, USA with Dr William Ganz (1985–86) and University of Alabama, USA with Dr Navin C Nanda (1986–87). He has organized more than 25 World Congresses in Cardiology. He is the Country Head, American Heart Association (AHA). He is the Editor of Cardiodiabetes Update, Atrial Fibrillation Update, STEMI Update, Heart Protection Book, CSI Cardiology Update 2014 by Jaypee Brothers Medical Publishers. He has authored the book Lifestyle and Health: A Mind Body Capsule. He is a former Editor-in-Chief of Indian Heart Journal and Journal of Indian Academy of Echocardiography. He is also the Chairman of Health Committee of ASSOCHAM & SCOPE. He had contributed more than 590 articles in various national and international journals. His clinical research work is recognized all over the world. He is recipient of various national and international awards. Recently, he was conferred Icon in Clinical, Preventive Cardiology and Echocardiography by His Excellency Bharat Ratna Dr APJ Abdul Kalam, Former President of India. He authored the first Heart Wellness Programme launched by Health Minister, the Govt of India. He worked with an eminent cardiologist of India, Dr KL Chopra for 22 years. He organized more than 2100 workshops on public health education and heart check-up camps. He is FRCP. He is fellow of ACC, ESC, ISCU, CSI, IMSA, ASE, IAE and GSI.



Navin C Nanda is the Distinguished Professor of Medicine and Cardiovascular Disease, and the Director, Heart Station/Echocardiograph Laboratories, University of Alabama, Birmingham, Alabama, USA. He is the Director, Echocardiography Laboratory, The Kirklin Clinic, University of Alabama Health Services Foundation, Birmingham. He is a nationally and internationally renowned cardiologist and Echocardiographer, whose pioneering work has significantly altered the way cardiology is practiced in the world today. He was awarded the prestigious Ellis Island Medal of Honor (USA), 2006 and also the 2010 International Service Award from the American College of Cardiology for "significantly enhancing cardiovascular care throughout the world". He was declared the "Echocardiographer of the Millennium" by the Argentinean and Columbian Societies Cardiology and the "Prince of Echocardiography" by the Italian Society of Echocardiography. He was also named the "Father of Echocardiography" by the Emirates Cardiology Society and the Indian Academy of Echocardiography, and "Father of Modern Echocardiography" by the Chinese Medical Association. He has been recognized as a "Gifted Teacher in Cardiology" by the International Academy of Cardiology. He has over 1000 scientific publications to his credit including 14 books, video-textbooks/CDs, and some of his books have been translated into Italian, French, German, Chinese and Turkish languages.



Jagat Narula is the Professor of Medicine and holds the Philip J and Harriet L Chair in Cardiovascular Medicine at the Mount Sinai Cardiovascular Institute in New York, USA. He is also the Director of the Cardiovascular Imaging Program at the Zena and Michael A Wiener Cardiovascular Institute, and of the Marie-Josée and Henry R Kravis Center for Cardiovascular Health, as well as Associate Dean for Global Health at the Mount Sinai School of Medicine. He is the Editor-in-Chief of JACC; Imaging, Executive Editor of JACC and the Editor-in-Chief of the Journal of WHF. He after completing his cardiology fellowship training and PhD (Cardiovascular Immunology) from the AIIMS, New Delhi, relocated to Massachusetts General Hospital (MGH) and Harvard Medical School in 1989. At MGH, after Cardiology, Heart Failure & Transplantation and Nuclear Cardiology Fellowships, he joined the cardiology faculty. In 1997, he moved to Hahnemann University School of Medicine, Philadelphia, where he was Thomas J Vischer Professor of Medicine, Chief of the Division of Cardiology, Vice-Chairman of the Department of Internal Medicine, and the Director of Heart Failure and Transplantation Center. He subsequently joined University of California, Irvine School of Medicine (2003) as Chief, Division of Cardiology, Associate Dean for Research, and Director of the Cardiovascular Center of the UC Irvine's Douglas Hospital. He was also the Director of Memorial Heart and Vascular Institute, Long Beach Memorial Hospital, and Medical Director, Edwards Lifesciences Center for Advanced Cardiovascular Technology, UC Irvine's Henry Samueli School of Engineering. He moved to Mount Sinai as the Philip J and Harriet L Goodhart Chair in Cardiology, and the Director of Cardiovascular Imaging Program in the Mount Sinai's Zena and Michael A Wiener Cardiovascular Institute (2011). He has more than 1000 original research publications or presentations to his credit and more than 35 books or journal supplements edited, and has been awarded as "The Best Young Investigator" on several occasions for his research contributions. He was awarded as the Best Educator as also the Innovator (2012) in Cardiovascular Medicine by the American College of Cardiology, and was honored as the Master of the American College of Cardiology (2013). He has received the Distinguished Scientist Award (2015) from the American College of Cardiology.

Available at all medical bookstores or buy online at www.jaypeebrothers.com

JAYPEE BROTHERS
Medical Publishers (P) Ltd.
www.jaypeebrothers.com

Join us on facebook.com/JaypeeMedicalPublishers

Shelving Recommendation
CARDIOLOGY

ISBN 978-93-5270-696-9