on orthopedics books, visit our website www.jaypeebrothers.com, for detailed information on orthopedics books, visit our website www.jaypeebrothers.com, for detailed information on orthopedics books, visit our website www.jaypeebrothers.com

Royal College of Surgeons
ADVANCING SURGICAL CARE

Tips & Tricks Masterclass of Intramedullary Nailing

Volume 3

JAYPEE
Get Full Access
emedicine360.com

edics books, visit our website www.jaypeebrothers.com, for detailed information on orthopedics books, visit our website www.jaypeebrothers.com, for detailed information on orthopedics books, visit our website www.jaypeebrothers.com

Royal College of Surgeons
ADVANCING SURGICAL CARE

Tips & Tricks Masterclass of Intramedullary Nailing

Volume 2

JAYPEE
Get Full Access
emedicine360.com

n orthopedics books, visit our website www.jaypeebrothers.com, for detailed information on orthopedics books, visit our website www.jaypeebrothers.com, for detailed information on orthopedics books, visit our website www.jaypeebrothers.com

Royal College of Surgeons
ADVANCING SURGICAL CARE

Tips & Tricks Masterclass of Intramedullary Nailing

Volume 1

JAYPEE
Get Full Access
emedicine360.com



Subhash Ch Halder

Based on a Course
Accredited by
The Royal College of Surgeons, England

Celebrating 50
Passion, Quality and Innovation in Healthcare Publishing

Case 3.9, A 2.3 fracture
Showing the 6 steps of maneuver to reduce the fracture in relation to the position of leg and 'C' arm P. 96-98

Case 3.10, A 2.3 fracture
Reduction of the fracture following 6 steps of reduction maneuver P. 99

Case 3.11, A 2.3 fracture
Failed to reduce the fracture following 6 steps of reduction maneuver P. 100-102
Then the fracture was reduced with 'Joystick' technique P. 103-104

Case 3.12, A 2.2 fracture
Incomplete reduction of fracture and fixation P. 105

Case 3.13, A 2.3 fracture
Anatomical reduction of the fracture and fixation P. 106

Case 3.14, A 2.3 fracture
Reduction of fracture with 'Joystick' technique P. 107-108

Case 3.15, A 2.2 fracture
Reduction of fracture with 'Joystick' technique but, displaced the fracture during insertion of nail P. 109-110

Case 3.16, A 2.2 fracture
Reduction of fracture with 'Joystick' technique but, displaced the fracture during fixation P. 111-113

Case 3.17, A 2.1 fracture
Incomplete reduction of fracture and unacceptable fixation then, revision of the operation, reducing the facture with 'Joystick' technique P. 114-116

Case 3.18, A 2.3 fracture
Incomplete reduction of fracture and unacceptable fixation then, revision of the operation, reducing the facture with 'Joystick' technique P. 117-120

Case 3.19, A 2.2 fracture
Incomplete reduction of fracture P. 121

Case 3.20, A 2.2 fracture
Anatomical reduction of the fracture following 6 steps of reduction maneuver P. 122

Case 3.21, A 3.3 fracture
Anatomical reduction of the fracture following 6 steps of maneuver P. 123-124

Case 3.22, A 3.3 fracture
Anatomical reduction of the fracture following 6 steps of maneuver P. 125

Chapter 4 Entry Hole in the Tip of the Trochanter Cases 4.1–4.18 127-143

Surface marking of the tip of the trochanter P. 128
Insertion of guidewire in the tip of trochanter P. 129-133
Insertion of the step drill in the trochanter P. 134-137
Exchange of threaded guidewire with bent tip guidewire through exchange tube in the greater trochanter P. 136 and 138
Insertion of guidewire through the multi-hole trocar P. 139-140
Insertion of solid trochanteric reamer in the trochanter P. 141-143

Chapter 5 How to Insert the H/S Guidewire in Ideal Position in the Head and Neck of the Femur? 144-168

Case 5.1, A 3.2 fracture P. 145-146
Showing ideal way,
1. To reduce the fracture
2. Insertion of guidewire inside the nail and neck of femur
3. Reaming the neck of femur
4. And position of the hip screw in the neck and head of the femur

Case 5.2, A 3.2 fracture P. 147-148
Showing ideal way,
1. To reduce the fracture
2. Insertion of guidewire inside the nail and neck of femur
3. Reaming the neck of femur
4. And position of the hip screw in the neck and head of the femur

Malposition of the Guidewire Inside the Nail and Neck of the Femur

Cases 5.3 and 5.4: Showing the reamer scratching inside the nail during reaming P. 150-152
Four different ways to insert guidewire in the center of the hole of the nail P. 153

Case 5.5
Proper insertion of soft tissue protector P. 154

Cases 5.6, 5.7, 5.8 and 5.9
Re-position of the guidewire after making a hole in the neck with drill bit P. 154-159

Cases 5.10 and 5.9
Reaming the neck of the femur without using guidewire P. 160-162
Reaming the head and neck of the femur without using guidewire P. 160-162
Repositioning the nail to get guidewire in center position P. 163-167

Chapter 6 Measurement of the Hip Screw
Cases 6.1–6.9 169-177

How to Measure the Proper Length of the Hip Screw?
Inadequate information in literature how to use measuring scale P. 170

Case 6.1
Better understanding of the length and position of the H/S in the lateral cortex of the femur P. 171

Cases 6.2, 6.3, 6.4, 6.5, 6.6, and 6.7
Explaining the outcome of the H/S with different length P. 172-177

Chapter 7 Distal Locking Screw in Short Gamma Nail
Cases 7.1–7.5 178-192

Efficacy of using Distal Locking Screws

Case 7.1, A 2.3 and Case 7.2, A 2.3 fractures
Treated with short Gamma nail without using distal locking screw P. 179-180

Case 7.3, A 2.2 fracture
Fixation failed as using distal locking screw in wrong position in the hole of the nail P. 181
Revision operation with short Gamma nail without using distal locking screw P. 182-183

Case 7.4
Showing the position of the distal locking screw outside the hole of the nail P. 184

Case 7.5
Showing the distal locking screw in wrong position in the hole of the nail P. 184

Conclusion
Considering reduction of the fractures, Choosing the right implant and its position in the neck of the femur P. 185-192

B. Subtrochanteric Fracture **P. 193-228**

Chapter 8 Subtrochanteric Fracture
Cases 8.1–8.17 193-228

Cases 8.1 and 8.2 Treated with DHS P. 195

Cases 8.3 and 8.4 Treated with long intramedullary nail P. 195

Cases 8.5 P. 196-200
Patient with Thomas splint P. 196
Patient with Thomas splint in anesthetic room P. 197, Step 1 and 2
Technique of transferring the patient from trolley to pinning table P. 198. Step 3
Removal of the Thomas splint P. 198, Step 3
Position of the foot (Neutral) P. 198, Step 4
Position of the foot (Dorsiflex) P. 198, Step 5
Reduction of the subtrochanteric fracture P. 199, Step 6
Position of C-arm (lateral view) P. 199, Step 7, 8
Threaded guidewire in the tip of the trochanter P. 199, Step 9, 10
Step drill in the trochanter P. 200, Step 10-12
How to bend the tip of the wire? P. 200, Step 13
Bent guidewire in the trochanter P. 200, Step14

Few Examples of Technique of Reduction of Subtrochanteric Fracture, Cases 8.6–8.17 P. 201-228

Chapter 9 Reaming of the Femur
Cases 9.1–9.23 229-340

Introduction P. 229-230
Curvature of femur P. 231-232
Malposition of the nail in distal end of the femur P. 233-235
Conventional reaming P. 236-238

Author's Reaming Technique
How to bend the guidewire? P. 239
Position of the bent guidewire in femur P. 240

Reaming of Posterior Cortex of the Femur

Practical demonstration of reaming the posterior cortex P. 241-242
Step 1: Position of the guidewire distal femur
Step 2: Rimming of posterior cortex of femur
Step 3: Holding the Bent guidewire in position

Cases 9.1 Technique of Reaming of the Femur and Insertion of the Nail P. 243-246

Step 1: Entry hole in tip of trochanter P. 244
Step 2a: Position of the guidewire in proximal, 2/3rd of femur P. 244
Step 2b: Rotation of the tip bent guidewire P. 244
Step 3: Insertion of the exchange tube P. 244
Step 4: Removal of the guidewire P. 244
Step 5: Insertion of the 2nd guidewire, Fig. C P. 245
Step 6: Position of the 2nd bent guidewire in distal femur P. 245
Step 7: Insertion of the bent guidewire in distal 1/3rd part of femur P. 245
Step 8A and B: Hold down the exchange tube in distal femur over the bent part of the wire in Figs. A and B P. 245
Step 8C and D: Removal of the exchange tube, leaving bent guidewire P. 245
Step 9: Rimming the distal femur P. 246
Step 10a: Removal of the reamer, leaving the guidewire in position P. 246
Step 10b: Measurement of the length of the nail P. 246
Step 11: Insertion of the nail P. 246
Step 12: Insertion of the H/S screw P. 246
Step 12: Insertion of the distal screw P. 246

Measurement of the Nail

Measurements of the nail over the bent guidewire P. 250, 300
Measurements of the nail by the side of the wire P. 285, 310
Nail follow the curvature of the guidewire during its insertion P. 250, 259, 269 and 275
Insertion of the polar pin in the distal femur P. 311, and 453

Few Examples of Reaming of Subtrochanteric Fracture, Cases 9.2–9.23 P. 247-334

Conclusion of Fixation of Subtrochanteric Fracture P. 335-340

Chapter 10 Revision Operation of Femoral Fracture
Cases 10.1–10.18 341-410

Revision of DHS to Gamma Nail

Cases 10.1–10.6 P. 342-360

Steps of Revision of Short Gamma nail to another Gamma

Cases 10.7–10.18
Technique of:
Removal of set screw of Gamma nail P. 363
Removal of hip screw and nail P. 365
After re-reduction, fracture was revised with another Gamma nail, P. 366-405
Conclusion of Revision of Gamma Nail P. 406-410

Chapter 11 Removal of the Broken Gamma Nail
Cases 11.1–11.12 411-436

Removal of broken proxy section of nail P. 412-415
Removal of broken distal lockings P. 416-422
Removal of broken nail by Hook method P. 423-425
Removal of broken nail by screw method P. 426
Removal of broken nail by guidewire method P. 427-430
Removal of broken nail by retrograde method P. 431-432
To use Hook method in different way in case of broken nail and distal locking screws P. 433-436

Chapter 12 Few Examples of Revision for Nonunion of Femoral Nailing Due to Implant Failure
Cases 12.1–12.10 437-478

Conclusion of revision operation P. 474-478

TIBIA

Chapter 13 Assessment of Tibial Nailing 479-504

Introduction P. 479-481
Few question before tibial nailing P. 482
Position of the leg P. 483-484
Entry hole in proximal Tibia P. 485
Conventional reaming P. 486-490
Consensus of reaming of distal fragment P. 491-492

Consensus of distal locking, static and dynamic P. 493
Steps to consider for tibial nailing P. 494

Author's Preferred Method of Nailing (Considering 7 Steps)

After cleaning the leg in supine position:
1. Position of the leg on wedge P. 495
2. Incision for entry hole in proximal tibia P. 496
3. Entry hole in proximal tibia with solid awl P. 497-498
4. Technique of bending tip of guidewire P. 499
5. Rotation of the wire inside tibia P. 500, Fig. 47
6. Reaming technique, up to fracture site P. 500, Figs. 48, 49
   holding the wire in position during reaming P. 500, Fig. 48B
7. Some aspects to consider during reaming P. 501
8. Accurate measurement of nail P. 503

Chapter 14 Tibial Nailing Using Conventional Nail: Steps of Author's Technique 505-537

Mid shaft, Transverse Fracture of Tibia using Conventional Nail

Case 14.1, Transverse fracture

Position of the leg P. 506, Fig. 2
Incision for entry hole P. 506, Fig. 3
Entry hole P. 506, Figs. 4 to 6
Rotation of the guidewire in tibia and technique of holding it in position P. 506, Figs. 7 and 8
Reduction of the fracture P. 507, Figs. 9 and 10
Insertion of exchange tube up to bent part of the wire P. 507, Fig. 11
Technique of exchange of bent tip guidewire with straight wire P. 507, Figs. 12 and 13
Accurate measure of nail P. 508, Fig. 14
Reaming the distal tibia over straight wire P. 508, Figs. 15 and 16
Steps of insertion of nail P. 509, Figs. 17 and 18
Proximal and distal locking screw P. 509, Figs. 19 and 20
Comparing position of the guidewire in proximal tibia, conventional versus author's method P. 510, Figs. 21-22

Distal 1/3rd, Spiral Fracture of Tibia using Conventional Nail

Case 14.2 Nailing was done following similar steps as mid shaft fracture of tibia P. 512-516

Case 14.3 Nailing of spiral fracture of distal tibia with Intra-articular involvement of fracture posterior malleolus, using conventional nail, following similar steps as mid shaft fracture P. 517-521, Fig. 1

Position of the leg, supine P. 518, Fig. 2
Incision and entry hole P. 518, Figs. 3 to 5
Insertion of bent guidewire in proximal fragment P. 518, Fig. 6
Rotating the guidewire in side tibia P. 518, Fig. 7
Steps of reaming proximal 2/3rd of tibia P. 519, Fig. 8
Technique of holding the bent guidewire in position P. 519, Fig. 8C
Reduction of the fracture posterior malleolus P. 519, Figs. 9 and 10
Technique of insertion of bent guidewire in distal 1/3rd of the tibia P. 520, Fig. 12
Insertion of exchange tube up to bent part of the guidewire P. 520, Fig. 13
Technique of exchange of bent tip guidewire with straight wire P. 520, Figs. 14 and 15
Accurate measurement of nail P. 521, Fig. 16
Technique of reaming the distal 1/3rd of tibia P. 521. Fig. 17
Insertion of the nail in distal tibia P. 521, Fig. 18

Distal 1/3rd, Spiral Fracture of Tibia with Butterfly Segment using Conventional Nail

Case 14.4 P. 523-530

Showing the medial and anterior curvature of the tibia P. 524, Fig. 2
Position of the leg P. 525, Fig. 3
Insertion of Steinman pin through os calcis for skeletal traction P. 525, Figs. 3 and 4
Position of leg in wedge P. 525, Fig. 5
Reduction of fracture and application of bone clip P. 525, Figs. 6 and 7
Incision and entry hole P. 525, Figs. 8 and 9
Insertion of bent part of the wire in proximal tibia P. 526, Fig. 10
Rotation of the guidewire inside the tibia P. 526, Fig. 11
Steps of reaming proximal 1/2 of tibia P. 526, Fig. 12
Technique of holding the bent guidewire in position P. 526, Fig. 12B
Technique of exchange of reamer with exchange tube P. 526, Fig. 13
Insertion of bent part of the guidewire in distal tibia P. 526-527, Figs. 14 and 15
Insertion of exchange tube in distal tibia P. 527, Fig. 16
Accurate measurement of nail P. 527, Fig. 17
Removal of exchange tube from distal tibia P. 527, Figs. 18 and 19
Steps of insertion of nail P. 528, Figs. 20 and 21
Proximal and distal locking screw P. 528, Fig. 22

Delayed Union of Distal 1/3rd Fracture of a Patient with Myasthenia Gravis

Case 14.5 **P. 531-537**

Nailing of fracture, using conventional nail, following the similar steps in Case 2 with special attention to changing the malposition of straight guidewire in ideal position with bent wire in distal tibia P. 533-535

Chapter 15 Halder Tibial Nail 538-556

Mid Shaft of Tibial Fracture, Transverse, Spiral and Oblique Fracture Treated with Halder Tibial Nail

Case15.1 Mid Shaft Transverse Fracture

Position of the leg
Incision for entry hole
Entry hole
Steps of reaming proximal 1/2 of tibia
Technique of holding the bent guidewire in position
Reaming the anterior cortex of proximal segment of tibia
— as in P. 506-507

Reduction of the fracture P. 541, Fig. 3
Technique of insertion of bent guidewire through the reamer in distal 1/3rd of the tibia P. 541, Figs. 4 and 5
Technique of exchange of bent tip guidewire with straight wire through the reamer P. 542, Fig. 6
Reaming the distal 1/3rd of the tibia P. 542, Fig. 7
Accurate measure of nail P. 503
Steps of insertion of nail up to fracture P. 542, Fig. 9
through the fracture into distal 1/3rd of tibia P. 543, Figs. 10 and 11
Insertion of 'Trio wire' P. 543, Fig. 12
Proximal locking screw P. 543, Fig. 12C

Following Cases were Fixed with Halder Tibial Nail in Similar Way

Case 15.2
Oblique mid shaft fracture of tibia P. 545-546

Case 15.3
Comminuted mid shaft fracture of tibia P. 547-550

Case 15.4
Spiral mid shaft fracture of tibia P. 551-552

Case 15.5
Short oblique mid shaft fracture of tibia P. 553-554

Case 15.6
Transverse mid shaft fracture of tibia P. 555-556

Chapter 16 Distal 1/3rd of Tibial Fractures
Cases 16.1–16.16 557-595

Introduction **P. 557**

Case 16.1 **P. 558-595**

Position of the leg
Incision for entry hole
Entry hole
Steps of reaming proximal 1/2 of tibia
Technique of holding the bent guidewire in position
Reaming the anterior cortex of tibia up to the fracture
— as in P. 506-507

Reduction of the fracture P. 559, Fig. 6
Technique of insertion of bent guidewire in distal 1/3rd of the tibia P. 559, Fig. 6
Technique of removal of the reamer, leaving guidewire *in situ* P. 559, Fig. 7
Insertion of exchange tube in distal tibia over the guidewire P. 560, Fig. 8
Technique of removal bent guidewire leaving exchange tube *in situ* P. 560, Fig. 9
Insertion of straight wire in distal tibia through the exchange tube P. 560, Fig. 10
Reaming the distal 1/3rd of the tibia P. 560, Fig. 11
Remove the reamer, leaving the guidewire in distal tibia P. 560, Fig. 12
Accurate measure of nail P. 503
Steps of insertion of nail up to fracture P. 560, Fig. 13
through the fracture into distal 1/3rd of tibia P. 560, Figs. 14 and 15
Insertion of 'Trio wire' P. 561, Fig. 17
Proximal locking screw P. 561, Fig. 18

Chapter 17 Periarticular Fractures of the Distal End of Tibia 596-635

Introduction **P. 596**

Case17.1 (treated with frame) P. 597-598

Case17.2 Spiral fracture, P. 600-602
Position of the leg initially supine P. 600, Fig. 2

1st, reduction and stabilization of fracture, lateral malleolus with 'Rush nail' P. 600, Fig. 3

Next,
Position of the leg on 'Wedge' with flexion of the knee
Incision for entry hole
Insertion of bent guidewire in proximal 2/3rd of tibia — as in P. 506-507
Steps of reaming of posterior cortex of proximal 3/4th of tibia
Technique of holding the bent guidewire in position
Reduction of the fracture — P. 600, Fig. 6
Positioning the bent tip wire in right direction in distal tibia — P. 600, Figs. 6 and 7
Technique of exchange of bent guidewire with straight one through the reamer in distal tibia — P. 601, Figs. 8 and 9
Reaming the distal tibia over straight wire — P. 601, Fig. 10
Accurate measure of nail as in — P. 504
Steps of insertion of nail — P. 601, Figs. 11 to 13
Insertion of 'Trio wire' — P. 601, Figs. 14A and B
Proximal locking screw — P. 601, Fig. 14C

Following Cases were Treated with Halder Tibial Nail in Similar Way as Described in Case 17.2

Case 17.3
Spiral fracture of tibia, without using Rush nail — P. 603-604

Case 17.4
Transverse fracture of tibia, plate on lateral malleolus — P. 605-606

Case 17.5
Transverse fracture of tibia, without using Rush nail — P. 607-609

Case 17.6
Spiral fracture of tibia, without using Rush nail — P. 610-611

Case 17.7
Oblique fracture of tibia, without using Rush nail — P. 612

Case 17.8
Transvers fracture of tibia, without using Rush nail — P. 613-614

Case 17.9
Transvers fracture of tibia, without using Rush nail — P. 615-617

Case 17.10, Comminuted Intra-articular Fracture — **P. 618-622**

Position of the leg initially supine
1st, reduction and stabilization of fracture lateral malleolus with 'Rush nail' — as in P. 600
Then, displaced intra-articular fracture was reduced and fixed with a lag screw — P. 619, Fig. 3
Position of the leg on 'Wedge' with flexion of the knee — P. 619, Fig. 3 as in P. 495
Incision for entry hole — P. 619, Fig. 31 as in P. 496
Insertion of bent guidewire in proximal 3/4th of tibia — P. 619. Fig. 4
Rotation of the guidewire to place on anterior cortex of tibia — P. 619, Fig. 5
Steps of reaming of posterior cortex of proximal 3/4th of tibia — P. 619, Fig. 6
Technique of exchange of the reamer with exchange tube — P. 619, Fig. 7
Exchange tube was inserted in distal tibia over the guidewire — P. 620, Figs. 8 and 9
Technique of removal bent guidewire leaving exchange *in situ* — P. 620, Fig. 10
Insertion of guidewire through the exchange tube — P. 620, Fig. 11
Technique of removal of exchange tube leaving straight wire *in situ* — P. 621, Fig. 12
Accurate measure of nail — P. 503
Steps of insertion of nail over the guidewire — P. 621, Fig. 13
Insertion of 'Trio wire' — P. 621, Fig. 14
Proximal locking screw — P. 621, Fig. 15

Following Cases of Intra-articular Fracture were Fixed with Halder Tibial Nail in Similar Way as Described in Case 17.10

Case 17.11
Comminute fracture of tibia using Rush nail — P. 621-625

Case 17.12
Comminute fracture of tibia without using Rush nail — P. 626-628

Case 17.13
Comminute fracture of tibia using Rush nail and lag screw — P. 629-631

Case 17.14
Comminute fracture of tibia, without using Rush nail — P. 632- 634

Chapter 18 Proximal Tibial Fracture
Cases 18.1–18.2 636-644

Case 18.1, Treated, using conventional Tibial nail — **P. 637-642**
Position leg on 'Wedge' with flexion of the knee — P. 638, Fig. 2
Position of the fracture on 'Wedge' — P. 638, Fig. 3
Reduction of fracture with strapping leg with wedge — P. 638, Fig. 4
Incision and entry hole in proximal tibia — P. 638, Figs. 5 and 6

Insertion of the bent guidewire in proximal tibia P. 638, Fig. 7
Insertion of the bent guidewire in distal tibia P. 638, Fig. 8
Rotation of tip of guidewire P. 639, Fig. 9
Steps of reaming distal 3/4th of tibia P. 639, Fig. 10
Insertion of exchange tube up to bent part of the wire P. 640, Fig. 11
Technique of removal of bent tip guidewire leaving exchange tube *in situ* P. 640, Fig. 12
Insertion of straight guidewire in distal tibia through exchange tube P. 640, Fig. 13
Accurate measurement of nail P. 640, Fig. 14
Steps of insertion of nail, 1st up to the fracture P. 640, Fig. 15
then through the fracture into distal tibia P. 641, Fig. 16
Proximal and distal locking screw P. 641, Fig. 17

Case 18.2 **P. 644-645**
Was treated with conventional tibial nail in similar way as described in Case 18.1 P. 639-641

Chapter 19 Segmental Fracture of Tibia
Cases 19.1–19.6 645-665

Case 19.1, Treated, using Halder Tibial nail **P. 646-650**
Preoperative X-ray of tibia P. 647, Fig. 3
Position of leg on 'Wedge' with flexion of the knee P. 647, Fig. 4
Reduction of fracture with strapping leg with wedge P. 647, Fig. 5
Incision in proximal tibia P. 647, Fig. 5
Entry hole in proximal tibia P. 647, Fig. 6
Insertion of the bent guidewire up to the fracture P. 647, Fig. 7
Insertion of the bent guidewire through middle segment P. 647, Fig. 8
Stabilized the middle segment with a bone clamp through two stab incisions P. 648, Fig. 9
Rotation of tip of guidewire P. 648, Fig. 10
Steps of reaming through the middle segment of tibia P. 648, Fig. 11
Positioning the guidewire in distal tibia P. 648, Fig. 12
Technique of removal of bent tip guidewire leaving reamer *in situ* P. 648, Fig. 13A
Insertion of straight guidewire in distal tibia through reamer P. 648, Fig. 13B
Reaming the distal tibia through the middle segment P. 648, Fig. 14
Accurate measurement of nail P. 503
Steps of insertion of nail, 1st up to the fracture P. 649, Fig. 15
then through the fracture into distal tibia P. 649, Fig. 16
Removal of straight guidewire P. 649, Fig. 17
Insertion of 'Trio wire' P. 649, Fig. 18
Proximal locking screw P. 649, Fig. 18

Following Cases of Segmental Fracture were Treated with Halder Tibial Nail in Similar Way as Described in Case 19.1, P. 646-650

Case 19.2
Proximal and mid shaft of tibia P. 651-652

Case 19.3
Mid and distal shaft of tibia P. 653-656

Case 19.4
Mid and distal shaft of tibia P. 657-660

Case 19.5
Mid and distal shaft of tibia P. 661-663

Case 19.6
Proximal shaft of tibia P. 664-665

Chapter 20 Complex Fracture of Tibia 666-683

Case 20.1
Comminuted fracture of distal 1/3rd of tibia treated with exterior fixator P. 667-668

Case 20.2–20.8: These Complex Tibial Fractures were Treated with Halder Tibial Nail in Similar Way as Described **P. 669-683**
in Case 15.1, P. 540-543
in Case 16.1, P. 558-561

Case 20.2
Compound comminuted fracture of distal 1/3rd of tibia P. 669-670

Case 20.3
Comminuted fracture of distal 1/3rd of tibia P. 671-673

Case 20.4
Segmental fracture of distal 1/3rd of tibia P. 674-675

Case 20.5
Comminuted intra-articular fracture of distal 1/3rd of tibia P. 676-677

Case 20.6
Comminuted fracture of distal 1/3rd of tibia P. 678-679

Case 20.7
Comminuted fracture of distal 1/3rd of tibia P. 680-681

Case 20.8
Comminuted fracture of distal 1/3rd of tibia P. 682-683

Chapter 21 Nonunion Fracture of Tibia
Cases 21.1–21.3 684-694

Description of Case 21.3 using Halder Tibial Nail

After cleaning the leg in supine position:
Position of the leg on wedge
Incision for entry hole in proximal tibia
Entry hole in proximal tibia with solid awl — as in P. 506-507
Technique of bending tip of guidewire
Rotation of the wire inside tibia
Reaming technique, up to fracture site
holding the wire in position during reaming
Bent guidewire was removed — P. 692, Fig. 8
Prepared sharp cut bent tip wire — P. 692, Fig. 9A
Insertion of sharp cut guidewire in lateral side of distal tibia — P. 692, Fig. 9B
Reaming the distal tibia over sharp cut guidewire — P. 692, Fig. 10A
Technique of exchange of sharp cut bent tip guidewire with straight ball tip wire — P. 692, Figs. 10B and 11
Accurate measurement of nail as in — P. 503
Steps of insertion of nail, up to nonunion site — P. 693, Fig. 12
then through nonunion — P. 693, Fig. 13
Ball tip guidewire removed — P. 693, Fig. 13
Insertion of 'Trio wire' — P. 693, Fig. 14
Insertion of proximal locking screw — P. 693, Fig. 15

Cases 21.1 and 21.2 were Treated with Halder Tibial Nail in Similar Way as Described in Case 21.3, P. 692-693

Chapter 22 Revision for Nonunion of Tibial Fracture
Cases 22.1–22.11 695-743

Case 22.1
Mid shaft nonunion of tibia
(as described in Case 22.2, P. 702-705) — P. 697-698

Case 22.2 — P. 699-707
Using Conventional Tibial Nail
After cleaning the leg in supine position
Position of the leg initially supine
Position of leg on 'Wedge' with flexion of the knee — as in P. 506-507
Incision for entry hole
Entry hole
Removal of nail — P. 703, Fig. 10
Close reduction of nonunion — P. 703, Fig. 11A
Prepare sharp cut guidewire — P. 703, Fig. 11B
Steps of insertion of sharp cut bent tip wire up to nonunion — P. 703, Fig. 12
then into distal tibia — P. 703, Fig. 13
further advancement into distal tibia — P. 704, Fig. 14A
Reaming the distal tibia over sharp cut guidewire — P. 704, Fig. 14
Exchange of reamer with an exchange tube — P. 704, Fig. 15
Technique of removal of sharp cut bent tip guidewire leaving exchange tube *in situ* — P. 704, Fig. 16
Insertion of straight sharp cut guidewire — P. 704, Fig. 17
Reaming the distal tibia over straight wire — P. 704, Fig. 18
Exchange the reamer with an exchange tube then remove the wire — P. 704, Fig. 19
Insertion of straight guidewire in distal tibia through exchange tube — P. 704, Fig. 20
Accurate measurement of nail as in — P. 503
Steps of insertion of nail, up to the nonunion — P. 705, Fig. 21
then through the nonunion into distal tibia — P. 705, Figs. 22 and 23
Proximal locking screw — P. 705, Fig. 24
Distal locking screw — P. 705 Fig. 25

Case 22.3, P. 708-713, Using Halder Tibial Nail

After cleaning the leg in supine position:
Position of the leg Initially supine
Position leg on 'Wedge' with flexion of the knee — P. 709, (as in P. 496-501)
Entry hole
Removal of nail — P. 709, Fig. 4
Repositioning the leg after removal wedge — P. 709, Fig. 5
Close reduction of nonunion of fibula — P. 709, Fig. 5
Insertion of Rush nail for fracture fibula (P. 601, 620) — P. 709, Fig. 5
Prepare sharp cut guidewire — P. 709, Fig. 6
Reposition the leg on wedge — P. 709, Fig. 7
Steps of insertion of sharp cut bent tip wire up to nonunion — P. 709, Fig. 7
then into distal tibia — P. 709, Fig. 8

further advancement into distal tibia P. 710, Figs. 9 and 10
Reaming the distal tibia over sharp cut guidewire P. 710, Fig. 11
Exchange the reamer with an exchange tube, then remove the wire P. 710, Fig. 12
Insertion of straight guidewire in distal tibia through exchange tube P. 711, Fig. 13
Accurate measurement of nail as in P. 504, 711, Fig. 14
Steps of insertion of nail, up to the nonunion P. 711, Fig. 15
then through the nonunion into distal tibia P. 711, Fig. 16
'Trio wore' distal locking P. 712, Fig. 17
Proximal locking screw P. 712, Fig. 18

Following Cases of Nonunion, Initially Treated with Various Method, Revised with Halder Tibial Nail in Similar Way as Described in Case 22.2, P. 699-707

Case 22.3 P. 710-713

Case 22.4
Distal 1/3rd, revision of exterior fixator P. 714-717

Case 22.5
Distal 1/3rd, revision of plate with Rush nail in lateral malleolus P. 718-721

Case 22.6
Distal 1/3rd revision of plate with Rush nail in lateral malleolus P. 722-724

Case 22.7
Distal 1/3rd revision of exterior fixator P. 725-727

Case 22.8
Distal 1/3rd revision of tibial nail with another nail and also insertion of Rush nail in lateral malleolus P. 728-731

Case 22.9
Distal 1/3rd revision of convention nail P. 732-733

Case 22.10
Nonunion of distal 1/3rd of tibia P. 734-739

Case 22.11
Nonunion of distal 1/3rd of tibia P. 740-743

Volume 2

SECTION 2 UPPER LIMB

Chapter 23 Humeral Fracture.....747-794

Introduction
Fractures of humerus at different level P. 748
Nonunion of humerus at different level P. 749
Osteolytic lesions of humerus at different levels P. 750

Humeral nail
Conventional, Antegrade and retrograde P. 751
Halder Humeral Nail (Retrograde)
Description of the implant P. 752
Approach: conventional, Retrograde P. 753
Modified retrograde approach (Halder) P. 754-755
Classification of fracture of humerus Halder modification P. 756-758
Steps of the modified retrograde approach (Halder)
Preparation for the operation:
1. Table P. 760
2. Position of the patient P. 761
3. Position of the 'C'arm P. 762
4. Assembling the implant with instrument P. 763-764

Description of the Operative Technique, step by step P. 766-780
Two part fracture of the humerus P. 766-767
Position of the patient P. 768
Application of towel for traction P. 768
Position of hands for reducing the fracture P. 769
Draping P. 770
Exposure of the olecranon fossa P. 771
Entry hole in supraolecranon area P. 772
Technique of cutting the guidewire P. 773
Insertion of guidewire in humerus and reaming P. 774

Reduction of the fracture P. 775-776
Insertion of bent tip guidewire in the head of the humerus P. 777
Exchange of bent wire with a straight wire P. 778
Measurement of the nail P. 779, Fig. 28
Insertion of the nail inside the entry hole P. 779, Fig. 29
Insertion of the nail up to the fracture P. 780, Fig. 30A
inside the head of the humerus P. 780, Fig. 30B
Insertion of the Trio wire P. 780, Fig. 30C
Insertion of the distal locking screw P. 780, Fig. 31 C
Insertion of the stopper P. 780, Fig. 31A
Clinical picture of the exposure of the elbow P. 781
X-ray of humerus after fixation P. 782

Salient Points to Remember during Operation

1. Transferring the patient from ward to theater P. 783
2. Attention to entry hole during reaming P. 785-786
3. Technique of exchange of bent guidewire with straight wire P. 787
4. Attention to fracture of the head of the humerus during reaming P. 787
5. Attention to the fracture during insertion of the nail P. 789
6. Technique of cutting the Trio wire P. 790
7. Technique of insertion cut Trio wire P. 790-791
8. Position of 'C' arm during insertion of the proximal locking screw P. 792-793
9. Mistake during measurement of the nail P. 794
10. Accurate measurement of the nail P. 794

Chapter 24 Two Part Fractures of the Humerus
Cases 24.1–24.38 795-922

Following cases of displaced two part fracture were reduced with simple traction and manipulation and treated in a similar way with Halder humeral nail as described in Case 23.1, P. 766-782:

Case 24.1
Technique of reduction and fixation of displaced two part fracture P. 796-799

Case 24.2
Technique of reduction and fixation of displaced two part fracture P. 800-803

Case 24.4
Technique of reduction and fixation of displaced two part fracture P. 805

Case 24.5
Technique of reduction and fixation of displaced two part fracture P. 806

Case 24.6
Technique of reduction and fixation of displaced two part fracture P. 807-811

Case 24.7
Technique of reduction and fixation of displaced two part fracture P. 812-815

Case 24.8
Technique of reduction and fixation of displaced two part fracture P. 816-819

Case 24.9
Technique of reduction and fixation of displaced two part fracture P. 820-822

Case 24.10
Technique of reduction and fixation of displaced two part fracture P. 823-826

Case 24.11
Technique of reduction and fixation of displaced two part fracture P. 827-830

Case 24.12
Technique of reduction and fixation of displaced two part fracture P. 831- 834

Case 24.13
Technique of reduction and fixation of displaced two part fracture P. 835- 839

Case 24.14
Technique of reduction and fixation of displaced two part fracture P. 840- 843

Case 24.15
Technique of reduction and fixation of displaced two part fracture P. 844-846

Reduction of Displaced Two Part Fracture using 'Joystick', 'Threaded Guidewire' Cases 24.16–24.22, P. 847-872

Description of Operation of Case 24.16, P. 848–852

Using 'threaded guidewire'

Position of the patient
Application of towel for traction
Position of hands for reducing the fracture — P. 848-850
Draping
Exposure of the olecranon fossa — (As described in
Entry hole in supraolecranon area — P. 768-774)
Technique of cutting the guidewire
Insertion of guidewire in humerus and reaming up to fracture site

Reduction:

Insertion of Joystick — P. 850, Figs. 9 and 10A
Maneuver of Joystick — P. 851, Fig. 10B and 11A and B
Insertion of bent tip guidewire in the head of the humerus — P. 851, Fig. 12
Measurement of nail — P. 851, Fig. 13
Reaming the head of the humerus — P. 851, Fig. 14
Insertion of the nail in the head on the humerus — P. 851, Fig. 15
Insertion of the Trio wire and proximal locking screw — P. 851, Fig. 16

Following cases of displaced two part fracture were reduced with 'Joystick threaded guidewire' and treated in a similar way with Halder humeral nail as described in Case 24.16, P. 847-852:

Case 24.17
Technique of reduction by threaded wire and fixation of two part fracture — P. 853-855

Case 24.18
Technique of reduction by threaded wire and fixation of two part fracture — P. 856-859

Case 24.19
Technique of reduction by threaded wire and fixation of two part fracture — P. 860-863

Case 24.20
Technique of reduction by threaded wire and fixation of two part fracture — P. 864-867

Case 24.21
Technique of reduction by threaded wire and fixation of two part fracture — P. 868-871

Case 24.22
Reduction by threaded wire and fixation of two part fracture — P. 872

Reduction of Displaced Two Part Fracture using Joystick, 'Lever' Case 24.23–24.26, P. 873-890

Description of Operation of Case 24.23, Using 'Lever' — **P. 874-877**

Position of the patient
Application of towel for traction — P. 874-875
Position of hands for reducing the fracture — (As described
Draping — in P. 765-775)
Exposure of the olecranon fossa
Entry hole in supraolecranon area
Technique of cutting the guidewire
Insertion of guidewire in humerus and reaming up to fracture site
Exchange of reamer with exchange tube — P. 875, Fig. 4

Reduction:

Incision of shoulder for lever — P. 875, Fig. 5
Insertion of Joystick — P. 875, Fig. 6
Reduction of fracture with lever — P. 875, Fig. 7
Rotation of tip of the guidewire — P. 875, Figs. 6 and 7
Insertion of bent tip guidewire in the head of the humerus — P. 875, Fig. 7
Insertion of exchange tube in the head of humerus — P. 875, Fig. 8A
Removal of bent guidewire, leaving exchange tube *in situ* — P. 875, Fig. 8A
Insertion of straight guidewire in head of humerus — P. 875, Fig. 8B
Measurement of the nail — P. 876, Fig. 9
Advancement of guidewire in subchondral bone — P. 876, Fig. 10
Removal of exchange tube — P. 876, Fig. 11A
Insertion of the nail up to the fracture — P. 876, Fig. 11B
then inside the head of the humerus — P. 876, Fig. 11C
Insertion of the Trio wire — P. 876, Fig. 12A
Insertion of the proximal locking screw — P. 876, Fig. 12B
Insertion of the distal locking screw — P. 876, Fig. 12C

Following Cases of Displaced Two Part Fracture were reduced with 'Joystick lever' and treated in a similar way with Halder humeral nail as described in Case 24.23, P. 874-877:

Case 24.24
Technique of reduction, using lever and fixation of two part fracture — P. 878-882

Case 24.25
Technique of reduction, using lever and fixation of two part fracture — P. 883-886

Case 24.26
Technique of reduction, using lever and fixation of two part fracture — P. 887-890

Reduction of Displaced Two Part Fracture, using Threaded Guidewire and Lever Together

Cases 24.27 and 24.28 — **P. 891-899**
Technique of reduction, using lever and threaded wire fixation two part fracture — P. 891-899

Description of Operation of Case 24.27 — **P. 893–896**

Using 'Guidewire and Lever' Together

Position of the patient — P. 893
Application of towel for traction — P. 893
Position of hands for reducing the fracture — P. 893
Draping — (As described in P. 771-772)
Exposure of the olecranon fossa — (As described in P. 768-775)
Entry hole in Supra plicranon area — (As described in P. 768-775)
Technique of cutting the guidewire — (As described in P. 768-775)
Insertion of guidewire in humerus and reaming up to fracture site — (As described in P. 768-775)
Exchange of reamer with exchange tube — P. 893, Fig. 4

Reduction:
Failure of closed reduction — P. 893, Fig. 5
Incision of shoulder for lever — P. 893, Fig. 6
Insertion of lever — P. 893, Fig. 7
Reposition of the lever — P. 893, Fig. 8
Insertion of threaded guidewire — P. 893, Fig. 9A
Reduction of fracture with lever and guidewire — P. 893, Figs. 9B and C
Insertion of bent tip guidewire in the head of the humerus — P. 894, Fig. 10
Insertion of exchange tube in the head of the humerus — P. 894, Fig. 11
Removal of bent guidewire — P. 894, Fig. 12
Insertion of straight guidewire in the head of the humerus — P. 894, Fig. 13
Measurement of the nail — P. 894, Fig. 14
Removal of exchange of tube and insertion of the nail up to the fracture — P. 894, Fig. 15A
then inside the head of humerus — P. 894, Fig. 15B
Insertion of the Trio wire — P. 894, Fig. 16A
Insertion of proximal locking screw — P. 894, Fig. 16B
Insertion of distal locking screw — P. 894, Fig. 17

Case 24.28 was reduced and fixed in similar was as described in Case 24.27

Some Examples of Complicated two part fracture

Cases 24.29–24.34 — P. 900-913

Following Complicated Fractures were Reduce and Fixed in a Similar Way as Described in Case 24.1, P. 766-780

Case 24.29
Close reduction of the fracture — P. 900-901

Case 24.30
Close reduction of the fracture — P. 902-903

Case 24.31
Close reduction of the fracture — P. 904-906

Case 24.32
Close reduction of the fracture — P. 907-909

Case 24.33
Close reduction of the fracture — P. 910-911

Case 24.34
Close reduction of the fracture — P. 912-913

Fracture Neck of Humerus in Adolescent

Cases 24.35–24. 38 — P. 914-921

Case 24.35
Failure of K-wire fixation — P. 915-916

Case 24.36
Failure of K-wire fixation, revision with Halder humerus nail — P. 917-919

Case 24.37
Failure of K-wire fixation, revision with Halder humerus nail — P. 920

Case 24.38
Primary fixation with Halder humerus nail — P. 921-922

Chapter 25 Three Part Fractures of the Humerus
Cases 25.1–25.16 923-992

Case 25.1 P. 923-928

Without Fixing Fracture Greater Tuberosity

Position of the patient
Application of towel for traction
Position of hands for reducing the fracture
Draping
Exposure of the olecranon fossa
Entry hole in Supraolecranon area
Technique of cutting the guidewire
Insertion of guidewire in humerus and reaming up to fracture site
— P. 925 (As described in P. 779-775)

Reduction:

Failure of closed reduction — P. 925, Fig. 4
Incision of shoulder for lever — P. 925, Fig. 5A
Reduction of fracture with the lever — P. 925, Fig. 5B
Insertion of threaded guidewire — P. 925, Fig. 6A
Reduction of rotation of head of humerus with guidewire — P. 925, Fig. 6B
Insertion of bent tip guidewire in the head of the humerus — P. 925, Fig. 7A
Removal of guidewire as was not in right position in the head — P. 925, Fig. 7B
Reinsertion of bent tip guidewire in the head of the humerus — P. 925, Fig. 8A
Removal of reamer — P. 926, Fig. 8B
Reaming the neck of the humerus conical reamer — P. 926, Figs. 9 and 10A
Removal of bent guidewire — P. 926, Fig. 10B
Insertion of straight guidewire in the head of the humerus — P. 926, Fig. 11
Measurement of the nail — P. 926, Fig. 12
Removal of conical reamer and insertion of the nail up to the fracture then inside the head of the humerus — P. 926, Fig. 13A
Insertion of the Trio wire — P. 926, Fig. 13B
Insertion of proximal locking screw — P. 926, Fig. 16C
One mistake during fixation — P. 927-928

Following cases of undisplaced three part fracture were reduced with 'Joystick method' and fixed in a similar way as described in case a Case 25.1, P. 925-928:

Case 25.2
Technique of reduction, using lever and fixation of three part fracture — P. 929-932

Case 25.3
Technique of reduction, using lever and fixation of three part fracture — P. 933-936

Case 25.4
Technique of reduction, using lever and guidewire for fixation of three part fracture — P. 937-941

Three Part Fracture Neck of Humerus with Displaced Greater Tuberosity

Cases 25.5–25.16 **P. 942-992**

Case 25.5
Greater tuberosity was reduced by open method — P. 942-943
Reduction technique of fracture greater tuberosity in plastic bone — P. 944-947

Case 25.6
Practical demonstration of reduction and fixation of greater tuberosity — P. 950-955

Case 25.7
Practical demonstration of reduction and fixation of fragmented greater tuberosity — P. 956-959

Following Displaced Three Part Fractures were Reduced and Fixed in a Similar Way as Described in Case 25.6, P. 950-955

Case 25.8
Technique of reduction of greater tuberosity and fixation of three part fracture — P. 961-963

Case 25.9
Technique of reduction of greater tuberosity and fixation of three part fracture — P. 964-968

Case 25.10
Technique of reduction of greater tuberosity and fixation of three part fracture — P. 969-973

Case 25.11
Technique of reduction of greater tuberosity and fixation of three part fracture — P. 974-975

Case 25.12
Technique of reduction of greater tuberosity and fixation of three part fracture P. 976-979

Case 25.13
Technique of reduction of greater tuberosity and fixation of three part fracture P. 980-984

Case 25.14
Technique of reduction of greater tuberosity and fixation of three part fracture P. 985-986

Case 25.15
Technique of reduction of greater tuberosity and fixation of three part fracture P. 987-991

Case 25.16
Open reduction of fracture and fixation with plate P. 992

Chapter 26 Four Part Fractures of the Humerus
Cases 26.1–26.13 993-1037

Four Part Fractures of Humerus were Reduced and Fixed in a Similar Way as Described in Displaced Three Part Fracture, P. 942-992

Case 26.1
Technique of reduction of greater tuberosity using 'Hook' method P. 994-997

Case 26.2
Technique of reduction of fracture using 'lever' method P. 998-1001

Case 26.3
Technique of reduction of fracture using 'lever' method P. 1002-1005

Case 26.4
Technique of reduction of fracture using lever and hook P. 1006-1009

Case 26.5
Technique of reduction of fracture using lever P. 1010-1013

Case 26.6
Technique of reduction of fracture using hook P. 1015-1019

Case 26.7
Technique of reduction of fracture using only traction P. 1020-1023

Case 26.8
Technique of reduction of fracture using lever and hook P. 1024-1028

Case 26.9
Technique of reduction of fracture using lever and hook P. 1029-1030

Case 26.10
Technique of reduction of fracture using lever and hook P. 1031-1032

Case 26.11
Fracture similar as case 26.10, treated with hemiarthroplasty P. 1033

Case 26.12
Technique of reduction of fracture using lever and hook P. 1034-1035

Case 26.13
Technique of reduction of fracture using lever and hook P. 1036-1037

Chapter 27 Proximal Humeral Fracture
Cases 27.1–27.16 1038-1102

Proximal Humeral Fractures were reduced and fixed in a similar way as described in displaced two part fracture, P. 768-780

Case 27.1
Conservative treatment P. 1039-1037

Case 27.2
Technique of reduction and fixation of oblique fracture with traction P. 1041-1044

Case 27.3
Technique of reduction and fixation of spiral fracture with traction P. 1045-1048

Case 27.4
Technique of reduction and fixation of short oblique fracture with guidewire P. 1049-1053

Case 27.5
Technique of reduction of oblique fracture with lever P. 1054-1057

Case 27.6
Technique of reduction of transverse fracture with lever P. 1058-1062

Case 27.7
Technique of reduction of transverse fracture with guidewire P. 1063-1067

Case 27.8
Technique of reduction of transverse fracture with lever P. 1068-1071

Case 27.9
Technique of reduction of oblique fracture with lever P. 1072-1075

Case 27.10
Technique of reduction of short oblique fracture with lever P. 1076-1080

Case 27.11
Technique of reduction of short oblique fracture by open method P. 1081-1084

Case 27.12
Technique of reduction of spiral fracture by open method P. 1085-1087

Case 27.13
Technique of reduction of comminuted fracture by traction P. 1088-1089

Case 27.14
Technique of reduction of spiral fracture with butterfly segment by traction P. 1090-1093

Case 27.15
Technique of reduction of spiral comminuted fracture by traction P. 1094-1097

Case 27.16
Technique of reduction of spiral fracture with butterfly segment by traction P. 1098-1102

Chapter 28 Fracture of the Shaft of the Humerus
Cases 28.1–28.13 1103-1139

Fractures Shaft of Humerus were Reduced and Fixed in a similar way as Described in Displaced Two Part Fracture, P. 768-780

Case 28.1
Short oblique fracture with conservative treatment P. 1104-1105

Case 28.2
Spiral fracture with conservative treatment P. 1106

Case 28.3
Spiral fracture with conservative treatment P. 1107

Case 28.4
Technique of reduction of short oblique fracture by traction P. 1108-1113

Case 28.5
Technique of reduction of short oblique fracture by traction P. 1114-1115

Case 28.6
Treated spiral fracture with antegrade nail P. 1116-1117

Case 28.7
Technique of reduction of transverse fracture with butterfly segment by traction P. 1118-1121

Case 28.8
Technique of reduction of transverse fracture with angulation by traction P. 1122-1127

Case 28.9
Technique of reduction of short oblique fracture by traction P. 1128-1132

Case 28.10
Technique of reduction of long spiral fracture by open method P. 1133-1134

Case 28.11
Technique of reduction of transverse fracture by traction P. 1135

Case 28.12
Close reduction and fixation of transverse fracture with butterfly segment P. 1136

Case 28.13
Technique of reduction of short oblique fracture by traction P. 1137-1139

Chapter 29 Fracture of the Distal 1/3rd of the Humerus
Cases 29.1–29.24 1140-1218

Case 29.1
Fixation of distal 1/3rd fracture with plate and screws P. 1141, Fig. 1

Case 29.2
Similar fracture, 29.1, treated with Halder humeral nail P. 1141, Fig. 2

Case 29.3
Showing the rotational stability of distal humeral fracture with Halder humeral nail P. 1142

Technique of Reduction and Fixation of Distal 1/3rd Fracture with Traction and Keeping the Elbow in Flexed Position

Case 29.4 P. 1143-1144
Position of the elbow P. 1144, Fig. 2
Exposure of the olecranon fossa P. 1144, Fig. 2
Entry hole P. 1144, Fig. 2
Technique of reduction of the fracture, using mallet P. 1144, Fig. 3

Insertion of the bent tip guidewire P. 1144, Fig. 4
Reaming humerus, maintaining reduction P. 1144, Fig. 5
Reaming of the head of humerus, maintaining reduction P. 1144, Fig. 6
Measurement of the nail as in P. 794

Steps of Insertion of the Nail, Holding the Reduction with Traction

Up to the fracture, then through the fracture P. 1145, Fig. 7
Insertion of Trio wire P. 1145, Fig. 8
Insertion of distal screws P. 1145, Fig. 8

Following cases of distal 1/3rd humeral fracture were treated, keeping elbow in flex position as described in Case 29.4, P. 1143-1146

Case 29.5
Technique of reduction and fixation of spiral fracture by traction P. 1147-1149

Case 29.6
Technique of reduction and fixation of periprosthetic fracture after removal of antegrade nail P. 1150-1152

Case 29.7
Technique of reduction and Fixation of spiral fracture with a butterfly segment by traction P. 1153-1155

Case 29.8
Technique of reduction and fixation of periarticular spiral fracture with a butterfly segment by traction P. 1156-1160

Case 29.9
Technique of reduction and fixation of periarticular spiral fracture with a butterfly segment by traction P. 1161-1163

Technique of Reduction of Distal 1/3rd Fracture with Traction, Flexion of the Elbow and Hammer, Case 29.10, P. 1164-1168

Position of elbow P. 1165, Figs. 2 and 3
Exposure of the olecranon fossa P. 1165, Figs. 4 and 5
Entry hole P. 1165, Figs. 6 and 7
P. 1166, Fig. 8
Technique of reduction of the fracture, using mallet P. 1166, Figs. 9 and 10A
Insertion of bent tip guidewire P. 1166, Fig. 10B
Reaming humerus, maintaining reduction with mallet P. 1166, Fig. 11
Measurement of the nail P. 1167, Fig. 12

Steps of Insertion of the Nail, Holding the Reduction with Traction

1st up to the fracture P. 1167, Fig. 13A
Then through the fracture P. 1167, Fig. 13B
Insertion of Trio wire P. 1167, Fig. 14
Insertion of distal screws P. 1167, Fig. 15

Following Cases of Distal 1/3rd humeral fracture were treated using Mallet as described in Case 29.10, P. 1164-1168

Case 29.11
Technique of reduction and fixation of spiral fracture with a butterfly segment by using mallet and traction P. 1169-1172

Case 29.12
Technique of reduction and fixation of spiral fracture by using mallet and traction P. 1173-1177

Case 29.13
Technique of reduction and fixation of oblique fracture by using mallet and traction P. 1178-1180

Case 29.14
Technique of reduction and fixation of spiral fracture with a butterfly segment by using mallet and traction P. 1181-1184

Case 29.15
Technique of reduction and fixation of spiral fracture with a butterfly segment by using mallet and traction P. 1185-1188

Case 29.16
Technique of reduction and fixation of spiral fracture with a butterfly segment by using mallet and traction P. 1189-1192

Case 29.17
Technique of reduction and fixation of spiral fracture by using mallet and traction P. 1193-1195

Case 29.18
Technique of reduction and fixation of long spiral fracture with a butterfly segment by using mallet and traction P. 1196-1198

Case 29.19 **P. 1199-1204**
Open reduction of fracture, held with bone clamp
Secure the radial nerve
Position of the elbow and exposure of the olecranon fossa P. 1200, Figs. 3 and 4
Entry hole P. 1200, Figs. 5 to 7
Steps of exposure of the radial nerve P. 1201, Figs. 8 to 10
Exposure of the fracture, reduction and held with clamp P. 1202, Fig. 11
Insertion of bent tip guidewire P. 1202, Fig. 12

Reaming humerus up to neck maintaining reduction P. 1202, Fig. 13
Insertion of exchange tube up to neck of humerus P. 1202, Fig. 14
Exchange of bent tip guidewire with straight wire P. 1202, Figs. 15 and 16
Measurement of the nail as in P. 794

Steps of Insertion of the Nail, Holding the Reduction with Mallet

Up to fracture P. 1202, Fig. 17A
Then through the fracture P. 1202, Figs. 17B and C
Insertion of Trio wire and proximal locking screw P. 1203, Fig. 18
Insertion of distal screws P. 1203, Fig. 19
Clinical picture of elbow at the end of the operation P. 1203

Following cases of distal 1/3rd humeral fracture were treated after securing radial nerve as described in Case 29.19, P. 1199-1204

Case 29.20
Technique of open reduction and fixation of spiral fracture with butterfly segment after securing the radial nerve P. 1205-1208

Case 29.21
Technique of open reduction and fixation of spiral fracture with butterfly segment after securing the radial nerve P. 1209-1211

Case 29.22
Technique of open reduction and fixation of spiral fracture with butterfly segment after securing the radial nerve P. 1212-1214

Case 29.23
Technique of open reduction and fixation of long spiral fracture after securing radial nerve P. 1215-1217

Case 29.24
Technique of open reduction and fixation of long spiral fracture after securing the radial nerve P. 1218

Chapter 30 Complex Fracture of the Humerus
Cases 30.1–30.18 1219-1302

1. Fracture Around Head and Neck of the Humerus

Case 30.1
Technique of reduction and fixation as three part fracture with traction P. 1220-1223

Case 30.2
Technique of reduction as three part fracture with traction and guidewire P. 1225-1229

Case 30.3
Technique of reduction and fixation as three part fracture without opening greater tuberosity P. 1230-1234

Case 30.4
Technique of reduction and fixation as two part fracture with traction P. 1235-1241

Case 30.5
Technique of reduction and fixation as two part fracture with traction and lever P. 1242-1243

Case 30.6
Technique of reduction and fixation as two part fracture with traction and lever P. 1244-1247

Case 30.7
Technique of reduction and fixation as two part fracture with traction and lever P. 1248-1250

Case 30.8
Technique of reduction and fixation as three part fracture with lever but without opening greater tuberosity P. 1251-1255

Case 30.9
Technique of reduction and fixation as three part fracture with guidewire but without opening greater tuberosity P. 1256-1259

Case 30.9, Revision
Technique of re-reduction with guidewire and lever and fixation P. 1260-1263

Case 30.10
Technique of reduction and fixation as two part fracture with traction and guidewire P. 1264-1267

Case 30.11
Technique of reduction and fixation as two part fracture with traction and guidewire P. 1268-1272

Case 30.12
Technique of reduction and fixation as three part fracture with traction, lever and guidewire P. 1273-1277

Case 30.13
Technique of open reduction and fixation as two part fracture P. 1278-1280

2. Fracture Around Proximal End of the Humerus

Case 30.14
Technique of open reduction and fixation as two part fracture P. 1281-1286

Case 30.15
Technique of reduction of fracture with traction and fixation as proximal humeral fracture P. 1287-1289

Case 30.16
Technique of reduction of fracture with traction and fixation as proximal humeral fracture P. 1290-1293

Case 30.17
Technique of reduction of fracture with traction and fixation as proximal humeral fracture P. 1294-1297

3. Fracture Around Distal End of the Humerus

Case 30.18
Technique of reduction of fracture with traction and guidewire P. 1298-1302

Chapter 31 Nonunion Fracture of the Humerus
Cases 31.1–31.39 .....P. 1303-1430

Fracture Around Head and Neck of the Humerus

Cases 31.1 and 31.2
Result of conservative treatment P. 1304

Case 31.3
Technique of closed reduction with lever and fixation as two part fracture P. 1305-1308

Case 31.4
Technique of closed reduction with lever and fixation as two part fracture P. 1309-1312

Case 31.5
Technique of closed reduction with lever and guidewire and fixation as two part fracture P. 1313-1316

Case 31.6
Technique of open reduction and fixation as two part fracture P. 1317-1319

Case 31.7
Technique of closed reduction with lever and fixation as two part fracture P. 1320-1323

Case 31.8
Technique of closed reduction and fixation as two part fracture P. 1324-1326

Case 31.9
Technique of open reduction and fixation as two part fracture P. 1327-1329

Case 31.10
Technique of open reduction and fixation as two part fracture P. 1330-1331

Case 31.11
Technique of open reduction with osteotomy and fixation as two part fracture P. 1332-1335

Fracture Around Proximal Humerus

Case 31.12
Technique of open reduction with osteotomy and fixation as proximal humeral fracture P. 1336-1338

Case 31.13
Technique of closed reduction and fixation as proximal humeral fracture P. 1339-1341

Case 31.14
Technique of open reduction and fixation as proximal humeral fracture P. 1342-1345

Case 31.15
Technique of open reduction and fixation as proximal humeral fracture P. 1346-1348

Case 31.16
Technique of closed reduction, insertion sharp cut guidewire, ream and fixation as proximal humeral fracture P. 1349-1352

Case 31.17
Technique of closed reduction, insertion sharp cut guidewire, ream and fixation as proximal humeral fracture P. 1353-1355

Case 31.18
Technique of open reduction and fixation as proximal humeral fracture P. 1356-1358

Case 31.19
Technique of closed reduction, insertion sharp cut guidewire, ream and fixation as proximal humeral fracture P. 1359-1362

Case 31.20
Technique of closed reduction, insertion sharp cut guidewire, ream and fixation as proximal humeral fracture P. 1363-1366

Around Shaft of the Humerus

Case 31.21
Technique of closed reduction, insertion sharp cut guidewire, ream and fixation as proximal humeral fracture P. 1367-1370

Case 31.22
Technique of closed reduction, insertion sharp cut guidewire, ream and fixation as shaft humeral fracture P. 1371-1374

Case 31.23
Technique of closed reduction, insertion sharp cut guidewire, ream and fixation as shaft humeral fracture P. 1375-1378

Case 31.24
Technique of closed reduction, insertion sharp cut guidewire, ream and fixation as shaft humeral fracture P. 1379-1382

Case 31.25
Technique of closed revision with another nail as shaft humeral fracture P. 1383-1385

Case 31.26
Technique of closed reduction, insertion sharp cut guidewire, ream and fixation as shaft humeral fracture P. 1386-1388

Case 31.27
Technique of closed reduction, insertion sharp cut guidewire, ream and fixation as shaft humeral fracture P. 1389-1390

Fracture Around Distal Humerus

Case 31.28
Technique of closed reduction, insertion sharp cut guidewire, ream and fixation as shaft humeral fracture P. 1391-1394

Case 31.29
Technique of closed reduction, insertion sharp cut guidewire, ream and fixation as distal humeral fracture P. 1395-1398

Case 31.30
Technique of open reduction and fixation as distal humeral fracture P. 1399-1401

Case 31.31
Technique of revision of broken plate with nail as distal humeral fracture P. 1402-1405

Case 31.32
Technique of revision of plate with nail as distal humeral fracture P. 1406-1409

Case 31.33
Technique of revision of broken plate with nail as distal humeral fracture P. 1410-1412

Case 31.34
Technique of revision of elastic nail with retrograde nail as proximal humeral fracture P. 1413-1415

Case 31.35
Technique of closed revision of antegrade nail with a retrograde nail, as proximal humeral fracture P. 1416-1421

Case 31.36
Technique of closed revision of antegrade nail with a retrograde nail, as shaft humeral fracture P. 1422-1423

Case 31.37
Technique of closed revision of antegrade nail with a retrograde nail, as distal humeral fracture P. 1424

Case 31.38
Technique of closed revision of retrograde nail with a retrograde nail, as distal humeral fracture P. 1425-1427

Case 31.39
Technique of closed revision of retrograde nail with a retrograde nail, as distal humeral fracture P. 1428-1430

Chapter 32 Fracture and Dislocation of the Shoulder
Cases 32.1–32.12 1431-1483

Following cases of dislocation of shoulder with fracture greater tuberosity were reduced by closed method with 'Joystick' method and fixation with retrograde nail.

Case 32.1
Technique of closed reduction of anterior dislocation with 'Joystick' and fixation P. 1433-1437

Case 32.2
Technique of closed reduction of anterior dislocation with 'Joystick' and fixation P. 1438-1441

Case 32.3
Technique of closed reduction of anterior dislocation with 'Joystick' and fixation P. 1442-1445

Case 32.4
Technique of closed reduction of anterior dislocation with comminuted fracture of greater tuberosity and fixation P. 1446-1449

Case 32.5
Technique of closed reduction of inf. dislocation with split head using 'Joystick' and fixation P. 1450-1453

Case 32.6
Technique of closed reduction of inferior dislocation with split head using 'Joystick' and fixation P. 1454-1457

Case 32.7
Technique of closed reduction of anterior dislocation with extension of fracture to the shaft and fixation P. 1458-1460

Case 32.8
Technique of closed reduction of anterior dislocation with 'Joystick' and fixation P. 1461-1463

Case 32.9
Technique of closed reduction of anterior dislocation with 'Joystick' and fixation P. 1464-1467

Case 32.10
Technique of closed reduction of inferior dislocation with 'Joystick' and fixation P. 1468-1471

Case 32.11
Technique of closed reduction of bilateral dislocation with 'Joystick' and fixation P. 1472-1478, Case 32.7

Case 32.12
Technique of closed reduction of anterior dislocation with segmental fracture to the shaft and fixation P. 1479-1483

Chapter 33 Segmental Fracture of the Humerus
Cases 33.1–33.11 1484-1518

Following Cases of Segmental Fracture were Reduced by Closed Method and Fixation with Retrograde Nail

Case 33.1
Technique of closed reduction of segmental fracture of proximal humerus and fixation P. 1485-1488

Case 33.2
Technique of closed reduction of segmental fracture of proximal humerus and fixation P. 1489-1492

Case 33.3
Technique of closed reduction of segmental fracture of proximal and shaft of humerus and fixation P. 1493-1495

Case 33.4
Technique of closed reduction of segmental fracture of shaft of humerus and fixation P. 1496-1497

Case 33.5
Technique of closed reduction of segmental fracture of neck and shaft of humerus and fixation P. 1498

Case 33.6
Technique of closed reduction of segmental fracture of neck and shaft of humerus and fixation P. 1499

Case 33.7
Technique of closed reduction of segmental fracture of neck and shaft of humerus and fixation P. 1500-1501

Case 33.8
Technique of closed reduction of segmental fracture neck of three part and proximal humerus and fixation P. 1502-1505

Case 33.9
Technique of closed reduction of segmental fracture of proximal and shaft of humerus and fixation P. 1506-1509

Case 33.10
Technique of closed reduction of segmental fracture of proximal and shaft of humerus and fixation P. 1510-1512

Case 33.11
Technique of closed reduction of segmental fracture of proximal humerus and fixation P. 1513-1518

Chapter 34 Osteolytic Lesions of the Humerus
Cases 34.1–34.19 1519-1572

Case 34.1
Technique of fixation of fracture through lesion in proximal humerus P. 1520-1523

Case 34.2
Technique of fixation of lytic lesion in proximal humerus P. 1524- 1525

Case 34.3
Technique of fixation of fracture through the lesion in head and neck of humerus P. 1526-1529

Case 34.4 and 33.5, bilateral

Case 33.4 (Right)
Technique of fixation of fracture through the lesion in head and proximal humerus P. 1530-1533

Case 34.5 (Left)
Technique of fixation of fracture through the lesion in proximal and shaft of the humerus P. 1534-1535

Case 34.6
Technique of fixation of lytic lesion in surgical neck of humerus P. 1536-1538

Case 34.7
Technique of fixation of fracture through lesion in proximal humerus P. 1539-1540

Case 34.8
Technique of fixation of lesion in shaft of the humerus P. 1541-1542

Case 34.9
Technique of fixation of fracture through lesion in distal humerus (revision of plate fixation) P. 1543-1544

Case 34.10
Technique of fixation of fracture through multiple lytic lesions in whole of the humerus P. 1545-1547

Case 34.11
Technique of fixation of fracture through multiple lytic lesions in whole of the humerus P. 1548-1550

Case 34.12
Technique of fixation of multiple lytic lesions in whole of the humerus P. 1551-1553

Case 34.13
Technique of fixation of multiple lesion in head and shaft of the humerus P. 1554-1557

Cases 34.14 and 34.15, bilateral

Case 34.14 (Right)
Technique of fixation of multiple lesions in whole of the humerus P. 1558-1559

Case 34.15 (Left)
Technique of fixation of multiple lesions in whole of the humerus P. 1560

Case 34.16
Technique of fixation of fracture through lesion in distal and shaft of the humerus P. 1561-1564

Case 34.17
Technique of fixation of lesion in distal and shaft of the humerus P. 1565-1566

Case 34.18
Technique of fixation of fracture through the multiple lytic lesions in shaft and neck of humerus P. 1567-1568

Case 34.19
Technique of fixation of fracture through the multiple lytic lesions in shaft and neck of humerus P. 1569-1572

Volume 3

SECTION 3 MANAGEMENT OF HAND INJURY

Chapter 35 Management of Phalangeal Fracture
Cases 35.1–35.33 1575-1671

Case 35.1
Problem and difficulty for fixation in theater P. 1576-1577

Phalangeal Fractures

Middle Phalanx

Case 35.2
Technique of isolating the others fingers from operative field P. 1578-1579

Case 35.3
Technique of insertion of K-wire in distal phalanx for traction P. 1580-1583

Case 35.4
Technique of closed reduction of die-punch fracture and fixation P. 1584-1586

Case 35.5
Technique of closed reduction and fixation of fracture subluxation of PIP joint P. 1587-1589

Case 35.6
Technique of closed reduction of die-punch fracture and fixation P. 1590-1593

Case 35.7
Technique of closed reduction of die-punch fracture with subluxation and fixation P. 1594-1595

Case 35.8
Technique of closed reduction of die-punch fracture with subluxation and fixation P. 1596-1597

Case 35.9
Technique of closed reduction of die-punch fracture with volar subluxation and fixation P. 1598-1601

Case 35.10
Technique of closed reduction of die-punch fracture and fixation P. 1602-1603

Case 35.11
Technique of closed reduction of die-punch fracture and fixation P. 1604-1606

Case 35.12
Technique of closed reduction of die-punch fracture and fixation P. 1607-1609

Case 35.13
Technique of closed reduction of die-punch fracture and fixation P. 1610-1611

Case 35.14
Technique of closed reduction of die-punch fracture with dorsal subluxation and fixation P. 1612-1614

Case 35.15
Technique of closed reduction of die-punch fracture with dorsal subluxation and fixation P. 1615-1616

Cases 35.15 and 35.16 (Ring and Little Finger)

Case 35.15 (Ring Finger)
Technique of closed reduction of die-punch fracture and fixation P. 1617-1619

Case 35.16 (Little Finger)
Technique of closed reduction of die-punch fracture and fixation P. 1620-1621

Case 35.17
Technique of closed reduction of fracture neck of middle phalanx and fixation P. 1622

Case 35.18
Technique of closed reduction of fracture base of middle phalanx and fixation P. 1623-1624

Case 35.19
Technique of closed reduction of 'T' intra-articular fracture base of middle phalanx and fixation P. 1625-1626

Case 35.20
Technique of closed reduction of 'T' intra-articular fracture base of middle phalanx and fixation P. 1627-1629

Case 35.21
Technique of closed reduction of 'T' intra-articular fracture base of middle phalanx and fixation P. 1630-1632

Case 35.22
Technique of closed reduction of die-punch fracture with extension into shaft and fixation P. 1633-1635

Case 35.23
Technique of closed reduction of die-punch fracture with extension into shaft and fixation P. 1636-1639

Case 35.24
Technique of closed reduction of die-punch fracture with extension into shaft and fixation P. 1640-1641

Case 35.25
Technique of closed reduction of comminuted fracture of entire shaft and fixation P. 1642-1644

Case 35.26
Technique of closed reduction of comminuted fracture base of mid phalanx and fixation P. 1645-1648

Case 35.27
Technique of closed reduction of die-punch fracture with extension into shaft and fixation P. 1649-1652

Fracture Proximal Phalanx

Case 35.28
Technique of closed reduction of comminuted 'T' intra-articular fracture of distal end of middle phalanx and fixation P. 1653-1657

Case 35.29
Technique of closed reduction of comminuted 'T' fracture shaft of proximal phalanx and fixation P. 1658-1660

Case 35.30
Technique of closed reduction of comminuted 'T' fracture base of proximal phalanx and fixation P. 1661-1662

Case 35.31
Technique of closed reduction of comminuted 'T' fracture base of proximal phalanx and fixation P. 1663-1664

Case 35.32
Technique of closed reduction of comminuted 'T' intra-articular fracture of base of proximal phalanx and fixation P. 1665-1667

Case 35.33
Technique of closed reduction of comminuted 'T' intra-articular fracture of base of proximal phalanx and fixation P. 1668-1670

Postoperative Management P. 1671

Chapter 36 Management of Metacarpal Fracture
Cases 36.1–36.28 1672-1746

Spiral/Oblique Fracture Neck of 5th Metacarpal

Case 36.1
Result of conservative treatment of displaced fracture P. 1673

Case 36.2
Plating of the fracture P. 1674-1675

Case 36.3
Treated with antegrade K wire P. 1676

Case 36.4
Technique of closed reduction and fixation with 2 × K-wires P. 1677-1680

Case 36.5
Technique of closed reduction and fixation with 2 × K-wires P. 1681-1684

Case 36.6
Technique of closed reduction and fixation with 2 × K-wires P. 1685-1688

Case 36.7
Technique of closed reduction and fixation with 2 × K-wires P. 1689-1691

Case 36.8
Technique of closed reduction and fixation with 2 × K-wires P. 1692-1693

Case 36.9
Technique of closed reduction and fixation with 2 × K-wires P. 1694-1695

Case 36.10
Technique of closed reduction and fixation with 2 × K-wires P. 1696

Case 36.11
Technique of closed reduction and fixation with 2 × K-wires P. 1697-1699

Case 36.12
Technique of closed reduction and fixation with 2 × K-wires P. 1700-1702

Case 36.13
Technique of closed reduction and fixation with 2 × K-wires P. 1703-1704

Transvers Fracture Neck of 5th Metacarpal

Case 36.14
Technique of closed reduction and fixation with 3 × K-wires P. 1705-1707

Case 36.15
Technique of closed reduction and fixation with 2 × K-wires P. 1708-1709

Fracture Neck of 4th and 5th Metacarpal

Case 36.16
Technique of closed reduction and fixation with 3 × K-wires P. 1710-1711

Transverse Fracture Neck of 5th Metacarpal with Fragmented Head

Case 36.17
Technique of closed reduction and fixation with 2 × K-wires like external fixator P. 1712-1713

Fracture and Dislocation of the Neck of the 5th Metacarpal

Case 36.18
Technique of closed reduction and fixation with 3 × K-wires P. 1714-1716

Fracture Shaft of Metacarpals

Case 36.19
Technique of closed reduction and fixation with 3 × K-wires P. 1717-1719

Case 36.20
Technique of closed reduction and fixation of spiral fracture of neck and shaft with 3 × K-wires, like exterior fixator P. 1720-1722

Case 36.21
Technique of closed reduction and fixation of oblique fracture at base of 5th metacarpal with 3 × K-wires P. 1723-1724

Case 36.22
Technique of closed reduction and fixation of transverse fracture with fracture base of 5th metacarpal with 4 × K-wires P. 1725-1728

Case 36.23
Technique of closed reduction and fixation of transverse fracture of 4th and 5th metacarpal with 3 × K-wires, like exterior fixator P. 1729-1731

Case 36.24
Technique of closed reduction and fixation of transverse fracture at base of 4th and 5th metacarpal with 3 × K-wires P. 1732-1733

Case 36.25
Technique of closed reduction and fixation of intra-articular fracture base of 1st metacarpal with 2 × K-wires P. 1734-1737

Case 36.26
Technique of closed reduction and fixation of complex fracture dislocation of base of 1st metacarpal and fracture trapezium with 2 × K-wires P. 1738-1740

Nonunion of Metacarpal Fractures

Case 36.27
Technique of closed reduction and fixation of nonunion of 5th metacarpal with 4 × K-wires like exterior fixator P. 1741-1743

Case 36.28
Technique of closed reduction and fixation of nonunion of 4th and 5th metacarpal with 3 × K-wires, like exterior fixator P. 1744-1746

Chapter 37 Management of Scaphoid Fracture
Cases 37.1–37.26 1747-1832

Fracture of the Scaphoid at Waist Level

Case 37.1 P. 1748-1751
Position of hand on table P. 1749
Surface marking P. 1749
Technique of closed reduction, insertion of guidewire, reaming and fixation P. 1750

Case 37.2
Technique of closed reduction, insertion of guidewire, reaming and fixation P. 1752-1753
Useful tips for insertion of wire P. 1754

Case 37.3
Technique of closed reduction, insertion of guidewire, reaming and fixation P. 1755-1757
Advantage of using 1.6 mm K-wire initially rather than scaphoid wire P. 1758

Case 37.4
Technique of closed reduction, initial insertion of 1.6 mm K-wire and fixation P. 1759-1761

Case 37.5
Technique of closed reduction, initial insertion of 1.6 mm K-wire and fixation P. 1762-1764

Nonunion Around Waist of Scaphoid

Case 37.6
Technique of closed reduction, initial insertion of 1.6 mm K-wire and fixation P. 1765-1768

Case 37.7
Technique of closed reduction, initial insertion of 1.6 mm K-wire and fixation P. 1769-1771

Case 37.8
Technique of closed reduction, initial insertion of 1.6 mm K-wire and fixation P. 1772-1774

Case 37.9
Technique of closed reduction, initial insertion of 1.6 mm K-wire and fixation P. 1775-1778

Nonunion of Scaphoid with Cyst

Case 37.10
Technique of closed reduction, initial insertion of 1.6 mm K-wire and fixation P. 1779-1781

Case 37.11
Technique of closed reduction, initial insertion of 1.6 mm K-wire and fixation P. 1782-1785

Case 37.12
Technique of closed reduction, initial insertion of 1.6 mm K-wire and fixation P. 1786-1788

Case 37.13
Technique of closed reduction, initial insertion of 1.6 mm K-wire and fixation P. 1789-1791

Case 37.14
Technique of closed reduction, initial insertion of 1.6 mm K-wire and fixation P. 1792-1793

Case 37.15
Technique of closed reduction, initial insertion of 1.6 mm K-wire and fixation P. 1794-1797

Nonunion of Scaphoid at Proximal Pole with and without Cyst

Case 37.16
Technique of closed reduction, initial insertion of 1.6 mm K-wire and fixation P. 1798-1801

Case 37.17
Technique of closed reduction, initial insertion of 1.6 mm K-wire and fixation P. 1802-1804

Case 37.18
Technique of closed reduction, initial insertion of 1.6 mm K-wire and fixation P. 1805-1807

Case 37.19
Technique of closed reduction, initial insertion of 1.6 mm K-wire and fixation P. 1808-1809

Case 37.20
Technique of closed reduction, initial insertion of 1.6 mm K-wire and fixation P. 1811-1813

Case 37.21
Technique of closed reduction, initial insertion of 1.6 mm K-wire and fixation P. 1814-1816

Case 37.22
Technique of closed reduction, initial insertion of 1.6 mm K-wire and fixation P. 1817-1819

Case 37.23
Technique of closed reduction, initial insertion of 1.6 mm K-wire and fixation P. 1820-1822

Open Reduction of Nonunion Around Waist of Scaphoid and Bone Graft

Case 37.24
Technique of open reduction, bone graft and fixation P. 1823-1826

Case 37.25
Technique of open reduction, bone graft and fixation P. 1827-1829

Case 37.26
Technique of open reduction, bone graft and fixation P. 1830-1832

Chapter 38 Miscellaneous
Cases 38.1–38.34 1833-1904

Fracture Malleoli of Ankle

Example of conventional way to fix the malleolar fracture with plate and screws P. 1834-1835

Case 38.1
Complications of wounds after open reduction P. 1836

Case 38.2
Technique of closed reduction, and fixation with Rush nail P. 1837

Case 38.3
Complications of wounds after open reduction P. 1838

Case 38.4
Technique of closed reduction, and fixation with Rush nail P. 1839

Case 38.5
Complications of wounds after open reduction P. 1840

Case 38.6
Technique of closed reduction, and fixation with Rush nail P. 1841

Case 38.7
Technique of closed reduction, and fixation with Rush nail P. 1842

Case 38.8
Technique of closed reduction, and fixation with Rush nail P. 1843

Case 38.9
Technique of closed reduction, and fixation with Rush nail P. 1844

Case 38.10
Technique of closed reduction, and fixation with Rush nail P. 1845

Case 38.11
Technique of closed reduction, and fixation with Rush nail P. 1846

Case 38.12
Technique of closed reduction, and fixation with Rush nail P. 1847-1848

Case 38.13
Technique of open reduction, and fixation with fibular nail P. 1849-1850

Case 38.14
Technique of closed reduction, and fixation with Rush nail P. 1851-1852

Case 38.15
Technique of reduction of a compound fracture, and fixation with Rush nail P. 1853-1855

Humeral Fracture

Case 38.16
Complications with various treatment of a humeral fracture P. 1857-1860

Femoral Nailing

Case 38.17
Conventional entry hole in proximal femur for intramedullary nailing P. 1861

Case 38.18
Complication following conventional intramedullary nailing through the entry hole P. 1862-1863

Case 38.19
Author's recommended technique of entry hole for intramedullary nailing P. 1864-1868

Case 38.20
Comparison of entry hole in proximal femur for intramedullary nailing P. 1869

Case 38.21
Technique of closed reduction, and fixation of a complicated entire femur fracture P. 1870-1871

Position of Distal Locking Screws

Case 38.22
Complication following insertion distal locking screws in wrong position during intramedullary nailing for femur P. 1872-1873

Case 38.23
Complication following insertion distal locking screws in wrong position during intramedullary nailing for femur P. 1874-1875

Insertion of Distal Locking Screws during Revision Operation

Case 38.24
Technique of insertion of distal locking screws by the side of existing holes during revision operation of femoral nail P. 1876-1877

Case 38.25
Technique of insertion of distal locking screws by the side of existing holes during revision operation of tibial nail P. 1878-1879

Unsolved Nonunion of Supracondylar Fracture of Femur

Case 38.26
Technique of fixation of nonunion of supracondylar fracture with intramedullary nail P. 1880-1883

Intramedullary Nailing for Periprosthetic Fracture of Total Knee Replacement (TKR)

Case 38.27
Technique of fixation of periprosthetic fracture of TKR P. 1884-1886

Case 38.28
Technique of fixation of periprosthetic fracture of TKR P. 1887-1888

Case 38.29
Technique of fixation of periprosthetic fracture of TKR P. 1889-1890

Technique of Osteotomy of Malunion of Fracture Tibia

Case 38.30
Technique of correction deformity of malunion of fracture tibia P. 1891-1894

Closure of the Wound using the Technique of Victorian Brace

Case 38.31
Skin graft to cover the wound, after release of compartment syndrome P. 1895

Case 38.32
Technique of how to tight the Victorian brace? P. 1896

Case 38.33
Technique of closer of a wound, following application of Victorian brace P. 1897-1899

Case 38.34
Technique of closer of a large wound, following application of Victorian brace P. 1900-1903

Chapter 36

Management of Metacarpal Fracture

Majority of these fractures are treated conservatively especially those with minimal displacement.
Confusion and controversy arise when the fractures are displaced and need to be fixed.

Questions are: How to fix?
What method: open or closed?
and
What implant to be used?

Fifth metacarpal fractures are by far the most common fractures of the hand.

Most of the time treated conservatively with its consequences such as malunion of fracture. Some of them are acceptable others are not.

Author's preferred method of closed reduction and percutaneous K-wire fixation of the fracture.
In this chapter, author is going to explain the procedure of fixation of the fracture in the following pages.

JAYPEE BROTHERS

CASE 36.1

1st, Conservative Treatment of Fifth Metacarpal Neck Fracture

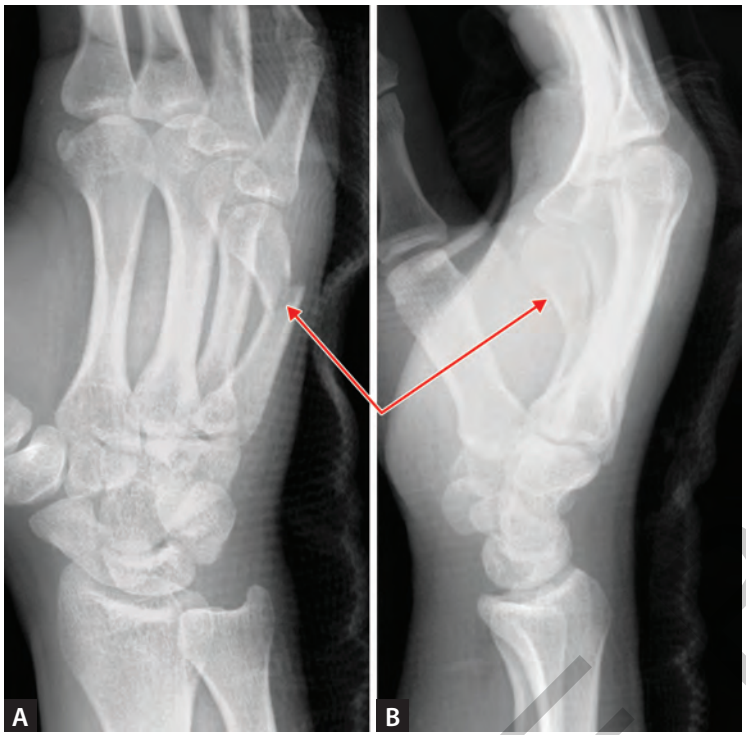

Figs. 1A and B: Fifth metacarpal neck fracture with marked angulation (red arrows).

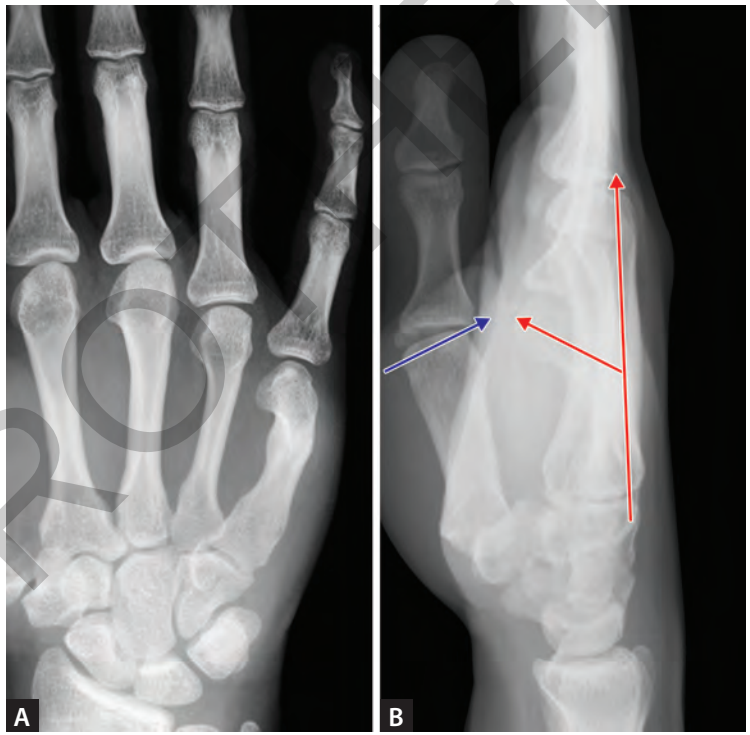

Figs. 2A and B: (A) The end result of conservative treatment. Fifth metacarpal fracture was healed in displaced position

(B) Lateral view showing marked angulation (red arrow) of 5th metacarpal. The head of the 5th metacarpal (blue arrow) is just underneath the palmer skin. Clinically, this person experiences significant pain while gripping objects, e.g. steering wheel or do it yourself (DIY) tools, etc.

JAYPEE BROTHERS

CASE 36.2

Alternative Method of Treatment of Fifth Metacarpal Neck Fracture by Plate and Screw Fixation



Fig. 1: A 30+ years old male patient had 5th metacarpal neck fracture of right hand with volar displacement of the head (red arrows).

JAYPEE BROTHERS

CASE 36.2 (continued)



Fig. 2: Preoperative X-ray of the hand.



Fig. 3: The fracture was immobilized with POP cast, but was not kept in reduced position.

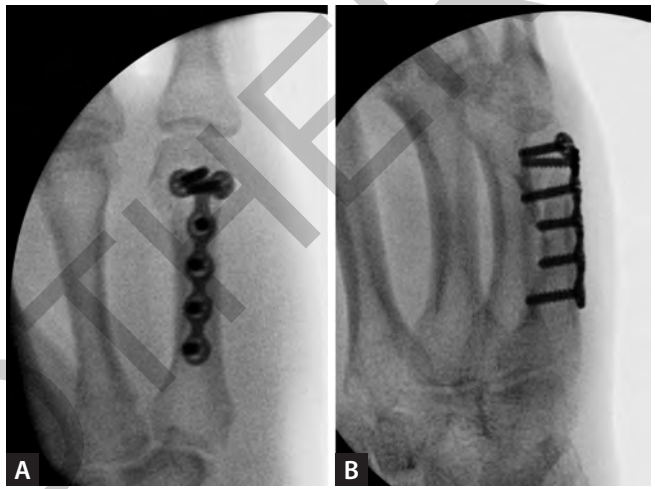

Figs. 4A and B: The fracture was fixed with a plate and screws after reducing the fracture by open method.



Figs. 5A to C: These were the X-rays after 8/52 of fixation.

JAYPEE BROTHERS

CASE 36.3

2nd, Conventional Way to Fix the Metacarpal Fracture with K-wire

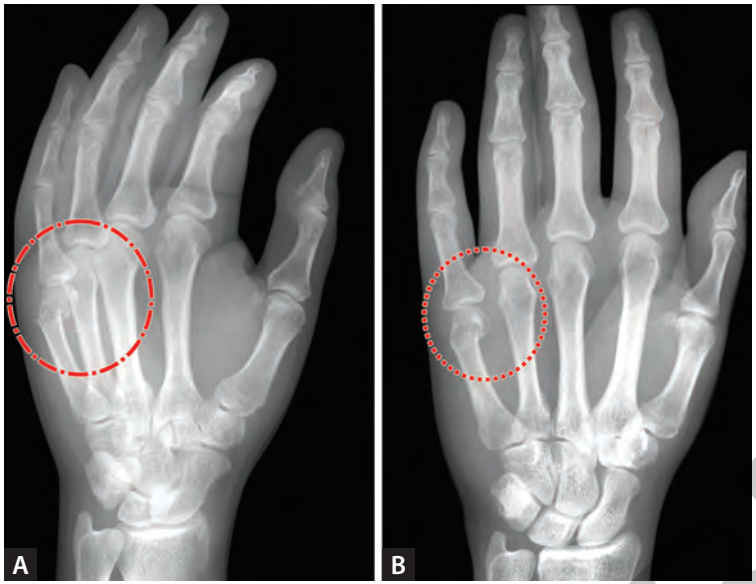

Figs. 1A and B: Fifth metacarpal neck fracture with angulation (red circles).

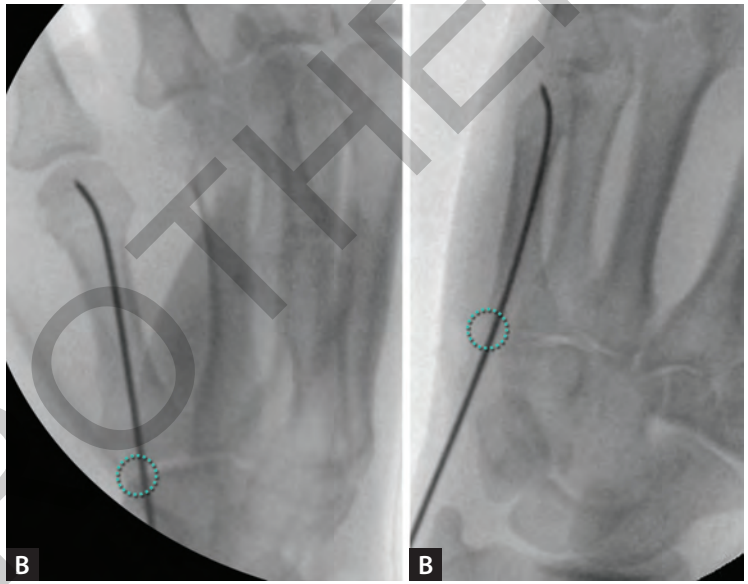

Figs. 2A and B: This fracture was reduced and fixed with one K-wire by antegrade method, making entry portal at the base of 5th metacarpal (green circles).
Two K-wires were usually needed for stable fixation and to maintain correct rotation. Sometimes it is difficult to pass second K-wire if medullary cavity was narrow.
It also requires more operative time.
In addition may need for plaster of Paris (POP) immobilization.

This type of fracture can be treated with K-wires in a different way.
That would be simple and effective
There is no need for additional POP cast to support the fracture.

JAYPEE BROTHERS

CASE 36.4

Author's Preferred Method of Fixation of Fifth Metacarpal Neck Fracture

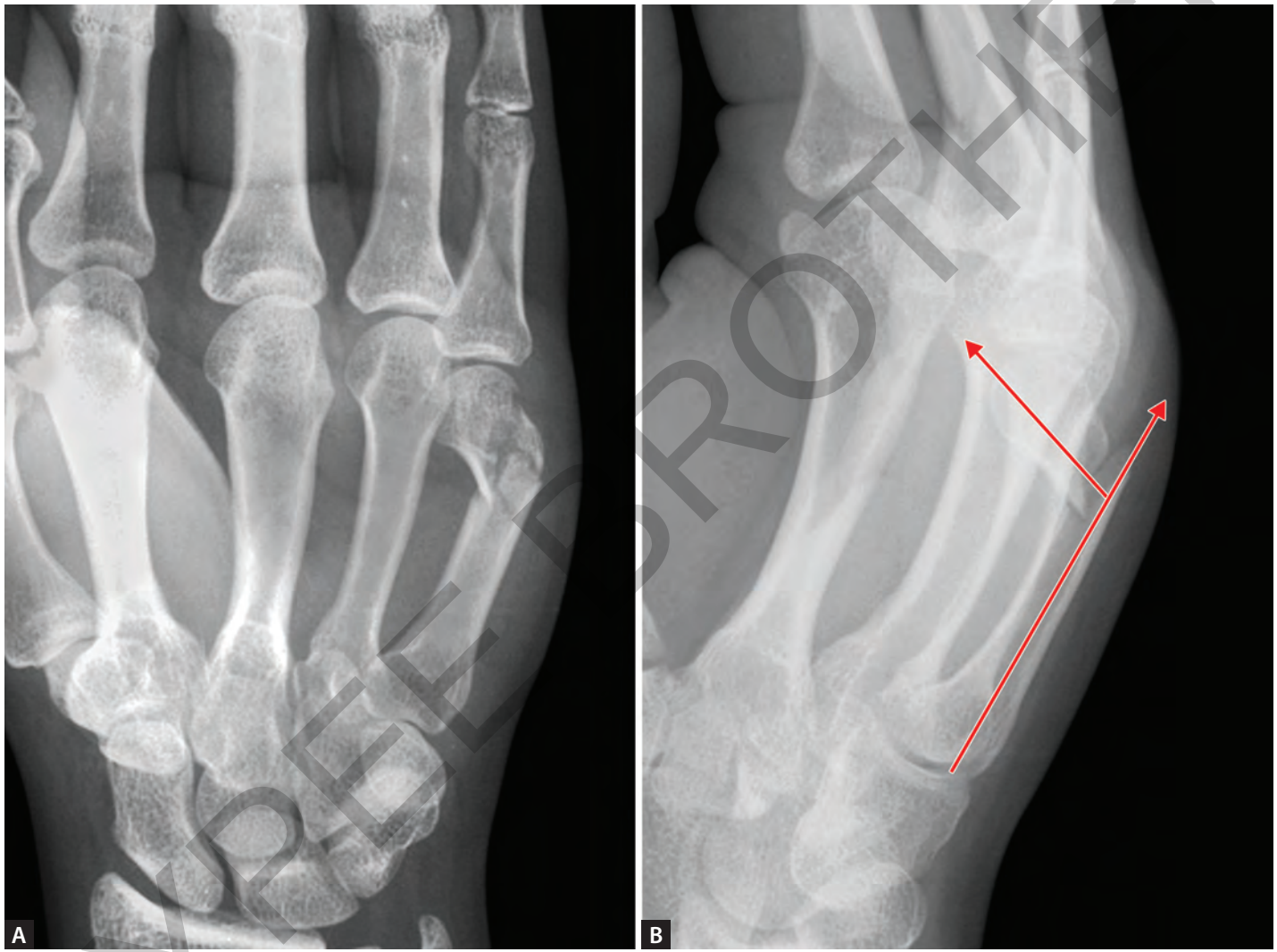

Figs. 1A and B: A 21+ years old male patient had an oblique 5th metacarpal neck fracture with angulation.

Please note: More than 90% cases, pattern of the fracture is oblique or spiral. The head of the 5th metacarpal gets displaced in volar direction with or without rotation deformity of the finger. There was also displaced spike of the proximal fragment in dorsal direction.
Red arrows are showing the displacement of fracture.

JAYPEE BROTHERS

CASE 36.4 (continued)

Author's preferred method for fixation

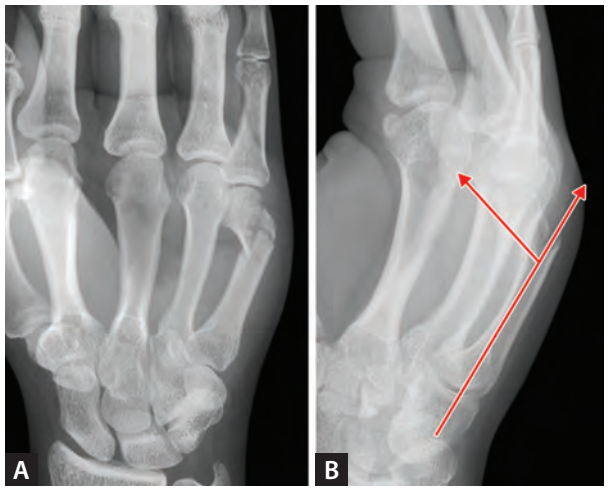

Figs. 2A and B: Preoperative X-rays. The aim of the fixation will be:

1. To keep reduced the volar displacement of the head with maintaining the length and the rotation of the 5th metacarpal.
2. To keep reduced the spiky end of the proximal fragment down to the distal fragment.



Figs. 3A and B: *Reduction:* Initially the fracture was reduced manually by applying traction holding the little finger.
With this maneuver, fracture was reduced. Red circles are showing reduction of the fracture.

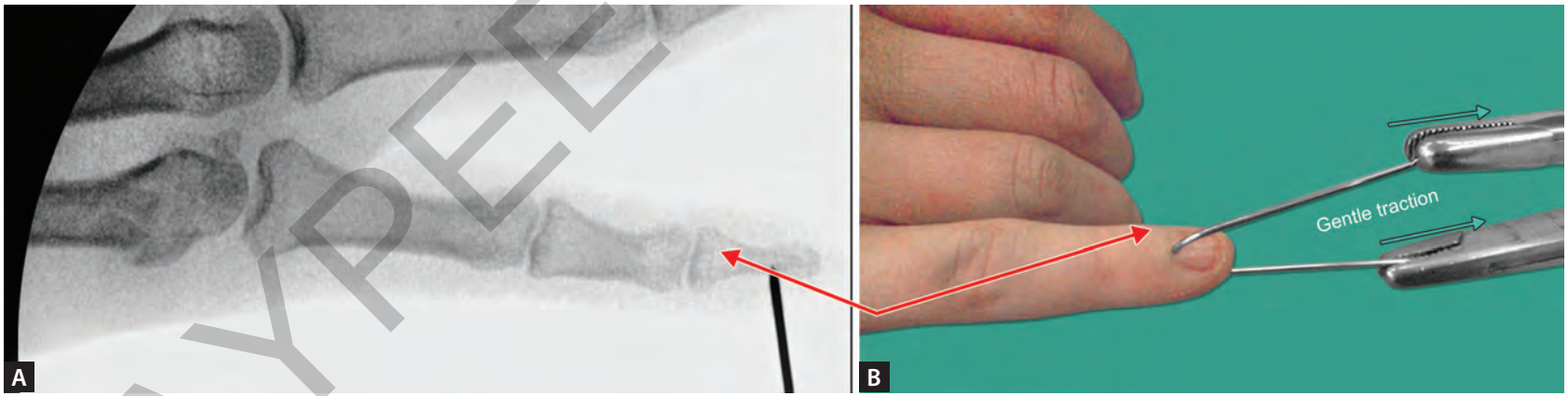

Figs. 4A and B: *To maintain the reduction of the fracture and rotation of the finger:* Sometimes author use finger traction as described in P. 1580-1582.
One 1.2 mm K-wire was inserted in distal phalanx for application of traction and maintaining rotation.

JAYPEE BROTHERS

CASE 36.4 (continued)

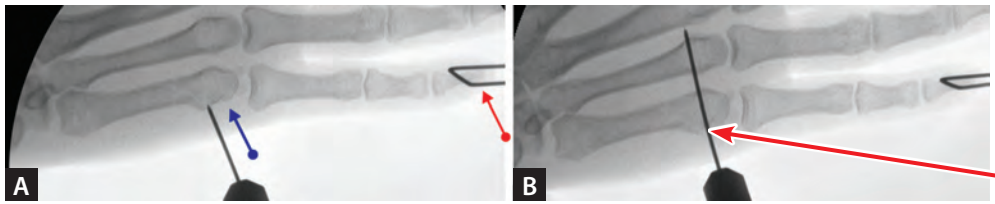

Figs. 5A and B: *To maintain the length and rotation of the metacarpal finger:*
(A) A stab incision was made on ulnar side of the head of 5th metacarpal at the junction of head and neck. A 1.6 mm K-wire was inserted in the head of the 5th metacarpal through the stab wound, while continuing traction and maintaining rotation of the finger (red arrow).
Blue arrow is showing joint space.
(B) The same K-wire was then advanced in the head of 4th metacarpal through the 5th metacarpal.
This single K- wire maintains the correct length and rotation of the 5th metacarpal.



Fig. 6: Picture of the hand, showing:
1. Position of the K-wire (red arrow)
2. Traction applied through distal phalanx (green arrows).

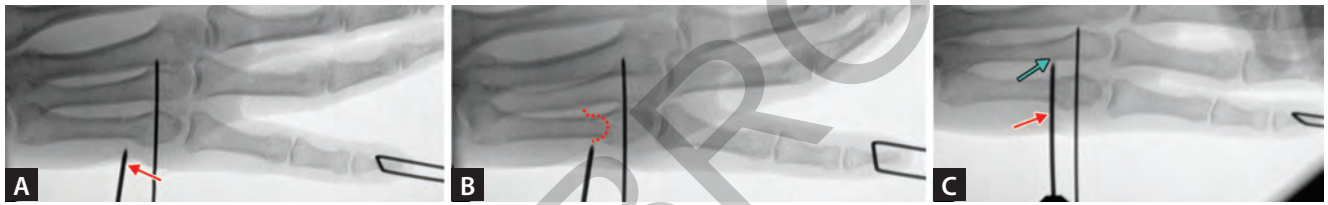

Fig. 7A to C: *Holding the reduction of the spiky end of proximal fragment:*
(A) Another stab incision was made on ulnar side of 5th metacarpal slightly dorsal and proximal to the 1st one. A 1.6 mm K-wire was then inserted in the stab wound by hand until it reaches the near cortex.
(B) The curved red dotted line is showing the spike of proximal fragment which usually overlaps over the distal fragment.
Aim is, to keep this spiky end down to distal fragment by applying pressure from the top overlying the 2nd K-wire.
(C) The 2nd K-wire (red arrow) was then passed *OVER* the spike but *UNDERNEATH* the extensor tendon by hand until it reached the near cortex of the 4th metacarpal (green arrow).

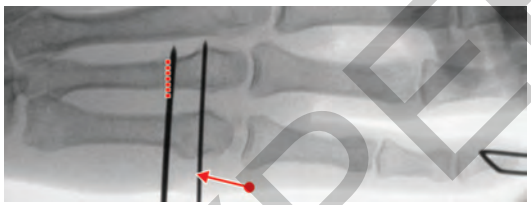

Fig. 8: The 2nd K-wire was then advanced into the shaft of 4th metacarpal by using a power tool. This 2nd K-wire was keeping the spike of proximal fragment down to the distal fragment to maintain reduction.

Anteroposterior view is showing both the K-wires in position:
1st one (red arrow) was traversing through the heads of 5th and 4th metacarpal, that maintain the length of metacarpal and rotation of the finger.
2nd K-wire was extraosseous but *UNDERNEATH* the extensor tendon of 5th metacarpal, and intraosseous in the shaft of the 4th metacarpal (red dotted line) that maintain the reduction of the fracture.

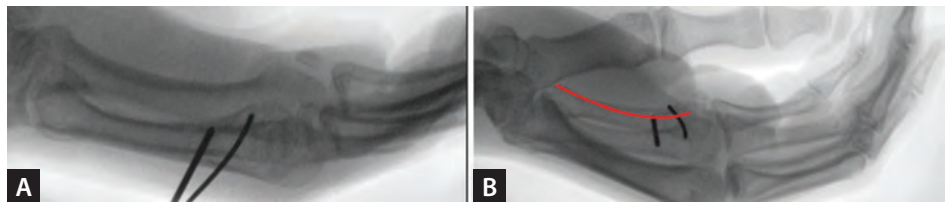

Figs. 9A and B: (A) True lateral view showing reduction of the fracture after operation.
(B) Slightly oblique view showing corrected alignment and reduction of the fracture after fixation (red curved line).

JAYPEE BROTHERS

CASE 36.4 (continued)

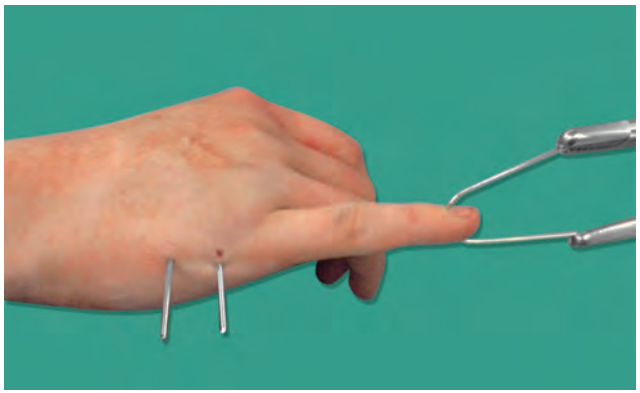

Fig. 10: Picture of the hand is showing end result using only two percutaneous K-wires.

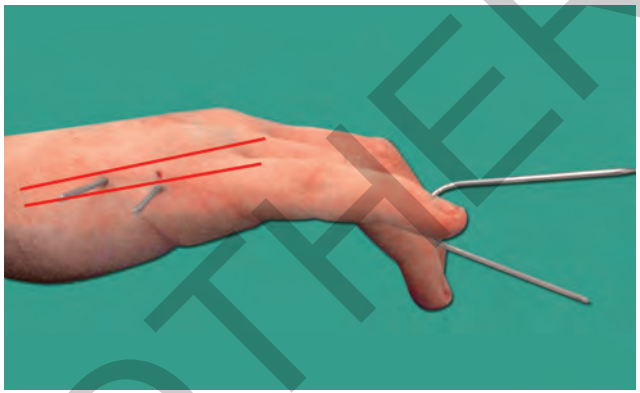

Fig. 11: These two red lines are showing the slightly different levels at which the K-wires were inserted—the second one is proximal and dorsal to the first.

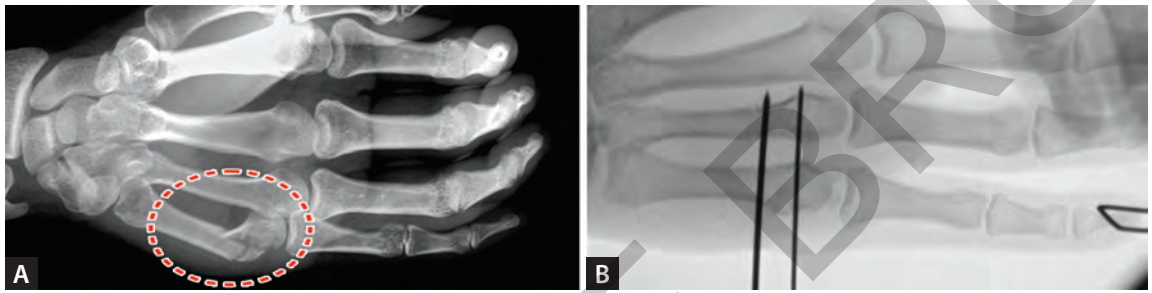

Figs. 12A and B: *Anteroposterior view:*
(A) Preoperative X-ray showing degree of displacement of fracture neck of 5th metacarpal (red circle).
(B) Last X-ray of the hand after fixation, showing the reduction and fixation of the fracture

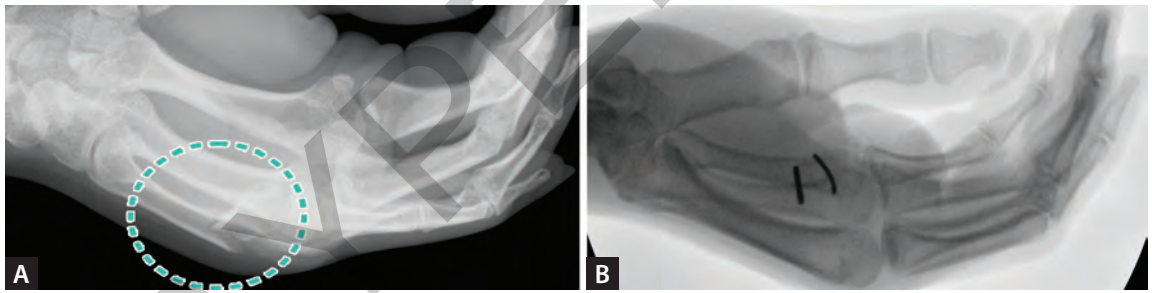

Figs. 13A and B: *Oblique view:*
(A) Preoperative X-ray showing degree of displacement in lateral view (green circle).
(B) Last X-ray of the hand after fixation, showing the reduction and fixation of the fracture.

Key Points:
1st: Initially, fracture was reduced by gentle traction of the finger applied manually.
2nd: 1.2 mm K-wire was inserted in distal phalanx for sustained traction.
3rd: 1.6 mm K-wire was inserted in the heads of the 5th and 4th metacarpals.
4th: 2nd 1.6 mm K-wire must be passed OVER the spiky end of metacarpal and UNDERNEATH the extensor tendon of the little finger and then insert into the shaft of 4th metacarpal bone.

Note: If the K-wire passes over the extensor tendon, this can be palpated under the skin.

If used correctly, then this cannot be felt by examining finger.

JAYPEE BROTHERS

CASE 36.5



Figs. 1A to C: A 28+ years male patient had an oblique 5th metacarpal neck fracture with angulation. There was some rotational problems of little finger. Red arrows are showing the displacement of fracture.

JAYPEE BROTHERS

CASE 36.5 (continued)

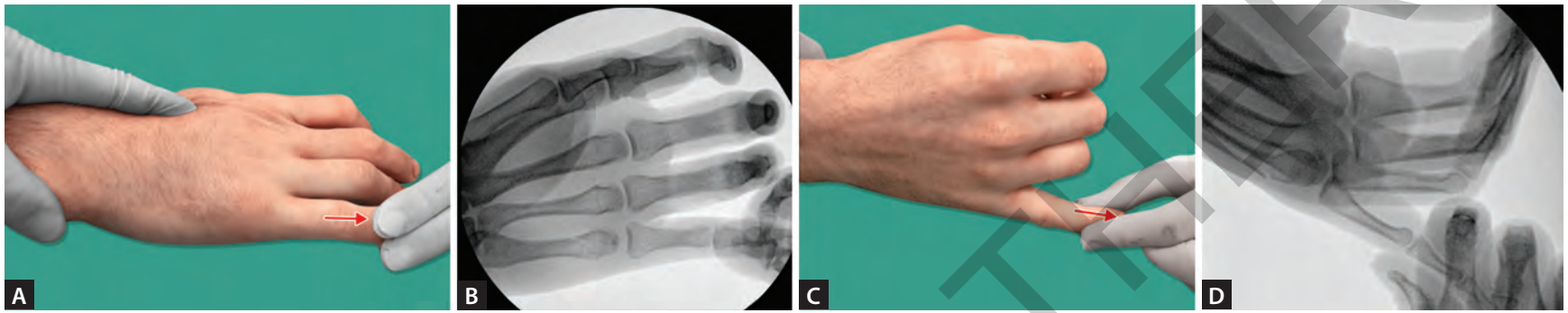

Figs. 2A to D: *Reduction*: Initially the fracture was reduced manually by applying traction holding the little finger (red arrows). Reduction of the fracture was checked with anteroposterior view (B) and lateral view (D).

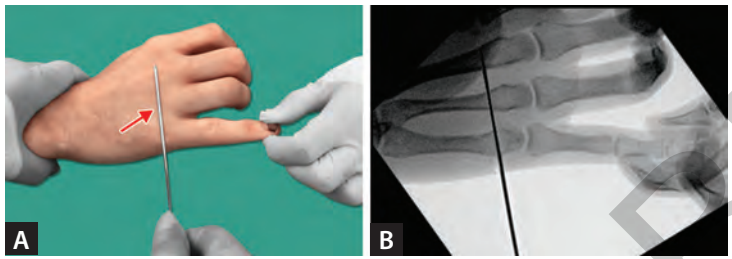

Figs. 3A and B: Keeping the fracture reduced by pulling the little finger, one 1.6 mm K-wire was placed over heads of the 5th and 4th metacarpal (red arrow) to identified the ideal position of the K-wire in heads of the metacarpals before inserting it.

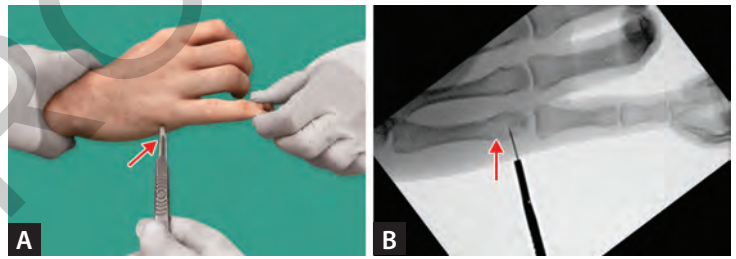

Figs. 4A and B: Keeping the fracture reduced by pulling the little finger, a stab incision was made on ulnar side of the head of 5th metacarpal, along the line of the wire, at the junction of head and neck (red arrows).

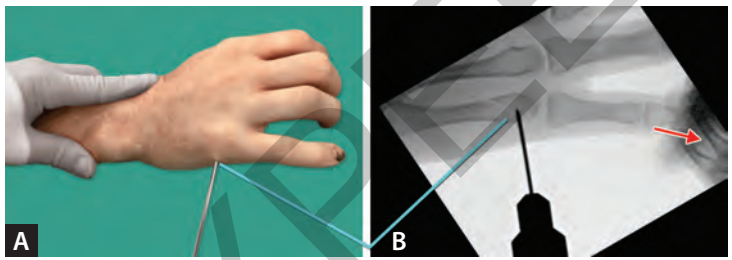

Figs. 5A and B: One 1.6 mm K-wire was inserted in the stab wound up to the head of the 5th metacarpal (green lines) while continuing traction and maintaining rotation of the finger (red arrow).

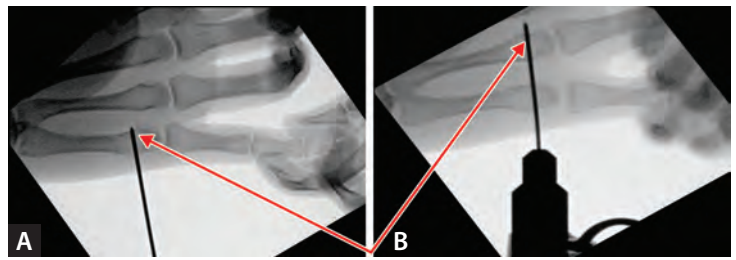

Figs. 6A and B: (A) A 1.6 mm K-wire was then advanced into the head of the 5th metacarpal.
The position of the K-wire in the head of the 5th metacarpal was checked. (B) The K-wire was then further advanced in the head of 4th metacarpal (red arrows).

With this 1.6 mm K-wire, the correct length and rotation of the 5th metacarpal was maintained.

JAYPEE BROTHERS

CASE 36.5 (continued)

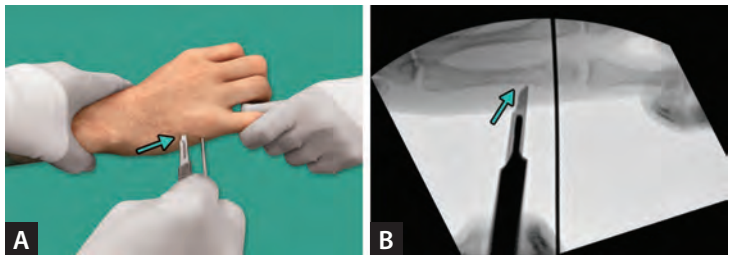

Figs. 7A and B: After securing the length and rotation of the finger, another stab incision was made on ulnar side of 5th metacarpal slightly dorsal and proximal to the 1st one (green arrows).



Figs. 8A and B: Another 1.6 mm K-wire was then inserted in the stab wound by hand up to the cortex of the 5th metacarpal (red arrows).

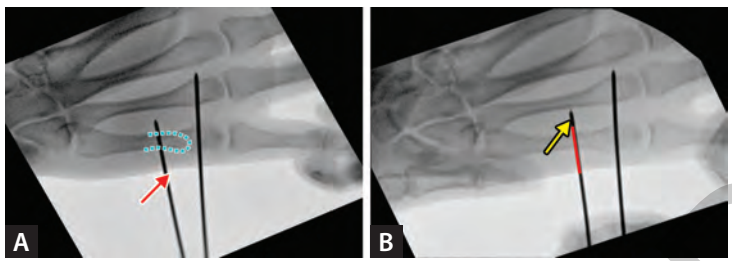

Figs. 9A and B: (A) The 2nd K-wire (red arrow) was passed *OVER* the spike of the proximal fragment of the 5th metacarpal (green dotted drawing), but *UNDERNEATH* the extensor tendon, maneuvering by the hand.
(B) Then, the K-wire was pushed in slight volar direction, as the position of the 4th metacarpal in slight volar position until it reached the ulnar side of the cortex of the 4th metacarpal (yellow arrow).

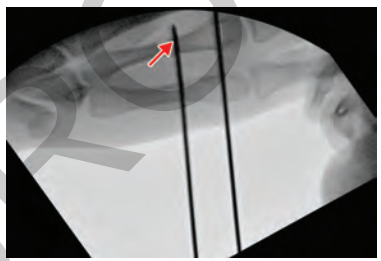

Fig. 10: The K-wire was then advanced into the shaft of 4th metacarpal by using a power tool (red arrow).
This 2nd K-wire was helping the spike of proximal fragment down to maintain the reduction of the fracture.

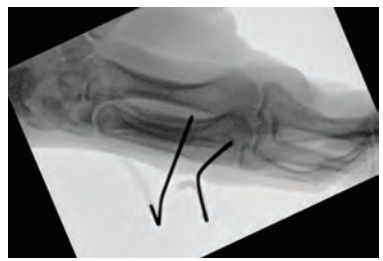

Fig. 11: After securing fracture with two K-wires, the outer ends of the wires were cut short and bent over.

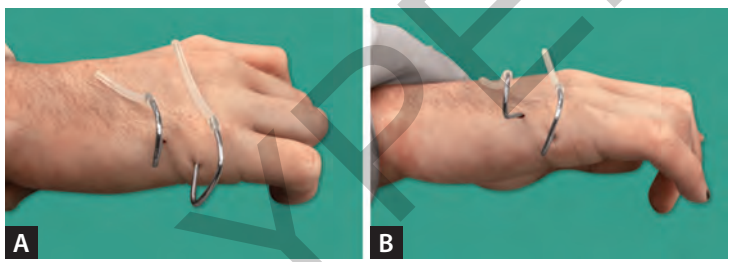

Figs. 12A and B: The sharp outer ends were protected with plastic tube.
Clinical pictures of the hand after fixation of the 5th metacarpal neck fracture.
Note: The position of the two K-wires in two different levels.

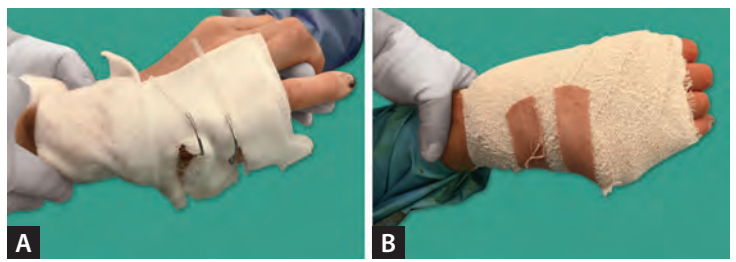

Figs. 13A and B: Stab wounds were protected with dressing.
No POP was needed for further immobilization of the hand.

JAYPEE BROTHERS

for detailed information on orthopedics books, visit our website www.jaypeebrothers.com, for detailed information on orthopedics books, visit our website www.jaypeebrothers.com, for detailed information on orthopedics books, visit our we

Tips & Tricks

Masterclass of Intramedullary Nailing

Salient Features

- This is a unique reference book explaining multiple variations of intramedullary nailing operative techniques in a detailed step-by-step manner
- Includes guidelines on positioning of the patient, finding the correct entry point, positioning of the guidewire, technique of reaming, and insertion of nail into an appropriate site in the bone to avoid subsequent complications, morbidity and mortality of the patient
- Encompasses a broad range of surgeries including fixation techniques of long bones as well as hand fractures
- Guidelines are based on a course accredited by the Royal College of Surgeons, England, UK, which is run by the author himself.

Subhash Ch Halder FRCS (England) is a Consultant Orthopedic Surgeon, Calderdale and Huddersfield Hospital, England, UK. He is the inventor of the Gamma Nail, Halder Humeral Nail and Halder Tibial Nail. He qualified from the Calcutta University, West Bengal, India in 1970. After his initial training, he travelled to the United Kingdom for higher education. On completion of his training, he remained and settled in the UK. Among other orthopedic surgeries, his interest was mainly in trauma surgery. He was not satisfied with the results of fixation of fracture of the neck of femur with pin and plate like dynamic hip screw (DHS). As a result, he went on to carry out some cadaveric work which resulted in a wax model of intramedullary nail for proximal femur, which was then given to the Howmedica Medical Company (now Stryker Corporation) for production, hence, the development of the Gamma nail—an intramedullary nail for fracture of the neck of femur. With this device, fractures can be fixed by closed technique with minimal invasion.

This has now become a well-recognized worldwide implant and method of fixation, especially for unstable fractures of the neck of femur. Due to its success of fixation, nearly all orthopedic companies copied the design of the Gamma nail. He then went on to develop the retrograde Halder Humeral Nail for the fixation of proximal down to the distal humeral fracture, with modified retrograde insertion technique of the nail. He has carried out more than 900 cases of humeral fractures with this implant without interfering the rotator cuff of the shoulder.

In addition to this, he also developed the Halder Tibial Nail using the same principle as the Halder Humeral Nail. With this implant, distal extra-articular tibial fractures can be treated with this nail avoiding any open fixations with plates and screws. He presented the results of these implants at orthopedic conferences around the world. For his innovative work, he was presented an Honorary Fellowship (1994) by the Royal College of Surgeons, England, UK. He was awarded at the Seventh International Congress on Surgery of Shoulder, Sydney (1998), for the best clinical paper for presentation of the humeral nail. He was also honored a Golden Gamma nail (2001) by the orthopedic company—Stryker to give recognition that millions of the Gamma nail had been sold worldwide.

He was honored with a Guest Professorship (2002), Tianjin Hospital, China. He improved the design of the Gamma Nail (2015) for fixation of intracapsular fractures of the neck of femur, which is now known as the Halifax nail. This design has got an American patent and at present on clinical trial. Furthermore, he was also granted Visiting Professorship (2018), Department of Orthopedics, Indira Gandhi Institute of Medical Sciences, Patna, Bihar, India.

Available at all medical bookstores
or buy online at www.jaypeebrothers.com



JAYPEE BROTHERS
Medical Publishers (P) Ltd.
www.jaypeebrothers.com

Join us on facebook.com/JaypeeMedicalPublishers

Shelving Recommendation
ORTHOPEDICS

