it our website www.jaypeebrothers.com, for detailed information on obstetrics & gynecology books, visit our website www.jaypeebrothers.com



Celebrating 50 YEARS
Passion, Quality and Innovation in Healthcare Publishing

Dutta's

Bedside Clinics and Viva-Voce in Obstetrics & Gynecology



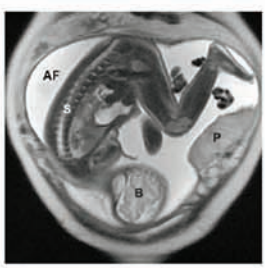

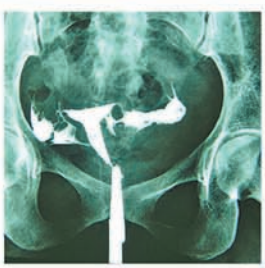



Hiralal Konar

7TH EDITION

JAYPEE

Contents

SECTION I: OBSTETRICS 1–370

Chapter 2: History Taking and Clinical Examination 3–15

- History 4
- Examination 5
- Obstetric Examination 8
- Normal Puerperium 11
- Postpartum Exercises 13

Chapter 2: Obstetric Case Discussions 16–119

- Case–1 Normal Pregnancy 18
- Case–2 Primigravida with Floating (Free) Head at Term 26
- Case–3 Normal Puerperium 31
- Case–4 Puerperium Normal and Abnormal 37
- Case–5 Pregnancy and Labor in a Woman with Prior Cesarean Delivery 41
- Case–6 Anemia in Pregnancy 48
- Case–7 Diabetes in Pregnancy 54
- Case–8 Breech Presentation 59
- Case–9 Prolonged Pregnancy 65
- Case–10 Fetal Growth Restriction 68
- Case–11 Pre-Eclampsia and Eclampsia 72
- Case–12 Pregnancy with Maternal Red Cell Alloimmunization 80
- Case–13 Multiple Pregnancy 86
- Case–14 Intrauterine Fetal Death 93
- Case–15 Polyhydramnios 96
- Case–16 Antepartum Hemorrhage (Placenta Previa) 100
- Case–17 Abruptio Placentae (Accidental Hemorrhage) 104
- Case–18 Postpartum Hemorrhage—Prevention and Management 107
- Case–19 Hemorrhage in Early Pregnancy 113
- Case–20 Miscarriage (Spontaneous Abortion) 117

Chapter 3: Single Best Answers and Multiple Choice Questions 120–164

Chapter 4: Labor and Delivery 165–215

- Maternal Pelvis 166
- Fetal Skull 174
- Mechanism of Labor 176
  - Mechanism of Normal Labor 176
- Labor-Normal, Vaginal Delivery and Management 180
  - Preterm Labor and Delivery 191
  - Prelabor Rupture of Membranes (PROM) 197
- Labor-Abnormal 198
  - Malposition and Malpresentation 198

- Occiput Posterior Position (OP) 198
- Breech Presentation 202
- Face Presentation 206
- Brow Presentation 209
- Transverse Lie 209
- Cord Prolapse 210
- Compound Presentation 211
- Unstable Lie 212

■ Prolonged (Protracted) Labor 212
■ Obstructed Labor 214

Chapter 5: Active Management of Labor 216–234

■ Labor Monitoring—Partography 217
■ Intrapartum Electronic Fetal Monitoring—Cardiotocography 229

Chapter 6: Obsterics Short Questions 235–256

Chapter 7: Operative Obstetrics 257–278

■ Dilatation and Evacuation (D and E) 258
■ Suction Evacuation 259
■ Manual Vacuum Aspiration (MVA) 260
■ Episiotomy 261
■ Forceps Delivery 263
■ Ventouse Delivery 268
■ Cesarean Section 269
■ Destructive Operations 277

Chapter 8: Practical Obstetrics 279–337

■ Obstetric Instruments 280
■ Specimens 312
■ Imaging Studies 316
- Ultrasonogram 316
- Magnetic Resonance Imaging (MRI) 323

■ Drugs in Obstetrics 324
- Oxytocics 324
- Antihypertensives 331
- Anticoagulants 333
- Anticonvulsants 333
- Tocolytic Drugs 336

Chapter 9: Maternal Health: India and Global Scenario 338–358

■ Maternal Mortality Ratio (MMR), Maternal Mortality Rate and Lifetime Risk 339
■ Sustainable Development Goals (SDG 3) 344
■ Millennium Development Goals (MDG 4 and 5) and Sustainable Development Goals (SDGs) 345
■ National Health Mission (NHM) and Reproductive and Child Health-II (RCH–II) 348

- Janani Shishu Suraksha Karyakram (JSSK) a Government of India (GOI) Scheme 350
- Maternal Health Beyond 2030....357

Chapter 10: Drug Therapy, Charts, Illustrations and Medications 359–370

- Drug Therapy in Pregnancy and Teratogenicity....360
- Obstetric Charts and Graphs....363
- Critical Periods in Embryonic Development 365

SECTION II: GYNECOLOGY 371–693

Chapter 11: Gynecology Case Discussion 373–432

- Case – 1 Fibroid Uterus....374
- Case – 2 Ovarian Tumor....381
- Case – 3 Pelvic Organ Prolapse....392
- Case – 4 Genitourinary Fistula 403
- Case – 5 Ureteric Injury in Gynecology....406
- Case – 6 Rectovaginal Fistula 408
- Case – 7 Old Complete Perineal Tear....410
- Case – 8 Pelvic Infections....413
- Case – 9 Genital Tuberculosis....416
- Case – 10 Abnormal Uterine Bleeding (AUB)....418
- Case – 11 Hydatidiform Mole 423
- Case – 12 Uterine Polyp....428
- Case – 13 Infertility....430

Chapter 12: Special Topics....433–456

- Physiology of Menstruation 434
- Polycystic Ovarian Syndrome 440
- Ovulation Induction 442
- Endometriosis....445
- Cervical Intraepithelial Neoplasia (CIN) 449
- Amenorrhea 453

Chapter 13: Gynecology Short Questions....457–474

Chapter 14: Viva-Voce in Gynecology 475–495

- Gynecology Questions and Answers 476

Chapter 15: Operative Gynecology 496–546

- Dilatation and Curettage....498
- Dilatation of Cervix....501
- Dilatation and Insufflation (Rubin's Test) 501
- Hysterosalpingography 502
- Cervical Biopsy....503
- Thermal Cauterization of the Cervix....504
- Marsupialization of a Bartholin's Cyst 504
- Female Sterilization (Tubectomy) 505

- Amputation of Cervix 507
- Fothergill's Operation 508
- Operations on the Ovary 509
- Abdominal Hysterectomy 509
- Myomectomy 516
- Vaginal Hysterectomy 519
- Anterior Colporrhaphy 523
- Colpoperineorrhaphy 523
- Large Loop Excision of Transformation Zone 525
- Radical Hysterectomy 526
- Endoscopic Surgery in Gynecology 528
- Robotics in Gynecology 545

Chapter 16: Practical Gynecology 547–649

- Gynecology Instruments 548
- Specimens 592
- Imaging Studies in Gynecology 626
  - Hysterosalpingogram (HSG) 626
  - Ultrasonography (USG) 633
  - X-ray 640
  - CT scan 642
  - MRI 643
- Drugs in Gynecology
  - Clomiphene Citrate 645
  - Letrozole 645
  - Danazol 645
  - Progesterone 646
  - Combined (Estrogen and Progesterone) Oral Contraceptive Preparations (COC) 646
  - Tranexamic Acid 648
  - Mifepristone 648
  - Metformin 649
  - Methotrexate 649
  - Cisplatin/Carboplatin 649

Chapter 17: Single Best Answer and Multiple Choice Questions 650–688

Chapter 18: History in Obstetrics and Gynecology 689–693

- Eponyms in Medicine 690

Index *695*

CHAPTER

4

Labor and Delivery

Chapter Objectives

Candidate should have the knowledge and understanding of:

- Physiology of labor
- Myometrial contractions
- Assessment of fetal well-being
- Labor monitoring
- Management of normal labor
- Labor: Induction, augmentation
- Malposition, malpresentations
- Abnormal labor: Prolonged labor, obstructed labor

- Maternal Pelvis 166
- Fetal Skull 174
- Mechanism of Labor 176
  - Mechanism of Normal Labor 176
- Labor-Normal, Vaginal Delivery and Management 180
  - Preterm Labor and Delivery 191
  - Prelabor Rupture of Membranes (PROM) 197
- Labor-Abnormal 198
- Malposition and Malpresentation 198
  - Occiput Posterior Position (OP) 198
  - Breech Presentation 202
  - Face Presentation 206
  - Brow Presentation 209
  - Transverse Lie 209
  - Cord Prolapse 210
  - Compound Presentation 211
  - Unstable Lie 212
- Prolonged (Protracted) Labor 212
- Obstructed Labor 214

JAYPEE BROTHERS

MATERNAL PELVIS

Study of bony pelvis is essential from obstetric point of view (Fig. 4.1). Architecture of maternal bony pelvis is extremely important to understand the mechanism of labor and to assess the success of the vaginal delivery. Articulated pelvis is composed of four bones—innominate bones–2, the sacrum and the coccyx. There are four joints that unite the four bones—sacroiliac joints–2, symphysis pubis in front and the sacrococcygeal joint posteriorly and inferiorly.

Anatomically the pelvis is divided into:

False pelvis: The part that lies above the pelvic brim.

True pelvis: The part that lies below the brim.

Brim of the pelvis (inlet): The important landmarks on the brim of the pelvis from anterior to posterior on each side are (Fig. 4.2):

(1) Upper border of the symphysis pubis
(2) Pubic crest
(3) Pubic tubercle
(4) Pectineal line
(5) Iliopubic eminence
(6) Iliopectineal line
(7) Sacroiliac articulation
(8) Anterior border of ala of the sacrum
(9) Sacral promontory
(10) To be continued with similar borders on the opposite side

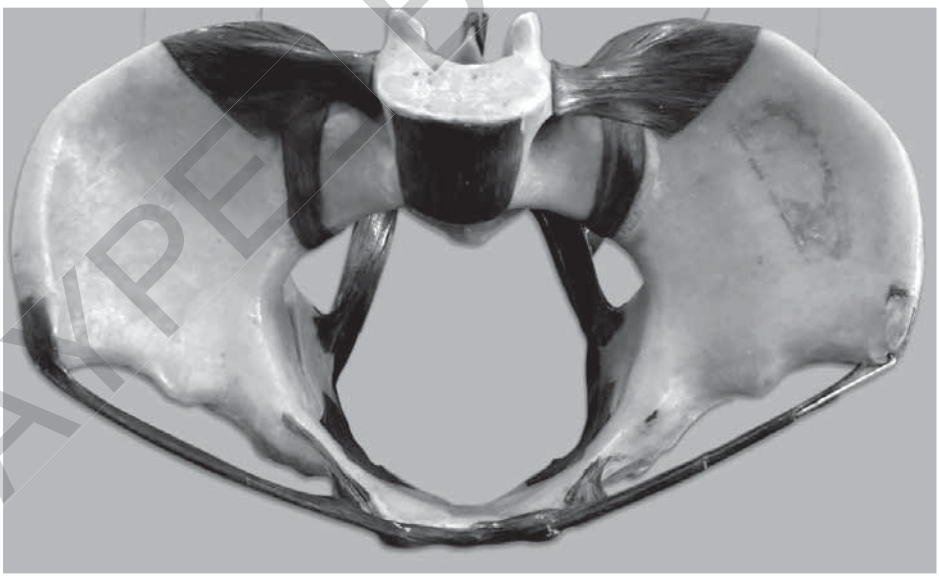

Fig. 4.1: Female pelvis: Anatomically pelvis is held with slight forward tilt, bringing the anterior superior iliac spine and the pubic symphysis in one coronal plane. This will also make the angle of inclination 55° with the horizon (Also see Figs. 4.5A and B).

JAYPEE BROTHERS

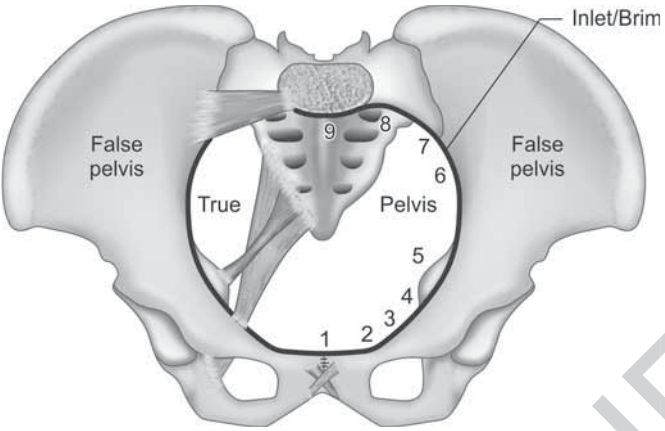

Fig. 4.2: Bony landmarks on the brim of the pelvis separating the true from the false pelvis; 1—symphysis pubis, 2—pubic crest, 3—pubic tubercle, 4—pectineal line, 5—iliopubic eminence, 6—iliopectineal line, 7—sacroiliac articulation, 8—anterior border of the ala of sacrum and 9—sacral promontory.

True pelvis: It is bounded anteriorly by symphysis pubis. It measures 4 cm (1½ inches). Posteriorly, it is bounded by the sacrum and coccyx. It measures 11.5 cm (4½ inches). True pelvis is divided into:

A. Inlet **B. Cavity** **C. Outlet**

Q. What are the different areas of the pelvis?

Ans. Two main areas are:

(1) False pelvis above. It has no obstetric significance.

(2) True pelvis below.

The boundary line between the two is the brim of the pelvis or inlet of the pelvis.

Q. What are the different parts of the true pelvis?

Ans. There are three parts:

(1) Inlet or brim of the pelvis

(2) Cavity of the pelvis

(3) Outlet of the pelvis

Q. What are the different boundary lines that divide the false pelvis, from the true pelvis?

Ans. The division between the false and true pelvis is made by the brim or inlet of the pelvis (Fig. 4.2).

Q What is the boundary line between the cavity and outlet?

Ans. The division between the cavity and outlet of the pelvis is made by the plane of least pelvic dimension (Fig. 4.3)

JAYPEE BROTHERS

Q. What are the different planes of the pelvis?

Ans. There are four planes of the pelvis (Fig. 4.3):

(A) **Plane of the inlet:** It an imaginary plane bounded by the points on the brim of the pelvis (mentioned earliers).

(B) **Plane of the cavity:** This plane extends from the mid point of the posterior surface of the symphysis pubis to junction of the second and third sacral vertebra. It is called plane of **greatest pelvic dimension**.

(C) **Plane of least pelvic dimension:** This plane extends from the lower border of the symphysis pubis to the tip of ischial spine and posteriorly it extends up to the tip of 5th sacral vertebra.

(D) **Plane of the outlet (anatomical outlet):** It is formed by a line joining the lower border of symphysis pubis to the tip of the coccyx.

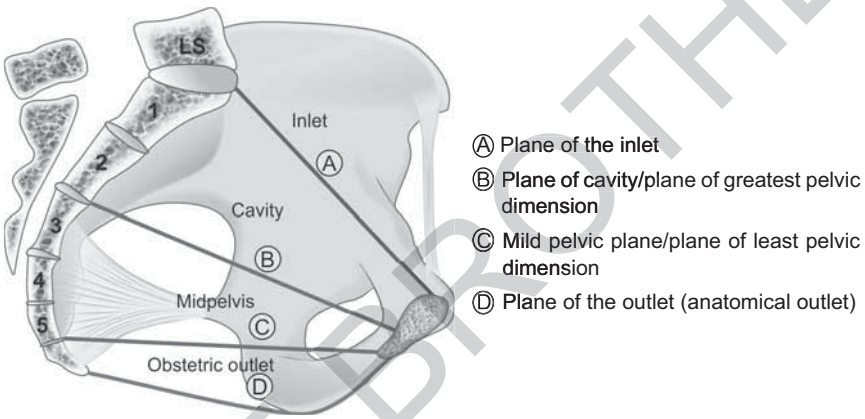

Fig. 4.3: Planes of the pelvis.

Q. Mention the different diameters at the brim of the pelvis.

Ans. (1) *Anteroposterior diameters (Fig. 4.4A)*:

(a) True conjugate, anatomical conjugate or conjugate vera: 11cm

(b) Obstetric conjugate : 10 cm

(c) Diagonal conjugate : 12 cm

(2) *Transverse diameters (Fig. 4.4B).*

(a) Anatomical transverse diameter 13 cm

(b) Obstetrical transverse diameter (≤13 cm)

(3) *Oblique diameters—12 cm (Fig. 4.4B):*

It starts from one sacroiliac joint and ends with the opposite iliopubic eminence. They are:

(a) Left

(b) Right

(c) Sacrocotyloid diameters (9.5 cm): It is the distance between the mid point of the sacral promontory to the iliopubic eminence. It is useful in flat pelvis where biparietal diameter lies during labor.

JAYPEE BROTHERS

(4) *Posterior sagittal diameters:*

(a) Cavity: Distance between the tip of the sacrum to the midpoint of bispinous diameter. It measures 5 cm.

(b) Outlet: It is the anteroposterior diameter extending between the sacrococcygeal joint and the midpoint of the transverse diameter of the outlet (anterior margin of the anus). It measures 8.5 cm.

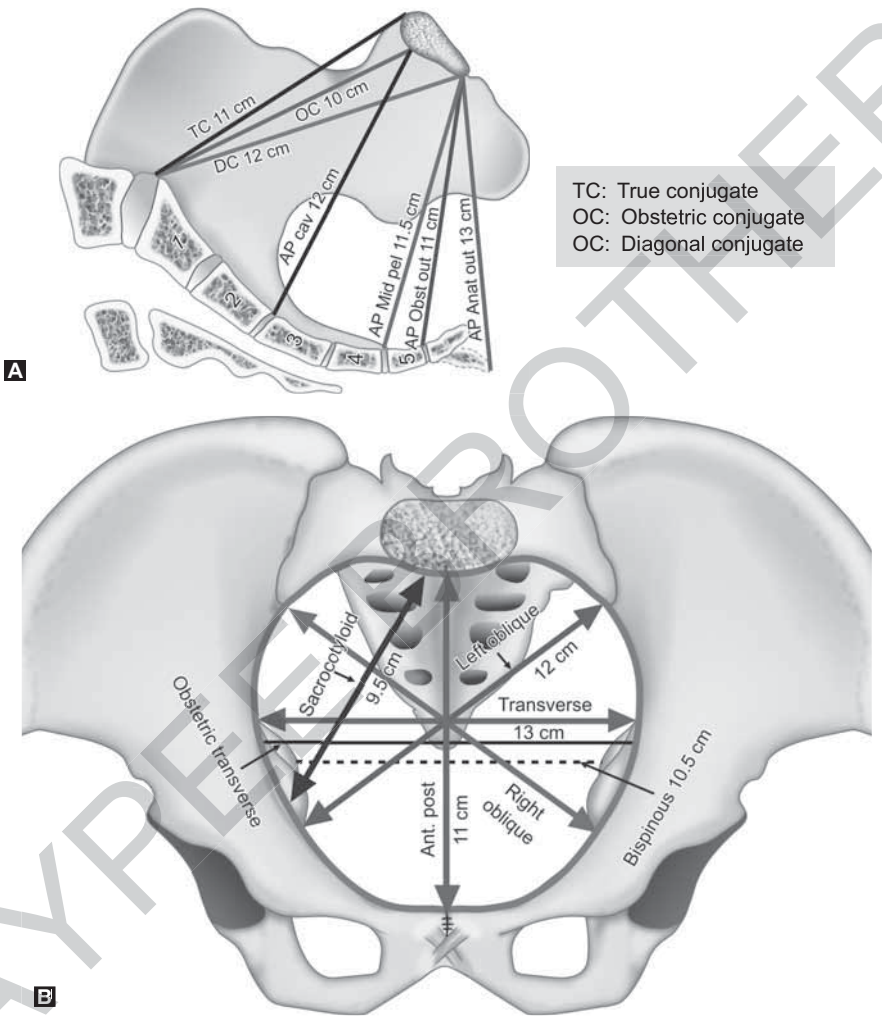

Figs. 4.4A and B: (A) Anteroposterior diameters of the pelvis; (B) Diameters of the inlet.

Q. What is the significance of the plane of least pelvic dimension?

Ans. (1) It is the **narrowest plane** in the pelvis.

(2) This plane corresponds to the **origin of levator ani muscle**. This is known as **pelvic floor**.

(3) During the course of mechanism of labor, **internal rotation of the fetal head** takes place at this plane.

(4) This level marks the beginning of the **forward curve of the pelvic axis**.

JAYPEE BROTHERS

(5) Pudendal nerve hooks around the dorsal surface of the ischial spine and enters the perineal pouch. It is a landmark used for **pudendal nerve block analgesia**.
(6) Bispinous diameter (10.5 cm): The distance between the tips of two ischial spines is in this plane. **Station of the presenting part** is expressed in either (above) – or (below) + in relation to this plane
(7) Deep transverse arrest (DTA) usually occurs at this plane.

Q. What are the different axes of the pelvis?

Ans. There are two axes:
(a) **Anatomical pelvic axis (curve of Carus)**: It is an uniformly curved line fitting with the concavity of the sacrum. It is formed by joining the axes of the inlet, cavity and outlet. Fetus does not traverse through this path (Fig. 4.5A).
(b) **Obstetric pelvic axis:** Fetal head negotiates through the obstetric pelvic axis. It is directed first downwards and backwards from the brim up to the level of ischial spine, then abruptly forwards (Fig. 4.5B).

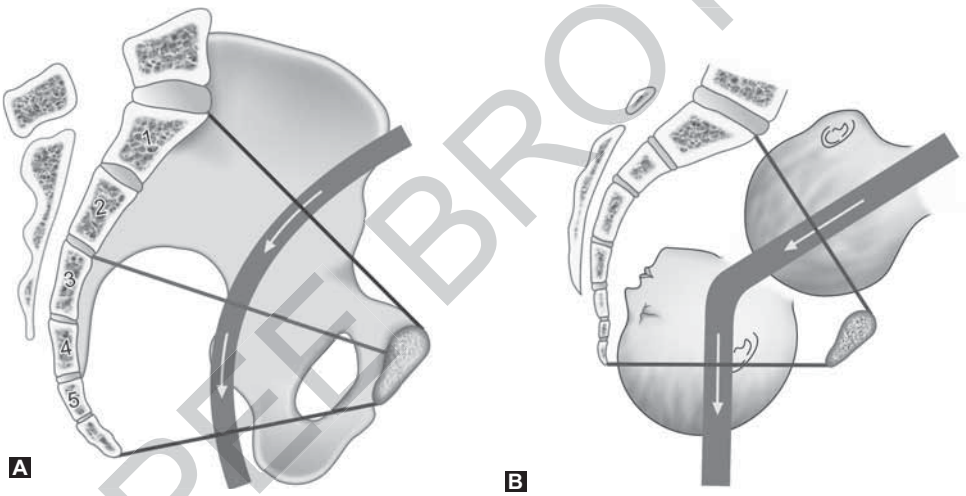

Figs. 4.5A and B: (A) Anatomical pelvic axis; (B) Obstetric pelvic axis.

Q. What are the different bones that constitute the pelvis?

Ans. The bones are four. These are:
(1) Innominate bones—2 (on one either side)
(2) Sacrum—1
(3) Coccyx—1

Q. What are the different joints in the pelvis?

Ans. Joints are total four:
(1) Sacroiliac joints—2: One on either side: These are synovial joints
(2) Symphysis pubis: Fibrocartilaginous joints
(3) Sacrococcygeal joints: Synovial hinge joint.

JAYPEE BROTHERS

Q. What are the different types of female pelvis?

Ans. On the basis of the shape of the inlet, female pelvis is divided into four parent types:

(A) Gynecoid (50%) (B) Anthropoid (25%)
(C) Android (20%) (D) Platypelloid (5%)

However, in majority of cases, combination of features is found.

Q. What are the important differences in the four types of parent pelvis?

Ans. Differences between four types of pelvis have been described below in tabular form:

Pelvis type	Inlet	Midcavity	Outlet: Subpubic angle
A. Gynecoid	Round 	Divergent sidewalls, Ischial spines (IS): Not prominent	Wide (85°) TDO: 11 cm
B. Anthropoid	Anteroposteriorly oval 	Straight or divergent Sidewalls Ischial spines: Prominent	Slightly narrow (medium) TDO: 11 cm
C. Android	Triangular 	Convergent sidewalls, IS: Prominent	Narrow TDO: <11 cm
D. Platypelloid	Transversely oval 	Divergent sidewalls, IS: Not prominent	Very wide >90° TDO: 11 cm

Note: Different diameters of the female bony pelvis have been measured by X-ray pelvimetry and computed tomography (CT). However, CT and X-ray pelvimetry are rarely used for pelvic assessment in labor. **Clinical pelvimetry is the only method of assessing the pelvis in labor. Fetal head is the best pelvimeter**.

Q. What is diagonal conjugate?

Ans. It is the distance between the lower border of the symphysis pubis and the midpoint on the sacral promontory. It measures 12 cm (4¾ inches).

JAYPEE BROTHERS

Q. How do you measure the diagonal conjugate?

Ans. Steps of assessment (Fig. 4.6):

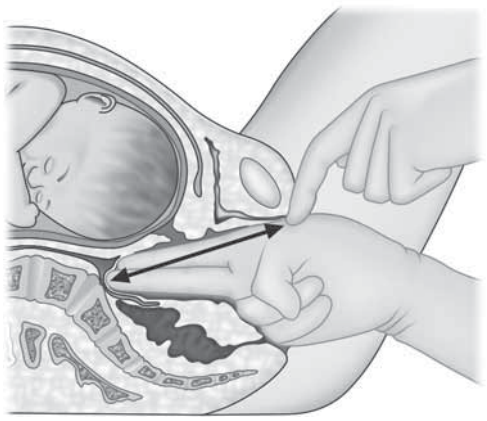

Fig. 4.6: Measurement of diagonal conjugate.

Diagonal conjugate:
Two fingers of gloved right hand are introduced into the vagina along the sacral curvature to reach the sacral promontory. In a normal pelvis, it is usually not felt. The point where the bone recedes from the fingers is the sacral promontory. The radial border of the fingers are then mobilized underneath the symphysis pubis and a mark is made over the gloved index finger. The distance between the marking and the tip of the middle finger is the measurement of diagonal conjugate.

Q. What is angle of pelvic inclination?

Ans. See Fig. 4.7.

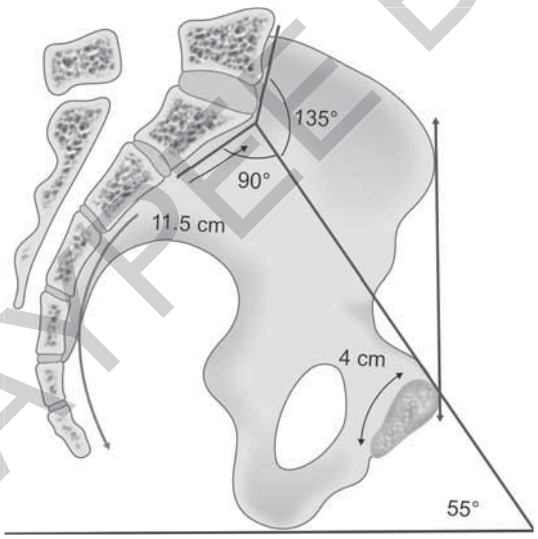

Fig. 4.7: Angle of inclination.

Angle of pelvic inclination:
Angle of pelvic inclination is the angle subtended by the plane of pelvic inlet with the horizon, when the plane of pelvic inlet is extended downwards to meet the ground. It is measured when the woman is in upright standing position. The anterior superior iliac spine and the pubic tubercle are in the same vertical plane. The angle measures about 55°.

JAYPEE BROTHERS

Q. What is the bony pelvic outlet?

Ans. See Fig. 4.8.

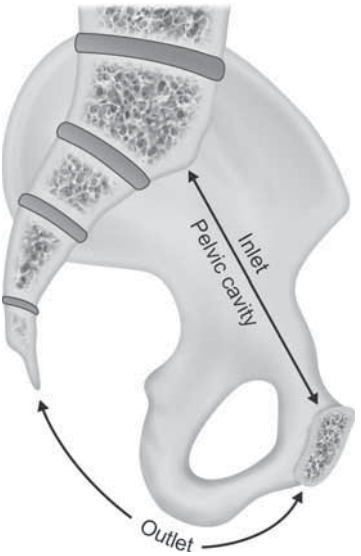

Fig. 4.8: Pelvic outlet.

Bony pelvic outlet or anatomical pelvic outlet: It is bounded anteriorly by the under surface of the symphysis pubis, laterally by the conjoint ischiopubic rami, ischial tuberosity and sacrotuberous ligament and posteriorly by the tip of the coccyx. (*See* also Fig. 4.7)

Q. What is meant by transverse diameter of the outlet?

Ans. See Fig. 4.9.

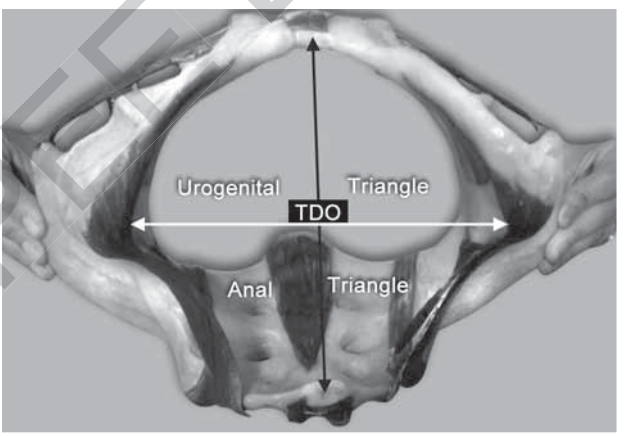

Fig. 4.9: Bony pelvic outlet. (TDO is shown).

Transverse diameter of the Outlet (TDO): It is the distance between the inner margin of the two ischial tuberosities. It measures 11 cm. Clinically, it is measured by placing the four knuckles of the clinched fist placed between the two ischial tuberosities. TDO forms the common base for the two triangular planes. The apex of the anterior triangle (urogenital) is formed by the inferior border of the pubic arch. The apex of the posterior triangle (anal) is formed by the sacrococcygeal joint.

JAYPEE BROTHERS

FETAL SKULL

Fetal skull is arbitrarily divided into several zones of obstetric significance (Fig. 4.10).

These are: ♦ Vertex ♦ Brow ♦ Face ♦ Sinciput ♦ Occiput ♦ Fontanelles.

(1) Fontanelle: Anterior (Bregma)
Posterior (Lamda)

(2) Sutures: Sagital (between the two parietal bones)
parietal, frontal, occipital (lamdoid suture)

(3) Anteroposterior diameters (Varies with degree of flexion):

(i) Complete flexion (when chin touches chest)
Suboccipitobregmatic diameter : 9.5 cm

(ii) Incomplete flexion:
Suboccipitofrontal diameter : 10 cm

(iii) Markedly deflexed:
Occipitofrontal diameter : 11.5 cm

(iv) Partial extension
Mentovertical diameter : 14 cm

(v) Incomplete extension
Submentovertical diameter : 11.5 cm

(vi) Complete extension
Submentobregmatic diameter : 9.5 cm

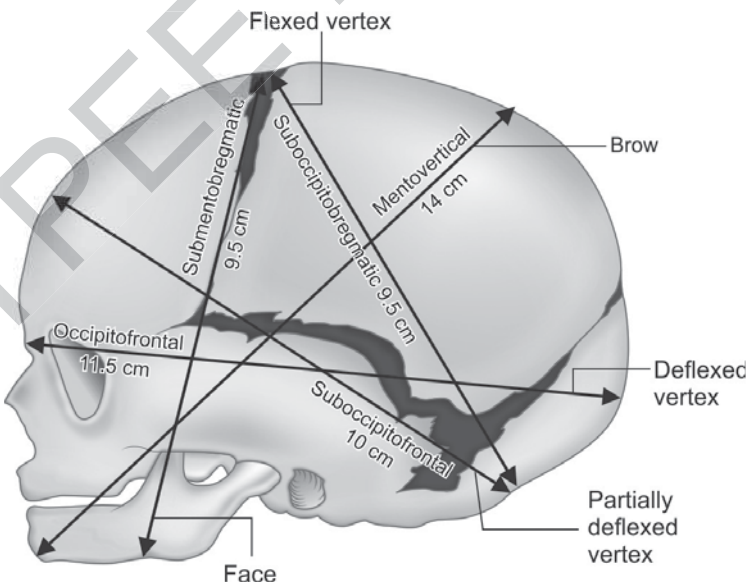

Fig. 4.10: Important landmarks of fetal skull.

JAYPEE BROTHERS

(4) Transverse diameters of the fetal skull:

(i) Biparietal diameter : 9.5 cm
(ii) Super-subparietal diameter (Asynclitism) : 8.5 cm
(iii) Bitemporal diameter : 8 cm
(iv) Bimastoid diameter : 7.5 cm

(Not compressible even after doing craniotomy.

Q. Mention the different engaging diameters of the skull that come into play from the attitude of complete flexion to complete extension.

Ans. (*See* Table below)

	Diameters	**Measurement in cm (inches)**	**Attitude of the head**	**Presentation**
1.	*Suboccipitobregmatic*—extends from the nape of the neck to the center of the bregma	9.5 cm (3¾")	Complete flexion	Vertex
2.	*Suboccipitofrontal*—extends from the nape of the neck to the anterior end of the anterior fontanelle or center of the sinciput	10 cm (4")	Incomplete flexion	Vertex
3.	*Occipitofrontal*—extends from the occipital eminence to the root of the nose (glabella)	11.5 cm (4½")	Marked deflexion	Vertex
4.	*Mentovertical*—extends from the midpoint of the chin to the highest point on the sagittal suture	14 cm (5½")	Partial extension	Brow
5.	*Submentovertical*—extends from junction of floor of the mouth and neck to the highest point on the sagittal suture	11.5 cm (4½")	Incomplete extension	Face
6.	*Submentobregmatic*—extends from junction of floor of the mouth and neck to the center of the bregma	9.5 cm (3¾")	Complete extension	Face

JAYPEE BROTHERS

MECHANISM OF LABOR

MECHANISM OF NORMAL LABOR

Q. What do you understand by the mechanism of labor?

Ans. It is the series of movements that occur in the fetal head in the process of adaptation during its journey through the pelvis.

Q. What are the principal movements that occur on the fetal head during the course of labor (mechanism of labor)?

Ans. The cardinal movements are: Here, it is described as in left occiput posterior position (Fig. 4.11).

(1) **Engagement:** Biparietal diameter passes through the pelvic brim. In a primigravida, engagement usually occurs before the onset of labor, whereas in a multigravida the same may occur during the course of labor.

(2) **Descent:** It is a continuous process throughout the course of labor.

(3) **Flexion:** Flexion is achieved when the head meets the resistance of the birth canal (pelvic floor muscles, cervix, pelvic walls) during descent. Flexion brings lesser diameter in the pelvis.

(4) **Internal rotation:** It is mainly due to:

(i) Gutter-shaped arrangement of the levator ani muscles (two halves)

(ii) Pelvic shape having the long anterior-posterior diameter of the outlet to accommodate the long diameter of the fetal head.

(5) **Crowning:** The biparietal diameter stretches the vulval outlet and there is no recession of the head even when the contractions are over.

(6) **Extension:** It is the result of final driving force that expels the fetal head out. The uterine contraction force is directed downward and the forces exerted by the pelvic and perineal floor muscles are upward and forward. The resultant force drives the head downward and upward (extension).



Fig. 4.11: Extension of the fetal head during normal delivery.

JAYPEE BROTHERS

(7) **Restitution:** It is the rotation of the head (45°) due to untwisting of the neck that occurred during internal rotation.

(8) **External rotation:** It is due to internal rotation of the shoulder.

(9) **Delivery of the shoulders:** The shoulders are placed in the antero-posterior diameter of the outlet. With further descent, the anterior shoulder is pushed below the symphysis pubis and is born first. Posterior shoulder then sweeps over the perineum by lateral flexion.

(10) **Delivery of the trunk:** It occurs by lateral flexion.

Q. What do you understand by asynclitism? What is its significance?

Ans. See p. 186.

STEPS FOR THE DEMONSTRATION OF MECHANISM OF LABOR

METHOD OF HOLDING THE MATERNAL BONY PELVIS ANATOMICALLY AND TO DEMONSTRATE THE PELVIC DIAMETERS AND MECHANISM OF LABOR

The bony pelvis is held with the fingers of the left hand. The left-sided ischium bone of the maternal bony pelvis is held with the fingers of the left hand keeping the symphysis pubis in front and the sacrum behind (Fig. 4.12). It is convenient to hold the ischium bone by the index, and middle fingers passing through the obturator foramen. The thumb is placed behind the ischium. A firm grip is made with pressure using the fingers as described earlier. Now the pelvis is held with a forward tilt to maintain the other points in relation to the anatomical position (*See* description Fig. 4.1, p. 166 and Fig. 4.7, p. 172). The right hand fingers are free for demonstration.



Fig. 4.12: Anatomical position of the pelvis.

JAYPEE BROTHERS

Q. How to hold the fetal skull?

Ans. The index finger of the right hand is introduced through the foramen magnum (Fig. 4.13A) and the skull is hold by the thumb and the middle fingers placed over the parietal eminence one on either side. The occiput is directed anteriorly and the vault of the skull directed below (Fig. 4.13B). The occiput is tilled downwards so as to put the mentum at a higher level. This suggests attitude of flexion of the head.

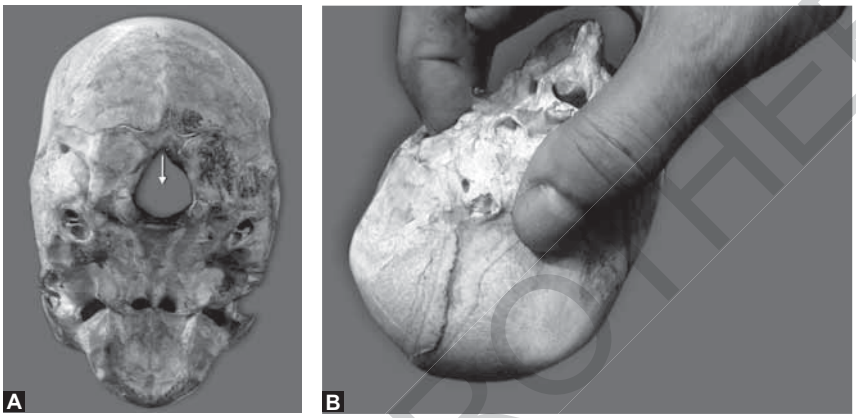

Figs. 4.13A and B: (A) Base of skull showing foramen magnum; (B) Demonstration of holding fetal skull is shown. Index finger is placed within the foramen magnum and the thumb and the middle finger are placed over the parietal eminence one on either side.

PROCEDURES TO DEMONSTRATE THE POSITION OF FETAL HEAD IN RELATION TO THE QUADRANT OF THE PELVIS

Q. Show the left occiput anterior position?

Ans. The maternal bony pelvis and the fetal skull are held as described in Fig. 4.14. Now the candidate is needed to direct the occiput of the fetal skull towards the left iliopubic eminence of the maternal bony pelvis (Fig. 4.15).



Fig. 4.14: Demonstration of the position of fetal head in relation to the Quadrant of the pelvis. Maternal pelvis (left hand) and fetal skull (right hand) is held and the position of left occiput anterior position is demonstrated.

JAYPEE BROTHERS

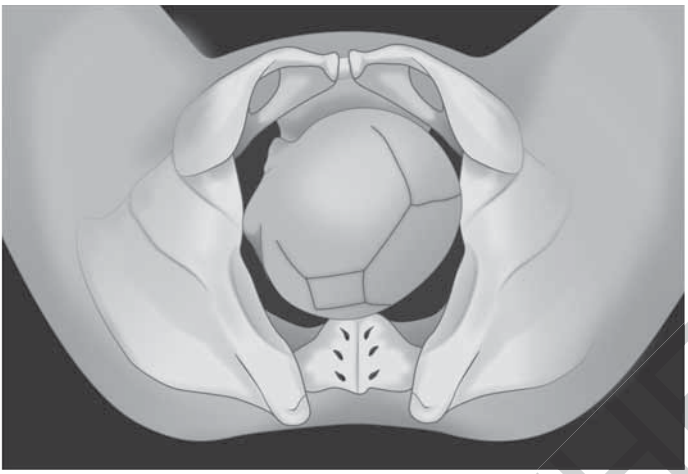

Fig. 4. 15: Left occiput anterior (LOA) (viewed from below).

Q. Show the left occiput transverse position of the fetal skull?

Ans. The candidate needs to direct the occiput towards left end of the obstetric transverse diameter of the pelvis (Fig. 4.16).

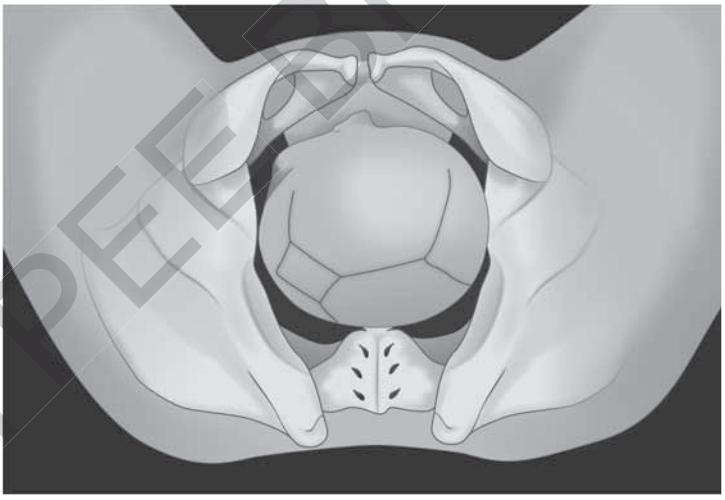

Fig. 4.16: Left occiput transverse (LOT) (viewed from below).

Q. Show the right occiput transverse position of the fetal skull?

Ans. The candidate needs to direct the occiput towards right end of the obstetric transverse diameter of the pelvis (Fig. 4.17).

JAYPEE BROTHERS



Fig. 4.17: Right occiput transverse position (ROT) (viewed from below).

LABOR–NORMAL, VAGINAL DELIVERY AND MANAGEMENT

Q. How do you define labor?

Ans. **Labor** is the series of changes that take place in the genital organs in an effort to expel the viable fetus from the womb to the outside world through the vagina. Labor begins when the uterine contractions are of sufficient frequency, intensity and duration to cause progressive effacement and dilatation of the cervix.

Q. What do you understand by delivery?

Ans. Delivery is the process of expulsion or extraction of a viable fetus out of the womb. Delivery can take place without labor as in elective cesarean delivery (abdominal). However, delivery may be vaginal also (forceps or ventouse delivery).

Q. What is normal labor?

Ans. Normal labor fulfills the following criteria:

(1) Fetus with vertex presentation
(2) Spontaneous onset of term
(3) Without undue prolongation of labor
(4) Spontaneous delivery with minimal aids
(5) Without any complications.

Q. What are the clinical stages of labor?

Ans. Stages of labor are total three:

First stage begins with onset of true labor pains and ends with full dilatation of the cervix (10 cm). Its duration is 12 hours in a primigravida and 6 hours in a multigravida.

JAYPEE BROTHERS

for detailed information on obstetrics & gynecology books, visit our website www.jaypeebrothers.com, for detailed information on obstetrics & g

Dutta's Bedside Clinics and Viva-Voce in Obstetrics & Gynecology

Salient Features

- Covers comprehensively the entire zone of Clinical, Practical and Viva-Voce part of the examination, fulfilling University course curriculum
- Answers are framed in a simple and concise way for easy understanding and reproduction
- Immensely helpful for quick revision of the entire course, to those having a background of textbook knowledge
- Model answers are made to guide a candidate how to write the theory questions (short questions chapters both in obstetrics and gynecology section)
- Topics on ultrasonography, doppler studies, computed tomography (CT), magnetic resonance imaging (MRI), positron emission tomography (PET), laparoscopic and hysteroscopic surgery and robotic surgery have been incorporated extensively to acquaint a candidate with the progress of Science and technology
- SBAs and MCQs are presented with model answers for wide coverage of the subject and to make up the weak areas
- Exhaustive number of clinical photographs, graphs, sketches and line drawings have been included for better understanding of difficult areas
- Authoritative and comprehensive synoptic guide for the Clinical and Viva-Voce part of the examination
- Above all, the information is up-to-date, evidence-based, and the reading is simple and enjoyable.

Available at all medical bookstores
or buy online at www.jaypeebrothers.com

JAYPEE BROTHERS
Medical Publishers (P) Ltd.
www.jaypeebrothers.com

Join us on facebook.com/JaypeeMedicalPublishers

Shelving Recommendation
OBSTETRICS & GYNECOLOGY

ISBN 978-93-5270-701-0

9 789352 707010