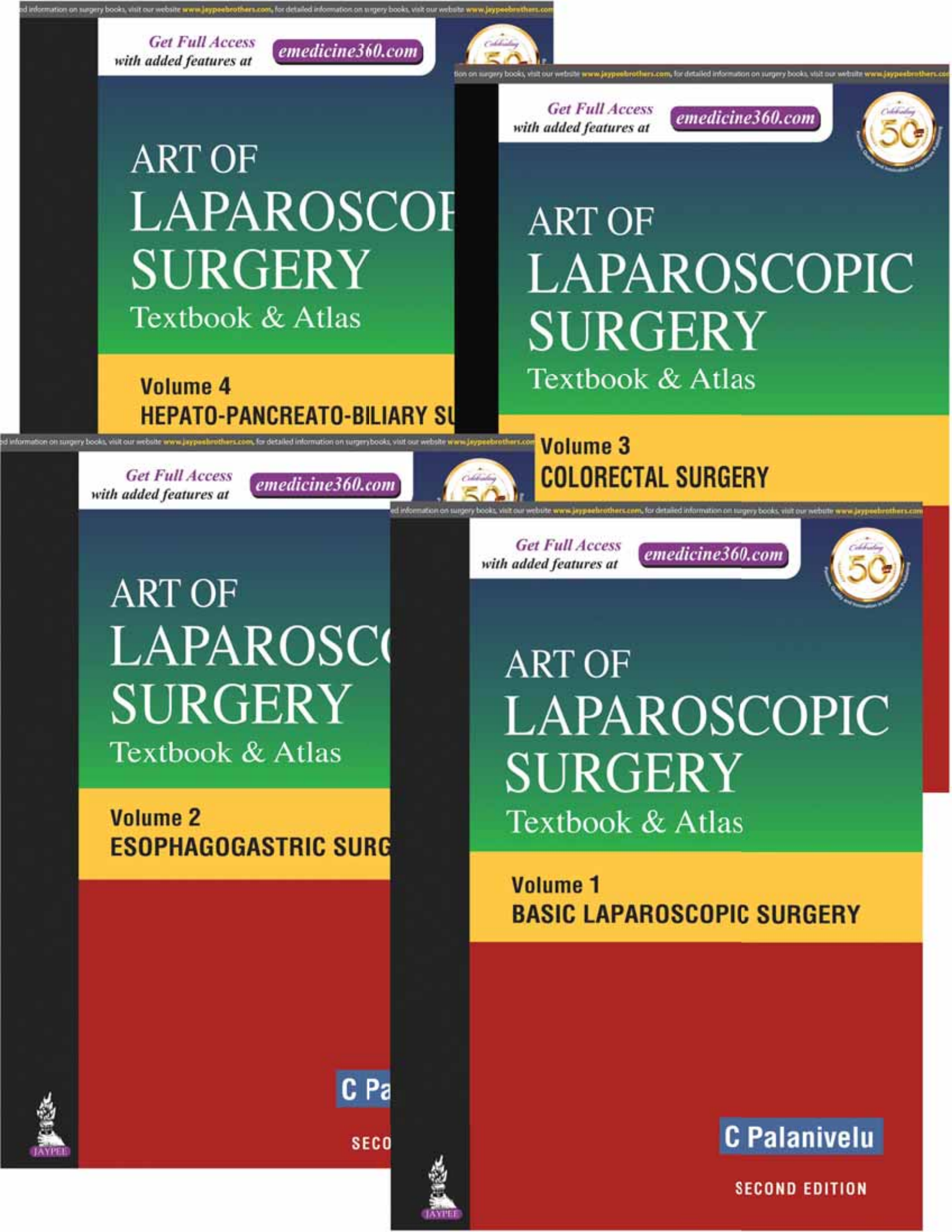
Get Full Access
with added features at
emedicine360.com
ART OF
LAPAROSCOPIC
SURGERY
Textbook & Atlas
Volume 4
HEPATO-PANCREATO-BILIARY SU
Volume 3
COLORECTAL SURGERY
Volume 2
ESOPHAGOGASTRIC SURG
Volume 1
BASIC LAPAROSCOPIC SURGERY
C Palanivelu
SECOND EDITION
JAYPEE

ART OF LAPAROSCOPIC SURGERY

Textbook and Atlas

Second Edition

VOLUME 4: HEPATO-PANCREATO-BILIARY SURGERY

C Palanivelu MS MCh FRCS FACS PhD DSc
Chair, Division of Surgical Gastroenterology and
Minimal Access Surgery
Director, GEM Hospital and Research Center
Coimbatore, Tamil Nadu, India



JAYPEE BROTHERS MEDICAL PUBLISHERS
The Health Sciences Publisher
New Delhi | London | Panama

JAYPEE BROTHERS

Contents

Volume 1: Basic Laparoscopic Surgery

1. History of Laparoscopic Surgery 1
2. Instrumentation and Imaging Systems in Laparoscopy 13
3. Anesthesia for Laparoscopic Surgery 35
4. Sterilization and Disinfection of Laparoscopic Instruments 47
5. Laparoscopic Space Access 62
6. Laparoscopic Tissue Approximation 73
7. Laparoscopic Hemostasis 111
8. Setting-up of Laparoscopic Operation Theater 127
9. Room Layout 130
10. Preoperative Imaging in Minimally Invasive Surgery 135
11. Diagnostic Laparoscopy: Indications, Tuberculosis, and Adhesiolysis 152
12. Staging Laparoscopy in Malignancy 175
13. Laparoscopy in Pregnancy 186
14. Reoperative Laparoscopic Surgery 201
15. Specimen Retrieval Systems in Laparoscopic Surgery 212
16. Complications of Laparoscopy 225
17. Single Incision Laparoscopic Surgery 233
18. Robotic Surgery 251
19. Laparoscopy in Pediatric Surgery: Current Practice 259
20. Metabolic Surgery: Current Concepts 264
21. Video-assisted Thoracic Surgery and Thymectomy 271
22. Head and Neck Minimal Access Surgery 279
23. Minimally Invasive Hernia Surgery: Current Practice 287
24. Training in Laparoscopy 297
25. Occupational Hazards for the Laparoscopic Surgeon 311
26. Documentation in Laparoscopic Surgery 316

JAYPEE BROTHERS

27. Laparoscopic Training for Staff Nurse 325
28. Enhanced Recovery after Surgery 330

Index *I-1–I-10*

Volume 2: Esophagogastric Surgery

SECTION 1: ESOPHAGUS

29. Anatomy of the Mediastinum, Esophagus, Hiatus, and Diaphragm 337
30. Laparoscopic Management of Achalasia Cardia 359
31. Gastroesophageal Reflux Diseases 384
32. Laparoscopic Management of Gastroesophageal Reflux Diseases 392
33. Laparoscopic Repair of Paraesophageal Hernia 414
34. Reoperative Antireflux Surgeries 430
35. Laparoscopic Management for Peptic Esophageal Stricture 440
36. Thoracoscopic or Laparoscopic Management of Benign Esophageal Diseases 446
37. Thoracolaparoscopic Management of Boerhaave's Syndrome 474
38. Foreign Bodies in the Foregut: Minimally Invasive Approach 482
39. Corrosive Injuries of Esophagus: Minimally Invasive Approach 497
40. Minimally Invasive Surgery in Esophageal Carcinoma: Current Concepts 507
41. Thoracolaparoscopic McKeown Esophagectomy 523
42. Laparoscopic Esophagogastrectomy and Intrathoracic Anastomosis (Ivor Lewis Esophagectomy) 546
43. Laparoscopic Transhiatal Esophagectomy 566
44. Complications of Esophagectomy 572

SECTION 2: STOMACH AND DUODENUM

45. Laparoscopic Management of Peptic Ulcer Disease 579
46. Laparoscopic Management of Gastric GIST 598
47. Gastric NET and Duodenal NET: Minimally Invasive Approach 617
48. Minimally Invasive Approach for Foreign Body in Stomach 623
49. Corrosive Injuries of Stomach: Minimally Invasive Approach 633
50. Laparoscopic Management of Gastric Volvulus 644
51. Laparoscopic Management of Median Arcuate Ligament Syndrome 654
52. Laparoscopic Duodenojejunostomy for Wilkie's Syndrome 658

JAYPEE BROTHERS

53. Laparoscopic Duodenal Excision in Nonampullary Tumors 665
54. Laparoscopic Surgery for Morbid Obesity: Current Concepts 676
55. Minimally Invasive Surgery for Gastric Carcinoma: Current Concepts 689
56. Laparoscopic D2 Subtotal and Total Gastrectomy 710

SECTION 3: POSTSCRIPT

57. Anesthetic Considerations in Thoracoscopic Esophagectomy 731
58. Early Postoperative Management in Thoracolaparoscopic Esophagectomy 739
59. Palliative Procedures in Upper GI Malignancies 744
60. Robotics in Upper Gastrointestinal Surgery 748
61. Thoracolaparoscopic Esophagectomy in Abnormal Anatomy (Situs Inversus Totalis) 751
62. Single-Incision Laparoscopy in Esophagogastric Surgery 754

Index *II-1–II-10*

Volume 3: Colorectal Surgery

63. Introduction 765
64. Applied Laparoscopic Anatomy of the Colon, Rectum and Anal Canal 776
65. Laparoscopic Colorectal Surgery Preoperative Workup and Staging 792
66. Laparoscopic Colorectal Surgery: Evidences 804
67. Laparoscopic Appendectomy 821
68. Laparoscopy in Small Bowel Obstruction 852
69. Intussusception 870
70. Laparoscopic Excision of Meckel's Diverticulum 881
71. Laparoscopic Management of Midgut Malrotation 892
72. Laparoscopic Management of Inflammatory Bowel Disease: Crohn's and Ulcerative Colitis 904
73. Laparoscopic Management of Rectal Prolapse 912
74. Laparoscopic Management of Parastomal Hernia 931
75. Laparoscopic Right Hemicolectomy: IRETA with Uncinate Process Approach 938
76. Laparoscopic Left Hemicolectomy 955
77. Laparoscopic Anterior Resection and Ultralow Anterior Resection 967
78. Laparoscopic Intersphincteric Resection with Coloanal Anastomosis 990
79. Laparoscopic Abdominoperineal Resection 1009

JAYPEE BROTHERS

80. Laparoscopic Total and Subtotal Colectomy **1024**
81. Laparoscopic Total Proctocolectomy with Ileal Pouch-anal Anastomosis **1040**
82. Laparoscopic Stoma Creation **1062**
83. Laparoscopic Management of Sigmoid Volvulus **1070**
84. Laparoscopic Hartmann's Procedure Reversal **1081**
85. Laparoscopic Management of Colovesical Fistula **1091**
86. Laparoscopic Management of Diverticular Disease **1102**
87. Laparoscopic Management of Rectovaginal Fistula **1118**
88. Single-Incision Multiport: Laparoscopic Colorectal Surgery **1129**
89. Transanal Endoscopic Microsurgery/Transanal Minimally Invasive Surgery **1145**
90. Combined Endoscopic Laparoscopic Procedure in Colorectal Surgery **1156**
91. Complications of Laparoscopic Colorectal Surgery **1164**

Index *III-1–III-10*

Volume 4: Hepato-Pancreato-Biliary Surgery

SECTION 4: BILIARY

92. Anatomy of Biliary System: Laparoscopic Bile Duct Injury Management **1187**
93. Laparoscopic Cholecystectomy, Indications, and Management **1195**
94. Laparoscopic Management of Acute Cholecystitis **1224**
95. Laparoscopic Management of Difficult Gallstone Disease **1239**
96. Laparoscopic Cholecystectomy in Cirrhotic Liver Problems and Management **1275**
97. Laparoscopic Modified Subtotal Cholecystectomy Indications and Techniques **1282**
98. Laparoscopic Bile Duct Injury and Management **1292**
99. Laparoscopic Treatment of Common Bile Duct Stones **1304**
100. Laparoscopic Choledochal Cyst Excision **1333**
101. Laparoscopic Management of Carcinoma Gallbladder **1356**

SECTION 5: LIVER

102. Anatomy of Liver **1375**
103. Laparoscopic Management of Benign Nonparasitic Hepatic Cysts **1392**
104. Laparoscopic Management of Hepatic Hydatid Disease **1399**
105. Laparoscopic Management of Liver Abscess **1430**

JAYPEE BROTHERS

106. Laparoscopic Parenchymal Transection Techniques and Instruments 1432
107. Laparoscopic Minor Hepatectomy 1438
108. Laparoscopic Hepatic Resection 1452
109. Laparoscopic Donor Hepatectomy 1469
110. Laparoscopic Radiofrequency Ablation in Hepatic Malignancies 1479

SECTION 6: SPLEEN

111. Laparoscopic Splenectomy 1491
112. Laparoscopic Splenopexy 1510

SECTION 7: PANCREAS

113. Anatomy of Pancreas 1521
114. Role of Laparoscopy in Acute Pancreatitis and its Complications 1529
115. Laparoscopic Management of Chronic Pancreatitis 1546
116. Laparoscopic Radical Distal Pancreatectomy 1561
117. Laparoscopic Spleen-preserving Distal Pancreatectomy 1570
118. Laparoscopic Median Pancreatectomy 1575
119. Laparoscopic Uncinate Process Excision 1586
120. Laparoscopic Pancreas-preserving Duodenectomy 1592
121. Laparoscopic Whipple Procedure 1601
122. Laparoscopic Management of Annular Pancreas 1633
123. International Summit on Laparoscopic Pancreatic Resection (ISLPR) "Coimbatore Summit Statements" 1640

Index *IV-1–IV-10*

JAYPEE BROTHERS

Preoperative Imaging in Minimally Invasive Surgery

CHAPTER 10

INTRODUCTION

In every surgical patient, proper preoperative imaging is essential in accurate diagnosis and helps in planning management. Ultrasonography (USG) abdomen, upper gastrointestinal (GI) endoscopy, colonoscopy, endoscopic ultrasound (EUS), contrast-enhanced computed tomography (CECT) chest and abdomen, and magnetic resonance imaging (MRI) abdomen and pelvis are routinely ordered investigations in gastroenterology patients.

Ultrasonography abdomen is the routine and basic initial investigation, helps us in identifying various abdominal conditions, like appendicitis, gallbladder (GB) calculi, various cystic lesions of liver, ascites, etc. CECT abdomen helps in doubtful conditions and in preoperative staging of various GI malignancies. MRI abdomen/pelvis is advised in hepatic/biliary lesions, suspected rectal lesions, and gynecological malignancies. Endoscopy is used for diagnosis and for biopsy of suspected lesions.

Ultrasonography, CECT abdomen, and MRI are routinely used at various centers and here in this chapter we are mainly focusing on the EUS and laparoscopic ultrasound (LUS), which are not routinely used.

ENDOSCOPIC ULTRASOUND/ ECHOENDOSCOPE

Endoscopic ultrasound was first developed by Olympus corporation to improve imaging of pancreaticobiliary system.[1] In 1980, the first mechanical radial EUS (180° mechanical radial scanner) was applied clinically (DiMagno et al., 1980).

Endoscopic ultrasound probes are available in various diameters (2–2.9 mm), frequencies (12–30 MHz), and lengths (170–220 cm). Higher ultrasound frequency yields higher resolution at the expense of reduced depth of penetration (reported depths of penetration are 29 mm for the 12 MHz probe and 18 mm for the 20 MHz probe).[2]

Acoustic coupling between the probe and tissue can be achieved by several methods, including close apposition of the probe to tissue with air aspiration, instillation of liquid into the gut lumen, use of a condom over the tip of the endoscope, and use of a balloon sheath over the probe.

Radial Endoscopic Ultrasound

The radial type scans in a plane perpendicular to the axis of the scope to produce 360° images similar to a computed tomography (CT) "slice." The transducer appears as a "bull's-eye" within the image.

Linear Endoscopic Ultrasound

The linear array type scans in a plane parallel to the axis of the scope. It is therapeutic in nature. It has the advantage of allowing visualization of a needle while performing a procedure.

Catheter-based Endoscopic Ultrasound Probes (Miniprobes)

They consist of a cable with a mechanical transducer at its end. The majority of miniprobes use a radial transducer; however, dual-plane reconstruction probes are also available and these allow the user to scan simultaneously in both linear and radial planes. The miniprobe is inserted down the working channel of a regular endoscope. Air is removed from the lumen, which is then filled with water to allow transmission of the ultrasound.

Contrast-enhanced Diffusion Endoscopic Ultrasound

It helps in differentiating hypervascular from hypovascular areas.

JAYPEE BROTHERS

Contrast-enhanced Harmonic Endoscopic Ultrasound

It helps in better visualization of the microcirculation and parenchymal perfusion, and better differentiation of tissue enhancement for more accurate classification.

Uses of Endoscopic Ultrasound

Diagnostic Uses

- For staging of GI lesions
- Endoscopic ultrasound-guided fine needle aspiration (EUS-FNA)
- Endoscopic ultrasound-guided tissue elastic imaging (EUS elastography).

In Upper Gastrointestinal Malignancies

Esophageal malignancies

The pooled sensitivity and specificity of EUS for assessing tumor depth per T stage were 81.6% and 99.4% for T1, 81.4% and 96.3% for T2, 91.4% and 94.4% for T3, and 92.4% and 97.4% for T4 (Fig. 10.1). "Sensitivity, specificity, and accuracies for the diagnosis of malignant lymph nodes (LNs) by EUS were 49–99%, 33–99%, and 71–96%. EUS-FNA staging was better than EUS staging as it has no clinically obvious complications, has sensitivity 81–97%, specificity 83–100%, and accuracy 83–97%."

After neoadjuvant treatment, because of fibrosis and inflammation which are indistinguishable from residual tumor, the accuracy of EUS is lower than initial staging accuracy.[3]

Stomach malignancies (Figs. 10.2 and 10.3)

Endoscopic ultrasound is used mainly in staging of gastric cancers, especially in early gastric cancer (EGC). Lesions on EUS are found as areas of focal thickening, irregularity, or disruption of the layers. The accuracy of EUS in T staging varies from 65% to 92.1%. For N staging the accuracy varies from 66% to 90%. EUS-FNA for nodal staging, the accuracy has improved and the sensitivity, specificity, and positive predictive value of EUS-FNA are reported to be 92%, 98%, and 97%, respectively. However, it cannot detect distant metastasis and hence has to be followed by other modalities like CECT abdomen to rule out metastasis. EUS cannot be used when entire length of lesion cannot be assessed as in cases of stricture. Ulceration and diffuse type of histology are also important factors in determining the accuracy of EUS.

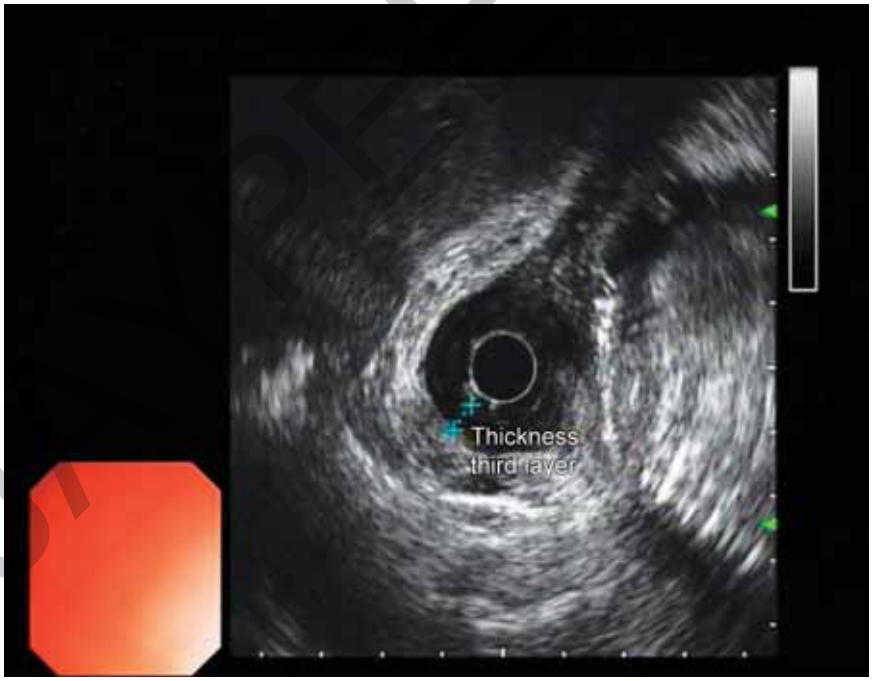

Fig. 10.1: Diagnostic endoscopic ultrasound in staging of esophageal cancer.

JAYPEE BROTHERS

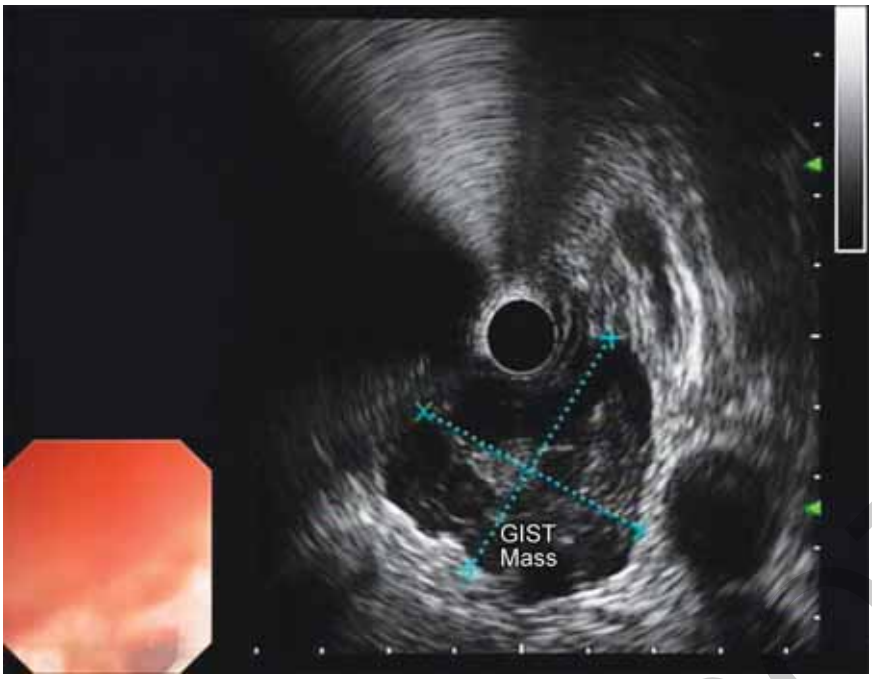

Fig. 10.2: Radial endoscopic ultrasound gastrointestinal stromal tumor (GIST) esophagogastric junction.

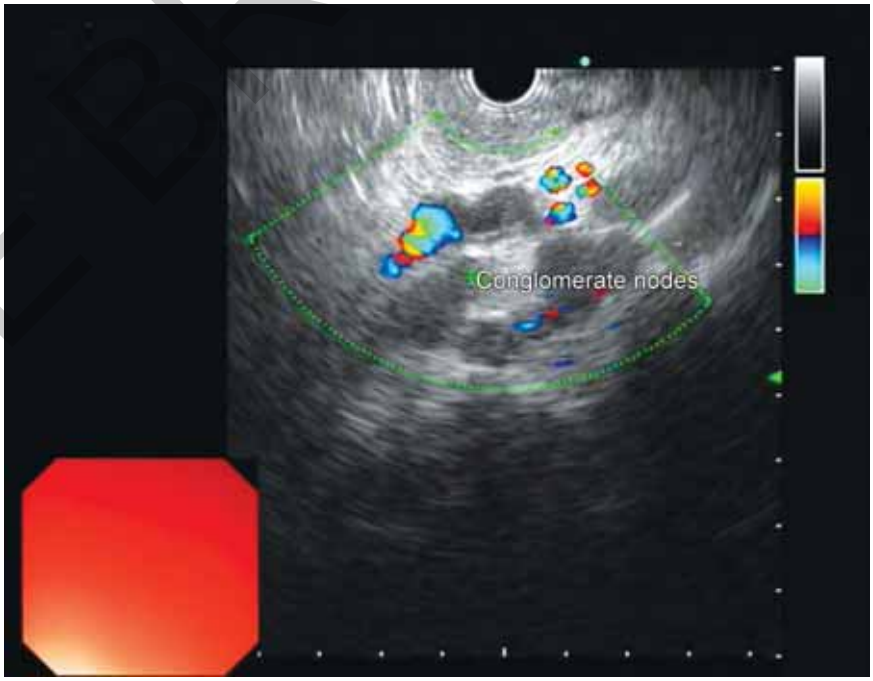

Fig. 10.3: Conglomerate lymph nodes seen in the celiac region proved to be tuberculosis.

Periampullary Tumors

Ampullary tumors are hypoechoic masses at the ampulla, which produce interface loss between different duodenal wall echogenic layers. The sphincter of Oddi may be difficult to visualize, but would appear as a thin hypoechoic layer surrounding the pancreaticobiliary duct. The accuracy in T staging for ampullary carcinomas was 72.7% for EUS and accuracy in N staging for ampullary carcinomas was 66.7%.

JAYPEE BROTHERS

Pancreas

Chronic pancreatitis: Rosemont criteria for diagnosing chronic pancreatitis (CP) were developed based on EUS imaging. Major criteria for CP were:

- Hyperechoic foci with shadowing and main pancreatic duct (PD) calculi
- Lobularity with honeycombing.

Minor criteria for CP were cysts, dilated ducts more than and equal to 3.5 mm, irregular PD contour, dilated side branches more than and equal to 1 mm, hyperechoic duct wall, strands, nonshadowing hyperechoic foci, and lobularity with noncontiguous lobules.

Recently, the image enhancement technique of elastography has been used to help improve the diagnostic capabilities of EUS for CP.

Pancreatic cysts: EUS-FNA has formed the cornerstone of the diagnosis of pancreatic cysts, with analysis of cyst fluid markers such as carcinoembryonic antigen (CEA) and amylase helping to discriminate mucinous from nonmucinous lesions, and to confirm communication with the PD (Fig. 10.4).[4]

Pancreatic masses: Endoscopic ultrasound has a high sensitivity and specificity for the detection of focal masses in the pancreas and has greater sensitivity and accuracy compared to CT, especially for smaller lesions less than 3 cm (Figs. 10.5 and 10.6).

Contrast-enhanced harmonic endoscopic ultrasound (CEH-EUS) may help localize a mass lesion within the pancreas that is suspected on cross-sectional imaging, but not initially visualized on EUS, can improve the staging of pancreatic cancers with respect to vascular involvement, and may help guide the target of biopsies within a particular lesion when performing FNA.[4]

Therapeutic uses in pancreatic lesions:

Celiac plexus block and neurolysis: EUS-guided celiac plexus block/celiac plexus neurolysis (CPB/CPN) is performed using a linear echoendoscope via a transgastric approach from the proximal stomach. EUS can be effectively performed as a safe day procedure. The principle involves combining endoscopic surgery.

Drainage of pancreatic fluid collections (PFCs): EUS and fluoroscopic imaging to facilitate the creation of a transgastric or transduodenal fistulous tract into the encapsulated PFC, through which stents (plastic pigtail or covered metal) are placed to maintain the patency of the cystogastrostomy or cystoduodenostomy tract to enable ongoing drainage.

Biliary Pathology

Gallstones: Microlithiasis (radiological invisibility stones less than 5 mm in diameter and/or stones less than 3 mm in diameter) in the GB may be undetected by

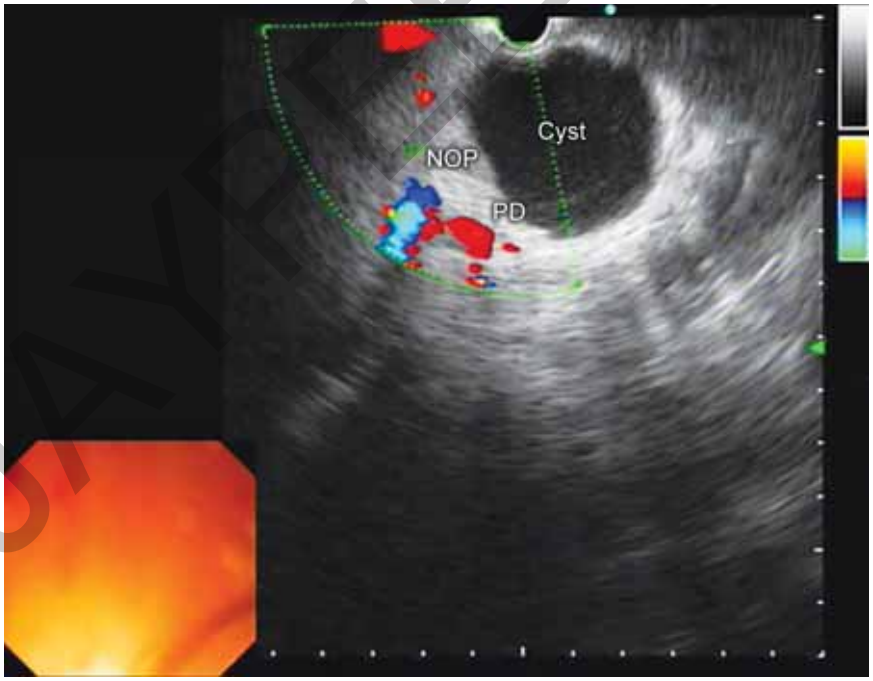

Fig. 10.4: Pancreatic cyst with pancreatic duct in the neck of the pancreas.

JAYPEE BROTHERS

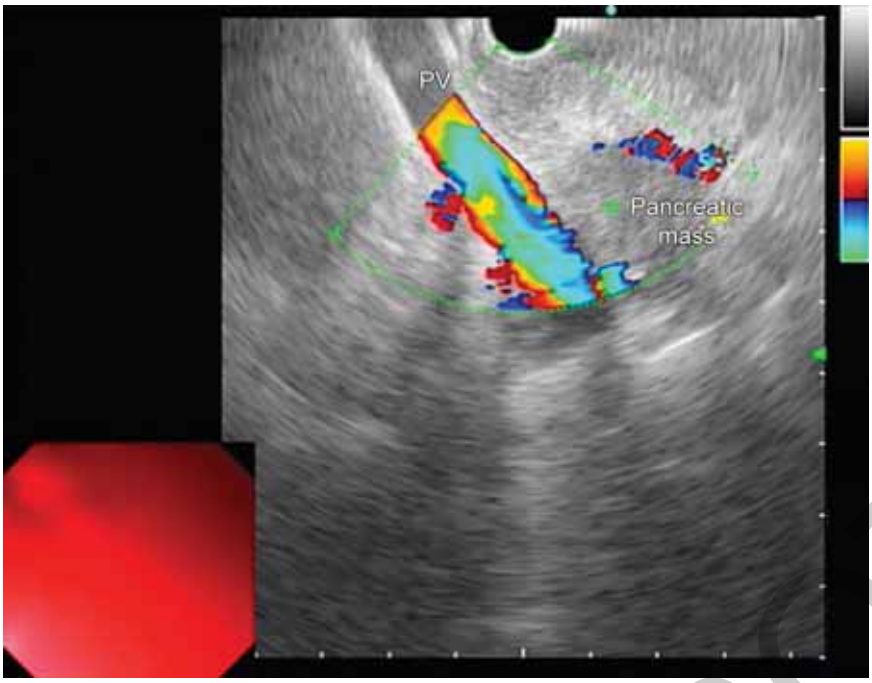

Fig. 10.5: Pancreatic mass with portal vein (PV) infiltration.

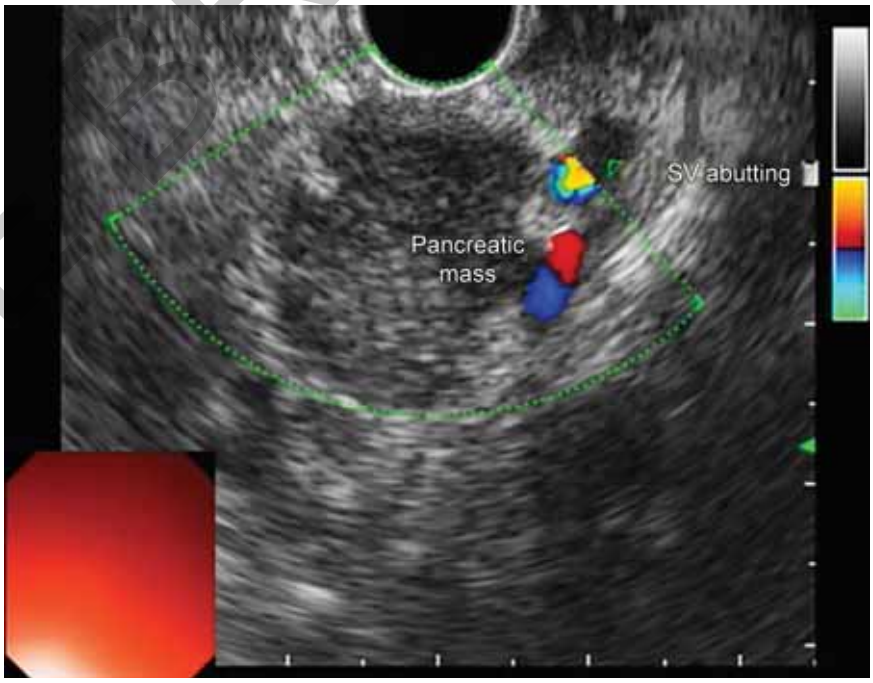

Fig. 10.6: Pancreatic body mass impinging on the splenoportal confluence.

transabdominal ultrasound and rarely detected on other imaging modalities including multidetector CT and MRI. In some patients with microlithiasis, biliary sludge and/or gallstones can be detected by EUS, with its high spatial resolution.

Endoscopic ultrasound should be considered as a minimally invasive highly accurate diagnostic tool for idiopathic pancreatitis after conventional radiography fails to detect any gallstones as there is high incidence of microlithiasis and/or biliary sludge.[5]

JAYPEE BROTHERS

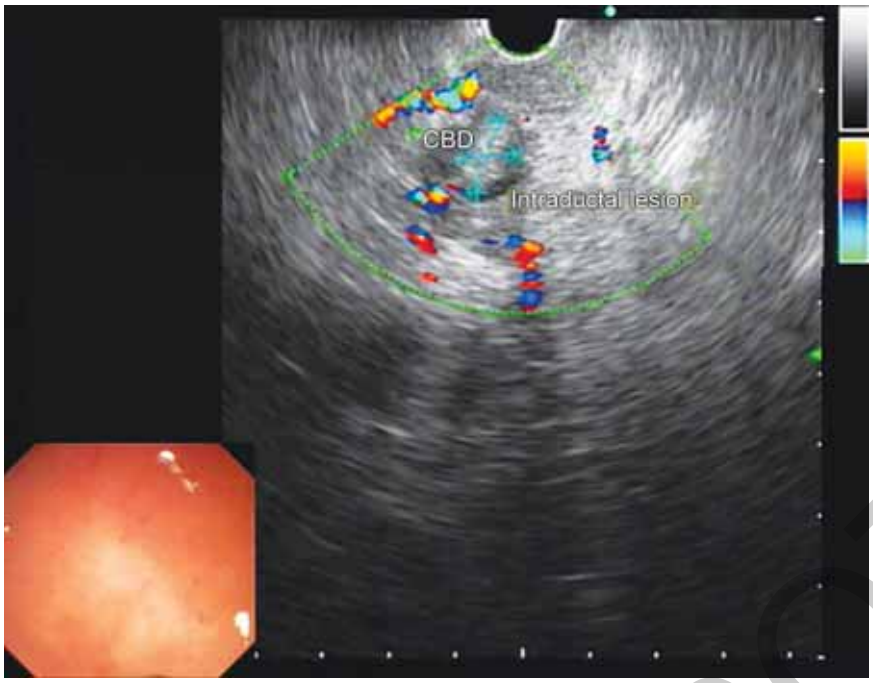

Fig. 10.7: Distal common bile duct (CBD) intraductal lesion suggestive of malignancy.

Nowadays, many gastroenterologists are preferring to use EUS to assess common bile duct (CBD) (Fig. 10.7) calculi in case of doubtful situations instead of magnetic resonance cholangiopancreatography (MRCP) as one can do endoscopic retrograde cholangiopancreatography (ERCP) in the same sitting if any CBD calculi are found on EUS.

Gallbladder polyp: EUS can differentiate the double layered structure of GB wall and provide higher resolution for imaging small polypoidal lesions.[6]

Gallbladder carcinoma: Diagnostic accuracy of EUS has been shown for T stage—Tis stage 100%, T1 stage 75.6%, T2 stage 85.3%, and T3–4 stage 92.7%. EUS also adds the possibility of FNA for tissue diagnosis of the primary as well as LNs, where diagnostic accuracy approaches 100%.

Postcholecystectomy syndrome: Cystic duct or GB remnant with or without stones is one of the important causes of postcholecystectomy syndrome. Diagnosis of residual GB with gallstones remains difficult. EUS is an excellent diagnostic modality in this situation.

Endoscopic ultrasound-guided gallbladder drainage: EUS-guided gallbladder drainage (EUS-GBD) is recently gaining alternative for management of acute cholecystitis in high-risk surgical patients. It is performed by using plastic stents, nasobiliary catheters, covered self-expandable metal stents, and, most recently, lumen-apposing metal stents (LAMSs).

Rectal lesions: The overall accuracy of T staging for rectal cancer varies between 70% and 90%. The overall accuracy of N staging by EUS is 73–83%.

In case of assessing the postneoadjuvant patients, we assess evidence for tumor regression from surrounding organs, not exactly for tumor, nodes, metastasis (TNM) staging, in particular the anal sphincters, vagina, and prostate. In this way EUS can direct therapy in patients who have undergone neoadjuvant therapy as a prelude to possible sphincter-sparing surgery.

LAPAROSCOPIC ULTRASOUND

Intraoperative laparoscopy was first reported by Schlegel et al. in 1961[7] and LUS by Fukuda et al. in 1981 in patients with liver tumors.[8] The use of LUS is gaining popularity and is set to become a valuable tool in the armamentarium of laparoscopic surgeons. LUS has increased accuracy of staging in hepatobiliary, pancreatic, and gastric neoplasms.

JAYPEE BROTHERS

Equipment

The addition of pictures allows the surgeon to operate by looking at a single monitor, instead of having to alternately view the laparoscopic and ultrasound monitors. Hand-eye coordination is significantly impaired if this function is not used. This can be done either with the help of video mixers or by the use of the recently available monitors that allow for two different inputs.

Laparoscopic ultrasound probes are sterilized in glutaraldehyde solutions before use. During sterilization, only the distal part of the equipment should be immersed in the solution. Care should be taken to avoid immersion of the connecting cable assembly as it can cause significant damage to the cables. Ethylene oxide sterilization can also be done. To minimize transducer sterilization time and increase its availability in several different operating rooms, some clinicians use especially designed waterproof gaskets and plug covers that cover the entire instrument (transducer, handle, and cord).

Technique

We use SSD-5000 Aloka ultrasound scan with laparoscopic color Doppler probe in our operation theater (Fig. 10.8). The imaging system is so accurate that even 2–3 mm lesions can be easily identified.



Fig. 10.8: Aloka Prosound SSD-5000.

The patients are placed in supine minimal Trendelenburg position to allow the upper abdominal organs to fall away from the field of vision. Routine evaluation of the abdomen is done after creation of pneumoperitoneum. Selection of the appropriate port is essential for laparoscopic assessment. During the initial phase, surgeons may find it easier to perform the scan through the umbilical port as it helps in easier orientation of cross-sectional anatomy (Fig. 10.9). The ultrasound probe can be used in various ports to improve visualization of different quadrants of the abdominal cavity.

For assessment of the biliary tree, the probe is placed over the CBD as proximally as possible and slowly withdrawn with minimal rotatory movements. The orientation of the probe is changed when it reaches the distal end and this part of the CBD is screened through the duodenum. The proximal bile duct, confluence, and hepatic ducts can be screened through the right lobe of the liver.

The assessment of liver lesions is done by placing the ultrasound probe opposed to the surface of the liver and moving the probe in a sweeping or lawn mowing fashion from medial to lateral side starting from the falciform ligament. The same process is repeated after withdrawing the probe for around 4 cm to scan the parenchyma in the lower portion. Flexible probes are more useful in assessing the liver close to the dome of the diaphragm (Fig. 10.10). The process is repeated till the entire right lobe is screened. The left lobe of the liver is assessed in a similar fashion. A thorough evaluation of the dome of the liver may require placement of the LUS transducer through a left paramedian port and the right upper quadrant port due to the physical boundaries determined by the falciform ligament. The hepatic veins and portal venous system are examined, followed by close inspection of the inferior vena cava. Newly discovered masses are aspirated or biopsied under guidance.

Ultrasound of pancreas involves the assessment of head, body, and tail. Air in the stomach can be aspirated and saline injected to enhance the acoustic interface and to avoid artifacts. The head of the pancreas can be assessed through the antrum and body of the stomach and tail of pancreas placing the probe directly over the pancreas after entering the lesser sac. The celiac axis, peripancreatic, periportal, and periaortic LNs are then evaluated. The use of a Doppler USG probe usually helps in identification of the vessels and their relation to the

JAYPEE BROTHERS

tumor. Colonic tumors are not ideal for assessment by LUS due to presence of gas in the colon.

The laparoscopic surgeon is often familiar with deflecting type instruments and will be comfortable maneuvering the laparoscopic probe to the desired location in the abdomen. It is always better that the surgeon takes an active role in LUS and learn the technique with the help of a radiologist. The presence of an experienced sonologist is helpful for recognition of anatomic landmarks, location and extent of the

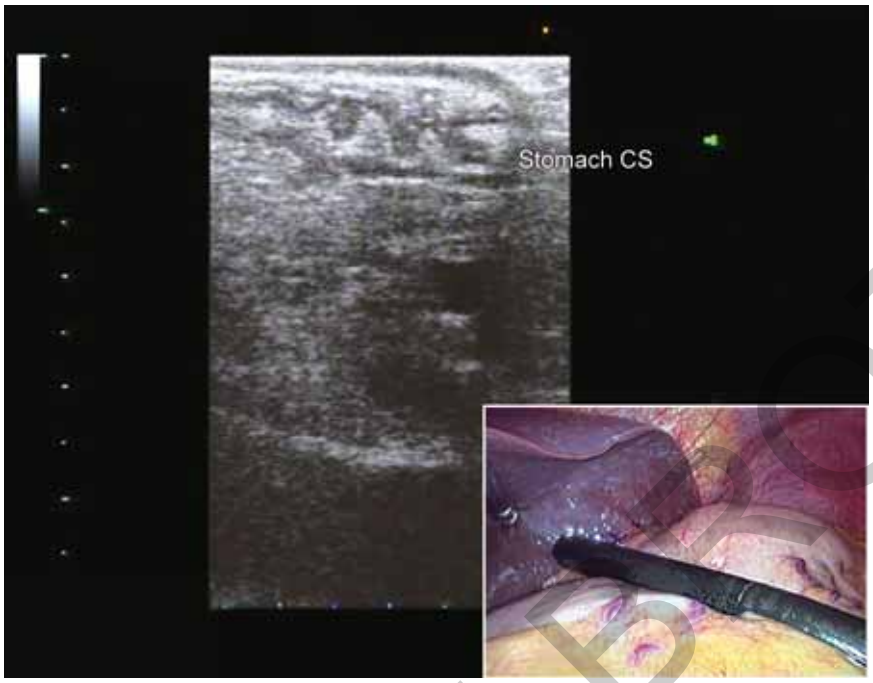

Fig. 10.9: Cross-sectional view of the stomach during laparoscopic ultrasound.



Fig. 10.10: Laparoscopic ultrasound probe—7.5 MHz with flexible tip.

JAYPEE BROTHERS

lesion, and other subtle abnormalities during the learning curve. The role of the surgeon in ultrasound imaging has been stressed in various forums and the American College of Surgeons and Society of American Gastrointestinal Endoscopic Surgeons (SAGES) have realized its importance; they recommend basic and LUS techniques to all their surgical trainees. Surgeons can start performing routine ultrasound examinations in common cases such as laparoscopic cholecystectomy; once they understand the basic principle of LUS they can identify various structures and artifacts. Once the technique has been mastered, the surgeon will be in a better position to assess the lesions during surgery based on surgical expertise and imaging techniques.[9]

Indications

Laparoscopic ultrasound is particularly useful in the assessment of parenchyma of solid organs (liver, spleen, kidney, or adrenal) and retroperitoneal structures. It is also used to assess the CBD during bile duct surgery and as a part of staging laparoscopy in patients with hepatobiliary and pancreatic cancers prior to laparotomy. Laparoscopy in combination with LUS has also demonstrated potential benefits in the preoperative staging of hepatobiliary, pancreatic, esophageal, and gastric neoplasms.

Liver

The resectability of primary and secondary liver tumors can be assessed by LUS. It helps in detection of additional liver lesions in patients with metastasis, which are not detected by routine preoperative investigations like CT and USG. Around 20% of patients who underwent LUS before radio frequency ablation had one or more lesions that were not picked up by the CT scan.[10] The addition of LUS to diagnostic laparoscopy resulted in the detection of new tumors in 33% of patients with liver tumors. In some series, there was a significant change in the management strategy as high as 38%[11] following laparoscopic ultrasonogram (Figs. 10.11 to 10.13).

Apart from detection of additional lesions, it also provides essential information during hepatic resections. It helps in localization of the tumor and assessment of vital structures close to the lesion, helping the surgeon to carry out a safe resection. At present, the sensitivity of LUS varies from 80% to 100% and the specificity varies from 75% to 100%. When compared to other preoperative imaging studies, LUS seems to increase sensitivity by 10–20% for assessment of liver tumors.[12]

Laparoscopic ultrasound can be used for various therapeutic purposes in liver conditions. It can be effectively used to drain abscesses, biopsy liver masses,

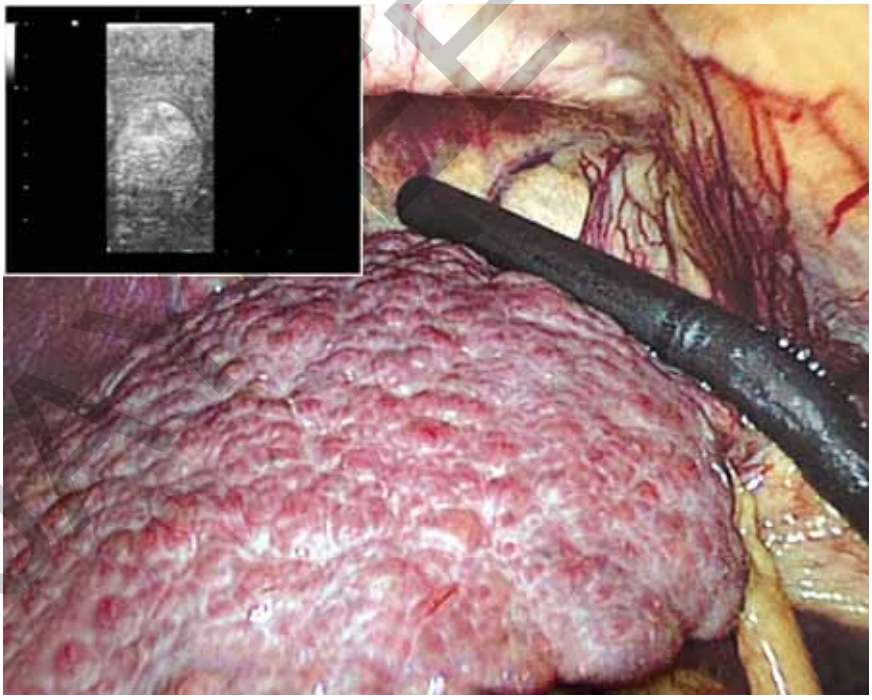

Fig. 10.11: Laparoscopic ultrasound shows hepatic mass in the 8th segment of liver.

JAYPEE BROTHERS

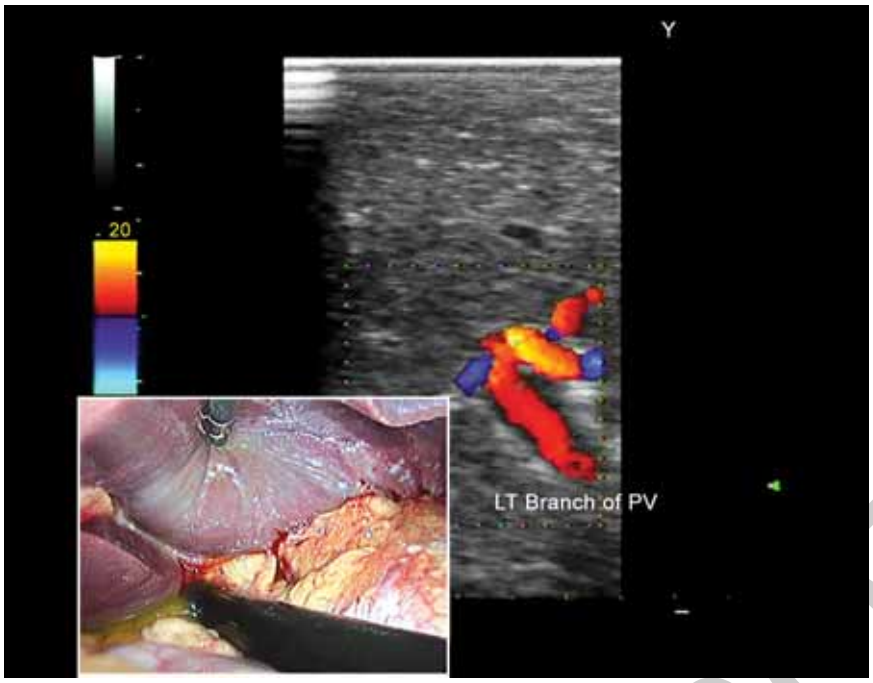

Fig. 10.12: Color Doppler study of hilum of liver.

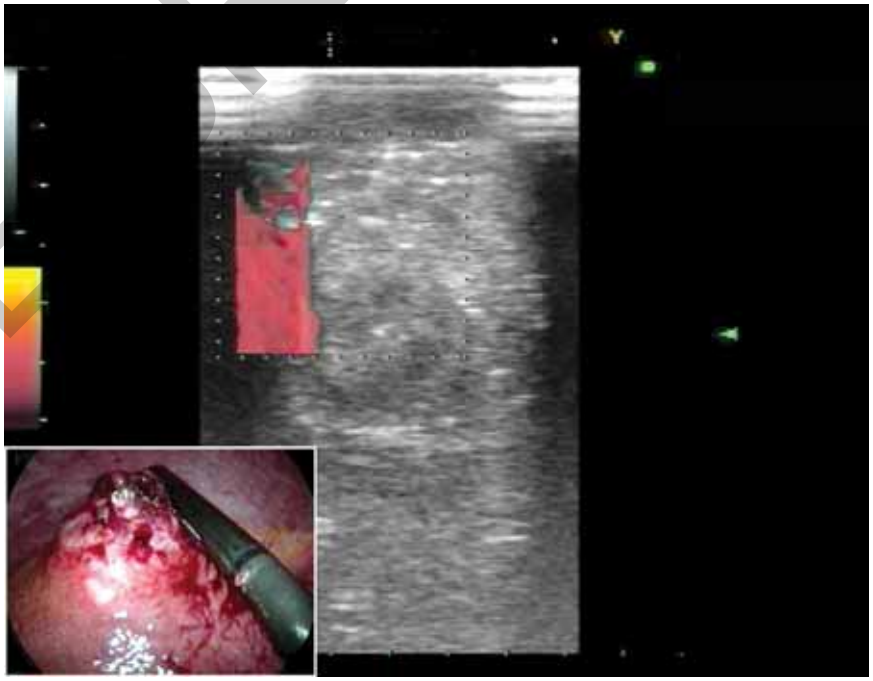

Fig. 10.13: Color Doppler assessment of hepatic tumor.

for interstitial tissue ablation for malignancy, and assist in deroofing of the liver parenchyma in case of liver cysts. Various interstitial tissue ablation methods are available for management of primary and secondary tumors of the liver. LUS helps in localization of these tumors, assessment of tumor margins, and in real time monitoring during ablation. In radiofrequency ablation, the hypoechoic area becomes hyperechoic after adequate ablation which is denoted by degassing or bubbling. The diameter of the ablated tissue measured by LUS

JAYPEE BROTHERS

should be 1 cm more than the diameter of the lesion to ensure complete ablation.

Gallbladder and Biliary Tree

It has been demonstrated that LUS is a more sensitive and specific investigative modality for detection of CBD stones when compared to intraoperative cholangiogram (IOC). LUS has a sensitivity of around 80–100% in detection of stones.[13-16] Time and cost studies also suggest that laparoscopic USG of the biliary tract may be less expensive than IOC. A cholangiogram takes approximately 10–15 minutes when compared to 4–9 minutes for laparoscopic USG.[17] The learning curve for assessment of bile duct stones is approximately around 20 cases and has been shown to be more cost-effective when compared to IOC.[9]

In cases of acute cholecystitis with extensive inflammatory phlegmon, the localization of cystic duct and its insertion into CBD is extremely difficult. IOC is often not possible due to cystic duct block and moreover the cystic duct is usually not delineated. Anatomic road mapping of the biliary system with LUS aids the surgeon in preventing bile duct injuries. Abnormally placed vessels in the hilum can also be visualized by color Doppler study (Figs. 10.14 and 10.15).

Pancreas

Assessment of pancreatic tumor by LUS has shown to decrease negative laparotomies. The signs of vascular infiltration like thrombosis of the vessels, luminal narrowing, loss of hyperechoic interface between vessel and tumor, and protrusion of tumor into the vessel clearly identifies patients with vascular infiltration. It can also be used to assess nodal status. Laparoscopy combined with LUS is more specific and accurate in predicting tumor resectability than laparoscopy alone (88–89% vs 50–60%).[18,19]

Endocrine tumors of the pancreas can be easily localized by LUS. The sensitivity of LUS in detecting pancreatic insulinomas is comparable to open intraoperative ultrasound.[20-22] It can also be used in benign conditions such as pseudocysts of the pancreas to define the center of the pseudocyst and the thinnest area of communication between stomach and cyst and for identification of dilated PD during pancreaticojejunostomy. Patients recovering from necrotizing pancreatitis may develop abscesses or infected necrosis and localization and determination of the best access route to the area of necrosis can be determined by LUS. It can also identify the location of the PD and guide the surgeon in avoiding injury to the duct, thus reducing the risk of pancreatic fistula (Figs. 10.16 and 10.17).

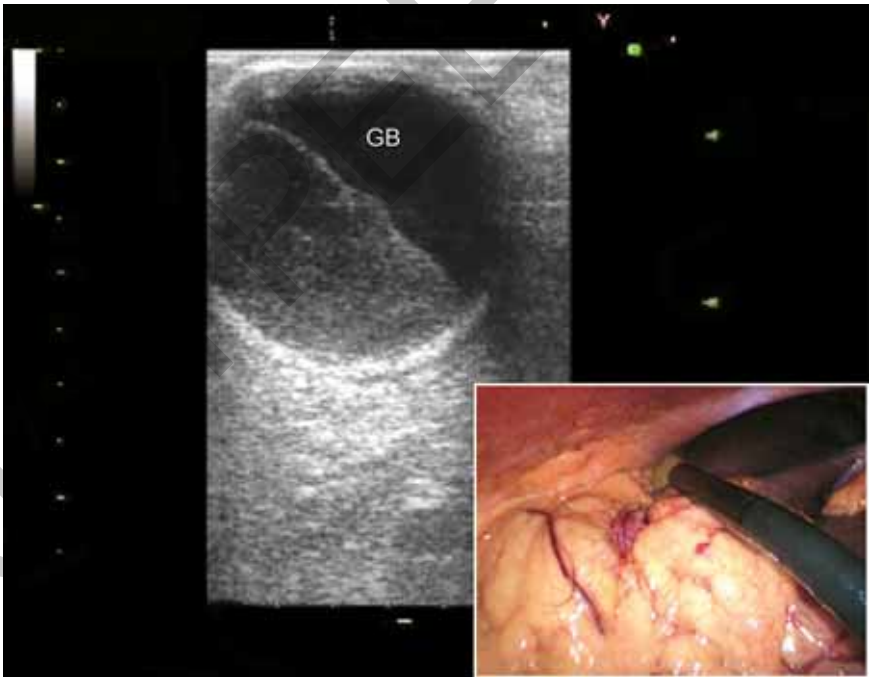

Fig. 10.14: Ultrasound study of inflammatory mass in the gallbladder (GB) area shows empyema of the gallbladder.

JAYPEE BROTHERS

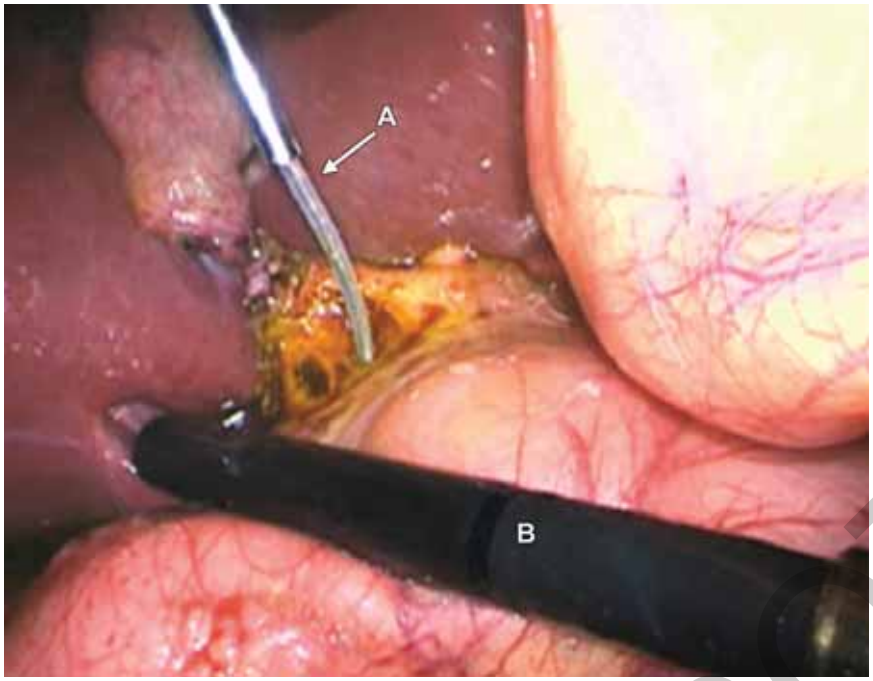

Fig. 10.15: Laparoscopic ultrasound for localization of common bile duct stone (A—basket; B—ultrasound probe).

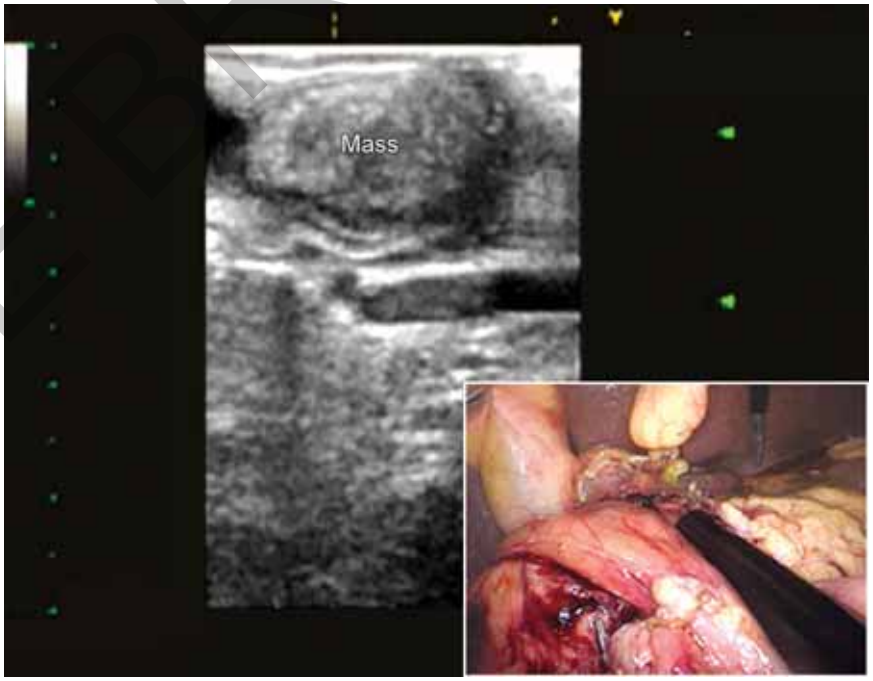

Fig. 10.16: Ultrasound study of the pancreas during Whipple's procedure showing periampullary growth.

Gastroesophageal Tumors

Inclusion of LUS in treatment protocols will lead to better identification of those patients that can be offered curative resections. The TNM staging of laparoscopy and LUS is superior to the staging provided by preoperative imaging including conventional USG, CT, and EUS. The resectability rates following LUS is also higher when compared to controls.[23,24]

JAYPEE BROTHERS

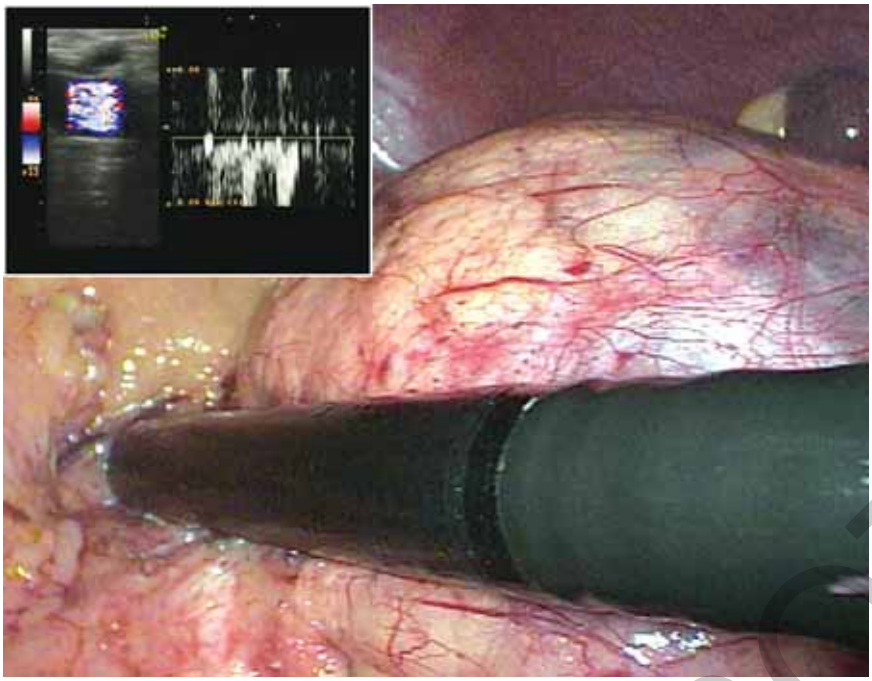

Fig. 10.17: Color Doppler study of localize the splenic vessels during laparoscopic pancreatic cystadenoma excision.

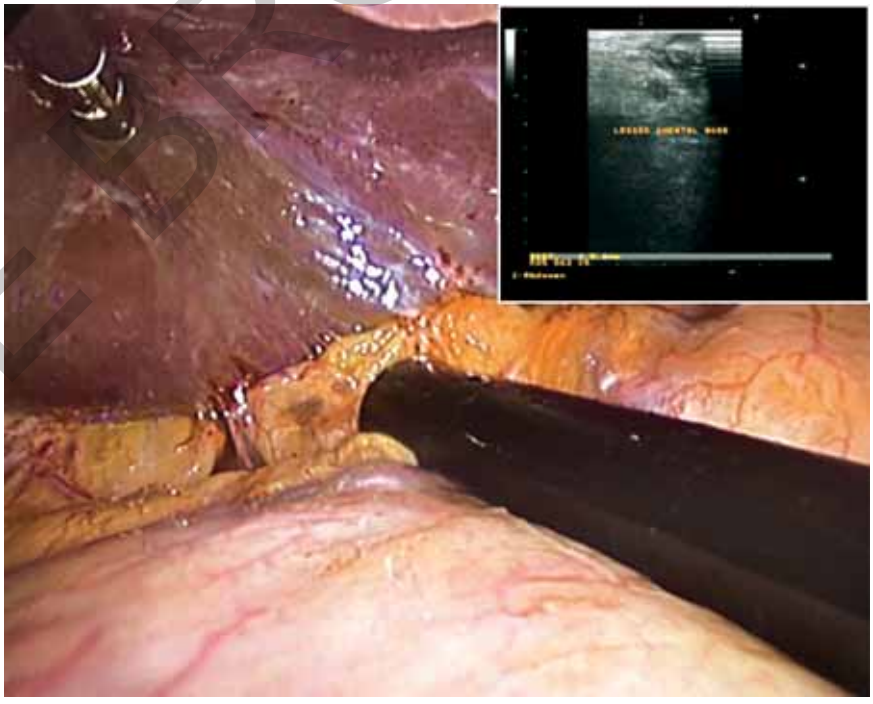

Fig. 10.18: Laparoscopic ultrasound study shows lesser omental node.

Others

Diagnosis and staging of lymphoproliferative disorders includes assessment of LNs, nodal and liver biopsies, and, in selected cases, splenectomy. LUS helps the surgeon in localization of the nodes and in obtaining biopsies (Fig. 10.18).[25]

Laparoscopic ultrasound may be helpful in locating the adrenal vein when a large amount of retroperitoneal fat covers the vein. It also helps in localization of the adrenal gland. LUS has also been used for localization of nodules in thoracoscopy and in various other therapeutic procedures like celiac

JAYPEE BROTHERS

ganglionectomy and chemical ablation of nerves in inoperable pancreatic tumors.[25]

Limitations

Laparoscopic ultrasound is not particularly useful for identification of colonic or small bowel tumors due to the presence of gas and feces. At present, biopsy of a lesion with the currently available probes is difficult except for the most experienced surgeons. Development of especially designed puncture probes will help in accurate biopsy of deep-seated lesions of the liver. Some authors have warned about the risk of tumor cell implantation at port sites, especially in patients with malignant ascites. But now, it has been proven that the incidence of port site metastasis is not greater than the incidence in open surgeries. The learning curve appears to be determined by the surgeon's ability to interpret the images and is highly operator dependent.

INDOCYANINE GREEN

Indocyanine green (ICG) is an anionic, water-soluble, relatively hydrophobic, tricarbocyanine molecule with a molecular mass of 776 Daltons. ICG dye was developed for near infra-red (NIR) photography by the Kodak research laboratories in 1955 and FDA approved for clinical use in 1959.

Following intravenous injection, ICG is rapidly bound to plasma proteins, especially lipoproteins, with minimal leakage into the interstitium. Depending on liver vascularization and function, ICG is rapidly extracted by the liver without modifications and nearly exclusively excreted by the liver appearing unconjugated in the bile about 8 minutes after injection.

When injected outside blood vessels, ICG binds to proteins and is found in the lymph, reaching the nearest draining lymph node usually within 15 minutes. After 1–2 hour, it binds to the regional lymph nodes, deposited into macrophages. The usual dose for standard clinical use is 0.1–0.5 mg/mL/kg.

ICG becomes fluorescent once excited either using a laser beam or by NIR light at about 820 nm and longer wave lengths, the absorption peak is around 807 nm, and the emission peak is around 822 nm. The fluorescence released by ICG can be detected using specifically designated scopes and camera.

Role in Laparoscopy

The imaging is generated by the high-end full high definition camera system connected to a laparoscope with 30° field of direction and 10 mm diameter equipped with a specific filter for optimal detection of the NIR fluorescence and white light without manual switching. The powerful xenon light source provides both visible and NIR excitation light. Switching from standard light to NIR is controlled by the surgeon by means of a pedal.

Fluorescence-guided Lymphadenectomy

Intraoperative sentinel node (SN) mapping guided by ICG fluorescence imaging. 0.5% ICG solution is injected into the submucosa endoscopically (1 to 3 days before the operation) or subserosa intraoperatively at four sites (0.5 mL each) around the tumor. Lymph nodes taking up ICG appeared as round spots emitting clear fluorescence and were defined as the fluorescent nodes (FNs) (Figs. 10.19A and B). The FNs were dissected out carefully from the surrounding fatty tissue. The lymph nodes in the dissected specimens were isolated from the surrounding tissues on the back table, and examined to determine if they also exhibited internal fluorescence. All the fluorescent lymph nodes were regarded as representing the FNs. After the operation, it was ensured, if possible, that no fluorescent spots remained in the resected specimens.

Tajima et al. in their study SN mapping guided by indocyanine green fluorescence imaging in gastric cancer concluded that ICG fluorescence imaging–guided SN mapping could be useful in predicting the metastatic status in the lymph nodes in gastric cancer.[26] Dissection of LBs containing FNs with laparoscopic surgery may be a promising approach as a new type of minimally invasive surgery for patients with cT1- or cT2- stage gastric cancer having no metastasis in the FNs.

Fluorescence-guided Laparoscopic Cholecystectomy

As ICG, once injected, concentrates in bile, it is possible to outline the biliary tree anatomy, especially in Calot's triangle, by visualization under NIR light, during laparoscopic cholecystectomy, in both elective and acute settings.

JAYPEE BROTHERS

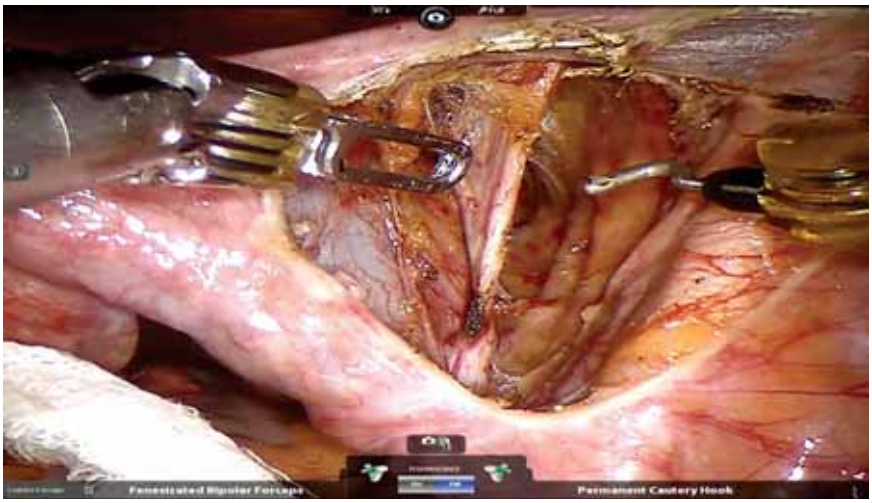

Fig. 10.19A: Robotic Wertheim's hysterectomy. View after lymphadenectomy.

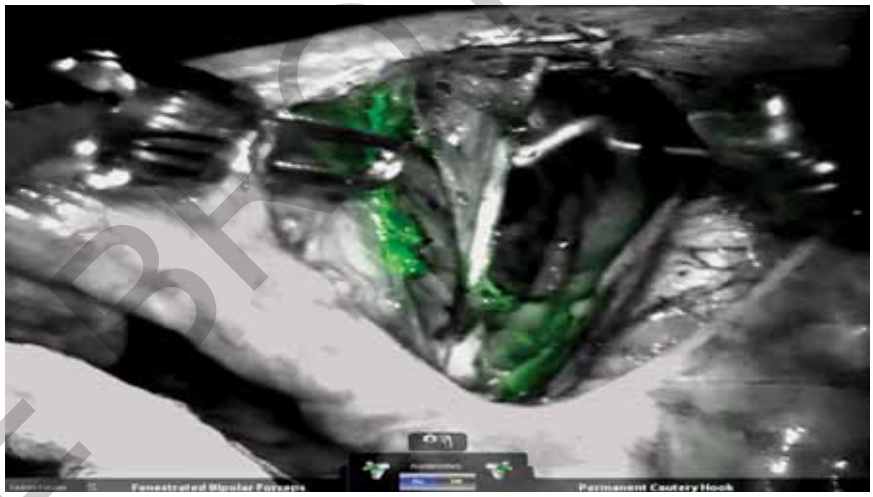

Fig. 10.19B: ICG camers shows fluorescent nodes along the vessels.

The ICG dye was injected intravenously at least 15 minutes before surgery to allow ICG to concentrate in the bile. If the vascular anatomy of the cystic artery required clarification, a small bolus of 2–3 mL of 0.4 mg/mL/kg was injected. Fluorescence appeared at the level of the Calot's triangle defining the cystic artery after 60 seconds.

Fluorescence-guided Laparoscopic Hepatectomy

Boundaries of hepatic segments prior to anatomic resection can be identified by fluorescence imaging (Figs. 10.20A and B). Using a standard vial of 25 mg, diluted with water solution, ICG is usually given at the standard dose of 2.5 mg (1 mL) intravenously few seconds before viewing the ducts. Alternatively, 2.5 up to 12.5 mg can be injected intravenous (IV) 30–90 minutes before and during surgery.

Mizuno et al. reported a single experience regarding the use of ICG-NIR-FC for donor hepatectomy in LDLT.[27] It was found useful to identify the exactly cutting line of the bile duct, which was appropriate for both donor and recipient under guidance of this imaging.

Fluorescence-guided Laparoscopic Colorectal Resection

ICG-enhanced fluorescence was used during laparoscopic colorectal resection in order to verify the adequate perfusion of the large bowel prior to anastomosis.

JAYPEE BROTHERS

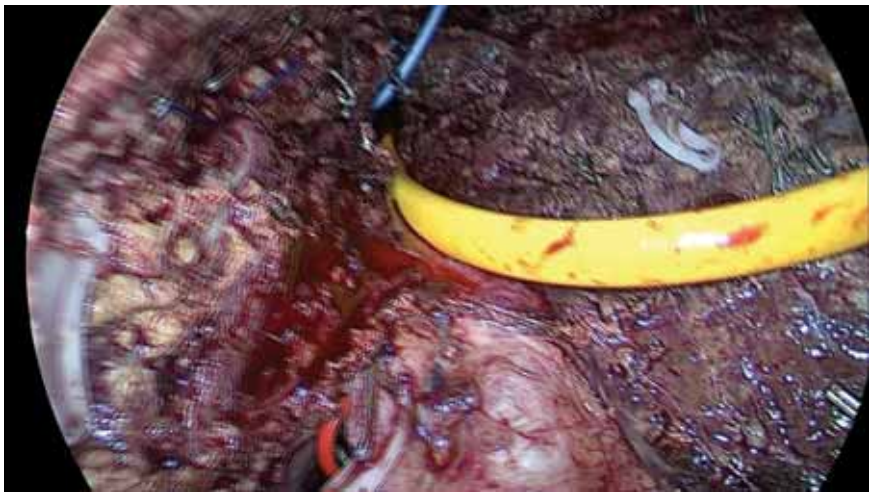

Fig. 10.20A: Laparoscopic right hepatectomy.

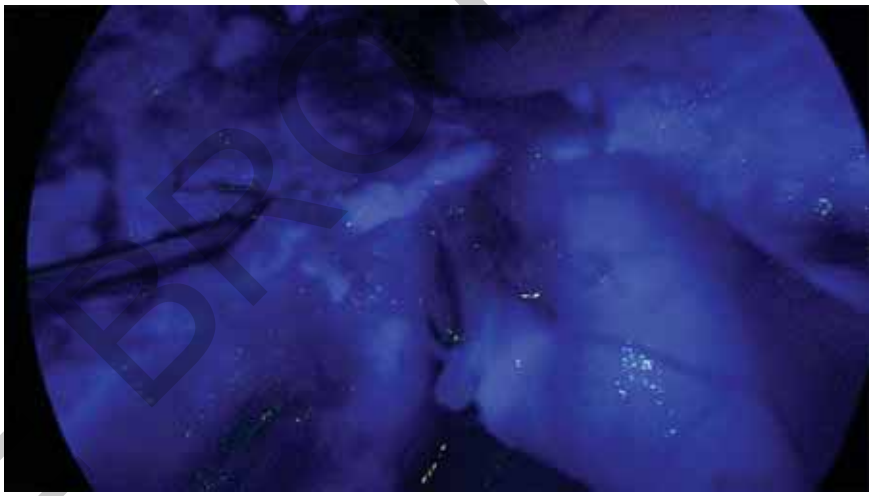

Fig. 10.20B: ICG camera view of right hepatectomy.

Once injected into a peripheral or central vein, ICG became fluorescent under NIR light, providing a "real-time" confirmation of the bowel perfusion. Thus, this helps to define the point of resection after mesenteric division as well as demonstrates the presence of an ischemic or "non-optimal" perfusion before performing the anastomosis.

Use of ICG was associated with improved knowledge of perfusion and subsequently revision of anastomotic sites, it also helped to reduce postoperative interventions for anastomotic leaks.[28,29]

CONCLUSION

Laparoscopic ultrasound is a promising investigative tool in the surgical armamentarium of the laparoscopic surgeon who wishes to take laparoscopic surgery to newer frontiers. With newly available technology such as three-dimensional (3D) ultrasound and growing interest among surgeons to learn the technique, LUS will enhance our ability to stage malignancies and assess resectability in a better way. It will also serve as a cost-effective and simple tool for various therapeutic options like radio-frequency ablation.

REFERENCES

1. Gress FG. The early history of interventional endoscopic ultrasound. Gastrointest Endosc Clin N Am. 2017;27(4):547-50.
2. Liu J, Carpenter S, Chuttani R, et al. Endoscopic ultrasound probes. Gastrointest Endosc. 2006;63(6): 751-4.

JAYPEE BROTHERS

3. Saadany SE, Mayah W, Kalla FE, et al. Endoscopic ultrasound staging of upper gastrointestinal malignancies. Asian Pac J Cancer Prev. 2016;17(5):2361-7.
4. Teshima CW. Endoscopic ultrasound in the diagnosis and treatment of pancreatic disease. World J Gastroenterol. 2014;20(29):9976.
5. Alizadeh AHM. Endoscopic Ultrasonography (EUS) and Gallbladder. In: Abdeldayem HM (Ed). Updates in Gallbladder Diseases. InTech; 2017. pp. 97-109.
6. Robinson O'Neill DE, Saunders MD. Endoscopic Ultrasonography in Diseases of the Gallbladder. Gastroenterol Clin N Am. 2010;39(2):289-305.
7. Fukuda M, Mima F, Nakano Y. Studies in echolaparoscopy. Scan J Gastroenterol. 1982;(Suppl 78):186.
8. Soper NJ. Laparoscopic ultrasound for gastrointestinal surgeon. J Gastrointest Surg. 2001;5(2):219-20.
9. Foroutani A, Garland AM, Berber E, et al. Laparoscopic ultrasound vs triphasic computed tomography for detecting liver tumors. Arch Surg. 2000;135(8):933-8.
10. Machi J, Sigel B. Operative ultrasound in general surgery. Am J Surg. 1996;172(1):15-20.
11. Senagonre AJ, Marcello PW. Laparoscopic Ultrasound in Minimally Invasive Procedures in the Abdomen and Pelvis. In: MacFadyen BV (Ed). Laparoscopic Surgery of the Abdomen. New York: Springer-Verlag; 2004. pp. 446-50.
12. Greig JD, John TG, Mahadaven M, et al. Laparoscopic ultrasonography in the evaluation of the biliary tree during laparoscopic cholecystectomy. Br J Surg. 1994; 81(8):1202-6.
13. Rothlin MA, Schlumpf R, Largiader F. Laparoscopic sonography: an alternative to routine intraoperative cholongiography? Arch Surg. 1994;129:694-700.
14. Barteau JA, Castro D, Arregui ME, et al. A comparison of intraoperative ultrasound versus cholangiography in the evaluation of the common bile duct during laparoscopic cholecystectomy. Surg Endosc. 1995;9(5):490-6.
15. John TG, Banting SW, Pye S, et al. Preliminary experience with intracorporeal laparoscopic ultrasonography using a sector scanning probe. A prospective comparison with intraoperative cholangiography in the detection of choledocholithiasis. Surg Endosc. 1994;8(10):1176-80.
16. Wade TP, Comitalo JB, Andrus CH, et al. Laparoscopic cancer surgery. Lessons from gallbladder cancer. Surg Endosc. 1994;8(6):698-701.
17. John TG, Greig JD, Carter DC, et al. Carcinoma of the pancreatic head and periampullary region. Tumor staging with laparoscopy and laparoscopic ultrasonography. Ann Surg. 1995;221(2):156-64.
18. Van Delden OM, Smits NJ, Bemelman WA, et al. Comparison of laparoscopic and transabdominal ultrasonography in staging of cancer of the pancreatic head region. J Ultrasound Med. 1996;15(3):207-12.
19. Angelini L, Bezzi M, Tucci G, et al. The ultrasonic detection of insulinomas during surgical exploration of the pancreas. World J Surg. 1987;11(5):642-7.
20. Jaroszewski DE, Schlinkert RT, Thompson GB, et al. Laparoscopic localization and resection of insulinomas. Arch Surg. 2004;139(3):270-4.
21. Lihara M, Kanbe M, Okamoto T, et al. Laparoscopic ultrasonography for resection of insulinomas. Surgery. 2001;130(6):1086-91.
22. Berends FJ, Cuesta MA, Kazemier G, et al. Laparoscopic detection and resection of insulinomas. Surgery. 2000;128(3):386-91.
23. Anderson DN, Campbell S, Park KG. Accuracy of laparoscopic ultrasonography in the staging of upper gastrointestinal malignancy. Br J Surg. 1996;83(10): 1424-8.
24. Finch MD, John TG, Garden OJ, et al. Laparoscopic ultrasonography for staging gastroesophageal cancer. Surgery. 1997;121(1):10-7.
25. Bezzi M, Silecchia G, De Leo A, et al. Laparoscopic and intraoperative ultrasound. Eur J Radiol. 1998;27(Suppl 2): S207-14.
26. Tajima Y, Yamazaki K, Masuda Y, et al. Sentinel node mapping guided by indocyanine green fluorescence imaging in gastric cancer. Ann Surg 2009;249:58-62.
27. Mizuno S, Isaji S. Indocyanine green (ICG) fluorescence imaging-guided cholangiography for donor hepatectomy in living donor liver transplantation. Am J Transplant 2010. pp. 2725-6.
28. Jafari MD, Lee KH, Halabi WJ, et al. The use of indocyanine green fluorescence to assess anastomotic perfusion during robotic-assisted laparoscopic rectal surgery. Surg Endosc. 2013;27:3003-8.
29. Kudszus S, Roesel C, Schachtrupp A, et al. Intraoperative laser fluorescence angiography in colorectal surgery: a noninvasive analysis to reduce the rate of anastomotic leakage. Langenbeck's Arch Surg. 2010;395:1025-30.

JAYPEE BROTHERS

for detailed information on surgery books, visit our website www.jaypeebrothers.com, for detailed information on surgery books, visit our website www.jaypeebroth

ART OF LAPAROSCOPIC SURGERY

Textbook & Atlas

Volume 4
HEPATO-PANCREATO-BILIARY SURGERY

The *Art of Laparoscopic Surgery : Textbook and Atlas* by C Palanivelu is the second edition of the book that discusses updated information pertaining to various minimal access surgeries. This edition of the book is divided into four distinct volumes as basic laparoscopic surgery, esophagogastric surgery, colorectal surgery and hepato-pancreato-biliary surgery. Each chapter in the book includes detailed operative description and images in the form of atlas. The book illustrates advanced laparoscopic techniques and step-by-step information of operative procedures. The book will assist in understanding current concepts of laparoscopic surgery and the technical details.

Available at all medical bookstores
or buy online at www.jaypeebrothers.com



JAYPEE BROTHERS
Medical Publishers (P) Ltd.
www.jaypeebrothers.com

Join us on facebook.com/JaypeeMedicalPublishers

Shelving Recommendation
SURGERY

