sit our website www.jaypeebrothers.com, for detailed information on otolaryngology books, visit our website www.jaypeebrothers.com

Celebrating 50 Passion, Quality and Innovation in Healthcare Publishing

Basic Concepts in Head & Neck Surgery and Oncology





Editors
Krishnakumar Thankappan
Subramania Iyer

Forewords
Alok Thakkar
Moni Abraham Kuriakose

2nd Edition

JAYPEE

Basic Concepts in
HEAD AND NECK SURGERY AND ONCOLOGY

SECOND EDITION

Editors

Krishnakumar Thankappan MS DNB MCh
Professor
Department of Head and Neck Surgery and Oncology
Amrita Institute of Medical Sciences
Kochi, Kerala, India

Subramania Iyer MS MCh FRCS
Professor and Head
Department of Head and Neck Surgery and Oncology
Amrita Institute of Medical Sciences
Kochi, Kerala, India

Forewords

Alok Thakar

Moni Abraham Kuriakose

JAYPEE BROTHERS

JAYPEE BROTHERS MEDICAL PUBLISHERS
The Health Sciences Publisher
New Delhi | London | Panama

CONTENTS

SECTION 1: THYROID

Chapter 1. Pathology of Thyroid Tumors 3
Smitha NV

- Classification *3*
- Fine Needle Aspiration Cytology (FNAC) *4*
- Papillary Carcinoma *5*
- Follicular Carcinoma *8*
- Poorly Differentiated Carcinoma *9*
- Anaplastic (Undifferentiated) Carcinoma *9*
- Medullary Carcinoma *10*
- Molecular Genetics *11*
- Ancillary Testing *13*

Chapter 2. Guidelines in the Management of Differentiated Thyroid Cancer 14
Shreya Bhattacharya, Krishnakumar Thankappan

- Diagnostic Evaluation *14*
- Treatment *15*
- Risk Stratification *20*
- Role of Radioiodine after Thyroidectomy *20*
- Distant Metastasis *21*
- External Beam Radiotherapy (EBRT) *21*
- Follow-up *21*
- Recurrent DTC *21*

Chapter 3. Guidelines in the Management of Medullary and Anaplastic Thyroid Cancer 23
Shreya Bhattacharya, Krishnakumar Thankappan

- **Medullary Thyroid Cancers** *23*
- Diagnostic Evaluation *23*
- TNM Staging *24*
- Treatment *24*
- Prognosis *26*
- Anaplastic Carcinoma *26*
- Staging *26*
- Management *26*

JAYPEE BROTHERS

Chapter 4. Principles of Thyroid Surgery 28
Shreya Bhattacharya, Krishnakumar Thankappan
- Surgical Anatomy *28*
- Surgical Technique *29*
- Complications of Thyroidectomy *30*

Chapter 5. Role of Nuclear Medicine in Adjuvant Therapy and Follow-up of Differentiated Thyroid Cancer 32
P Shanmuga Sundaram
- Selection of Patients for Radioiodine ^{131}I Ablation *33*
- Side Effects of ^{131}I High-dose Therapy *36*
- Long-term Effects of ^{131}I *37*

Chapter 6. Medical Management of Differentiated Thyroid Cancer 39
Vasantha Nair, Krishnakumar Thankappan
- General Principles *39*
- Follow-up after Initial Therapy *39*
- T4 Suppression Therapy *40*
- Role of T3 *41*
- Chemotherapy *41*
- Addressing Comorbidities *41*

Chapter 7. Parathyroid Tumors: Evaluation and Management 44
Shibu George
- Anatomy *44*
- Primary Hyperparathyroidism and Parathyroid Adenoma *44*
- Asymptomatic Primary Hyperparathyroidism *45*
- Parathyroid Carcinoma *47*
- Secondary Parathyroid Malignancy *48*

SECTION 2: SALIVARY GLANDS AND PARAPHARYNGEAL TUMORS

Chapter 8. Pathology of Salivary Gland Tumors 55
Chaya Prasad, Smitha NV
- WHO Classification *55*
- Malignant Tumors *55*
- Benign Tumors *65*

JAYPEE BROTHERS

Chapter 9. Imaging of Salivary Gland Tumors 67
Sandya CJ, Akshay Kudpaje, Sivakumar Vidhyadharan, Rajsekar CS
- Normal Anatomy *67*
- Neoplasms of Salivary Glands *68*
- Malignant Neoplasms of Parotid Gland *70*

Chapter 10. Guidelines in the Management of Salivary Gland Malignancies 72
Mahamaya Prasad Singh, Krishnakumar Thankappan, Subramania Iyer
- Epidemiology *72*
- Clinical Presentation *72*
- Imaging *72*
- Biopsy *74*
- Treatment *74*
- Prognosis *76*

Chapter 11. Principles of Salivary Gland Tumor Surgery 77
Mahamaya Prasad Singh, Krishnakumar Thankappan, Subramania Iyer
- Surgical Anatomy *77*
- Parotidectomy: Surgical Technique *78*
- Submandibular Gland *80*
- Surgical Technique *80*

Chapter 12. Imaging in Parapharyngeal Tumors 81
Sandya CJ, Akshay Kudpaje
- Anatomy *81*
- Imaging Assessment *81*
- Pathology *82*

Chapter 13. Parapharyngeal Space Tumors 89
Mahamaya Prasad Singh, Krishnakumar Thankappan
- Anatomy *89*
- Boundaries *89*
- Tumors of the Parapharyngeal Space *89*
- Clinical Presentation *90*
- Treatment *91*
- Approaches to the Parapharyngeal Space *91*

JAYPEE BROTHERS

Chapter 14. Tumors of Infratemporal Fossa: Approaches and Management 94
Divya GM
- Surgical Anatomy *94*
- Classification of Tumors of Infratemporal Fossa *94*
- Diagnosis *96*
- Patient Selection *97*
- Approaches to Infratemporal Fossa *97*

Chapter 15. Malignant Tumors of the Temporal Bone 101
Deepak Balasubramanian
- Etiology *101*
- Spectrum of Malignancies in the Temporal Bone *101*
- Pathways of Tumor Spread in the Temporal Bone *101*
- Clinical Presentation *102*
- Clinical Evaluation *102*
- Staging *102*
- Treatment *103*
- Prognosis *103*

Chapter 16. Facial Nerve 105
Salima Rema Windsor
- Anatomy *105*
- Surgical Landmarks for Facial Nerve *107*
- Pathophysiology *108*
- Etiology of Facial Nerve Paralysis *109*
- Management of Facial Nerve Paralysis *110*
- Treatment of Facial Paralysis *111*
- Facial Reanimation *111*

SECTION 3: NECK

Chapter 17. Neck Nodal Levels and Classification of Neck Dissection 117
Shashikant Vishnubhai Limbachiya, Deepak Balasubramanian
- Anatomy of the Fascial Spaces of the Neck *117*
- Neck Lymphatics *117*
- Classification of Neck Nodal Levels *117*
- Terminology of Neck Dissection *121*
- Staging of the Neck *122*

JAYPEE BROTHERS

Chapter 18. Management of the Node Negative Neck 124
Shashikant Vishnubhai Limbachiya, Deepak Balasubramanian
- Treatment Options *124*

Chapter 19. Management of the Node Positive Neck 127
Shashikant Vishnubhai Limbachiya, Deepak Balasubramanian
- Treatment for N+ Neck *127*
- Radical Neck Dissection *127*
- Modified Radical Neck Dissection *131*
- Complications of Neck Dissection *132*

Chapter 20. Nodal Metastasis from an Unknown Primary Origin 134
Krishnakumar Thankappan
- Theories of Occurrence *134*
- Evaluation *134*
- AJCC 8th Edition: Changes in Relation to Cervical Metastasis with Unknown Primary *135*
- Treatment *137*

SECTION 4: PARANASAL SINUSES

Chapter 21. Pathology of Tumors of the Nose and Paranasal Sinuses 143
Chaya Prasad
- WHO Histological Classification *143*

Chapter 22. Imaging of the Paranasal Sinus Tumors 151
Sandya CJ, Akshay Kudpaje, Sivakumar Vidhyadharan, Chinmay Kulkarni
- Sinonasal Neoplasms *151*
- Imaging Modalities *151*
- Lymphatic Spread *151*
- Perineural Spread *152*
- Orbital Involvement *153*
- Brain and Dural Involvement *153*
- Soft Tissue Involvement *154*

Chapter 23. Guidelines in the Management of Malignancies in Maxillo-ethmoid Complex 156
Adharsh Anand, Deepak Balasubramanian
- Patterns of Spread *156*
- Presenting Signs and Symptoms *157*

JAYPEE BROTHERS

- Ohngren's Classification *157*
- TNM Staging, AJCC 8th Edition *157*
- Evaluation *157*
- Treatment Guidelines *158*
- Management of Neck *161*
- Management of the Orbit *161*
- Reconstruction and Rehabilitation *161*
- Outcome *162*

Chapter 24. Principles of Surgery in the Management of Tumors of Maxillo-ethmoid Complex 163
Adharsh Anand, Deepak Balasubramanian
- Surgical Anatomy *163*
- Surgical Treatment *163*

SECTION 5: ORAL CAVITY AND OROPHARYNX

Chapter 25. Imaging in Oral and Oropharyngeal Tumors 171
Sandya CJ, Akshay Kudpaje, Shreya Bhattacharya
- Oral Cavity *171*
- Retromolar Trigone *172*
- Lymphatic Evaluation *179*
- Metastases *179*

Chapter 26. Guidelines in the Management of Oral Cavity Cancers 181
Sivakumar Vidhyadharan, Anoop R, Krishnakumar Thankappan
- Epidemiology *181*
- Clinical Presentation *181*
- Treatment: General Principles *185*

Chapter 27. Guidelines in the Management of Oropharyngeal Cancers..... 190
Prameela CG
- Epidemiology *190*
- Etiology *190*
- Anatomy *191*
- Subsites of Oropharynx *191*
- Pathology *191*
- Clinical Features *191*
- Distant Metastasis *192*

JAYPEE BROTHERS

- Evaluation *192*
- Management *193*
- Subsite-wise Treatment Approaches *196*
- Transoral Surgical Approaches *200*
- Adjuvant Treatment *200*
- Definitive Radiotherapy *201*
- Altered Fractionation Schedules *202*
- Treatment Sequelae *204*

Chapter 28. Principles of Surgery in Oral Cavity Cancers 205
Sivakumar Vidhyadharan, Subramania Iyer, Krishnakumar Thankappan

- Surgical Anatomy *205*
- Retromolar Trigone *207*
- Surgical Management and Techniques *207*
- Management of the Mandible *212*
- Assessment of Bony Invasion *213*
- Mandibulectomy *214*

SECTION 6: LARYNX, HYPOPHARYNX AND NASOPHARYNX

Chapter 29. Imaging in Laryngeal and Hypopharyngeal Tumors..... 221
Sandya CJ, Akshay Kudpaje

- Anatomy of Larynx *221*
- Imaging Techniques *222*
- Supraglottic Cancers *223*
- TNM Staging *226*

Chapter 30. Guidelines in the Management of Laryngeal Cancers 231
Akshay Kudpaje, Krishnakumar Thankappan

- Anatomy *231*
- Clinical Features *232*
- Treatment *233*

Chapter 31. Guidelines in the Management of Hypopharyngeal Cancers..... 239
Akshay Kudpaje, Krishnakumar Thankappan

- Anatomy *239*
- Clinical Features *240*
- Treatment *242*

JAYPEE BROTHERS

Chapter 32. Principles of Surgery in Larynx and Hypopharynx Cancers 247
Akshay Kudpaje, Krishnakumar Thankappan, Subramania Iyer

- Transoral Laser Microsurgery *247*
- Vertical Partial Laryngectomy *249*
- Supraglottic Laryngectomy *250*
- Supracricoid Partial Laryngectomy with Cricohyoidoepiglottopexy (SCPL-CHEP) *250*
- Supracricoid Partial Laryngectomy with Cricohyoidopexy (SCPL-CHP) *251*
- Near Total Laryngectomy *252*
- Total Laryngectomy *253*
- Alaryngeal Speech *253*

Chapter 33. Tracheostomy and Airway Management 255
Salima Rema Windsor

- Tracheostomy *255*
- Pediatric Tracheostomy *258*
- Types of Tracheostomy Tubes *260*
- Percutaneous Dilatational Tracheostomy *260*

Chapter 34. Guidelines in the Management of Carcinoma of the Nasopharynx 263
Pushpaja KU

- Anatomy *263*
- Lymphatic Drainage *263*
- Epidemiology *263*
- Etiology *264*
- Pathology *264*
- Routes of Spread *264*
- Clinical Presentation *265*
- Diagnosis *266*
- General Treatment Principles *268*

SECTION 7: GENERAL TOPICS

Chapter 35. Melanoma and Nonmelanoma Skin Cancers 273
Divya GM

- Melanoma *273*
- Nonmelanoma Skin Cancers *279*
- Basal Cell Carcinoma *281*
- Squamous Cell Carcinoma *283*

JAYPEE BROTHERS

Chapter 36. Role of Chemotherapy in Head and Neck Cancer 285
K Pavithran
- Induction Chemotherapy *285*
- Induction Chemotherapy Followed by CRT versus CRT Alone *286*
- Locally Advanced SCCHN *286*
- Postoperative Concurrent Chemoradiotherapy *287*
- Nasopharyngeal Carcinoma *288*
- Recurrent or Metastatic Disease *288*
- Metronomic Chemotherapy *288*
- Immunotherapy *288*

Chapter 37. Principles of Radiotherapy in Head and Neck Malignancies 290
Anoop R
- General Principles and Radiobiology *290*
- Four R's of Radiobiology *290*
- Fractionation *291*
- Methods of Radiation Delivery *291*
- Clinical Applications *292*
- Radiation Treatment Planning *292*
- External Beam Radiation Therapy *294*
- Three-dimensional Conformal Radiation Therapy (3D-CRT) *295*
- Intensity-modulated Radiation Therapy *295*
- Brachytherapy *297*
- Side Effects of Radiation Treatment *298*

Chapter 38. Molecular Biology of Head and Neck Cancer 300
Mayuri Mohan Rajapurkar
- Tobacco-related Cancers *301*
- Human Papillomavirus-related Cancers *301*
- Genetic Susceptibility *301*
- Carcinogenesis *302*
- Field Cancerization *302*
- Epithelial-to-Mesenchymal Transition *303*
- Epigenetic Modification *303*
- Molecular Pathways involved in HNSCC *303*
- Genetic Expression Profiling and Prognostic Markers *304*
- Role of Immunotherapy *305*

Chapter 39. Recent Advances in Management of Head and Neck Cancer 307
Deepak Balasubramanian
- Human Papillomavirus and Head and Neck Cancer *307*
- Transoral Robotic Surgery *307*

JAYPEE BROTHERS

- Sentinel Node Biopsy *308*
- Molecular Diagnostics in Thyroid Cancer *308*
- Newer Systemic Agents (Epidermal Growth Factor Receptor and Tyrosine Kinase Inhibitor) *309*
- Advances in Radiation Delivery Techniques *309*

Chapter 40. Head and Neck Reconstruction 310

Mohit Sharma, Abhijeet N Wakure, Sivakumar Vidhyadharan, Subramania Iyer

- Principles of Reconstruction *310*
- Goals of Reconstruction *310*
- Reconstructive Strategies *310*
- Postreconstruction Rehabilitation *323*

Index 327

JAYPEE BROTHERS

CHAPTER 14

Tumors of Infratemporal Fossa: Approaches and Management

Divya GM

JAYPEE BROTHERS

INTRODUCTION

The infratemporal fossa (ITF) is a deeply situated area having a complex anatomy with communications to many surrounding areas. This area can give rise to a range of benign and malignant tumors. Lesions in this area, with the exception of those with an inherent rapid growth pattern, may continue to grow unnoticed for a considerable period and delay the diagnosis. This delay in diagnosis, extensive disease, and the course of critical neurovascular structures through ITF in intimate association with one another pose a challenging scenario.

SURGICAL ANATOMY

Infratemporal fossa is roughly quadrangular in shape **(Fig. 1)**. It is bounded superiorly by the greater wing of the sphenoid medially and a part of the squama of the temporal bone laterally. The anterior boundary is formed by the posterior surface of the maxilla and posteriorly it is related to styloid apparatus, carotid sheath, and deep part of the parotid gland. The lateral boundary is formed by the zygomatic arch, masseter, and temporalis muscles, and the ascending ramus of the mandible and medial boundary is by the lateral surface of the lateral pterygoid plate, and the superior constrictor muscle of the pharynx. The bony boundaries are depicted in **Figure 2**. The ITF has no anatomical floor; it is limited anteriorly by the attachment of the medial pterygoid muscle and communicates with the parapharyngeal space anterior to the internal carotid artery.

The contents of the ITF are the medial and lateral pterygoid muscles, the mandibular division of the trigeminal nerve (V3), chorda tympani branch of facial nerve, otic ganglion, internal maxillary artery, and pterygoid venous plexus. The lateral pterygoid muscle arising from the infratemporal surface of the skull and the lateral aspect of the lateral pterygoid plate inserting into the mandibular condyle, crosses the entire ITF in an anterior-posterior direction and effectively divides the ITF into superior and inferior compartments.

The ITF communicates with the temporal fossa deep to the zygomatic arch. It communicates with the pterygopalatine fossa through the pterygomaxillary fissure and orbit via the inferior orbital fissure. It is connected to the middle cranial fossa via the foramen ovale and foramen spinosum. Because of these communications, tumors of ITF can easily spread to various surrounding areas.

CLASSIFICATION OF TUMORS OF INFRATEMPORAL FOSSA

The ITF encounters various types of pathologies. A systematic classification of tumors of the ITF was first put forward by Conley and according to him they are classified as primary, contiguous,

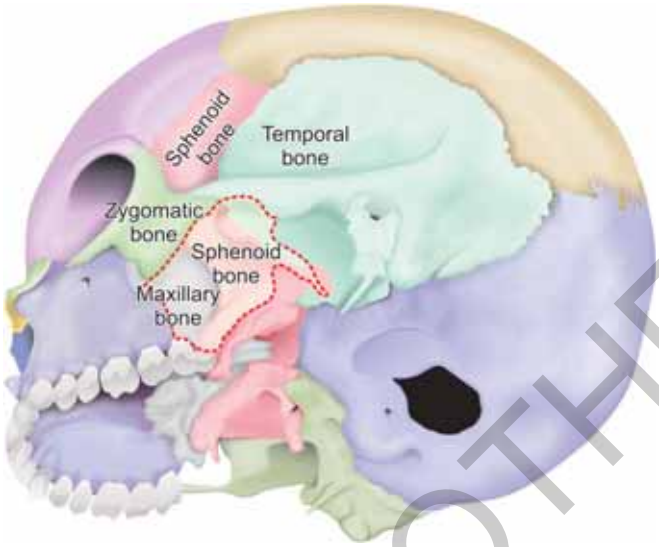

Fig. 1: Infratemporal fossa in quadrangular shape.

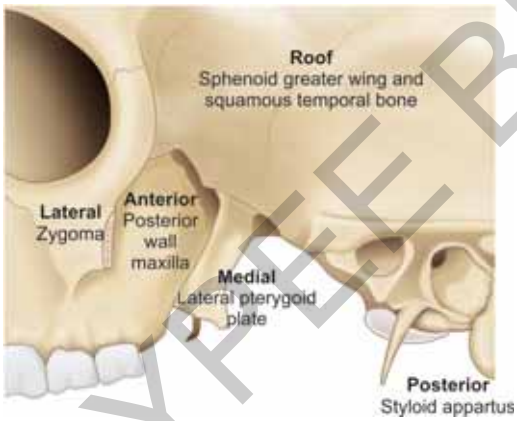

Fig. 2: Bony boundaries.

and metastatic. Extension of tumors from adjoining anatomical areas such as the maxilla, nasal cavity, nasopharynx, sphenoid, mandible, parotid gland, external acoustic meatus, and the cranial cavity are termed contiguous. This is the largest group and comprises both benign and malignant tumors. Approach to the ITF is then combined with the approach to the location of the primary pathology to obtain en bloc excision. This group of tumors is diagnosed relatively early because they usually present with symptoms pertaining to the site of their origin.

Primary tumors of the ITF are mesodermal in origin and comprise 25–30% of all the tumors seen in the area. Both benign and malignant tumors are encountered and they may remain undiagnosed for long periods of time. The symptoms are few and insidious and often referred to other areas. Conductive hearing loss, trismus, and sensory disturbances of the face are often present, but their onset may be so gradual that the patient may not have taken them seriously for a long time before seeking medical attention. The primary ITF tumors include meningioma, schwannoma, neurofibroma, malignant lymphoma, hemangioma, rhabdomyosarcoma, fibrosarcoma, and histocytosis X.

Metastatic tumors to the ITF by the hematogenous route are rare, but there are reports on metastases to ITF from lung, ovary, and breast carcinoma.

JAYPEE BROTHERS

DIAGNOSIS

The essential prerequisites in the management of ITF tumors are histopathology and assessment of tumor extension. Radiographic imaging is the vital component for knowing the exact extent of the tumor, owing to the inaccessibility of the ITF to physical examination. Both computed tomography (CT) and magnetic resonance imaging (MRI) provide valuable information and are obtained using standard skull base protocols. CT is superior to MRI in showing the remodeling or erosion of neurovascular foramina or other bones of the skull base. MRI better delineates the soft tissue planes, the tumor–soft tissue interface, and the presence of tumor along neural and vascular structures **(Figs. 3A and B)**. It may also help to identify the tissue of origin of the tumor to some extent, but is difficult in large tumors and those with multiple extensions CT and MRI are often complementary.

The relationship of the tumor to the ICA is a crucial issue and this information can be obtained noninvasively by magnetic resonance angiography (MRA) and computed tomography angiography (CTA). Angiography is preferred, if preoperative embolization of the tumor is indicated. If the risk for injury or sacrifice of the ICA is high, the collateral cerebral blood flow may be evaluated using angiography balloon occlusion with xenon CT.

In majority of cases, a histologic diagnosis can be obtained by aspiration cytology, but in deep-seated lesions, a CT-guided and fine needle aspiration may be needed. If cytology is not conclusive or in suspected cases of soft-tissue sarcomas, biopsy is indicated. The transantral and transoral route via the gingivolabial sulcus are the most frequently used routes for obtaining a biopsy. Rarely, a histologic diagnosis cannot be obtained before the approach. A frozen section analysis, obtained via a skull base approach, may be sufficient to justify the resection of the tumor under these circumstances.

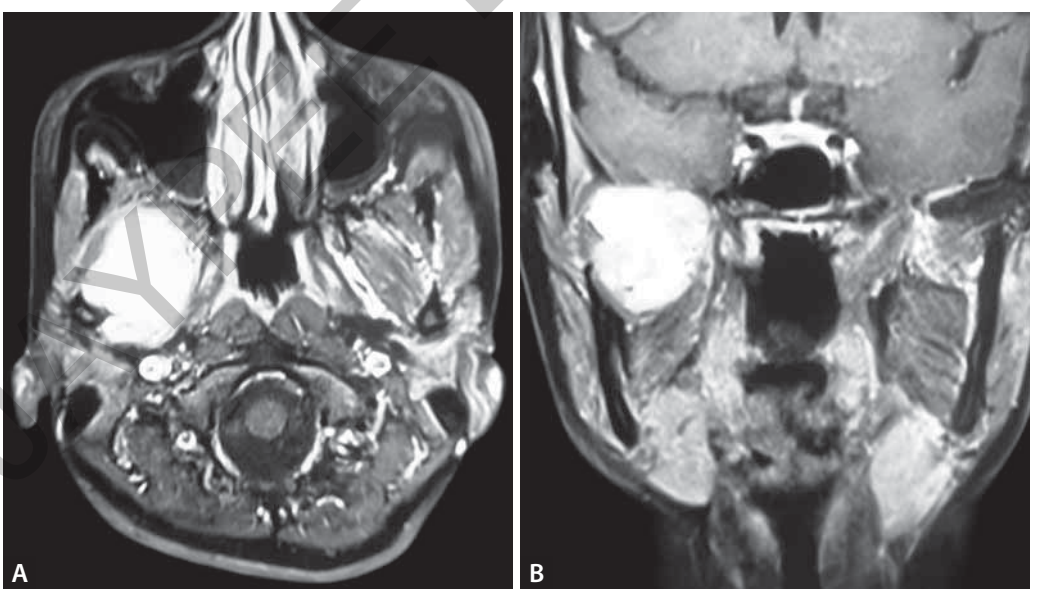

Figs. 3A and B: MRI showing soft tissue tumor involving right infratemporal fossa.

JAYPEE BROTHERS

PATIENT SELECTION

For the therapeutic-surgical plan, assessment of the nature, origin, and extension of the tumor is crucial. The selection of the surgical approach is also affected by other factors as patient needs and demands the biologic behavior of the tumor, other coexistent diseases, and the training and experience of the surgeon. A multidisciplinary approach is needed in most pathologies affecting the ITF to stage, diagnose, and extirpate the tumor, and at the same time to provide an acceptable cosmetic and functional reconstruction.

APPROACHES TO INFRATEMPORAL FOSSA

The advances in imaging, surgical techniques developed in the fields of head and neck, craniofacial, orthognathic, and skull base surgery, and an improved understanding of the anatomy of the skull base have improved and modified the surgical approaches to the ITF.

The approach to ITF may be anterior, lateral or combinations.

- *Anterior*:
  - Transmandibular
  - Transfacial
  - Intraoral.
- *Lateral*:
  - Transmandibular
  - Transzygomatic
  - Subtemporal preauricular approach
  - Lateral Fisch approaches.
- *Combinations*: These approaches may be combined with a (fronto) temporal craniotomy as necessary.

Anterior Approaches

Transmandibular: Mandibular or Extended Mandibular Swing

This approach provides good control of the vessels and nerves and en bloc resection of nasopharynx, posterior maxilla, ITF structures, mandibular ramus, and parotid gland. Here the lower lip is divided in the midline **(Fig. 4A)**, the mandible is sectioned anterior to the mental foramen, and the hemimandible swung laterally, providing the exposure **(Fig. 4B)**. The procedure has been modified by Attia et al. by a second osteotomy of the mandibular ramus above the lingula to allow the ascending ramus to be retracted further laterally and superiorly for improved access.

Transfacial Approaches

Facial translocation: Janecka described this approach which combined facial soft tissue translocation and craniofacial osteotomies. The facial incision resembles a Weber–Ferguson incision. Craniofacial osteotomies include the maxilla with floor of the orbit and complete zygoma as separate units. The coronoid process is also removed giving an excellent exposure. At the end of the procedure the removed bones are replaced and fixed by miniplates.

Pedicled bone cheek flaps: The basic concept of the transfacial approaches is the mobilization of pedicled bone cheek flaps (PBCF) in which the midfacial bone segment remains pedicled to the soft tissues of the cheek thereby retaining their blood supply. According to the classification system proposed by Clauser **(Table 1)**, there are four levels of transfacial approaches with the aim of simplifying surgical planning. The approach is determined by the anatomical site of the lesion.

The transfacial approach providing maximum access to the ITF is the Maxillo-Cheek Flap (MCF) combined with the mandibular cheek flap. By taking the maxilla laterally out of the operative field, the MCF removes the anterior boundary of the ITF. The inclusion of the zygoma and/or the mandible from either an anterior or lateral approach then removes its lateral boundary. The addition of a (fronto) temporal craniotomy allows the

JAYPEE BROTHERS

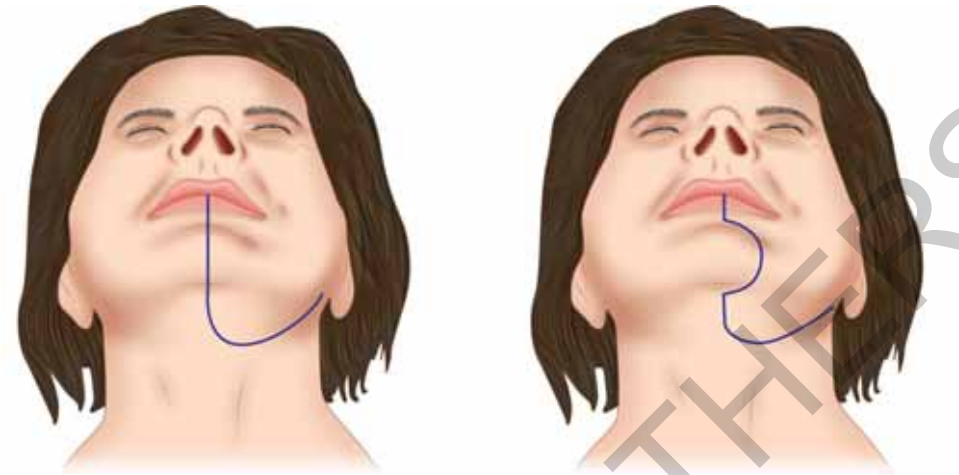

Fig. 4A: Midline lip-split.

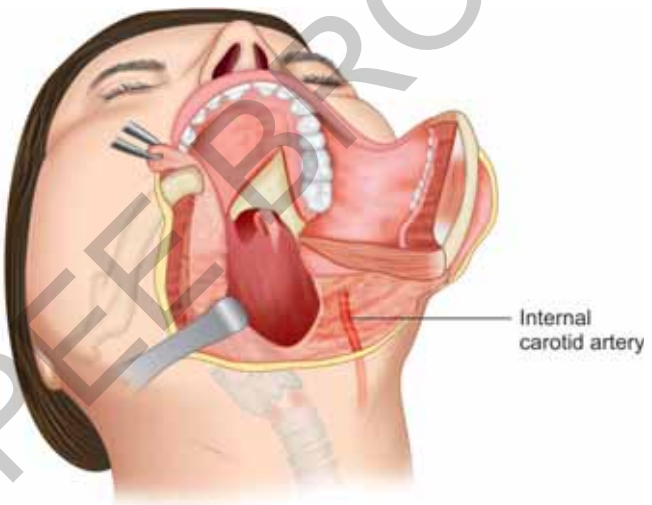

Fig. 4B: Left paramedian mandibulotomy.

JAYPEE BROTHERS

roof to be removed under direct vision. These combination approaches give a wide exposure to ITF.

Maxillary swing: Wei, et al. described this technique. Here the maxilla is separated from the facial skeleton, but remains attached anteriorly to the cheek flap and is known to offer excellent exposure to midline structures. The major limitation of the maxillary swing is limited exposure of tumors involving the petrotemporal compartment of the skull base, as well as extension into the middle cranial fossa.

Intraoral Approaches

These approaches provide limited access that cannot be easily extended peroperatively. The superior gingivolabial sulcus posteriorly is close to the tuberosity of the maxilla and provides

Table 1: Transfacial approaches.

Levels	*Extent of lesions*	*Approach*
Level 1	Lesions of the ethmoid, sphenoid, upper nasopharynx, and anterior cranial base	Nasal cheek flap + Le Fort I Optional: Nasal Maxillo-cheek Flap (NMCF)
Level 2	Lesions involving the retropharynx and clivus	NMCF ± Contralateral Maxillo-cheek Flap (MCF)
Level 3	Lesions of the retromaxilla or pterygomaxillary space	MCF
Level 4	Lesions of the parapharyngeal space or infratemporal fossa	MCF or mandibular cheek flap or combination of the two

access to the lower part of the ITF. They can provide access for biopsy purposes and very occasionally can be employed for the removal of small, benign, and well-circumscribed lesions.

Le Fort I approach: After down-fracturing the maxilla, removal of the posterolateral wall of the maxilla provides limited exposure to the ITF, by removing its anterior boundary.

Transantral approach: The anterior, lateral, medial, and posterior walls of the maxilla are removed leaving the alveolus and the orbital floor intact. This will give minimal access to the ITF and nasopharynx.

Transpalatine approach: Limited exposure of the inferomedial aspect of the ITF can be achieved with this approach.

Lateral Approaches

Lateral Transmandibular Approaches

The exposure of the ITF obtained from a lateral approach via the mandible is variable. An osteotomy of the mandibular ramus with separation/distraction of the bone ends can provide limited exposure. More extensive exposure similar to that achieved with the extended mandibular swing may be achieved by elevation of the ascending ramus and masseter muscle out of the operative field with a simple osteotomy at the junction of the body and ascending ramus. By resection of the ascending ramus of the mandible, wide lateral exposure of the ITF and adjacent areas may be obtained.

Lateral Transzygomatic Approach

The lateral transzygomatic approaches to the ITF and adjacent areas involve the disarticulation and inferior displacement of the zygoma, usually pedicled to the masseter muscle, as well as the displacement of the temporalis muscle. The temporalis muscle may be displaced in either a superior or inferior direction. These techniques improve access to the superior compartment of the ITF by removing its lateral boundary.

Subtemporal Preauricular Approach

This approach uses a preauricular incision. It involves dividing the zygomatic arch and displacing it inferiorly, dividing the malar eminence (zygoma) and displacing it anteriorly, and cutting the coronoid process and retracting it superiorly with the attached temporalis muscle. Reconstruction is accomplished by using the temporalis muscle or a pericranial flap to cover the dura, a free fat graft to fill the space left by tumor excision, and by wiring the zygomatic arch and malar eminence into their original positions. It can be combined with intradural approaches to provide additional exposure to the anterior and middle cranial fossa, cavernous sinus, and sella turcica. Extradurally, the orbit, pterygopalatine fossa,

JAYPEE BROTHERS

and nasopharynx can also be addressed using this approach.

Lateral Fisch Approaches

Access to the ITF and adjacent areas using the lateral approach was described by Fisch et al. Fisch has offered three basic approaches. The type A approach consists of radical mastoidectomy, anterior transposition of the facial nerve, and exploration of the posterior ITF. The Fisch type B and C approaches are designed to approach more anterior pathology involving the petrous apex, clivus, and superior ITF. The type C approach is an extension of the type B approach, and is used for lesions of the anterior ITF, sella, and nasopharynx. These approaches are by postauricular incision.

The type D approach is a preauricular ITF approach that uses orbitozygomatic osteotomies and resection of the floor of the middle fossa to expose the medial middle cranial fossa without a lateral temporal craniotomy. Subtype D1 addresses tumors of the anterior ITF, while the subtype D2 is designed for lateral orbital wall lesions and high pterygopalatine fossa tumors. Although these preauricular approaches do not include a temporal craniotomy, the floor of the skull base can be drilled away to allow full access to the ITF.

There is no one correct/ideal approach to the ITF. The only requirements are that the approach adopted should provide adequate access for the lesion, and the morbidity of the approach is considered acceptable.

Endoscopic Approach to the Infratemporal Fossa

The endoscopic endonasal approach provides an alternative to open surgical approaches. A transmaxillary corridor with transpterygoid dissection is used to expose the pterygopalatine fossa. Further removal of the posterior wall of the maxillary sinus transgresses the pterygomaxillary fossa to provide access to the ITF.

FURTHER READING

1. Givi B, Liu J, Bilsky M, et al. Outcome of resection of infratemporal fossa tumors. Head Neck. 2013;35(11):1567-72.
2. Janecka IP, Sen CN, Sekhar LN, et al. Facial translocation: A new approach to the cranial base. Otolaryngol Head Neck Surg. 1990;103(3):413-9.
3. McCoul ED, Schwartz TH, Anand VK. Endoscopic approach to the infratemporal fossa. Operative Techniques in Otolaryngology. 2011;22(4):285-90.
4. Sekhar LN, Schramm VL Jr, Jones NF. Subtemporal-preauricular infratemporal fossa approach to large lateral and posterior cranial base neoplasms. J Neurosurg. 1987;67(4):488-99.
5. Taylor RJ, Patel MR, Wheless SA, et al. Endoscopic endonasal approaches to infratemporal fossa tumors: A classification system and case series. Laryngoscope. 2014;124(11):2443-50.

JAYPEE BROTHERS

or detailed information on otolaryngology books, visit our website www.jaypeebrothers.com, for detailed information on otolaryngolo

Basic Concepts in
Head & Neck Surgery and Oncology

Salient Features

- Simple and covers the basic concepts in the management of head and neck cancers
- Site-wise coverage in six sections and a section for general topics
- Each section has chapters on pathology, imaging, management principles and surgical principles
- Provides fundamental knowledge necessary to practice evidenced-based management of head and neck cancers
- Useful for ENT surgeons, general surgeons, oral and maxillofacial surgeons, radiation and medical oncologists, especially the postgraduate trainees and residents in these specialties
- Six new chapters added on Parathyroid Tumors, Infratemporal Fossa, Temporal Bone Tumors, Facial Nerve, Tracheostomy, and Melanoma and Nonmelanoma Skin Cancers
- Completely revised chapters on Management of Differentiated Thyroid Cancers and Cervical Nodal Metastasis with Unknown Primary.

Krishnakumar Thankappan MS DNB MCh is a Professor, Department of Head and Neck Surgery and Oncology, Amrita Institute of Medical Sciences, Kochi, Kerala, India. He completed his basic training in Otolaryngology at BJ Medical College, Pune; MCh in Head and Neck Surgical Oncology at Amrita Institute of Medical Sciences, Kochi; and Advanced Fellowship in Head and Neck Oncology at Roswell Park Cancer Institute, Buffalo, USA. He has also got advanced training in Skull Base Surgery at the University of Pittsburg, USA. He is also a pioneer in the field of Robotic Surgery in India. He has published more than 60 papers in international journals. He serves as a Reviewer for several international journals and is the Regional Editor (Asia Pacific) for the Journal of Cranio-Maxillary Trauma and Reconstruction and the social media Editor for the Oral Cancer Journal. He has also written a book titled "Dysphagia Management in Head and Neck Cancers".

Subramania Iyer MS MCh FRCS is a Professor and Head, Department of and Head and Neck Surgery and Oncology, Amrita Institute of Medical Sciences, Kochi, Kerala, India. He is graduated from the Government Medical College, Kottayam, Kerala, in 1979, before completing his higher surgical training in Head and Neck Surgery and Plastic Surgery from AIIMS, New Delhi; Medical College, Calicut; and various centers in the United Kingdom. He did a Fellowship in Craniofacial Surgery at Mexico City, UICC; Laryngeal Cancer Surgery at Center Oscar Lambret, Lille; and Tissue Engineering at Rice University, Houston. He is the Past President of the Foundation for Head and Neck Oncology of India, Secretary of the Indian Society of Microsurgery, President of the Head and Neck Cooperative Research Group, Member of the Executive Council of the Association of Plastic Surgeons of India, and President of the Eurasian Association of Head and Neck Oncology. He has written several international publications and serves as a Reviewer for many journals in the field of otolaryngology and plastic surgery.

Available at all medical bookstores
or buy online at www.jaypeebrothers.com



JAYPEE BROTHERS
Medical Publishers (P) Ltd.
www.jaypeebrothers.com

Join us on facebook.com/JaypeeMedicalPublishers

Shelving Recommendation
OTOLARYNGOLOGY

