formation on dermatology books, visit our website www.jaypeebrothers.com, for detailed information on dermatology books, visit our website www.jaypeebrothers.com

Celebrating 50 YEARS
Passion, Quality and Innovation in Healthcare Publishing

Leg Ulcers

Diagnosis & Management



S Sacchidanand
Eswari L
Shilpa K

JAYPEE

Contents

1. Epidemiology and Socioeconomic Impact 1
Shashi Kumar BM, Savitha AS
Epidemiology 1
Etiology 1
Social and Economic Impact 2
Psychological Problems 3

2. Venous Anatomy of the Lower Extremity 5
Madhulika Mhatre, Aseem Sharma, Aniketh Venkataram
Superficial Venous System 5
Deep Venous System 9
Perforating Veins 9
Accompanying Nerves 10
Applied Anatomy 10

3. Pathology of Leg Ulcers 13
Divya Gorur, Heera Ramesh
Pathophysiology of Venous Leg Ulcer 13
Pathophysiology of Arterial Ulcers 14
Vasculitic Ulcers 15
Neuropathic and Diabetic Foot Ulcer 15
Ulcerating Skin Diseases 16
Infectious Diseases 17
Drugs 17
Malignancy (Ulcerating Tumors) 17
Hematological Disorders 17
Clotting Disorders 17

4. Microbiology of Leg Ulcers 19
Amrita Hongal, Ujwal M
Sample Collection and Analysis Methods 19
Pathogenesis and the Flora 19

5. Wound Healing 23
Shivakumar Patil, Kavya Thimmaiah
Hemostasis 23
Inflammation 24
Proliferation 24
Remodeling of Connective Tissue 25
Scarless Healing 26
Chronic Wound 26

Factors Influencing Wound Healing 26
Healing of Skin Wounds 27
Wound Strength 27

6. History Taking and Examination in Chronic Leg Ulcers **28**
Shilpa K, S Sacchidanand
History Taking 28
Physical Examination 29

7. Venous Leg Ulcers **37**
Amina Asfiya, Manjunath Shenoy
Etiopathogenesis 37
Classification of Chronic Venous Insufficiency 38
Clinical Features 38
Venous Ulcer 39
Arterial Disease 39
Diagnostic Evaluation 40
Management 41
Venous Ulcer Recurrence 45
Criteria for Specialist Referral for Appropriate Management 45

8. Diabetic Foot Ulcers **47**
Vivekanand, Vaibhav Lende, Sravan CPS
Epidemiology 47
Pathophysiology 47
Biomechanics and Foot Pressures 50
Presentation and Diagnosis 50
Management 52
The Charcot Foot 56

9. Neuropathic Ulcers **61**
Savitha AS, S Sacchidanand
Causes of Neuropathic Ulcers 61
Etiopathogenesis 61
Stages of Ulcer Formation 62
Clinical Features 62
Approach to Patient with Neuropathic Ulcer 63
Management of Ulcer 63

10. Ischemic Ulcers, Pyoderma Gangrenosum and Vasculitic Ulcers **68**
Biju Vasudevan, Gayatri Gupta
***Ischemic (Arterial) Ulcers* 68**
Risk Factors 68
Pathogenesis 69
Clinical Features 69
Management 73
***Pyoderma Gangrenosum* 80**
Definition 80
Epidemiology 80
Etiology 80

Pathogenesis 80
Associations 80
Clinical Features 81
Differential Diagnosis 82
Diagnosis 82
Treatment 82
Prognosis 83
Vasculitic Ulcer 83
Introduction 83
Clinical Features and Management 84

11. Principles of Leg Ulcer Management **87**
Anju George

12. Investigations and Radiological Diagnosis of Leg Ulcers **94**
Shwetha S, Deepak HS
Investigations for Leg Ulcers due to Venous Insufficiency and Dependency 94
Investigations for Arterial Cause of Leg Ulcers 99
Investigations for Ulcer Secondary to Vasculitis 103
Neuropathic Ulcers 104
Hereditary Sensory Neuropathy Type 1C: Charcot–Marie–Tooth Disease 107
Laboratory Screening Tests for Clotting Disorders 108
Metabolic Causes of Leg Ulcers 108
Infectious Causes of Leg Ulcer 108
Hematological Causes of Leg Ulcers 108
Investigating Atypical Leg Ulcers 108

13. Topical Therapy for Leg Ulcers **114**
Nagesh TS, Sneha M
History and Physical Examination 114
Management of Leg Ulcer 114

14. Systemic Therapy of Leg Ulcers **120**
Brijesh Nair
Pentoxifylline 120
Aspirin 121
Zinc 121
Antibiotics/Antimicrobials 121
Systemic Steroids 122
Phlebotonics/Flavonoids 122
Fibrinolytic Enhancers 123
Prostaglandin and Prostacycline Analogues 123

15. Compression Therapy and Dressings **126**
Shilpa K, S Sacchidanand, Sachin S
Mechanism of Compression Stockings 126
Types of Compression Stockings 126
Grading the Strength of Compression Stockings 126
Assessment to be done Before Prescribing Compression Therapy 128
Dressings 129

16. Role of Skin Grafting in Managing Leg Ulcers **136**
Smitha Segu, Suhas S
Applied Anatomy of Skin 136
Stem Cells in Skin and Skin Regeneration 137
Common Ulcers and Role of Skin Grafts 138
Optimization of the Wound Bed 138
Negative Pressure Wound Therapy (Vacuum-Assisted Closure Therapy) 139
Hyperbaric Oxygen Therapy 139
Pre-Requisites of Wound Bed for Split Thickness Skin Graft 140
Contraindications for Skin Grafting 140
Skin Graft 140
Skin Graft Storage 145
Complications 145
Recent Advances in Skin Replacement 146

17. Role of Platelet Rich Plasma and Platelet Rich Fibrin in Managing Leg Ulcers **148**
Reena Rai, Yuvasri Gunasekaran
Role of Platelet-Derived Products 148
Platelet Rich Plasma 149
Platelet Rich Fibrin 151

18. Novel Research and Recent Advances in Managing Leg Ulcers **155**
Eswari L, S Sacchidanand
The Role of Stem Cells 155
Biopharmaceutical Agents 156
Endothelial Progenitor Cell Therapy 156
Novel Drug Delivery Systems 156
Biologically Active Skin Graft Substitutes/ Tissue Engineered Skin Equivalents 159
Acellular Regenerative Tissue Scaffold 160
Human Amniotic Cellular/ Tissue Based Products 161
Topical Therapy 161
Dressings 162
Balneotherapy 162
Oral Nutritional Supplements 162
Photodynamic Therapy 162
Negative Pressure Wound Therapy 163
Hyperbaric Oxygen Therapy 163
Electrical Stimulation 164
Pulsed Radiofrequency Electromagnetic Field 164
Surgical Therapy 164

Index *169*

CHAPTER 2

Venous Anatomy of the Lower Extremity

Madhulika Mhatre, Aseem Sharma, Aniketh Venkataram

INTRODUCTION

Historically, microcirculation of the lower limb has not been given its due importance or diligence, with a description of a functional, three-pronged system comprising the superficial plexus, the deep plexus and the interconnecting communicators, as described in older literature. These were based primarily on cadaveric studies, and basic radiological assessment. In recent times, however, with the advent of the Doppler ultrasound, and emerging radiographic modalities like endoscopic ultrasonography, invasive intravascular ultrasound, and digital subtraction venography, the microvasculature of the venous system has been delineated in great detail.

The papillary dermal plexus drains into the reticular venous plexus, which further terminates into the superficial veins through vertical channels. The fascia of the deep muscle is a fulcrum for the deep and superficial compartments, the former comprising vasculature from the skin above, and the latter till the bone below. The venous vasculature is, thus, subdivided into the superficial venous plexus, deep venous plexus, communicators (intracompartmental), perforators communicating veins connect veins within a compartment, perforators connect veins between the superficial and deep compartments; hence, the nosology, and the plantar reservoir vein complex.

The complex interplay between these deep compartments, the perforators and the communicators, and the three muscular pumps, viz., the foot, the calf, and the thigh pumps, help to maintain circulation in the lower limb and prevent acute and venous insufficiency of the venous system.

The learning objective of this chapter includes knowledge of normal anatomical make-up of the lower extremity veins, its anatomical variants, and aberrations. It shall be covered under the subheadings of (Fig. 1):

- Superficial veins
- Deep venous plexus
- Perforators
- Accompanying structures.

SUPERFICIAL VENOUS SYSTEM

Synonyms: Superficial compartment, subcutaneous plexus group

This compartment shows the most anatomic variability in terms of venous structure and distribution. The small plantar (Lejar's plexus) and dorsal subcutaneous veins mark its origin, forming the venous plexus of the foot. They lie in the superficial fascia over the surface of deep fascia. Most of their blood flows to the deep veins through perforating veins. The dorsal arch is formed at the level of proximal metatarsals by small superficial veins and give off the great (medially) and small (laterally) saphenous veins (Fig. 2). Other tributaries include the medial and dorsal digital veins, and the marginal veins.

Great Saphenous Vein

Synonyms: Long saphenous vein

Course

This is the longest vein, the human body has. Originating from the medial marginal vein and the medial dorsal venous arch, the great saphenous vein (GSV) crosses the distal third of the medial surface of the tibia obliquely. It then ascends slightly behind the medial border and crosses

JAYPEE BROTHERS

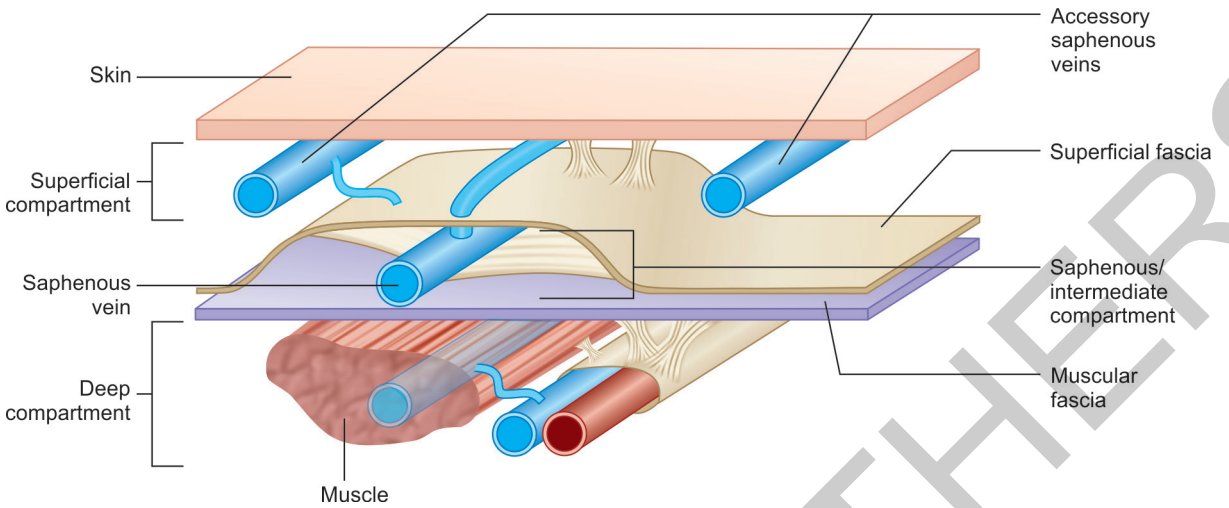

Fig. 1: The compartments. The saphenous fascia forms the superior border of saphenous compartment and the inferior border is formed by the muscle fascia. It contains the saphenous veins and the saphenous nerve. The accessory saphenous vein overlies this compartment, below the dermis.

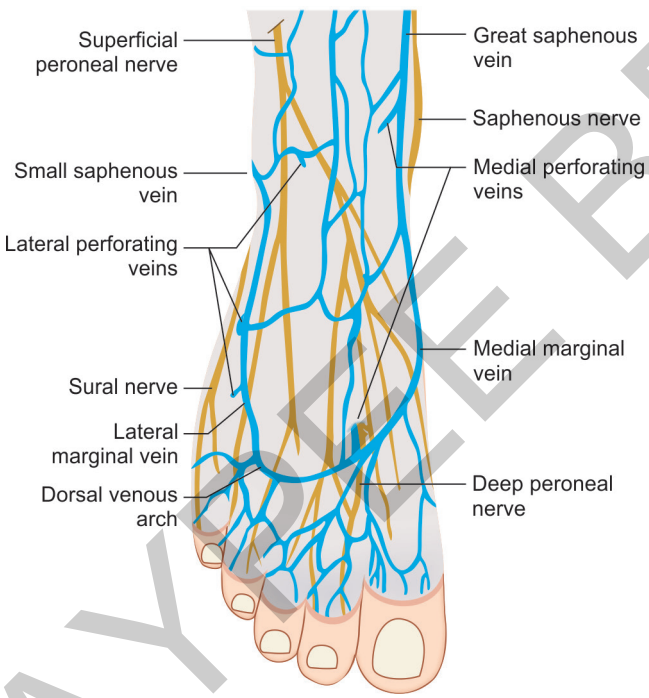

Fig. 2: Superficial and perforating veins of the foot and ankle.

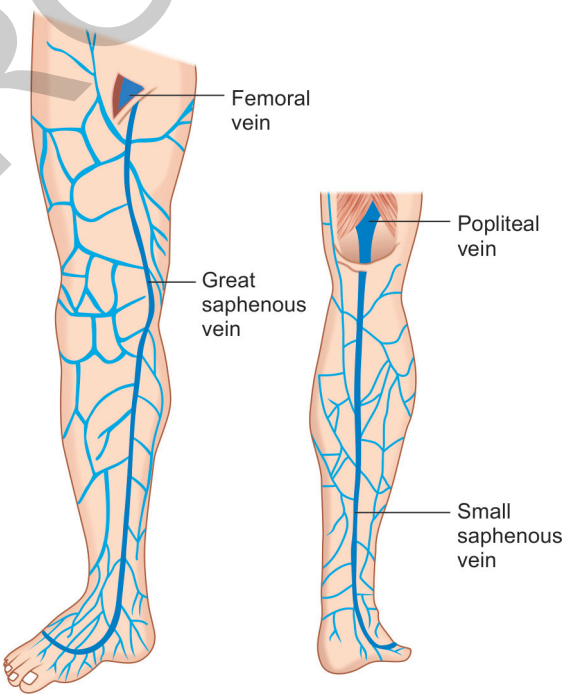

Fig. 3: Anatomical course of the greater and smaller saphenous veins.

the knee, posteromedially, to the medial tibiofemoral condyles. It further runs up and connects with femoral vein at saphenofemoral junction (SFJ), through fossa ovalis—saphenous, in the femoral triangle. As discussed, the anatomic variability of the GSV renders it unreliable for surface markings (Figs. 3 and 4).

Tributaries

- *Calf tributaries—arch veins*: GSV gives off two main tributaries, the anterior and posterior arch veins and many other unnamed communications with small saphenous vein (SSV). The "da Vinci vein" or posterior arch vein drains the medial side, and joins the GSV, distal

JAYPEE BROTHERS

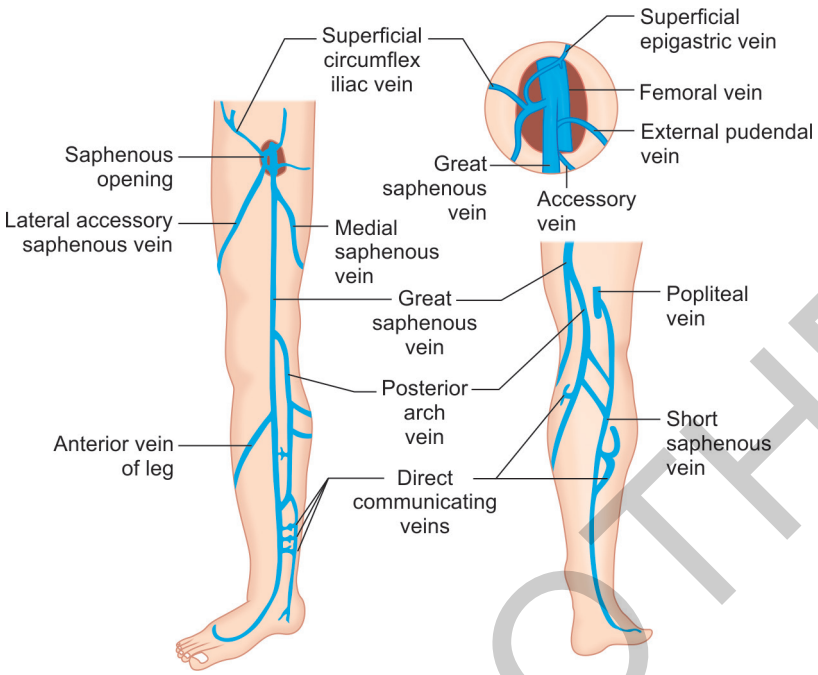

Fig. 4: Tributaries of the saphenous veins along their respective courses.

to knee. Cockett perforators, invariably connect the posterior tibial vein to the posterior arch vein.

- *Thigh tributaries—accessory saphenous veins*: GSV receives the lateral and medial accessory saphenous veins. The lateral vein drains the anterolateral thigh, while the medial vein drains the posteromedial aspect of the thigh.
- Before piercing the cribriform fascia, the GSV gives off the following branches:
  - Superficial circumflex iliac
  - Superficial epigastric
  - Superficial external pudendal
  - Deep external pudendal (immediately before termination after piercing the femoral sheath).

The Eye of Horus: Horus was the Egyptian God of the sky. A sonographic peculiarity can be found in the anatomical association of the various fascias involving the inferior extremity veins. The saphenous fascia, lies in front of the saphenous canal, and the fascia lata, behind it. Together with the saphenous vein in the center, they form the "Eye of the Egyptian", or the "Horus Eye" (Figs. 5A and B).

Small Saphenous Vein

Synonyms: Lesser saphenous, short saphenous

Course

It begins on dorsal venous arch (lateral aspect), opposite to the GSV origin, runs posterior to the lateral malleolus, and emerges lateral to the calcaneal tendon. At the upper leg, the SSV empties at the saphenopopliteal junction (SPJ) into the popliteal vein, between the gastrocnemius muscle heads. Anatomic aberrations include the SSV terminating into the GSV, or even rarely, the femoral vein (Figs. 3 and 4).

Tributaries

Named: Giacomini, an eponym for an Italian anatomist, is a large communicant vein between the GSV and SSV.

Junctions

Saphenofemoral Junction

It is best described as a venous star with five main tributaries. Due to high variability and anatomical aberrations, the branches at this confluence have never been delineated.

Saphenopopliteal Junction

The termination of the SPJ is highly variable. A universal classification divided Types A, B, and C. Type A is the classical SPJ. Type B is when the SSV empties into the SPJ with another cranial extension into the GSV or SFJ. Type C is when there is no SPJ, but the vein empties higher up.

JAYPEE BROTHERS

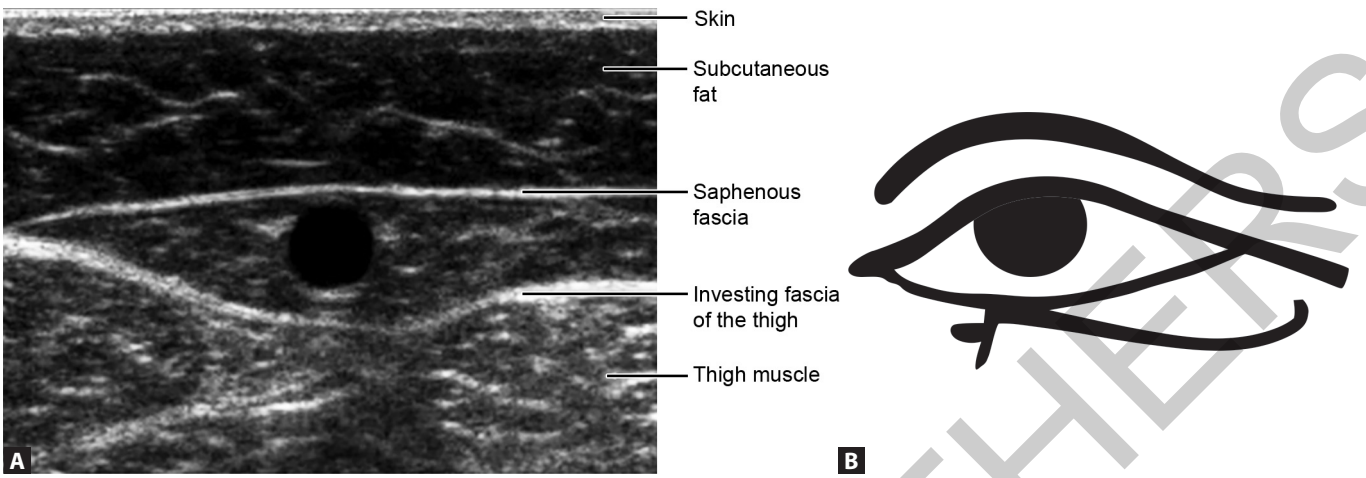

Figs. 5A and B: (A) The Eye of Horus; (B) Schematic representation of the Egyptian eye.
Source: Dr Sandhya Dey, Consultant Radiologist, Mumbai.

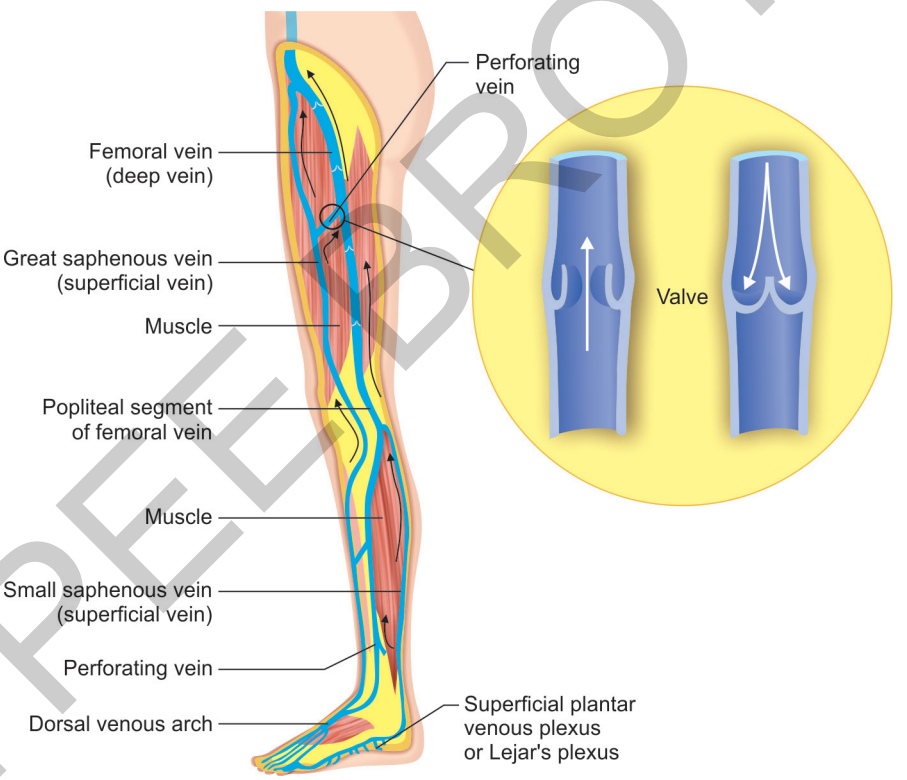

Fig. 6: The valvular system of the superficial veins of the inferior extremity.

Valves

Bicuspid valves exist direct flow to the heart. These are larger valves at termination of venous trunks. The GSV usually has 6–14 valves, up to 20, more in number in the leg, compared to the thigh. One valve called the preterminal valve is present as GSV pierces through the cribriform fascia and the terminal valve at the SFJ (Fig. 6).

The SSV has 4–13 valves, which are more closely spaced, with the highest valve at the termination of the SSV.

JAYPEE BROTHERS

DEEP VENOUS SYSTEM

Synonyms: Deep fascial plexus group, venae comitantes, submuscular plexus

Often paired, the deep veins are known as "venae comitantes" or (artery) accompanying veins, by virtue of flanking major vessels.

Course

The deep plantar arch accumulates blood from metatarsum and phalanges. At the ankle, the medial and lateral plantar veins form the posterior tibial vein. The major dorsal deep veins (dorsalis pedis) form the anterior tibial veins.

The posterior tibial veins drain the GSV and posterior arch veins via perforators. They then pierce the soleus muscle and continue as the popliteal vein.

The anterior tibial veins drain the muscles of the anterior compartment. They branch to form the peroneal veins forms. The anterior tibial and peroneal veins form the tibioperoneal trunk, which drains into the popliteal vein.

The profunda femoris vein drains the lateral thigh and receives perforators form the lateral accessory saphenous vein, which joins the femoral vein to form the common femoral vein, which receives the GSV at the SFJ. It also receives the medial and lateral circumflex femoral veins, and continues as the external iliac vein (Fig. 7).

The deep veins of the foot and distal calf have many valves at 2 cm intervals. The thigh deep veins have very few valves.

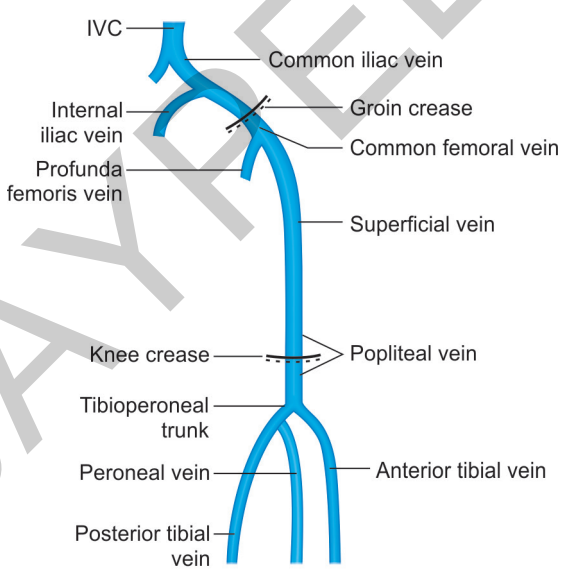

Fig. 7: The deep venous plexus of the lower limb.

Venous Sinuses—The Gastrocnemius—Soleus Muscle Pump

These large, thin-walled blood-filled spaces located mostly in the soleus (<20 sinuses in number) and to a lesser extent in gastrocnemius, formed by superficial, deep, and the perforator complex. They can house a significant volume of blood, thereby functioning as peripheral heart chambers. Their primary function is to aid circulation by enforcing venous return against the gravitational pull. The draining veins have valves, which are vital for the efficiency of the peripheral muscle pump.

PERFORATING VEINS

They form connections between the superficial and deep venous plexi. They are classified as: indirect and direct.

- *Indirect*—connects superficial and deep veins through muscular veins.
- *Direct*—GSV and SSV are large direct perforators (Figs. 8 to 10).

Small direct perforators have been grouped and enumerated on the basis of anatomic levels in the lower limb (Fig. 11).

Thigh:

- *Dodds*—to popliteal vein
- *Hunterian*—to superficial femoral vein.

Calf:

- *Lateral*: Peroneal perforators; SSV to the peroneal vein. Named ones include the *Bassi* perforator (lateral malleolus)
- *Anterior*: Premalleolar, mid-crural; drain GSV into anterior tibial vein.

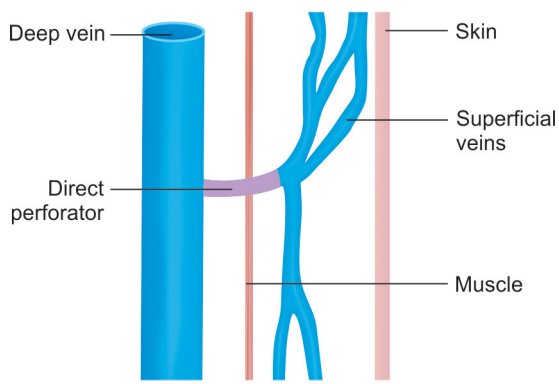

Fig. 8: Direct perforating veins.

JAYPEE BROTHERS

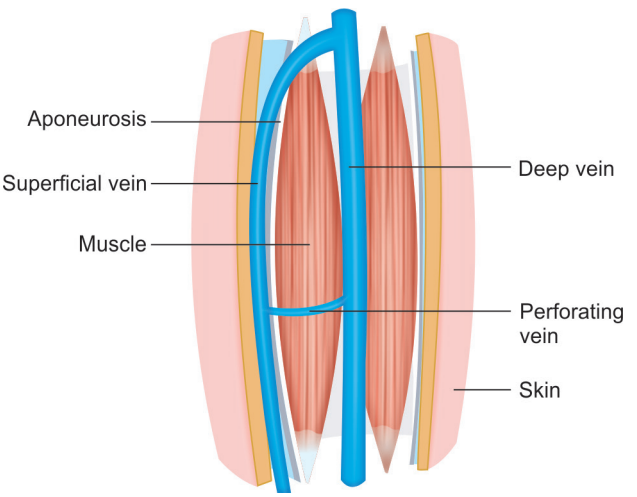

Fig. 9: Representative diagram of the anatomical location of the perforators.

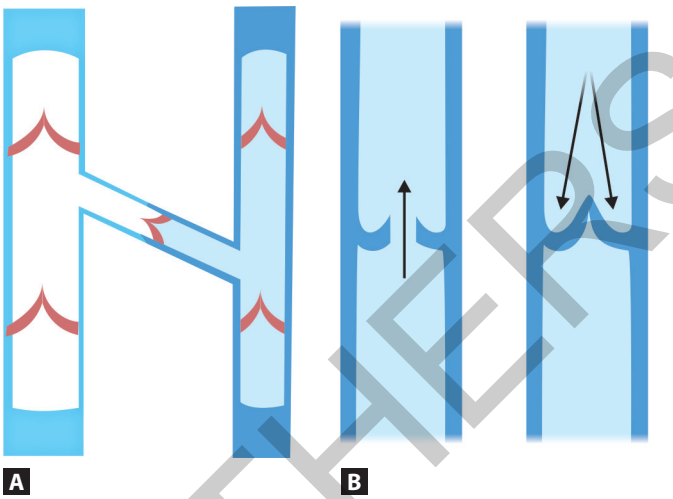

Figs. 10A and B: The perforators and valves allowing unidirectional flow.

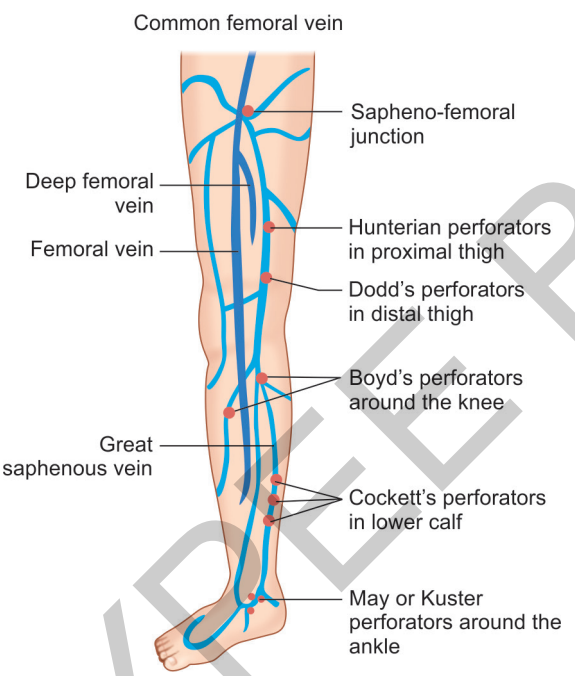

Fig. 11: Eponymous perforators of the lower limb.

- *Medial*:
  - *Cockett I (behind malleolus)*—connects GSV to posterior tibial veins
  - *Cockett II* (7–10 cm from medial malleolus)
  - *Cockett III* (10–12 cm from malleolus).

Paratibial Perforators

- *Boyd's* perforators—connect the GSV to the popliteal veins.
- Ankle perforator—*May and Kuster*
- *Foot*—connects the superficial venous arch to the dorsalis pedis vein; less than 10 in number.

In 2001, the International Union of Angiology (IUA) retracted this named nosology and aimed to rename the perforators as per draining veins (Table 1).

ACCOMPANYING NERVES

Saphenous Nerve

The cutaneous branch of femoral nerve originates in the thigh. It accompanies the superficial femoral artery, deep to the Sartorius. The nerve then travels close to the GSV, which makes venesection, phlebotomy, or venous ablation almost impossible without nerve injury. Eventually, it terminates by supplying skin over the medial leg and foot.

Sural Nerve

This is the cutaneous branch of tibial nerve. It originates between the gastrocnemius muscle heads, and terminated by supplying posterolateral skin over the leg and lateral foot.

APPLIED ANATOMY

Venous diseases can be divided into:

- *Diseases due to thrombosis*:
  - Superficial thrombophlebitis
  - Deep vein thrombosis.
- *Diseases due to insufficiency*:
  - Varicose veins
  - Lipodermatosclerosis

JAYPEE BROTHERS

Table 1: The revised International Union of Angiology (IUA) nosology (2002).

Current and historical nomenclature of perforating veins of the lower extremity		
Location	***Current nomenclature***	***Eponym***
Foot perforators	Dorsal foot PV Medial foot PV Lateral foot PV Plantar foot PV	
Ankle perforators	Medial ankle PV Anterior ankle PV Lateral ankle PV	May's or Kuster's
Leg perforators	Medial leg PV Paratibial PV • Posterior tibial PV Anterior leg PV Lateral leg PV Posterior leg PV • Medial gastrocnemius PV • Lateral gastrocnemius PV • Intergemellar PV • Para-Achilean PV	Boyd's, Sherman's, 24 cm Cockett's I, II, and III
Knee perforators	Medial knee PV Suprapatellar PV Lateral knee PV Infrapatellar PV Popliteal fossa PV	

(PV: perforator vein)

- Chronic venous insufficiency—venous ulceration
- Stasis dermatitis.

CONCLUSION

To conclude, the venous anatomy of the lower limb is both unreliable and unpredictable. Common patterns with specific anatomic variability, when studied and understood, help comprehend venous pathology better, and additionally, help in identifying disease patterns venous diseases, albeit not fatal primarily, do impact quality of life severely, if left untreated. For this very reason, a thorough knowledge of this chapter is quintessential.

BIBLIOGRAPHY

1. Ballard J, Bergan J. Chronic Venous Insufficiency. London: Springer London; 2000.
2. Caggiati A, Bergan J, Gloviczki P, et al. Nomenclature of the veins of the lower limbs: An international interdisciplinary consensus statement. J Vasc Surg. 2002;36(2):416-22.
3. Caggiati A, Bergan JJ, Gloviczki P, et al. International Interdisciplinary Consensus Committee on Venous Anatomical Terminology. Nomenclature of the veins of the lower limb: extensions, refinements, and clinical application. J Vasc Surg. 2005;41(4):719-24.
4. Caggiati A, Bergan JJ. The Saphenous vein: derivation of its name and its relevant anatomy. J Vasc Surg. 2002;35(1):172-5.
5. Caggiati A, Phillips M, Lametschwandtner A, et al. Valves in small veins and venules. Eur J Vasc Endovasc Surg. 2006;32(4):447-52.
6. Carradice D, Chetter I. Minimally invasive treatment of venous insufficiency using endovenous laser ablation. Kingston: University of Hull; 2011.
7. Cavezzi A, Labropoulos N, Partsch H, et al. Duplex ultrasound investigation of the veins in chronic venous disease of the lower limbs—UIP Consensus Document. Part II: Anatomy. Phlebology. Journal Venous Dis. 2006;21(4):168-79.
8. Cavezzi A, Labropous , Partsch H, et al. Duplex Ultrasound Investigation of the Veins in Chronic Venous Disease of the Lower Limbs—UIP Consensus Document. Part II. Eur J Vasc Endovasc Surg. 2006;31(3):288-99.
9. Currie S, Kennish S, Flood K. Essential radiological anatomy for the MRCS. Cambridge: Cambridge University Press; 2009.
10. Delis KT, Knaggs AL, Khodabakhsh P. Prevalence, anatomic patterns, valvular competence, and clinical significance of the Giacomini vein. J Vasc Surg. 2004;40(6):1174-83.
11. Dodd H, Cockett FB. Surgical anatomy of the veins of the lower limb. In: Dodd H, Cockett FB (Eds). The pathology and surgery of the veins of the lower limb. London: E&S Livingstone; 1996. pp. 28-64.
12. Earthslab.com. (2018). Nerves of Foot. [online] Available from https://www.earthslab.com/anatomy/nerves-of-the-foot/. [Accessed December, 2018].
13. Englund R. Duplex Scanning For Recurrent Varicose Veins. ANZ J Surg. 1996;66(9):618-20.
14. Fan CM. How I Decide to Ablate a Refluxing Perforator. Endovascular Today. 2015;2:68-73.
15. Flandershealth.us. (2018). Anatomy of the Lower Extremity Veins—Varicose Veins. [online] Available from https://www.flandershealth.us/varicose-veins/anatomy-of-the-lower-extremity-veins.html. [Accessed December, 2018].
16. Gezamo Z, Gloviczki P. Venous Embryology and Anatomy. In: Bergan JL (Ed). The Vein Book, 1st edition. United Kingdom: Taylor & Francis; 2007. pp. 15-25.
17. Green D. Sclerotherapy for the permanent eradication of varicose veins: Theoretical and practical considerations. J Am Acad Dermatol. 1998;38(3):461-75.
18. Kalra M, Gloviczki P. Surgical treatment of venous ulcers: role of subfascial endoscopic perforator vein ligation. Surg Clin North Am. 2003;83(3):671-705.
19. Kuster G, Lofgren EP, Hollinshead WH. Anatomy of the veins of the foot. Surg Gynecol Obstet. 1968;127(4):817-23.
20. Lanzer P. Panvascular medicine. 2nd edition, UK: Springer; 2009.

JAYPEE BROTHERS

21. Ludbrook J. Musculovenous pumps of the human lower limb. Am Heart J. 1966;71(5):635-41.
22. May R. Nomenclature of the surgically most important connecting veins. In: May R, Partsch H, Staubesand J (Eds). Perforating veins. Baltimore: Urban & Schwartzenberg; 1981. pp. 13-18.
23. Monahan T, Chander R. Ultrasound assessment of great saphenous vein insufficiency. J Vascr Diag. 2015;2015:15-21.
24. Mózes G, Carmichael S, Gloviczki P. Surgical Anatomy of the Veins of the Lower Limb. Persp Vasc Surg. 2000;13(2):0107-16.
25. Mozes G, Carmichael SW, Gloviczi P. Development and anatomy of the venous system. In: Gloviczki P (Ed). Handbook of venous disorders, 2nd edition. London (UK): Arnold publishers; 2001. pp. 14-22.
26. Mozes G, Gloviczki P, Menawat SS, et al. Surgical anatomy for endoscopic subfascial division of perforating veins. J Vasc Surg. 1996;24(5):800-8.
27. Mozes G, Gloviczki P. New Discoveries in Anatomy and New Terminology of Leg Veins: Clinical Implications. Vasc Endovasc Surg. 2004;38(4):367-74.
28. Mühlberger D, Morandini L, Brenner E. Venous valves and major superficial tributary veins near the saphenofemoral junction. J Vasc Surg. 2009;49(6):1562-9.
29. Pascarella L, Mekenas L. Ultrasound Examination of the patient with primary venous insufficiency. In: Bergan JL (Ed). The Vein Book, 1st edition. United Kingdom: Taylor & Francis; 2007. pp. 177-83.
30. Reich-Schupke S, Stücker M. Nomenclature of the veins of the lower limbs—current standards. JDDG. 2010;9(3):189-94.
31. Sam RC, Silverman SH, Bradbury AW. Nerve injuries and varicose vein surgery. Eur J Vasc Endovasc Surg. 2004;27(2): 113-20.
32. Schweighofer G, Mühlberger D, Brenner E. The anatomy of the small saphenous vein: fascial and neural relations, saphenofemoral junction, and valves. J Vasc Surg. 2010;51(4): 982-9.
33. Shah DM, Chang BB, Leopold PW, et al. The anatomy of the greater saphenous venous system. J Vasc Surg. 1986;3(2): 273-83.
34. Sherman RS. Varicose veins: Anatomic findings and an operative procedure based upon them. Ann Surg. 1944;120:222-32.
35. Thomson H. The surgical anatomy of the superficial and perforating veins of the lower limb. Ann R Coll Surg Engl. 1979;61:198-205.
36. Travell J, Simons D. Myofascial pain and dysfunction. Philadelphia: Lippincott Williams and Wilkin; 1992.
37. Uhl J, Gillot C. Anatomy of the veno-muscular pumps of the lower limb. Phlebology: The Journal of Venous Disease. 2014;30(3):180-193.
38. Vaidyanathan S, Ajay K. Chronic venous disorders of the lower limbs. India: Springer India Private; 2016.
39. Vaidyanathan S. Chronic venous disorders of the lower limbs. India: Springer India Private;2016.
40. Zamboni P, Mendoza E, Gianesini S. Saphenous vein-sparing strategies in chronic venous disease. united kingdom: Springer; 2018.
41. Zygmunt J, Pichot O, Dauplaise T. Venous anatomy. Practical Phlebology: Venous Ultrasound. USA: CRC Press; 2013.

JAYPEE BROTHERS

For detailed information on dermatology books, visit our website www.jaypeebrothers.com, for detailed information on dermatology books, visit our website www.jaypee

Leg Ulcers

Diagnosis & Management

Leg ulcers and management is a comprehensive book containing chapters which have been thoroughly updated with latest information, current scientific knowledge on various aspects of etiology and management. It involves the clinical experience of experts across the country and across specialties and is enriched with clinical photographs and tables for better understanding. It serves as a ready reckoner for dermatologists, vascular surgeons and plastic surgeons.



S Sacchidanand MBBS MD DVD DHA FRCP (GI) is presently the Vice Chancellor of Rajiv Gandhi University of Health Sciences, Bengaluru, Karnataka, India. He is the former Director of Medical Education and Dean cum Director of Bangalore Medical College and Research Institute. He is the current President of Association of Cutaneous Surgeons of India (ACSI). He was the President of Indian Association of Dermatologists, Venereologists and Leprologists (IADVL) in 2008. He is also the pioneer in starting the fellowship courses in Dermatosurgery, Aesthetic surgery, Pediatric Dermatology and Trichology at Bangalore Medical College and Research Institute. He has more than 125 research publications to his credit. He has edited many books in Dermatology and is the Chief Editor of IADVL Textbook of 4th edition and upcoming 5th edition.



Eswari L MBBS MD DVL FRGUHS (Dermatosurgery) FAADV (Dermatopathology) is working as an Associate Professor in Department of Dermatology at Bangalore Medical College and Research Institute. She is also the current Joint Secretary of Bangalore Dermatology Society. She has great interest in leg ulcers, Dermatopathology, HIV and STD, Hair Transplantation and Dermatosurgeries. She has completed 6 IADVL projects which were awarded grants. She has a total of 15 national and international publications to her credit. She is also the Assistant Editor of JCAS, CDR, and IJDPDD. She has authored chapters in various books on dermatology.



Shilpa K MBBS MD DVL FRGUHS (Dermatosurgery) is working as an Associate Professor in Department of Dermatology at Bangalore Medical College and Research Institute. She has great interest in Clinical Dermatology, Dermatosurgery and Trichology. She has authored many chapters in various books of dermatology. She has also edited many dermatology books including IADVL Textbook 4th Edition. She has many research publications to her credit.

Available at all medical bookstores
or buy online at www.jaypeebrothers.com

JAYPEE BROTHERS
Medical Publishers (P) Ltd.
www.jaypeebrothers.com

Join us on facebook.com/JaypeeMedicalPublishers

Shelving Recommendation
DERMATOLOGY

ISBN 978-93-5270-939-7